



Anterior interosseous nerve paralysis due to Gantzer's muscle

Ilse DEGREEF, LUC DE SMET

From The University Hospital Pellenberg, Leuven, Belgium

A case of an older female patient with paralysis of the anterior interosseous nerve is reported. During exploration an accessory muscle slip running from the coronoid process of the ulna towards the flexor pollicis longus (Gantzer's muscle) was found compressing the nerve.

CASE REPORT

A 69-year-old female patient noticed impossibility to flex the interphalangeal joint (IP) of her left thumb, immediately after she recovered from an emergency laparotomy. There was no history of trauma or other pathologic conditions. The index and medius finger also felt odd; there was no pain. Physical examination revealed normal passive motion, no specific tenderness, normal sensibility and vascularisation. The left thumb was held in hyperextension of the IP (fig 1). Active flexion of the IP of the left thumb and the DIP (distal interphalangeal joint) of the left index were impossible; making the "O" sign was disturbed (Spinner's sign) (fig 2). Squeezing the muscle mass of the flexors in the forearm provoked slight flexion of the IP of the thumb. Sonography of the forearm and hand was normal. Electromyography disclosed paralysis of the FPL (flexor pollicis longus), PQ (pronator quadratus) and deep flexor to the index finger (FDP II) and partial paralysis of the FDP to the medius. The symptoms remained present for two months without change and an exploration was proposed. The median nerve was explored in the antecubital

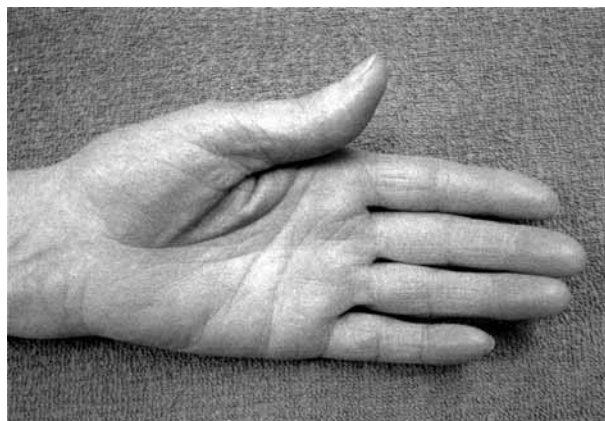


Fig. 1. — Aspect of the hand : note hyperextension of the IP of the thumb.

fossa and anterior forearm. No abnormalities were seen in the proximal part, the fibrous arcade of the superficial flexor was not abnormally tight, the passage of the the median nerve through the pronator teres was not compromised. A muscle belly with a tight fibrous edge was identified, running from the

■ Luc De Smet, MD, PhD, Professor of Orthopaedic Surgery.

■ Ilse Degreef, MD, Orthopaedic fellow.
Orthopaedic Department, U.Z. Pellenberg, Leuven, Belgium.

Correspondence : Luc De Smet, U.Z. Pellenberg, Weligerveld 1, B-3212 Lubbeek, Belgium.

E-mail : luc.desmet@uz.kuleuven.ac.be.

© 2004, Acta Orthopædica Belgica.

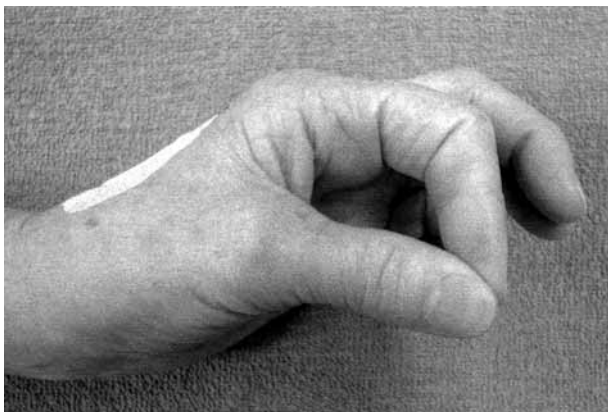


Fig. 2. — Spinner's sign

coronoid process of the ulna, posteriorly (deep) to the median nerve and the anterior interosseous nerve (AIN) and merging distally with the origin of the FPL. The fibrous edge obviously strangled the anterior interosseous nerve and was resected (fig 3).

DISCUSSION

Compression of the median nerve is most common in the carpal tunnel. Compression may occur in other locations, even though the existence of the pronator syndrome has been questioned. Paralysis of the anterior interosseous nerve (AIN) due to compression in the forearm is also called Kiloh-Nevin syndrome (3, 5, 6, 10, 11). The AIN innervates the FPL, PQ and FDP to the index (sometimes also the FDP to the medius). The physical signs are well known : making the "O" sign is disturbed due to the inability to flex the IP of the thumb and the DIP of the index (Spinner's sign) (7). Several causes have been listed : abnormal muscles and tendons, (micro)trauma, vascular arcades and intrinsic compression (7).

The origin of the flexor pollicis longus, in the deep group of flexors of the forearm is on the anterior side of the radius and interosseous membrane ; an additional head running from the ulna posterior to the median nerve and (usually) posterior or (occasionally) anterior to the anterior interosseous nerve has been described as Gantzer's muscle. This

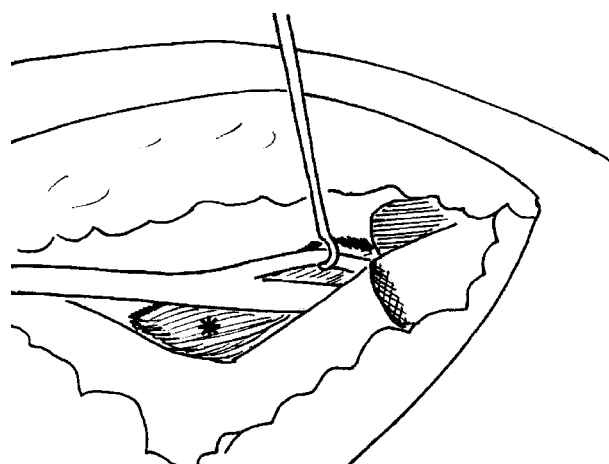
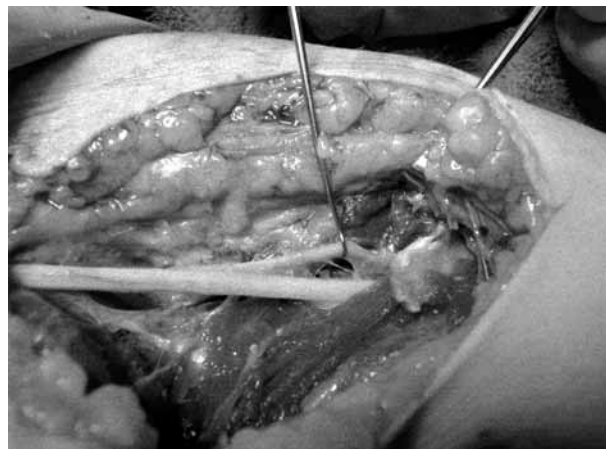


Fig. 3. — Intraoperative view : the anterior interosseous nerve is retracted with a hook; the fibrous edge of Gantzer's muscle is indicated with the arrow. Inset : drawing of the anatomy.

muscle is not rare : it has been noted in up to 40% of cases in cadaver studies. The relationship with the anterior interosseous nerve has been studied by several authors (1, 2, 4, 8, 9). Although this muscle has been suspected to be responsible for the Kiloh Nevin syndrome, clear case reports are rare. Tabib *et al* (12) recently reported a case very similar to ours.

The distinction with rupture of the FPL or locked trigger thumb has to be considered when a patient complains of inability to flex the IP of his thumb (7).

The diagnosis is made clear with an EMG study, provided that the specific muscles are examined.

During exploration it is important to do a careful dissection and to look specifically for fibrous bands or edges compromising the anterior interosseous nerve.

REFERENCES

1. **Al Qattan M.** Gantzer's Muscle. An anatomical study of the accessory head of the flexor pollicis longus. *J Hand Surg* 1996 ; 21 : 269-270.
2. **Dellon A, McKinnon S.** Musculoaponeurotic variations along the course of the median nerve in the proximal forearm. *J Hand Surg* 1987 ; 12-B : 359-363.
3. **Hill N, Howard F, Huffer B.** The incomplete anterior interosseous nerve syndrome. *J Hand Surg* 1985 ; 10-A : 4-16.
4. **Jones M, Abrahams P, Sanudo J, Campillo M.** Incidence and morphology of accessory heads of flexor pollicis longus and flexor digitorum profundus (Gantzer's muscle). *J Anat* 1997 ; 191 : 451-455.
5. **Kaplan E, Spinner M.** The anterior interosseous nerve syndrome. *J Bone Joint Surg* 1969 ; 51-A : 1677-1685.
6. **Kiloh L, Nevin S.** Isolated neuritis of the anterior interosseous nerve. *Br Med J* 1952 ; 1, 850-851.
7. **Lister G.** *The Hand : Diagnosis and Indications.* Churchill Livingstone, Edinburgh, 3rd Ed, pp 292-294.
8. **Mangini U.** Flexor pollicis longus : its morphology and clinical significance. *J Bone Joint Surg* 1960 ; 42-A : 467-470.
9. **Shiali S, Hanson M, Branovacki G, Gonzales M.** The flexor pollicis longus and its relation to the anterior and posterior interosseous nerves. *J Hand Surg* 1998 ; 23-B : 170-172.
10. **Spinner M.** Nerve compression lesions of the forearm, elbow and arm. In : Tubiana R. (ed) *The Hand*, WB Saunders, Philadelphia, Vol 4, 1993, pp 400-432.
11. **Spinner M.** The anterior interosseous nerve syndrome with special attention to its variations. *J Bone Joint Surg* 1970 ; 52-A : 84-94.
12. **Tabib W, Aboufarah F, Assilineau A.** Compression du nerf interosseux antérieur par le muscle de Gantzer. *Chir Main* 2001 ; 20 : 241-246.