



Chondrolipoma of the hand : A case report

Stefan KRÜGER, Bernd KISSE, Anja STAHLBRECHER, Alfred C. FELLER, Josef HOCH

From the Department of Plastic and Reconstructive Surgery, Klinikum Neustadt, and the Institute of Pathology, Medical University of Lübeck, Germany

The authors present the case of a chondrolipoma which was excised from the left hand's palm of an 83-year old woman. Chondrolipomas are rare neoplasms; their terminology and pathogenesis have been controversial in the past. Chondrolipoma in the hand does not seem to have been reported so far. The present case thus expands the spectrum of neoplasms known to arise at this anatomical site.

INTRODUCTION

The hand may be the primary site of a large variety of neoplasms. Most of them are benign in nature. In a series of 543 tumorous lesions of the hand, only 2% proved to be malignant (6). Among the most common types of bone and soft tissue neoplasms of the hand are chondroma, tendon sheath giant cell tumour and lipoma (1).

Chondrolipoma is a rare neoplasm whose terminology and pathogenesis have been described inconsistently by various authors in the past. In the English-language literature, this tumour had not yet been included in the spectrum of hand tumours so far.

CASE REPORT

An 83-year-old woman presented with paraesthesiae in the left hand and swelling of the palm which she had first noticed a few weeks previously. There was no history of trauma. Clinical examination confirmed a tumour-like swelling in the

center of the left palm. Flexion and extension of thumb, forefinger and middle finger were not impaired, but caused slight dull pain in the palm: the latter was swollen. Mobility of the wrist was not affected. Magnetic resonance imaging (MRI) demonstrated a well-circumscribed 4 cm-sized tumour situated on the volar aspect of metacarpals II-IV and compressing the flexor tendons (fig 1). Slight compression of the median nerve was also detectable (not illustrated in fig 1).

Intraoperatively, a well-circumscribed tumour was found resting on the flexor tendons. The complete tumour was shelled out easily (fig 2). The patient's postoperative course was uneventful.

On gross examination, the tumour was composed of fatty tissue with scattered plump white areas reminiscent of cartilage (fig 3). This macro-

-
- Bernd Kisse, MD, Senior Surgical Registrar.
 - Anja Stahlenbrecher, MD, Senior Surgical Registrar.
 - Josef Hoch, MD, Chief of the Department of Plastic and Reconstructive Surgery.

Department of Plastic and Reconstructive Surgery, Klinikum Neustadt, Germany.

- Stefan Krüger, MD, Senior Registrar.
 - Alfred C. Feller, MD, Professor of Pathology.
- Institute of Pathology, Medical University of Lübeck, Germany.*

Correspondence : Stefan Krüger, Institute of Pathology, Medical University of Lübeck, Ratzeburger Allee 160, D-23538 Lübeck, Germany.

E-mail : krueger@patho.uni-luebeck.de.

© 2004, Acta Orthopædica Belgica.

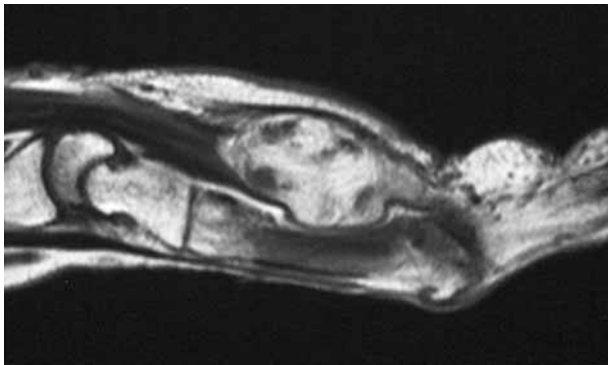


Fig. 1. — MRI scan showing a soft tissue tumour in the hand palm. No infiltrative tumour growth is evident.

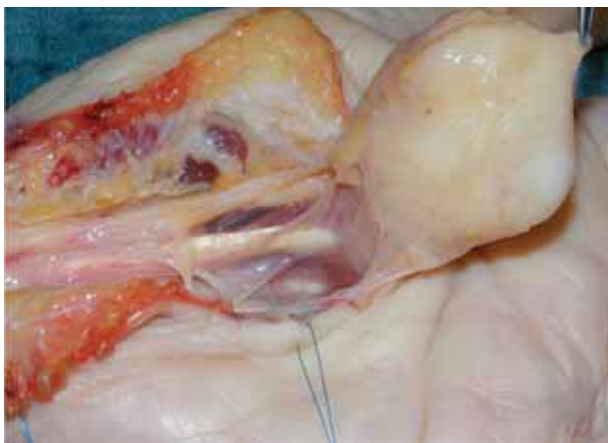

Fig. 2. — Intraoperative view. The well-circumscribed tumour has just been shelled out.

scopic appearance was confirmed by histology : The major component of the tumour was benign adipose tissue, which contained lobules of mature cartilage (fig 4). Lipocytes and chondrocytes lacked any mitotic activity or nuclear atypia. Occasionally, small strands of fibrous tissue were present. The tumour was enclosed within a thin fibrous capsule.

DISCUSSION

Chondrolipomas are rare tumours which can be found in almost any anatomical site, particularly in the connective tissue of the skeletal system, breast,

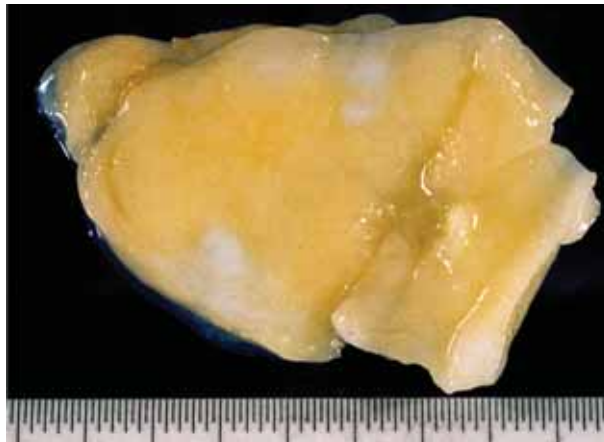

Fig. 3. — Macroscopic view of the cut surface of the tumour. It is predominantly composed of fat (yellow areas), in which lobules of cartilage (white areas) are detectable.

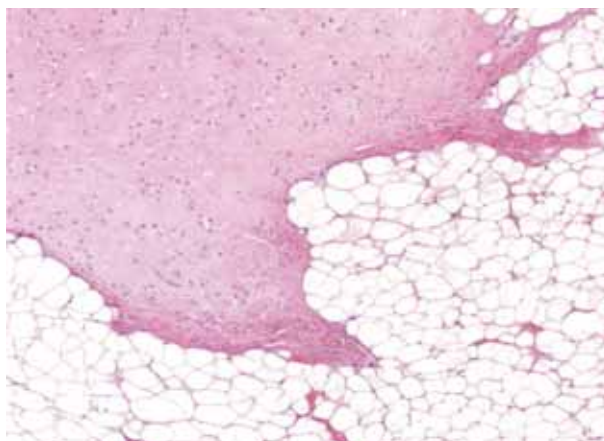


Fig. 4. — Histological examination corresponds to the macroscopic aspect. Mature cartilage (left upper section) is surrounded by mature fat tissue (haematoxylin-eosin, $\times 100$).

and pharynx (3). Concerning the pathogenesis and terminology of these lesions, there has been much debate in the past. In 1948, Stout proposed the term mesenchymoma to designate benign tumours composed of a mixture of two or more nonepithelial elements other than fibrous tissue (9), but this term has now been abandoned due to its lack of specificity. Other terms like choristoma, which defines a tumour-like ectopic rest of normal tissue, and hamartoma, which designates an overgrowth of

mature tissues normally present in the affected site, have also been proposed (2, 7). At present, the most established opinion is that these lesions are true neoplasms (lipomas) with cartilaginous metaplasia and that they should be best referred to as chondrolipomas (5, 10). A recent study reported an abnormal expression of transforming growth factor- β (TGF- β), latent TGF- β binding protein-1 (LTBP-1) and bone morphogenetic protein (BMP) in chondrolipoma (8), which points to a unique pathogenesis of this neoplasm.

Cartilaginous metaplasia in lipomas is an infrequent occurrence, which is predominantly observed in large-sized, long-standing lipomas (3). Because the hand is of utmost importance in activities of everyday life, hand tumours are usually diagnosed and resected at an early stage and rarely achieve a large size. This may provide a possible explanation for the fact that chondrolipoma has not yet been reported at this anatomic site.

Chondrolipomas have no specific radiographic features. The diagnosis is based on histopathological examination. Because morphological differential diagnoses are lacking, the histological diagnosis of a chondrolipoma is straightforward. However, clinicians and pathologists should be aware of the terminological (but not histological) similarity between chondrolipoma and chondroid lipoma. The latter term defines a unique and recently recognised benign adipose tissue tumour containing a chondroid matrix, fat and lipoblasts and therefore resembling myxoid liposarcoma or extraskeletal myxoid chondrosarcoma (4).

Chondrolipomas are best treated by complete surgical excision. Since most reports are confined to a very limited number of cases, no data on recurrence rates of chondrolipomas are available.

Malignant transformation has not been described until now.

In conclusion, we present here the case of a chondrolipoma of the hand which represents, to the best of our knowledge, the first such case described in the English language literature. Therefore, the present case expands the spectrum of neoplasms known to arise at the hand.

REFERENCES

1. **Ariyam S.** Benign and malignant soft tissue tumors of the hand. In : MacCarthy JG (ed). *Plastic Surgery, Vol 7 – The Hand*. WB Saunders, Philadelphia, 1990, pp 5483-5509.
2. **Austin JR, de Tar M, Rice DH.** Pulmonary chondroid hamartoma presenting as an inflatable neck mass. Case report and clinicopathologic analysis. *Arch Otolaryngol Head Neck Surg* 1994 ; 120 : 440-443.
3. **Boltze C, Hribaschek A, Lippert H, Roessner A.** Intermuscular chondrolipoma of the thigh : the diagnostic way of a rare entity. *Pathol Res Pract* 2003 ; 199 : 503-507.
4. **Fletcher CDM, Unni KK, Mertens F.** *WHO classification of tumours : Pathology and genetics of tumours of soft tissue and bone*. IARC Press, Lyon, 2002, p 30.
5. **Fushimi H, Kotoh K, Nishihara K, Fujinaka H, Takao T.** Chondrolipoma of the breast : a case report with cytological and histological examination. *Histopathology* 1999 ; 35 : 478-479.
6. **Johnson J, Kilgore E, Neumeyer W.** Tumorous lesions of the hand. *J Hand Surg* 1985 ; 10 : 284-286.
7. **Metcalfe JS, Ellis B.** Choristoma of the breast. *Hum Pathol* 1985 ; 16 : 739-40.
8. **Nakano M, Arai E, Nakajima Y, Nakamura H, Miyazono K, Hirose T.** Immunohistochemical study of chondrolipoma : possible importance of transforming growth factor (TGF)-beta, latent TGF-beta binding protein-1 (LTBP-1), and bone morphogenetic protein (BMP) for chondrogenesis in lipoma. *J Dermatol* 2003 ; 30 : 189-195.
9. **Stout AP.** Mesenchymoma, the mixed tumor of mesenchymal derivatives. *Ann Surg* 1948 ; 127 : 278.