

# HETEROTOPIC OSSIFICATION FOLLOWING TOTAL HIP ARTHROPLASTY : A REVIEW

by H. P. HU\*, T. J. J. H. SLOOFF\* and J. R. VAN HORN\*\*

**Heterotopic ossification is the most frequent complication of total hip arthroplasty. When formed in the para-articular tissues, it may cause pain and restriction of hip motion. The present article extensively reviews the current literature on heterotopic ossification following total hip arthroplasty with regard to epidemiologic factors, clinical presentation and possible pathogenesis. Preventive measures are emphasized. Postoperative treatment with radiation and nonsteroidal antiinflammatory drugs have yielded good results in the prevention of heterotopic ossification. On the other hand, biphosphonates were ineffective. In comparison with radiation therapy, prophylaxis with nonsteroidal antiinflammatory drugs gave better results. Further research is still needed to define the most effective and safe medication regimen.**

**Keywords :** heterotopic ossification ; total hip arthroplasty ; NSAID.

**Mots-clés :** ossifications hétérotopiques ; arthroplastie totale de hanche ; AINS.

## SAMENVATTING

*H. P. HU, T. J. J. H. SLOOFF en J. R. VAN HORN. Heterotopie ossificaties na totale heup arthroplastieken : een literatuuroverzicht.*

Het ontstaan van heterotopie ossificaties in de peri-articulaire weke delen is de meest voorkomende complicatie van totale heup-ervangingsoperaties en kan aanleiding geven tot pijnklachten en een verminderde heupfunctie. In dit artikel wordt het optreden van heterotopie ossificaties na totale heup arthroplastieken behandeld aan de hand van een uitgebreide literatuurstudie. Naast epidemiologische,

klinische en etiologische aspecten, wordt ruime aandacht besteed aan preventieve maatregelen. Goede resultaten in de preventie van heterotopie ossificaties zijn geboekt met postoperatieve bestraling en toediening van non-steroïdale anti-inflammatoire middelen. De biphosphonaten blijken echter ineffectief te zijn. In vergelijking met bestraling lijkt non-steroïdale anti-inflammatoire therapie minder nadelen op te leveren. Verder onderzoek is vereist om de juiste medicatie-kuur en dosering vast te kunnen stellen.

## RÉSUMÉ

*H. P. HU, T. J. J. H. SLOOFF et J. R. VAN HORN. Ossifications hétérotopiques après arthroplastie totale de hanche : revue de la littérature.*

Les ossifications hétérotopiques postopératoires constituent la complication la plus fréquente après arthroplastie totale de hanche et peuvent donner lieu à des douleurs et à une limitation fonctionnelle.

Les auteurs ont passé en revue une abondante littérature publiée à ce sujet. Après une étude des aspects épidémiologiques, cliniques et étiologiques, ils s'attachent à la prévention. De bons résultats sont obtenus par l'irradiation postopératoire et l'administration d'anti-inflammatoires non-stéroïdiens. Les biphosphonates semblent dépourvu d'effet réel. Par rapport à l'irradiation, les anti-inflammatoires non-stéroïdiens présentent moins d'inconvénients. Une

\* Institute for Orthopedics, St. Radboud Hospital, University of Nijmegen (The Netherlands).

\*\* Department of Orthopedics, Medisch Spectrum Twente, Enschede (The Netherlands).

étude ultérieure sera nécessaire pour définir avec précision la durée et le dosage du traitement.

## INTRODUCTION

Early reports on the results of total hip replacement focused mainly on postoperative infection and implant loosening, while heterotopic ossification (H.O.) was dismissed as a matter of only academic interest (23). Nowadays, it is generally accepted that the formation of heterotopic bone may affect the result of even a well-performed surgical procedure. Hip function may be completely restricted by the development of a bone bridge between proximal femur and lower pelvis, but even small amounts of heterotopic bone may already cause pain and decreased mobility (54).

The etiology of this complication is still not completely understood, but it is obvious that the process of de novo bone formation is initiated by the surgical procedure. Moreover, certain individuals are more prone to develop this complication than others. The only possible treatment for established H.O. is surgical excision, but the recurrence rate is extremely high (29, 31, 81). Preventive measures include postoperative treatment with biphosphonates, radiation and non-steroidal antiinflammatory drugs (NSAIDs). No consensus on the management of H.O. has been reached, although the increased interest in H.O. and its prevention has resulted in numerous and divergent publications, which we review here.

## INCIDENCE

The reported incidence of H.O. following total hip arthroplasty varies widely. Whereas some studies have revealed an incidence of 8% (7, 56), other series have shown much higher frequencies. An incidence as high as 90% was found by Rosendahl *et al.* (85). A review of these incidences is listed in table I. This wide range in frequency may be explained by the use of different criteria for patient selection, varying follow-up periods, and multiple classification systems. Furthermore, minor ossifications were certainly often overlooked in studies which were not mainly concerned with H.O.

Recent studies, dedicated specifically to the problem of H.O. following total hip replacement, may give a more reliable incidence. In all of them, ossifications were found in 60 to 75% of the cases (4, 22, 34, 89, 91, 92, 101). Significant amounts of heterotopic bone, consistent with the highest classes of the gradation systems used, were formed in an average of 25%. This implies that H.O. is the most frequent complication of total hip arthroplasty.

## CLINICAL FEATURES

Although the diagnosis of H.O. is confirmed by radiographic evaluation, some early clinical signs and symptoms may indicate the possibility of this complication. Persistent postoperative pain in the affected hip has often been associated with the formation of heterotopic bone (21, 41, 42, 66, 69, 100). According to Nollen and Slooff (69) the character of this pain is different from that of normal wound pain. Other authors have mentioned prolonged pyrexia as an accompanying clinical symptom (41, 44), as well as reddening of the overlying skin (42). Once the process of bone formation has stabilized, pain is no longer a feature (29, 54, 66, 81, 91).

It is generally agreed that large and bridging ossifications may restrict hip motion (2, 4, 21, 23, 29, 42, 43, 44, 47, 59, 66, 69, 79, 81, 91), but it is not clear whether the functional result is affected by all degrees of heterotopic bone. Kromann-Andersen *et al.* (54) stated that even small amounts reduce the range of hip motion, and that this reduction is directly proportional to the degree of ossification.

Rosendahl *et al.* (85) introduced Trendelenburg's sign as a measure of the degree of H.O. They assumed that heterotopic bone is usually formed in the gluteus medius and would cause weakness of this muscle, Ahrengart *et al.* (4), however, found a negative correlation at 6 weeks postoperatively, while hip muscle strength appeared to be unaffected.

## LABORATORY TESTS

Laboratory tests are usually of little value in diagnosis. The erythrocyte sedimentation rate

(ESR) and the white blood cell count (WBC) are within normal range, and are useful only to distinguish this complication from postoperative infection (42, 54, 69, 98). However, in the study of Kjaersgaard-Andersen *et al.* (52) patients with severe ossifications had a significantly elevated ESR at 6 and 12 weeks post operation, indicating that an inflammatory process is part of the development of the complication. Furthermore, a correlation with increased serum alkaline phos-

phatase activity has been found at 3 weeks postoperatively (69), while a distinct rise above 250 IU/l at 12 weeks postoperatively was considered as a predictor of severe ossifications (51). However, the prospective study of Mollan (65) did not support these findings. Measurements of serum calcium, phosphate and muscle enzymes such as creatinephosphokinase or lactodehydrogenase give no additional information (69).

Table I. — Incidence of heterotopic ossification following total hip arthroplasty

Series	Minimal period of follow-up	No. of operations	Total incidence of H.O. (%)	Significant H.O. (%)
Amstutz 1970	1 y.	50	8	ns.
Hamblen and Harris 1971	ns.	422	20	3 (b)
Charnley 1972	4 y.	379	ns.	5 (d)
Brooker <i>et al.</i> 1973	6 mo.	100	21	9 (a)
Nollen & Slooff 1973	1 y.	200	53	7 (d)
Johnston 1973	ns.	326	12	2 (d)
Lazansky 1973	6 mo.	501	8	0.5 (d)
Hanslik & Radloff 1974	1 y.	356	36	7 (d)
Matos <i>et al.</i> 1975	ns.	221	41	13 (d)
Ornshold & Esperen 1975	ns.	121	45	6 (d)
Caron 1976	ns.	2424	35	7 (d)
Delee <i>et al.</i> 1976	1 y.	2173	15	11 (c)
Riegler & Harris 1976	4 mo.	102	50	9 (d)
Salvati <i>et al.</i> 1976	1 y.	100	39	3 (d)
Taylor <i>et al.</i> 1976	6 mo.	370	36	5 (d)
Rosendahl <i>et al.</i> 1977	2 y.	70	90	24 (d)
Jowsey <i>et al.</i> 1977	1 y.	224	ns.	12 (d)
Ritter & Vaughan 1977	2 y.	507	30	2 (b)
Beckenbaugh & Ilstrup 1978	4 y.	255	ns.	5 (c)
Mollan 1979	2 y.	131	18	ns.
Kromann-Andersen <i>et al.</i> 1980	3 mo.	356	49	17 (c)
Blasingame <i>et al.</i> 1981	1 y.	69	81	17 (a)
Hieron <i>et al.</i> 1983	3 y.	237	ns.	24 (d)
Morrey <i>et al.</i> 1984	ns.	507	78	27 (c)
Errico <i>et al.</i> 1984	6 mo.	100	58	17 (c)
Bundrick <i>et al.</i> 1985	5 y.	236	64	14 (a)
Thomas & Amstutz 1985	3 y.	200	66	18 (a)
Ritter & Sieber 1985	5 y.	525	26	1 (b)
Soballe <i>et al.</i> 1988	5 y.	129	63	44 (c)
Schmidt <i>et al.</i> 1988	1 y.	99	73	48 (c)
Sodeman <i>et al.</i> 1988	ns.	150	67	23 (a)
Testa & Mazur 1988	6 mo.	90	60	11 (a)
Fahrer <i>et al.</i> 1988	5 y.	204	62	15 (a)
Cella <i>et al.</i> 1988	6 mo.	64	67	11 (a)
Ahrengart <i>et al.</i> 1989	1 y.	145	75	21 (a)

Significant ossifications were defined as those consistent with the highest classes of the gradation system used; (a) = Brooker III-IV, (b) = Hamblen 3, (c) = Delee 2-3, and (d) = author's own classification (ns. = not stated).

## RADIOLOGY

The definite diagnosis of H.O. is made radiographically. The first signs are seen 2 to 3 weeks postoperatively as vague opacities in the soft tissues of the gluteal region, where they may be easily overlooked (69). At 6 to 12 weeks postoperatively, most of the cases may be diagnosed by increased density of the newly formed bone (25, 81), and after 1 year the formation and maturation of most cases will have stabilized (29, 91). It has been demonstrated, though, that ossifications may increase up to 5 years postoperatively (54).

To classify the extent of heterotopic bone on AP-radiographs, more than 15 different classifications have been developed. In general, they divide H.O. into 3 to 5 classes according to its volume, localization, restrictive effect on motion, or a combination of these factors. The most commonly used classification has been proposed by Brooker *et al.* (18). They use 4 numerical classes, in which the heterotopic bone is classified mainly according to its restrictive effect on hip function (fig. 1). The most important difference is found between Class II and Class III ossifications, where the gap between the opposing bone surfaces is larger or smaller than 1 cm. Although arbitrary, the criterion is useful to identify the more severe ossifications. The volume of heterotopic bone, however, is not taken into account, so that both very large and very small ossifications may be classified as equal. Therefore, the classification system of Hamblen and Harris (41) has been adopted by several authors for further evaluation of soft tissue involvement (9, 22, 58, 72). In combination with the classification of Brooker, the amount of H.O. can be assessed as involving less than 1/3 (grade 1), between 1/3 and 2/3 (grade 2), or more than 2/3 (grade 3) of the soft tissues around the hip. In this way, the restrictive effect of H.O. as well as its volume can be diagnosed in a convenient way. Another frequently used classification system is that of Delee *et al.* (29), in which the amount of H.O. is graded as occupying less or more than 50% of the distance between acetabulum and femur (Class 1 & 2), or as a bridging ossification (Class 3).

## HIGH RISK FACTORS

### Gender and age

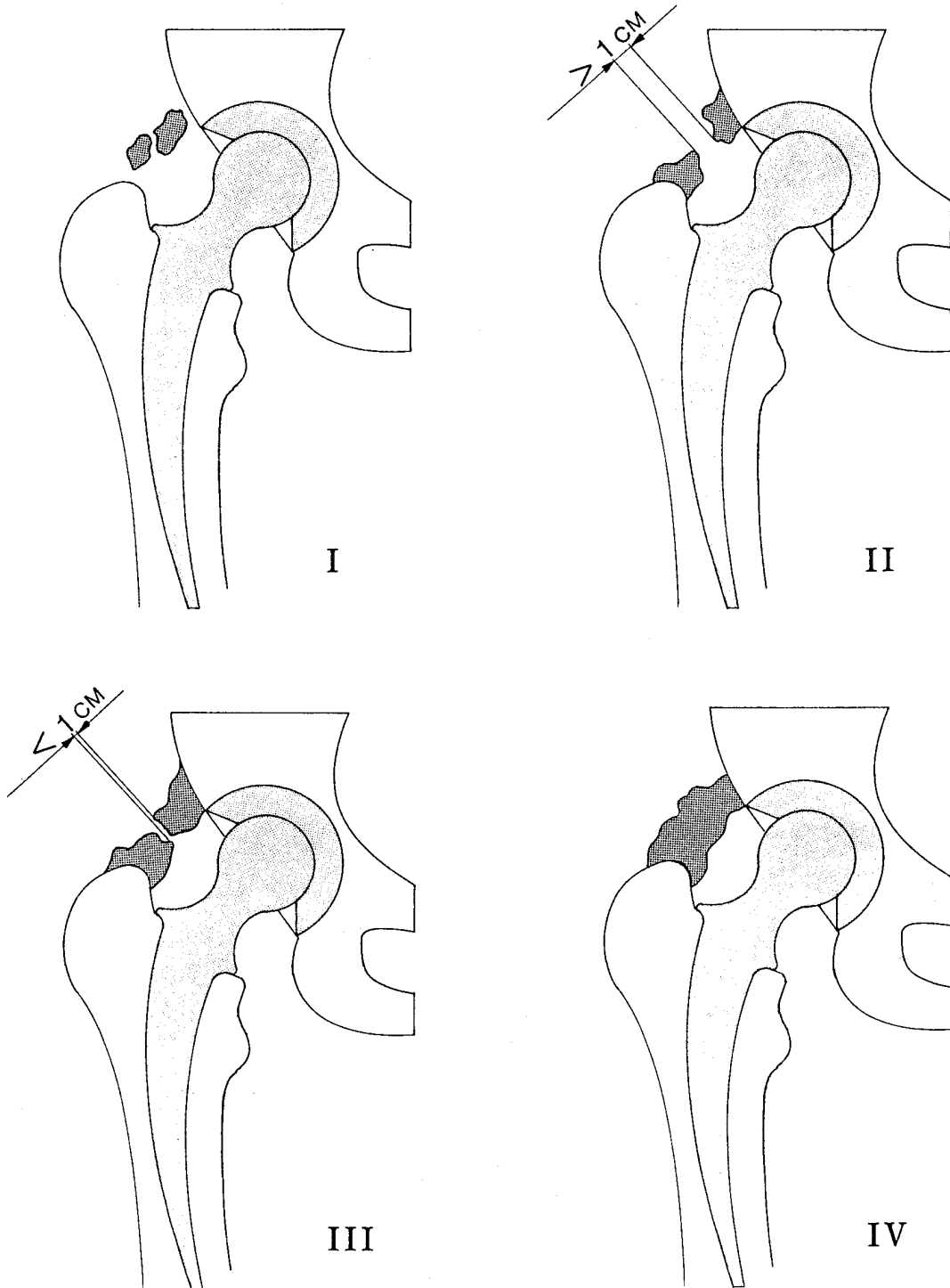
Males are more at risk to develop H.O. than females (29, 44, 54, 56, 59, 66, 81, 91, 92). In the study of Delee *et al.* (29), the incidence was distributed over both sexes in a ratio of 2 to 3 males to 1 female. Although this may result from a genetic predisposition, it can also be explained by surgical difficulties. Males generally have greater muscle bulk, and may require a more traumatic surgical approach (44), and a more aggressive rehabilitation program (42). The positive correlation with high body weight (21, 44) supports this assumption. Salvati *et al.* (86), however, could not find a correlation with gender, and Riegler and Harris (79) reported that the clinically serious ossifications were more frequently found in females.

Hierton *et al.* (44) have reported that advanced age may be a risk factor, but other workers could find such a positive correlation only in women above 65 years (4, 56).

### Primary disease

The primary disease that necessitates total hip replacement may be an important determinant of the occurrence of H.O. An increased incidence is found in hips that are stiffer preoperatively, and in hypertrophic osteoarthritis with formation of extensive marginal osteophytes (4, 29, 56, 59, 81). A higher incidence is also found in diseases with an "ossifying diathesis", such as DISH (Diffuse Idiopathic Skeletal Hyperostosis) (15, 34), and ankylosing spondylitis (14, 47, 81, 100). Both conditions are more or less associated with certain HLA antigens, but in H.O. no correlation with HLA antigens has been detected (39, 60, 53).

Remarkably, patients with rheumatoid arthritis (although not ankylosing spondylitis) have shown lower incidences of H.O. compared to patients with osteoarthritis (29, 44, 69, 81, 100). It is strongly suspected that the frequently used NSAIDs, which are effective inhibitors of H.O., have contributed to the low incidence in this group of patients.



**Fig. 1.** — Classification of heterotopic ossification according to Brooker *et al.* (1973).

- Class I : Islands of bone within the soft tissue around the hip.
- Class II : Bone spurs from the pelvis or proximal end of the femur, leaving at least one centimeter between opposing bone surfaces.
- Class III : Bone spurs from the pelvis or proximal end of the femur, reducing the space between opposing bone surfaces to less than one centimeter.
- Class IV : Apparent bone ankylosis of the hip.

### Previous procedures

The incidence of H.O. is increased in total hip arthroplasties after previous hip procedures (18, 79). Delee *et al.* (29) supposed that previous hip surgery was a risk factor only if that surgery was followed by the formation of heterotopic bone. In their study, 22 patients with H.O. following previous hip procedures all showed recurrence after hip replacement and resection of the ossifications. Other authors have found similar recurrence rates (33, 81).

Another interesting phenomenon is that patients with previous H.O. after his arthroplasty are at very high risk to develop the complication after contralateral total hip replacement (59, 69, 81, 91, 92).

### Type of prosthesis and surgical approach

It is not clear whether the type of prosthesis seriously influences the development of H.O. Although some authors have reported a positive correlation with the CAD prosthesis (44) and the Charnley prosthesis (81), no significant differences can be derived from other studies (18, 43, 79). On the other hand, cup-arthroplasty has shown a higher incidence than total hip replacement (18, 41). Hamblen and Harris (41) have suggested that this was caused by the anterior Smith-Petersen approach, which leads to greater trauma from prolonged muscle ischemia and muscle damage than the lateral approach. Likewise, Rosendahl *et al.* (85) assumed that the high incidence of H.O. in their study (90%) was caused by the McFarland-Osborne procedure with stripping of the periosteum of the greater trochanter.

Trochanteric osteotomy has also been implicated in H.O. (32, 69, 71, 76, 103). Morrey *et al.* (66) compared the anterolateral, transtrochanteric and posterior approach in relation to H.O. Although a slight increase in the incidence of bridging ossifications was observed with the transtrochanteric route, no significant differences could be detected among the three surgical approaches. Testa and Mazur (101) found similar results after comparison of the direct lateral and the transtrochanteric approach.

### Peri- and postoperative complications

Factors implicated in the perioperative period include difficult surgical exposures (21, 79), long operations (21, 44, 91), and increased blood loss (91). Postoperatively, the formation of wound hematoma (21, 79), superficial and deep wound infection (21, 73, 86), and dislocation of the prosthesis (7, 47), especially when this occurs in the first week postoperatively (10), have been shown to increase the risk of H.O. These complicating factors also indicate the important role of tissue trauma in the formation of heterotopic bone.

In conclusion, the presence of various individual and perioperative factors may have important consequences for the development of H.O. following total hip arthroplasty. The typical high-risk patient is a male with limited preoperative hip motion and osteoarthritis with extensive marginal osteophytes or DISH or ankylosing spondylitis. He has had previous ipsilateral hip surgery or has developed H.O. after contralateral hip arthroplasty, while the present procedure was difficult and attended by extensive tissue trauma.

### PATHOGENESIS

There is no doubt that surgical intervention is a prerequisite for H.O. to occur. However, it remains unknown exactly how the process of bone formation is activated. H.O. involves the formation and mineralization of bone matrix at extraskelatal sites. The final product shows a lamellar bone structure with secondary Haversian systems and hemopoietic bone marrow (21, 47, 69), but may have a higher metabolic activity than normal bone (77). Distinction must be made from heterotopic calcification, which refers to the precipitation of calcium-phosphate crystals in extraskelatal tissues as a function of the local pH and the concentration gradients (47).

For the formation of bone matrix, the presence of osteoblasts at the site of ossification is necessary. These osteoblasts originate from mesenchymal precursor cells by cellular differentiation. On the basis of his experiments with transitional epithelium-induced bone, Friedenstein (38) postulated

that there are two types of osteogenic precursor cells : determined and inducible ones. The determined osteogenic precursor cells (DOPC) are found only within the stromal tissue of bone marrow and have the capacity to differentiate into bone forming cells at other sites without any stimulus. The inducible osteogenic precursor cells (IOPC), on the other hand, need a certain inducing agent to display their osteogenic activities. The IOPC are not only present in bone-marrow tissue, but can also be derived from the connective tissue framework of muscles and tendons, and the peripheral blood circulation. Several authors have suggested that the dispersion of bone-marrow particles, and therefore the DOPC, into the operation wound elicits the process of H.O. (16, 24, 78). However, this hypothesis appears less likely when H.O. occurs in the gluteus medius muscle ; it is improbable that the marrow particles reach the center of this muscle (3).

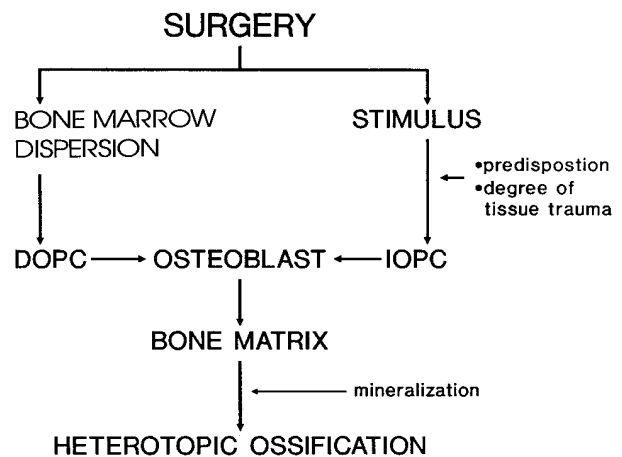
Other authors have proposed that uncommitted mesenchymal cells, corresponding to the IOPC, are responsible for H.O. (25, 47). These cells are already present at the site of ossification, and turn into bone forming cells after receiving an adequate stimulus. Experimental studies have revealed an increasing number of regulating factors for the proliferation and differentiation of osteogenic precursor cells. Among them are bone morphogenetic protein (BMP) and a variety of growth factors (108). The release of such a stimulating factor during surgery may initiate the IOPC and therefore H.O. However, the magnitude of the stimulus and the biological responsiveness to the stimulus are of great importance, so that the extent of bone formation depends on the interaction between them (92). With regard to risk factors, it may be assumed that this interaction is influenced by the individual constitution and the degree of operation trauma.

In Fig. 2, the possible pathways of the pathogenesis of H.O. following total hip arthroplasty are summarized.

**THERAPY**

No therapy is recommended for asymptomatic cases. The only treatment for established H.O.

which leads to pain or functional impairment consists of surgical removal. The newly formed bone, however, must be mature before excision to reduce the risk of recurrence. Although the degree of maturity can be estimated on postoperative radiographs, the serum alkaline phosphatase level and especially the bone scan are more reliable indicators (104). Nevertheless, the recurrence rate after excision of H.O. still remains very high. Fahmy and Wroblewski (33) have found that the ossification recurred in 21 out of 23 revision cases (91%), and usually in greater amounts. Similar findings have been reported after resection of H.O. in patients with spinal cord injury (40). Since free fat transplants may prevent excessive scarring of the dura mater after laminectomy operations (55), Riska and Michelsson (80) introduced this technique to prevent the recurrence of H.O. after resection. Although they and subsequently Abrahamsson *et al.* (1) obtained good results with this method, the number of patients in their studies (7 and 4, respectively) is too small to draw definite conclusions.



**Fig. 2.** — Possible pathways of heterotopic ossification following total hip arthroplasty. Surgical intervention may activate the process of bone formation by the dispersion of bone-marrow particles containing determined osteogenic precursor cells (DOPC), or by producing a stimulus for the inducible osteogenic precursor cells (IOPC) present in the connective tissues. The response of the IOPC to the stimulus probably depends on the individual constitution and the degree of tissue trauma. Subsequently, the mesenchymal precursor cells differentiate into osteoblasts, which produce bone matrix. After mineralization and maturation, heterotopic bone with the same structure as normal bone is formed.

that there are two types of osteogenic precursor cells : determined and inducible ones. The determined osteogenic precursor cells (DOPC) are found only within the stromal tissue of bone marrow and have the capacity to differentiate into bone forming cells at other sites without any stimulus. The inducible osteogenic precursor cells (IOPC), on the other hand, need a certain inducing agent to display their osteogenic activities. The IOPC are not only present in bone-marrow tissue, but can also be derived from the connective tissue framework of muscles and tendons, and the peripheral blood circulation. Several authors have suggested that the dispersion of bone-marrow particles, and therefore the DOPC, into the operation wound elicits the process of H.O. (16, 24, 78). However, this hypothesis appears less likely when H.O. occurs in the gluteus medius muscle ; it is improbable that the marrow particles reach the center of this muscle (3).

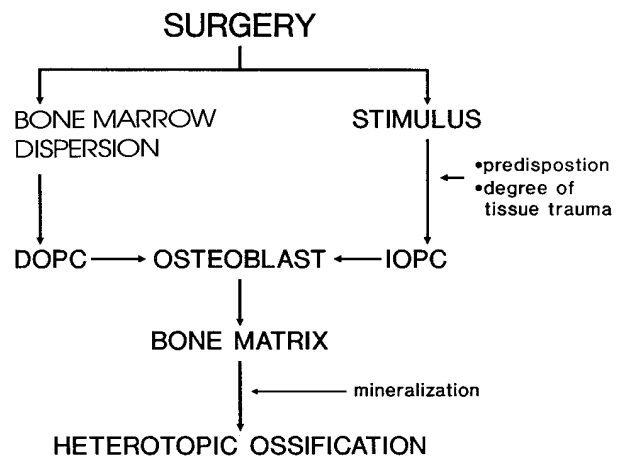
Other authors have proposed that uncommitted mesenchymal cells, corresponding to the IOPC, are responsible for H.O. (25, 47). These cells are already present at the site of ossification, and turn into bone forming cells after receiving an adequate stimulus. Experimental studies have revealed an increasing number of regulating factors for the proliferation and differentiation of osteogenic precursor cells. Among them are bone morphogenetic protein (BMP) and a variety of growth factors (108). The release of such a stimulating factor during surgery may initiate the IOPC and therefore H.O. However, the magnitude of the stimulus and the biological responsiveness to the stimulus are of great importance, so that the extent of bone formation depends on the interaction between them (92). With regard to risk factors, it may be assumed that this interaction is influenced by the individual constitution and the degree of operation trauma.

In Fig. 2, the possible pathways of the pathogenesis of H.O. following total hip arthroplasty are summarized.

**THERAPY**

No therapy is recommended for asymptomatic cases. The only treatment for established H.O.

which leads to pain or functional impairment consists of surgical removal. The newly formed bone, however, must be mature before excision to reduce the risk of recurrence. Although the degree of maturity can be estimated on postoperative radiographs, the serum alkaline phosphatase level and especially the bone scan are more reliable indicators (104). Nevertheless, the recurrence rate after excision of H.O. still remains very high. Fahmy and Wroblewski (33) have found that the ossification recurred in 21 out of 23 revision cases (91%), and usually in greater amounts. Similar findings have been reported after resection of H.O. in patients with spinal cord injury (40). Since free fat transplants may prevent excessive scarring of the dura mater after laminectomy operations (55), Riska and Michelsson (80) introduced this technique to prevent the recurrence of H.O. after resection. Although they and subsequently Abrahamsson *et al.* (1) obtained good results with this method, the number of patients in their studies (7 and 4, respectively) is too small to draw definite conclusions.



**Fig. 2.** — Possible pathways of heterotopic ossification following total hip arthroplasty. Surgical intervention may activate the process of bone formation by the dispersion of bone-marrow particles containing determined osteogenic precursor cells (DOPC), or by producing a stimulus for the inducible osteogenic precursor cells (IOPC) present in the connective tissues. The response of the IOPC to the stimulus probably depends on the individual constitution and the degree of tissue trauma. Subsequently, the mesenchymal precursor cells differentiate into osteoblasts, which produce bone matrix. After mineralization and maturation, heterotopic bone with the same structure as normal bone is formed.



Other therapies, such as medication with corticosteroids or biphosphonates, are ineffective in established ossification. Therefore, this complication should be managed by prophylactic measures.

### PREVENTION

In view of the role of tissue trauma in the pathogenesis of H.O., prevention must be started during the surgical procedure. The tissues must be handled with care, and the operation wound should be carefully cleansed of bone-marrow particles and bony splinters. Additional preventive measures are recommended in patients at risk for H.O. Nowadays, pharmaceutical agents such as biphosphonates and nonsteroidal antiinflammatory drugs, and radiation therapy have become available for this purpose.

#### Biphosphonates

Based on the initial reports on the use of HEBP (1-hydroxy, ethylidene-1,1-biphosphonate, formerly HEBP) in myositis ossificans progressiva (11) and Paget's disease (90), this compound was tried in the prevention of H.O. following total hip arthroplasty (13, 69). The principal pharmacologic action of HEBP and other biphosphonates consists of a reduction of bone mineralization and bone resorption (37, 46, 49, 87), and it was thought that these effects would also influence the formation of H.O.

Bijvoet *et al.* (13) have found that the radiological appearance of ossifications was significantly less in HEBP-treated patients. However, after the discontinuation of the treatment, the incidence of H.O. rapidly approached that of untreated patients. Nevertheless, it was believed that with HEBP treatment the ossifications were less painful and caused less functional impairment. Similar findings have been reported by other authors (35, 36, 95, 97).

Since the effect of HEBP is only evident during its administration, prolongation of the postoperative treatment from 3 to 6 months has been proposed (35, 95). However, this would seriously increase the risk of adverse effects, especially osteomalacia. The results of the study of Thomas

and Amstutz (102) strongly discourage the use of HEBP for the prevention of H.O. In treated patients, both the incidence and amount of heterotopic bone appeared to be increased, while neither the range of motion nor the ratings for pain were significantly affected. Plasmans *et al.* (74, 75) have demonstrated that HEBP does not inhibit the formation of experimentally-induced heterotopic bone matrix, but only delays its mineralization. Therefore, the initially formed H.O. can not be detected radiographically until mineralization occurs after discontinuation of the HEBP medication. These findings, together with the clinical results, indicate that preventive treatment with HEBP is ineffective.

#### Radiation therapy

Coventry and Scanlon (26) introduced radiation therapy to prevent H.O. following total hip arthroplasty. The rationale for this therapy is that irradiation destroys the precursors of bone-forming cells, and may arrest the process of H.O. in an early stage of bone formation. Their treatment consisted of a total dose of 2,000 rads, delivered in 10 fractions over a period of 12 days. Although the occurrence of ossifications was not prevented in all cases, the heterotopic bone formed after irradiation was significantly less severe. When started too late, no effect from postoperative radiation therapy can be expected. Similar results are reported by other workers (19, 61, 72, 110). Apart from an increased risk of malignancy, irradiation may have a detrimental effect on the healing process of trochanteric osteotomies. Non-union has been reported to occur in 11 to 43% of the cases (26, 72). To reduce these risks, Ayers *et al.* (9) lowered the total dose of 2,000 rads to 1,000 rads, given in 5 fractionated portions. This low dose was as effective in preventing H.O. as the higher dose (8, 17, 99). Moreover, even a single dose of 700 rads, given within 3 days postoperatively, effectively replaced the higher fractionated courses (58). Important benefits of this single-dose method include less manipulation of the patient directly after surgery and a reduction in the costs and length of hospitalization.

## NSAIDs

The nonsteroidal antiinflammatory drugs (NSAIDs) are frequently used in rheumatic diseases to relieve pain and to restore mobility. The use of these drugs, especially indomethacin, in the prevention of H.O. is based only on empirical findings. Dahl (27) was the first to observe that analgesic therapy after total hip replacement with indomethacin reduced the occurrence of H.O. Subsequently, Almasbakk and Roysland (6) studied the effect of indomethacin on 27 total hip arthroplasties compared to 54 nontreated hip replacements. Indomethacin, given in a dose of 25 mg 3 times daily during 4 postoperative weeks, significantly decreased the incidence and severity of H.O. Similar results with indomethacin prophylaxis were obtained in several other studies on high-risk patients (22, 50, 82, 83, 93). Also in patients undergoing resection of H.O. after previous total hip replacements, the recurrence of H.O. was effectively prevented by indomethacin (50, 57, 82, 88, 94, 96).

Clear evidence can be derived from a double-blind trial of Schmidt *et al.* (89). Of the 201 patients involved, 102 patients received indomethacin in a dose of 25 mg 3 times daily for 6 weeks after hip replacement, while the remaining 99 patients only received a placebo. One year postoperatively, the group of treated patients showed an incidence of H.O. of 13% (all Delee Grade I), whereas the placebo-treated patients revealed a total incidence of 72%, of which 18% were bridging ossifications (Delee Grade III).

Likewise, NSAIDs other than indomethacin have proved their effectiveness in the prevention of H.O. following total hip arthroplasty. Ibuprofen, administered in a dose of 400 mg 3 times daily for the first 3 months postoperatively, gave favorable results (30), as did diclofenac (111). Effective salicylate prophylaxis in children with head injuries has been reported by Mital *et al.* (64). Hence, it is clear that the postoperative administration of indomethacin and other NSAIDs is a successful means of prevention of H.O. following total hip arthroplasty.

The mode of action by which NSAIDs interfere with the process of heterotopic bone formation

remains speculative. Experimental studies have demonstrated that indomethacin delays fracture healing and bone remodelling (5, 31, 84) and decreases bone formation on implantation of demineralized bone matrix (67, 68, 105, 106). It was assumed that the antiinflammatory properties, due to the inhibition of prostaglandin synthesis (109), were mainly responsible for these effects of indomethacin. The initial inflammatory reaction following fracture trauma and implantation of bone matrix is diminished. As a result, fracture repair and bone induction are disturbed. Alternatively, it was presumed that a decrease in prostaglandins may affect the proliferation of mesenchymal cells necessary for bone formation (28, 31).

The inhibitory effect of indomethacin and other NSAIDs on H.O. following total hip replacement may be explained in a similar way. These drugs diminish the immediate postoperative inflammatory reaction, which may play an important role in activating the process of bone formation by recruiting osteogenic mesenchymal cells or by sensitizing them to an inductive stimulus (93). An important consequence of this assumption is that effective prophylactic treatment with NSAIDs must be started in the recovery room or even before operation. This is supported by a study on induced H.O., in which indomethacin reduced bone formation only when administered before or at the beginning of the experiment (106). Furthermore, the treatment period of 6 weeks or longer may be shortened. Indeed, a postoperative treatment for 3 weeks has been shown as effective as the longer treatment periods (93). A recent study, in which indomethacin was administered for 10 postoperative days, indicates that the duration may be shortened even further (62).

Despite the convenience of this type of prophylaxis, it should be noted that NSAIDs may exert undesirable effects. Cella *et al.* (22) found that one-third of their patients at high risk for H.O. could not safely receive or tolerate indomethacin. Most adverse reactions involve the gastrointestinal tract and the central nervous system, but the NSAIDs may also inhibit platelet aggregation and interact with protein-bound anticoagulants, resulting in an increased bleeding time. Hence, these drugs should

be administered with caution in patients with a history of peptic ulceration or who are receiving anticoagulant or thrombolytic agents. Furthermore, it has been demonstrated that NSAIDs may affect bone ingrowth in laboratory animals (48), and it is feared that the same may happen in uncemented bone-ingrowth prostheses. On the other hand, no deleterious effects of indomethacin and other NSAIDs on the union of trochanteric osteotomies have been encountered to date (30, 82, 83).

### CONCLUSIONS

H.O. is certainly the most frequent complication of total hip arthroplasty; the total incidence is 60 to 75%, while significant amounts of heterotopic bone are formed in approximately 25% of all cases. The pathogenesis is still not understood, but it is presumed that the stimulus for H.O. is elicited by surgical intervention. The response of osteogenic mesenchymal cells to this stimulus largely depends on the extent of tissue trauma with its inflammatory reaction and on the individual constitution.

Since severe ossifications can only be treated by removal on reoperation, the use of prophylactic measures is justified in high-risk patients. In this respect, irradiation and NSAIDs have revealed favorable results in the prevention of H.O., most probably by interference with the early stage of bone formation. On the other hand, preventive treatment with biphosphonates has been shown to be ineffective. In comparison to radiation therapy, the administration of NSAIDs has several advantages; it does not require manipulation or transportation of the patient in the postoperative period, and it is inexpensive. Furthermore, NSAIDs do not increase the risk of malignancy, and appear to have no effect on the union of trochanteric osteotomies. However, care should be taken when NSAIDs are administered in combination with anticoagulants, and in patients with a previous history of peptic ulcers.

The effective preventive dose of indomethacin is 25 to 50 mg 3 times daily, given directly after operation and continued for 3 weeks. Probably, the same preventive effect could be obtained with

a shortened treatment duration or a lower dosage. This would also decrease the adverse effects. Moreover, it must be decided whether NSAIDs can be used prophylactically in the same way as antibiotics in total hip replacements. Further research is needed to answer these questions and to define the most effective and safe medication regimen. In order to reach this goal, it is essential to elucidate the pathogenesis of H.O. Besides clinical studies, experimental studies, in which H.O. is induced by implantation of demineralized bone matrix (107) or by trauma (63), may be very useful.

### REFERENCES

1. ABRAHAMSSON S. O., AHLGREN S. V., DAHLSTRÖM J. A., OHLIN P., STIGSSON L. Ectopic bone after hip replacement. Excision and free fat transplants in four cases. *Acta Orthop. Scand.*, 1984, 55, 589-592.
2. AHRENGART L., SAHLIN K., LINDGREN U. Myositis ossificans after total hip replacement and perioperative muscle ischemia. *J. Arthroplasty*, 1987, 2, 65-69.
3. AHRENGART L. *Trauma-induced heterotopic bone formation. Clinical studies on patients undergoing total hip replacement, and experimental studies in the rabbit.* Thesis. Karolinska Institute, Stockholm, Sweden, 1989.
4. AHRENGART L., LINDGREN U. Functional significance of heterotopic bone formation after total hip arthroplasty. *J. Arthroplasty*, 1989, 4, 125-131.
5. ALLEN H. L., WASE A., BEAR W. T. Indomethacin and aspirin: effect of nonsteroidal anti-inflammatory agents on the rate of fracture repair in the rat. *Acta Orthop. Scand.*, 1980, 51, 595-600.
6. ALMASBAKK K., ROYSLAND P. Does Indomethacin (IMC) prevent postoperative ectopic ossification in total hip replacement? *Acta Orthop. Scand.*, 1977, 48, 556.
7. AMSTUTZ H. C. Complications of total hip replacement. *Clin. Orthop.*, 1970, 72, 123-137.
8. ANTHONY P., KEYS H., EVARTS C. M., RUBIN P., LUSH C. Prevention of heterotopic bone formation with early postoperative irradiation in high risk patients undergoing total hip arthroplasty: comparison of 10.00 Gy vs 20.00 Gy schedules. *Int. J. Rad. Onc. Biol. Phys.*, 1987, 13, 365-369.
9. AYERS D. C., EVARTS C. M., PARKINSON J. R. The prevention of heterotopic ossification in high-risk patients by low-dose radiation therapy after total hip arthroplasty. *J. Bone Joint Surg.*, 1986, 68-A, 1423-1430.
10. AZCARATE J. R., DE PABLOS J., CORNEJO F., CANADELL J. Postoperative dislocation: a risk factor

- for periprosthetic ectopic ossifications after total hip replacement. *Acta Orthop. Belg.*, 1986, 52, 145-150.
11. BASSET C. A. L., DONATH A., MACAGNO F., PREISIG R., FLEISCH H., FRANCIS M. D. Diphosphonates in the treatment of myositis ossificans. *Lancet*, 1969, II, 845.
  12. BECKENBAUGH R. D., ILSTRUP DE. M. Total hip arthroplasty. A review of three hundred and thirty-three cases with long follow up. *J. Bone Joint Surg.*, 1978, 60-A, 306-313.
  13. BIJVOET O. L. M., NOLLEN A. J. G., SLOOFF T. J. J. H., FEITH R. Effect of a diphosphonate on pararticular ossification after total hip replacement. *Acta Orthop. Scand.*, 1974, 45, 926-934.
  14. BISLA R. S., RANAWAT C. S., INGLIS A. E. Total hip replacement in patients with ankylosing spondylitis with involvement of the hip. *J. Bone Joint Surg.*, 1976, 58-B, 233-238.
  15. BLASINGAME J. P., RESNICK D., COUTTS R. D., DANZIG L. A. Extensive spinal osteophytosis as a risk factor for heterotopic bone formation after total hip arthroplasty. *Clin. Orthop.*, 1981, 161, 191-197.
  16. BOITZY A., ZIMMERMAN H. Komplikationen bei Totalprothesen der Hüfte. *Arch. Orthop. Unfall Chir.*, 1969, 66, 192-200.
  17. BOSSE M. J., POKA A., REINERT C. M., EL-LWANGER F., SLAWSON R., McDEVITT E. R. Heterotopic ossification as a complication of acetabular fracture. *J. Bone Joint Surg.*, 1988, 70-A, 1231-1237.
  18. BROOKER A. W. F., BOWERMAN J. W., ROBINSON R. A., RILEY Jr. L. H. Ectopic ossification following total hip replacement. *J. Bone Joint Surg.*, 1973, 55-A, 1629-1632.
  19. BRUNNER R., MORSCHER E., HÜNIG R. Pararticular ossification in total hip replacement: an indication for irradiation therapy. *Arch. Orthop. Trauma Surg.*, 1987, 106, 102-107.
  20. BUNDRICK T. J., COOK D. E., RESNIK C. S. Heterotopic bone formation in patients with DISH following total hip replacement. *Radiology*, 1985, 155, 595-597.
  21. CARON J. C. *Para-articular ossifications in total hip replacement*. In: *Total Hip Prosthesis*, ed. Geschwend N., Debrunner H. U., Hans Huber Publishers, Bern, Stuttgart, Vienna, 1976, pp. 171-185.
  22. CELLA J. P., SALVATI E. A., SCULCO T. P. Indomethacin for the prevention of heterotopic ossification following total hip arthroplasty. *J. Arthroplasty*, 1988, 3, 229-234.
  23. CHARNLEY J. The long-term results of low-friction arthroplasty of the hip performed as a primary intervention. *J. Bone Joint Surg.*, 1972, 54-B, 61-76.
  24. CHARNLEY J. *Low Friction Arthroplasty of the Hip. Theory and Practice*. Springer-Verlag, Berlin, Heidelberg, New York, 1979, pp. 355-356.
  25. CONNOR J. M. *Soft tissue ossification*. Springer-Verlag, Berlin, Heidelberg, New York, Tokyo, 1983, pp. 27-31 and pp. 117-127.
  26. COVENTRY M. B., SCANLON P. W. The use of radiation to discourage ectopic bone. A nine-year study in surgery about the hip. *J. Bone Joint Surg.*, 1981, 63-A, 201-208.
  27. DAHL H. K. *Kliniske Observasjoner*. In: *Symposium on arthrose*, Ed. MSD, Blindern, Norway, 1975, pp. 37-46.
  28. DEKEL S., LENTHALL G., FRANCIS M. J. O. Release of prostaglandins from bone and muscle after tibial fracture. An experimental study in rabbits. *J. Bone Joint Surg.*, 1981, 63-B, 185-189.
  29. DELEE J., FERRARI A., CHARNLEY J. Ectopic bone formation following low friction arthroplasty of the hip. *Clin. Orthop.*, 1976, 121, 53-59.
  30. ELMSTEDT E., LINDHOLM T. S., NILSSON O. S., TÖRNKVIST H. Effect of Ibuprofen on heterotopic ossification after hip replacement. *Acta Orthop. Scand.*, 1985, 56, 25-27.
  31. ELVES M. W., BAYLEY I., ROYLANCE P. J. The effect of Indomethacin upon experimental fractures in the rat. *Acta Orthop. Scand.*, 1982, 53, 35-41.
  32. ERRICO T. J., FETTO J. F., WAUGH T. R. Heterotopic ossification. Incidence and relation to trochanteric osteotomy in 100 total hip arthroplasties. *Clin. Orthop.*, 1984, 190, 138-141.
  33. FAHMY N. R. M., WROBLEWSKI B. M. Recurrence of ectopic ossification after excision in Charnley low friction arthroplasty. *Acta Orthop. Scand.*, 1982, 53, 799-802.
  34. FAHRER H., KOCH P., BALLMER P., ENZLER P., GERBER N. Ectopic ossification following total hip arthroplasty: is diffuse idiopathic skeletal hyperostosis a risk factor? *Brit. J. Rheum.*, 1988, 27, 187-190.
  35. FINERMAN G. A. M., KRENGEL Jr W. F., LOWELL J. D., MURRAY W. R., VOLZ R. G., BOWERMAN J. W., GOLD R. H. *Role of a diphosphonate (EHDP) in the prevention of heterotopic ossification after total hip arthroplasty: a preliminary report*. In: *The Hip*, Ed. C. V. Mosby, St. Louis, 1977, pp. 222-234.
  36. FINERMAN G. A. M., STOVER S. L. Heterotopic ossification following hip replacement or spinal cord injury. Two clinical studies with EHDP. *Metab. Bone Dis. Rel. Res.*, 1981, 4 & 5, 337-342.
  37. FLEISCH H., RUSSEL R. G. G., FRANCIS M. D. Diphosphonates inhibit hydroxyapatite dissolution in vitro and bone resorption in tissue-culture and in vivo. *Science*, 1969, 165, 1262-1264.
  38. FRIEDENSTEIN A. Y. Induction of bone tissue by transitional epithelium. *Clin. Orthop.*, 1968, 59, 21-37.
  39. GARLAND D. E., ALDAY B., VENOS K. G. Heterotopic ossification and HLA antigens. *Arch. Phys. Med. Rehab.*, 1984, 65, 531-532.

40. GARLAND D. E., ORWIN J. F. Resection of heterotopic ossification in patients with spinal cord injuries. *Clin. Orthop.*, 1989, 242, 169-176.
41. HAMBLEN D. L., HARRIS W. H. Myositis ossificans as a complication of total hip arthroplasty. *J. Bone Joint Surg.*, 1971, 53-B, 764.
42. HAMBLEN D. L. *Ectopic ossification*. In : *Complications of total hip replacement*. Ed. Ling R. S. M., Churchill Livingstone, Edinburgh, London, 1986. pp. 100-109.
43. HANSLIK L., RADLOFF H. Der Krankheitswert paraartikulärer Verknöcherungen nach totalendoprosthetischem Hüftgelenkersatz. *Arch. Orthop. Unfall Chir.*, 1974, 80, 153-164.
44. HIERTON C., BLOMGREN G., LINDGREN U. Factors associated with heterotopic bone formation in cemented total hip prostheses. *Acta Orthop. Scand.*, 1983, 54, 698-702.
45. JOHNSTON R. C. Clinical follow-up of total hip replacement. *Clin. Orthop.*, 1973, 95, 118-126.
46. JOWSEY J., HOLLEY K. E., LINMAN J. W. Effect of sodium etidronate in adult cats. *J. Lab. Clin. Med.*, 1970, 76, 126-133.
47. JOWSEY J., COVENTRY M. B., ROBINS P. R. *Heterotopic ossification : theoretical consideration, possible etiologic factors, and a clinical review of total hip arthroplasty patients exhibiting this phenomenon*. In : *The Hip*, Ed. C. V. Mosby, St. Louis, 1977, p. 210-221.
48. KELLER J. C., TRANCIK T. M., YOUNG F. A., ST. MARY E. Effects of Indomethacin on bone ingrowth. *J. Orthop. Res.*, 1989, 7, 28-34.
49. KING W. R., FRANCIS M. D., MICHAEL W. R. Effect of disodium ethane-1-hydroxy-1,1-diphosphonate on bone formation. *Clin. Orthop.*, 1971, 78, 251-270.
50. KJAERGAARD-ANDERSEN P., SCHMIDT S. A. Indomethacin for prevention of ectopic ossification after hip arthroplasty. *Acta Orthop. Scand.*, 1986, 57, 12-14.
51. KJAERGAARD-ANDERSEN P., PEDERSEN P., KRISTENSEN S. S., SCHMIDT S. A., PEDERSEN N. W. Serum alkaline phosphatase as an indicator of heterotopic ossification following total hip arthroplasty. *Clin. Orthop.*, 1988, 234, 102-109.
52. KJAERGAARD-ANDERSEN P., SCHMIDT S. A., PEDERSEN N. W., KRISTENSEN S. S., PEDERSEN P. Erythrocyte sedimentation rate and heterotopic bone formation after cemented total hip arthroplasty. *Clin. Orthop.*, 1989, 248, 189-194.
53. KRIEGBAUM N. J., LUNDBERG D., PEDERSEN W., JAKOBSEN B. K. HLA and myositis ossificans circumscripta. *Scand. J. Rheum.*, 1986, 15, 352.
54. KROMANN-ANDERSEN C., SCHERFF SÖRENSEN T., HOUGAARD K., ZDRAVKOVIC D., FRI-GAARD E. Ectopic bone formation following Charnley hip arthroplasty. *Acta Orthop. Scand.*, 1980, 51, 633-638.
55. LANGENSKIÖLD A., KIVILUOTO O. Prevention of epidural scar formation after operation on the lumbar spine by means of free fat transplants. *Clin. Orthop.*, 1976, 115, 992-95.
56. LAZANSKY M. G. Complications revisited. The debit side of total hip replacement. *Clin. Orthop.*, 1973, 95, 96-103.
57. LIDGREN L., NORDSTRÖM B. Treatment of peri-articular calcification after total hip arthroplasty. *Arch. Orthop. Trauma Surg.*, 1979, 94, 67-70.
58. LO T. C. M., HEALY W. L., COVALL D. J., DOTTER W. E., PFEIFFER B. A., TORGERSON W. R., WALISEWSKI S. A. Heterotopic bone formation after hip surgery : prevention with single-dose postoperative hip irradiation. *Radiology*, 1988, 168, 851-854.
59. MATOS M., AMSTUTZ H. C., FINERMAN G. Myositis ossificans following total hip replacement. *J. Bone Joint Surg.*, 1975, 57-A, 137.
60. MATTINGLY P. C., MOWAT A. G. HLA antigens in patients with ectopic ossification after total hip replacement. *J. Rheum.*, 1980, 7, 582.
61. McLENNAN L., KEYS H. M., EVARTS C. M., RUBIN P. Usefulness of postoperative hip irradiation in the prevention of heterotopic bone formation in a high risk group of patients. *Int. J. Rad. Onc. Biol. Phys.*, 1984, 10, 49-53.
62. McMAHON J. S., WADDEL J. P., MORTON J. *Effect of short-course Indomethacin on heterotopic bone formation after uncemented total hip arthroplasty*. Presented at the 57th meeting of the American Academy of Orthopedic Surgeons, New Orleans, 1990.
63. MICHELSSON J. E., GRANROTH G., ANDERSON L. C. Myositis ossificans following forcible manipulation of the leg. *J. Bone Joint Surg.*, 1980, 62-A, 811-815.
64. MITAL M. A., GARBER J. E., STINSON J. T. Ectopic bone formation in children and adolescents with head injuries : its management. *J. Ped. Orthop.*, 1987, 7, 83-90.
65. MOLLAN R. A. B. Serum alkaline phosphatase in heterotopic para-articular ossification after total hip replacement. *J. Bone Joint Surg.*, 1979, 61-B, 432-434.
66. MORREY B. F., ADAMS R. A., CABANELA M. E. Comparison of heterotopic bone after anterolateral, transtrochanteric, and posterior approaches for total hip arthroplasty. *Clin. Orthop.*, 1984, 188, 1600-167.
67. NILSSON O. S., BAUER H. C. F., BROJÖ O., TÖRNKVIST H. Influence of Indomethacin on induced heterotopic bone formation in rats. Importance of length of treatment and of age. *Clin. Orthop.*, 1986, 207, 239-245.
68. NILSSON O. S., BAUER H. C. F., BROJÖ O., TÖRNKVIST H. A comparison of Indomethacin and Diclofenac in the inhibition of experimental heterotopic bone formation. *Int. Orthop.*, 1987, 11, 283-287.

69. NOLLEN A. J. G., SLOOFF T. J. J. H. Para-articular ossifications after total hip replacement. *Acta Orthop. Scand.*, 1973, 44, 230-241.
70. ORNSHOLT J., ESPEREN J. O. Para-articular ossifications after primary prosthetic replacement ad modum Austin T. Moore. *Acta Orthop. Scand.*, 1975, 46, 643-650.
71. PARKER H. G., WIESMAN H. G., EWALD F. C., THOMAS W. H., SLEDGE C. B. Comparison of preoperative, intraoperative and early postoperative total hip replacements with and without trochanteric osteotomy. *Clin. Orthop.*, 1976, 121, 44-49.
72. PARKINSON J. R., EVARTS C. M., HUBBARD L. F. Radiation therapy in the prevention of heterotopic ossification after total hip arthroplasty. In: *The Hip*, Ed. C. V. Mosby, St. Louis, 1982, pp. 211-227.
73. PATTERSON F. P., BROWN C. S. The McKee-Farrar total hip replacement. *J. Bone Joint Surg.*, 1972, 54-A, 257-275.
74. PLASMANS C. M. T. *The influence of a diphosphonate on induced ectopic bone*. Thesis. University of Nijmegen, The Netherlands, 1977.
75. PLASMANS C. M. T., KUIJPERS W., SLOOFF T. J. J. H. The effect of ethane-1-hydroxy-1,1-diphosphonic acid (EHDP) on matrix induced ectopic bone formation. *Clin. Orthop.*, 1978, 132, 233-243.
76. PRESTON E. T. Total hip arthroplasty: a review of four years experience. *Clin. Orthop.*, 1978, 137, 48-50.
77. PUZAS J. E., BRAND J. S., EVARTS M. C. *The stimulus for bone formation*. In: *The Hip*, C. V. Mosby, St. Louis, 1986, pp. 25-38.
78. PUZAS J. E., MILLER M. D., ROSIER R. N. Pathologic bone formation. *Clin. Orthop.*, 1989, 245, 269-281.
79. RIEGLER H. F., HARRIS C. M. Heterotopic bone formation after total hip arthroplasty. *Clin. Orthop.*, 1976, 117, 209-216.
80. RISK A. E. B., MICHELSSON J. E. Treatment of para-articular ossification after total hip replacement by excision and use of free fat transplants. *Acta Orthop. Scand.*, 1979, 50, 751-754.
81. RITTER M. A., VAUGHAN R. B. Ectopic ossification after total hip arthroplasty. Predisposing factors, frequency and effect on results. *J. Bone Joint Surg.*, 1977, 59-A, 345-351.
82. RITTER M. A., GIOE T. J. The effect of Indomethacin on para-articular ectopic ossification following total hip arthroplasty. *Clin. Orthop.*, 1982, 167, 113-117.
83. RITTER M. A., SIEBER J. M. Prophylactic Indomethacin for the prevention of heterotopic bone formation following total hip arthroplasty. *Clin. Orthop.*, 1985, 196, 217-225.
84. RÖ J., SUDMANN E., MARTON P. F. effects of Indomethacin on fracture healing in rats. *Acta Orthop. Scand.*, 1976, 47, 588-599.
85. ROSENDAHL S., KROGH CHRISTOFFERSEN J., NORGAARD M. Para-articular ossification following hip replacement. *Acta Orthop. Scand.*, 1977, 48, 400-404.
86. SALVATI E. A., CHUEM IM V., AGLIETTI P., WILSON Jr P. D. Radiology of total hip replacements. *Clin. Orthop.*, 1976, 121, 74-82.
87. SCHENK R., MERZ W. A., MÜHLBAUER R., RUSSELL R. G. G., FLEISCH H. Effect of ethane-1-hydroxy-1,1-diphosphonate (EHDP) and dichloromethylene diphosphonate (Cl<sub>2</sub>MDP) on the calcification and resorption of cartilage and bone in the tibial epiphysis and metaphysis of rats. *Calcif. Tissue Res.*, 1973, 11, 196-214.
88. SCHMIDT S. A., KJAERGAARD-ANDERSEN P. Indomethacin inhibits the recurrence of excised ectopic ossification after hip arthroplasty. A 3-4 year follow-up of 8 cases. *Acta Orthop. Scand.*, 1988, 59, 593.
89. SCHMIDT S. A., KJAERGAARD-ANDERSEN P., PEDERSEN N. W., KRISTENSEN S. S., PEDERSEN P., NIELSEN J. B. The use of Indomethacin to prevent the formation of heterotopic bone after total hip replacement. *J. Bone Joint Surg.*, 1988, 70-A, 834-838.
90. SMITH R., RUSSEL R. G. G., BISHOP M. Diphosphonates and Paget's disease of bone. *Lancet*, 1971, I, 945-947.
91. SOBALLE K., CHRISTENSEN F., KRISTENSEN S. S. Ectopic bone formation after total hip arthroplasty. *Clin. Orthop.*, 1988, 228, 57-62.
92. SODEMANN B., PERSSON P. E., NILSSON O. S. Periarticular heterotopic ossification after total hip arthroplasty for primary coxarthrosis. *Clin. Orthop.*, 1988, 237, 150-157.
93. SODEMANN B., PERSSON P. E., NILSSON O. S. Prevention of heterotopic ossification by nonsteroid antiinflammatory drugs after total hip arthroplasty. *Clin. Orthop.*, 1988, 237, 158-163.
94. SODEMANN B., PERSSON P. E., NILSSON O. S. Nonsteroid anti-inflammatory drugs prevent the recurrence of heterotopic ossification after excision. *Arch. Trauma Surg.*, 1990, 109, 53-56.
95. SPIELMAN G., GENARELLI T. A., ROGERS C. R. Disodium etidronate: its role in preventing heterotopic ossification in severe head injury. *Arch. Phys. Med. Rehab.*, 1983, 64, 539-542.
96. STEENMEYER A. V., SLOOFF T. J. J. H., KUIJPERS W. The effect of Indomethacin on para-articular ossification following total hip replacement. *Acta Orthop. Belg.*, 1986, 52, 305-307.
97. STOVER S. L., NIEMANN K. M. W., MILLER III J. M. Disodium etidronate in the prevntion of postoperative recurrence of heterotopic ossification in spinal-cord injury patients. *J. Bone Joint Surg.*, 1976, 58-A, 683-688.
98. SUNDARAM N. A., MURPHY J. C. M. Heterotopic

- bone formation following total hip arthroplasty in ankylosing spondylitis. *Clin. Orthop.*, 1986, 207, 223-226.
99. SYLVESTER J. E., GREENBERG P., SELCH M. T., THOMAS B. J., AMSTUTZ H. The use of postoperative irradiation for the prevention of heterotopic bone formation after total hip replacement. *Int. J. Rad. Onc. Biol. Phys.*, 1988, 14, 471-476.
  100. TAYLOR A. R., KAMDAR B. A., ARDEN G. P. Ectopic ossification following total hip replacement. *J. Bone Joint Surg.*, 1976, 58-B, 134.
  101. TESTA N. N., MAZUR K. U. Heterotopic ossification after direct lateral approach and transtrochanteric approach to the hip. *Orthop. Rev.*, 1988, XVII, 965-971.
  102. THOMAS B. J., AMSTUTZ H. C. Results of the administration of diphosphonate for the prevention of heterotopic ossification after total hip arthroplasty. *J. Bone Joint Surg.*, 1985, 67-A, 400-403.
  103. THOMPSON R. C., CULVER J. E. The role of trochanteric osteotomies in total hip replacement. *Clin. Orthop.*, 1975, 106, 102-106.
  104. TIBONE J., SAKIMURA I., NICKEL V. L., HSU J. D. Heterotopic ossification around the hip in spinal cord-injured patients. *J. Bone Joint Surg.*, 1978, 60-A, 769-775.
  105. TÖRNKVIST H., NILSSON O. S., BAUER F. C. H., LINDHOLM T. S. Experimentally induced heterotopic ossification in rats influenced by anti-inflammatory drugs. *Scand. J. Rheum.*, 1983, 12, 177-180.
  106. TÖRNKVIST H., BAUER F. C. H., NILSSON O. S. Influence of Indomethacin on experimental bone metabolism in rats. *Clin. Orthop.*, 1985, 193, 264-270.
  107. URIST M. R. Bone formation by auto-induction. *Science*, 1965, 150, 893-899.
  108. URIST M. R., DeLANGE R. J., FINERMAN G. A. M. Bone cell differentiation and growth factors. *Science*, 1983, 220, 680-686.
  109. VANE J. R. Inhibition of prostaglandin synthesis as a mechanism of action for aspirin-like drugs. *Nature*, 1971, 231, 232-235.
  110. VAN DER WERF G. J. I. M., VAN HASSELT N. G. M., TONINO A. J. Radiotherapy in the prevention of recurrence of paraarticular ossification in total hip prostheses. *Arch. OOrthop. Trauma Surg.*, 1985, 104, 85-88.
  111. WAHLSTRÖM O., DJERF K., HAMMERBY S., RISTO O. *Prophylactic treatment with Diclofenac (Voltaren) of heterotopic bone formation in hip arthroplasty. A double-blind, placebo-controlled study.* Presented at the annual meeting of the Swedish Medical Association, Stockholm 2-4 December, 1987.

H. P. HU

Institute for Orthopaedics

St. Radboud Hospital

University of Nijmegen,

P.O. Box 9101

6500 HB Nijmegen (The Netherlands)