

# AVASCULAR NECROSIS OF THE HUMERAL HEAD AFTER DISLOCATION WITH FRACTURE OF THE GREATER TUBEROSITY

S. SUSO, L. PEIDRO, R. RAMON

**A case of posttraumatic avascular necrosis of the humeral head in a young patient was detected 3 years after an anterior dislocation with a nondisplaced greater tuberosity fracture. The evolution to degenerative joint disease is described.**

**Keywords :** avascular necrosis ; fracture-dislocation ; humeral head.

**Mots-clés :** nécrose avasculaire ; fracture luxation ; tête humérale.


## INTRODUCTION

Posttraumatic avascular osteonecrosis of the humeral head is most frequently associated with displaced complex fractures and fracture-dislocations (6, 8). In elderly patients osteonecrosis can also occur in undisplaced fractures or even without fracture (2). However, to our knowledge, no case such as ours has been previously published.

## CASE REPORT

A 28-year-old male, without previous history of disease, suffered an anterior dislocation with fracture of the greater tuberosity of the right humerus after a car crash. Closed reduction was performed about 30 min. after injury, and the patient was immobilized for 3 weeks with a Velpeau bandage (fig. 1). Three months later the shoulder was painless with a normal range of motion. Three years later, after minor trauma, he complained of pain in the shoulder, and he had a painful arc


on abduction. An x ray showed a thin radiolucent halo on the superomedial edge of the humeral head compatible with osteonecrosis (fig. 2a). Bone scintigraphy indicated avascular necrosis. He was treated with nonsteroidal anti-inflammatory drugs and extremity rest. Afterwards the patient underwent physical therapy and an exercise program with good response. An x ray taken one year later showed a necrotic cap with collapse of the fragment (fig. 2b).



*Fig. 1.* — X ray performed after closed reduction shows a fracture of the greater tubercle.

<sup>1</sup> Hospital Clínic, Department of Orthopaedics, Faculty of Medicine, University of Barcelona, Barcelona, Spain.

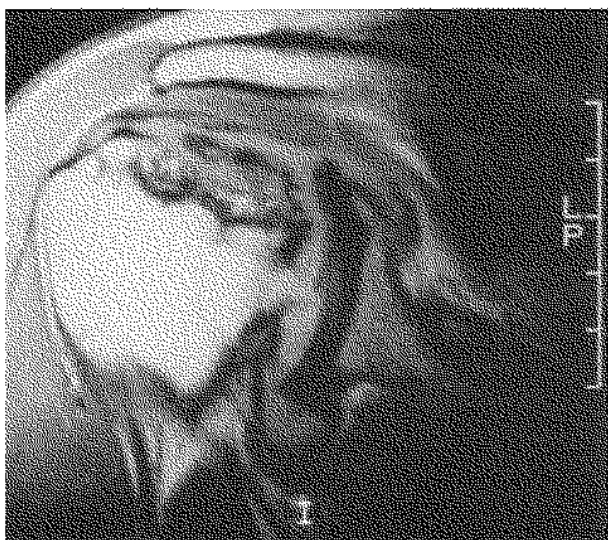
Correspondence and reprints : S. Suso, c/Ganduxer 133 2º B, 08022 Barcelona, Spain.

*Fig. 2a**Fig. 2b*

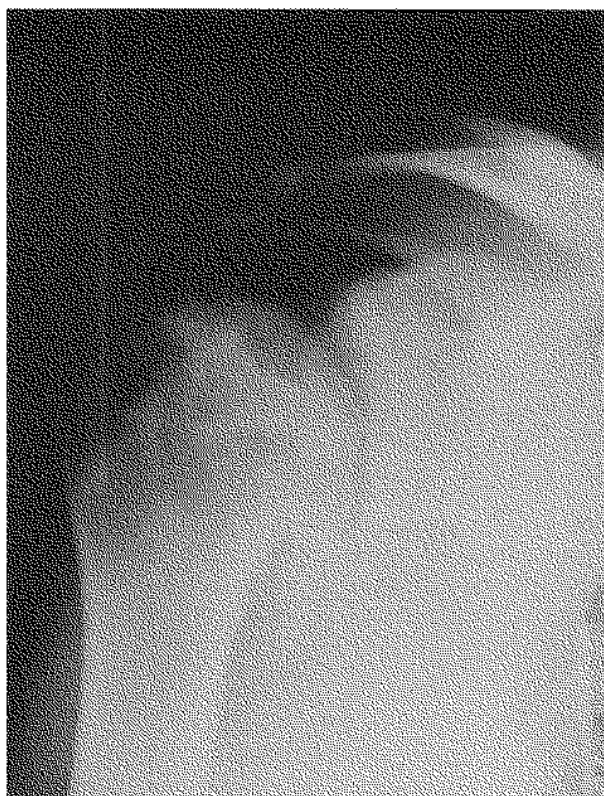
*Fig. 2.* — a) Anteroposterior roentgenogram taken 3 years after injury shows a thin radiotransparent halo on the superomedial edge of the humeral head compatible with osteonecrosis.

b) One year later a necrotic cap was more evident with collapse of the fragment and incipient osteophytosis.

MRI revealed epiphyseal necrosis with a total collapse and fragmentation of the necrotic area (fig. 3). At follow-up 6 years after the injury there was a deformity of the epiphysis with marginal osteophytes and osteoarthritic involvement (fig. 4). He felt no pain in the shoulder, and admitted only to occasional soreness and crepitation. He had active elevation of  $120^\circ$ , and the rotation arcs were diminished, with external rotation of  $10^\circ$ . Nevertheless, the degenerative joint disease is currently quite well tolerated by the patient.



*Fig. 3.* — MRI carried out one year after diagnosis revealed epiphyseal necrosis with total collapse and fragmentation of the necrotic area.



*Fig. 4.* — Six years after injury there is deformity of the humeral head with large marginal osteophytes and osteoarthrosis.

## DISCUSSION

Gerber (5) has shown that the anterolateral branch of the anterior circumflex artery provides the main blood supply to the head of the humerus. It enters the humeral head at the lateral and superior aspects of the intertubercular groove. Within the humeral head, as the arcuate artery, it supplies almost the entire epiphysis. The posterior humeral circumflex artery vascularizes the posterior portion of the greater tuberosity and a small posteroinferior part of the articular segment.

This could explain how in a nondisplaced fracture of the greater tuberosity such as our case, the humeral head could be deprived of its principal blood supply, thereby causing osteonecrosis.

The initial treatment of the osteonecrosis should be symptomatic, with pain relief and physiotherapy to maintain an adequate range of movement. Some authors suggest that physical therapy will also give a favorable outcome even over the long term (9). Operations suggested in the early stages of osteonecrosis include drilling of the humeral head and muscle-pedicled bone graft (7), but no long-term studies have been performed.

In established symptomatic osteonecrosis with humeral head collapse and osteoarthritis, humeral head replacement is an accepted treatment (1, 3). The age of our patient and his lack of serious symptoms indicate that, for the moment, he should continue conservative treatment.

### REFERENCES

1. Bigliani L. Fractures of the proximal humerus. In : The shoulder (C. A. Rockwood-Matsen), W. B. Saunders Co, Philadelphia, 1990, 9, 278-330.
2. Calderazzi A., Bagnolesi P., Fratini L., Scalera R., Amato V. Aseptic necrosis of the humeral head. Rays, 1989, 13, 13-17.
3. Fourier P., Martini M. Post-traumatic avascular necrosis of the humeral head. Intern. Orthop. (SICOT), 1977, 1, 187-190.
4. Frostick S. P., Wallace W. A. Osteonecrosis of the humeral head. Bailliere Clin. Rheum., 1989, 3, 651-657.
5. Gerber C., Schneeberger A. G., Vinh T. S. The arterial vascularization of the humeral head. J. Bone Joint Surg., 1990, 72-A, 1486-1494.
6. Neer C. S. Displaced proximal humeral fractures. Part II. Treatment of three-part and four-part displacement. J. Bone Joint Surg., 1970, 52-A, 1090-1103.
7. Rindell K. Muscle pedicled bone graft in revascularization of aseptic necrosis of the humeral head. Ann. Chir. Hynaec., 1987, 76, 283-285.
8. Svend-Hansen H. Displaced proximal humeral fractures : A review of 49 patients. Acta Orthop. Scand., 1974, 45, 359-364.
9. Terret A. G. J., Molyneux T. P. Hass'disease. J. Manipulative Physiol. Ther., 1988, 11, 43-47.

### SAMENVATTING

*S. SUSO, L. PEIDRO en R. RAMON. Avasculaire necrose van de humeruskop na voorste schouderluxatie, met niet verplaatste fractuur van het tuberculum maius.*

Beschrijving van één geval van posttraumatische avasculaire necrose van de humeruskop, bij een jonge man, 3 jaar na een voorste luxatie, met niet verplaatste fractuur van het tuberculum maius.

Beschrijving van de evolutie naar arthrose.

### RÉSUMÉ

*S. SUSO, L. PEIDRO et R. RAMON. Nécrose avasculaire de la tête de l'humérus après luxation de l'épaule, associée à une fracture sans déplacement du trochiter.*

Présentation d'un cas de nécrose avasculaire posttraumatique de la tête humérale chez un homme jeune, 3 ans après luxation antérieure, avec fracture sans déplacement du trochiter.

Description de l'évolution vers l'arthrose.