

# LUMBAR DISC HERNIATION IN EIGHT SIBLINGS WITH A POSITIVE FAMILY HISTORY FOR DISC DISEASE

R. SCAPINELLI

Lumbar disc herniation has been observed by the author in many members of a large family, with the maximum incidence in males of the third generation, where 8 siblings were similarly affected and 6 underwent operation, mostly in their third decade of life. A number of patients in the same family suffered from chronic low back pain. In the majority of cases environmental factors apparently do not seem to play a significant role in the development of the disease. The author believes that a genetic predisposition to early disc degeneration can be invoked to explain so large an aggregation of patients suffering from lumbar disc disorders.

**Keywords :** lumbar disc herniation ; low back pain ; heredity ; familial predisposition ; genetic factors ; intervertebral disc.

**Mots-clés :** hernie discale lombaire ; lombalgie ; hérédité ; prédisposition familiale ; facteurs génétiques ; disque intervertébral.

---

## INTRODUCTION

The aetiology of intervertebral disc degeneration and disc herniation is still debated and speculative. Among the great variety of causative factors (1, 8, 10, 12), heredity has been implicated (3, 5, 14, 15), particularly when disc prolapse affects children and adolescents (3, 9, 11, 16) or teenage monozygotic twins (4, 6).

In the present paper the author describes an Italian family showing in two generations such a striking incidence of low back pain with lumbar disc herniation that genetic predisposition seems very likely.

## MATERIAL AND METHODS

The present study deals with a large family, originating in a rural village near Padua, composed of father, mother and 14 children (6 females and 8 males) (fig. 1). The father was in his turn the second-born of 14 children (4 females and 10 males) and the mother the third-born of 15 children (5 females and 10 males). The proband was a 44-year-old patient (fig. 2, III, 6), who had been surgically treated by the author in May 1991 for a lumbosacral disc herniation. Because of the existence in his family history of a considerable number of cases of lumbar disc herniation or low back pain, the author contacted the members of his family to discover their specific spinal disorder, occupation, type of complaints (low back pain, sciatica or cruralgia), onset of symptoms, history of significant trauma, and possible associated pathogenetic factors. The hospital charts and radiological documentation were obtained from those patients who had been operated on for disc prolapse or in whom such disease had been treated conservatively. The medical records and x rays of the lumbar spine were obtained from those complaining of chronic low back pain. As much information as possible about the family history regarding any spinal disorders affecting brothers and sisters of both father and mother and their respective families was collected directly or by telephone.

## RESULTS (figs. 1 and 2)

In the proband's family six of the 14 siblings (one woman, III, 11, and 5 men, III, 3, 5, 6, 9,

---

Institute of Orthopedic Surgery and Traumatology, University of Padua, I-35128 Padua, Italy.

Correspondence and reprints : R. Scapinelli.




Fig. 1. — The members of the third generation with their parents. Among them those affected by lumbar disc herniation are numbered according to birth order. F = father, M = mother.

10) underwent surgery for lumbar disc herniation, some in orthopaedic and some in a neurosurgical hospital. In two other siblings (one man, III, 1) and one woman, III, 4) the diagnosis of lumbar disc herniation was made clinically on the basis of physical and electromyographic findings, but both were treated nonoperatively. Two others (a man, III, 8 and a woman, III, 13) have complained of chronic low back pain from the end of their third decade. The father (II, 2), a bricklayer, who died at 78 years from a tumor of the head of the pancreas, experienced from the age of 29 or 30 repeated bouts of low back pain. The mother (II, 18), still in good health, refers to occasional low back problems, not necessitating the use of a corset.

The age at operation of the 6 surgically treated siblings (III, 3, 5, 6, 9, 10, 11) was respectively

39, 35, 44, 24, 30 and 26 years. The body weight of those siblings affected by disc herniation was within normal limits in six, and slightly excessive in two (III, 3, 9). All were psychologically normal. Only one male suffered from an abdominal hernia. Mild signs of joint laxity were present in the female patient (III, 11) and in two of the males of the same sibship (III, 3, 6) and in one of the latter's daughters (IV, 2). The common laboratory investigations were all negative. Most patients of the third generation were blood group O, Rh positive (III, 2, 3, 6, 10, 11).

As regards occupation, none of the eight siblings affected by LDH have ever performed manual work: among the six males two were clerks, two tradesmen, two carpenters. In four of them (III, 3, 9, 11, 13) backache started between 22 and 27 years of age. The interval between the first

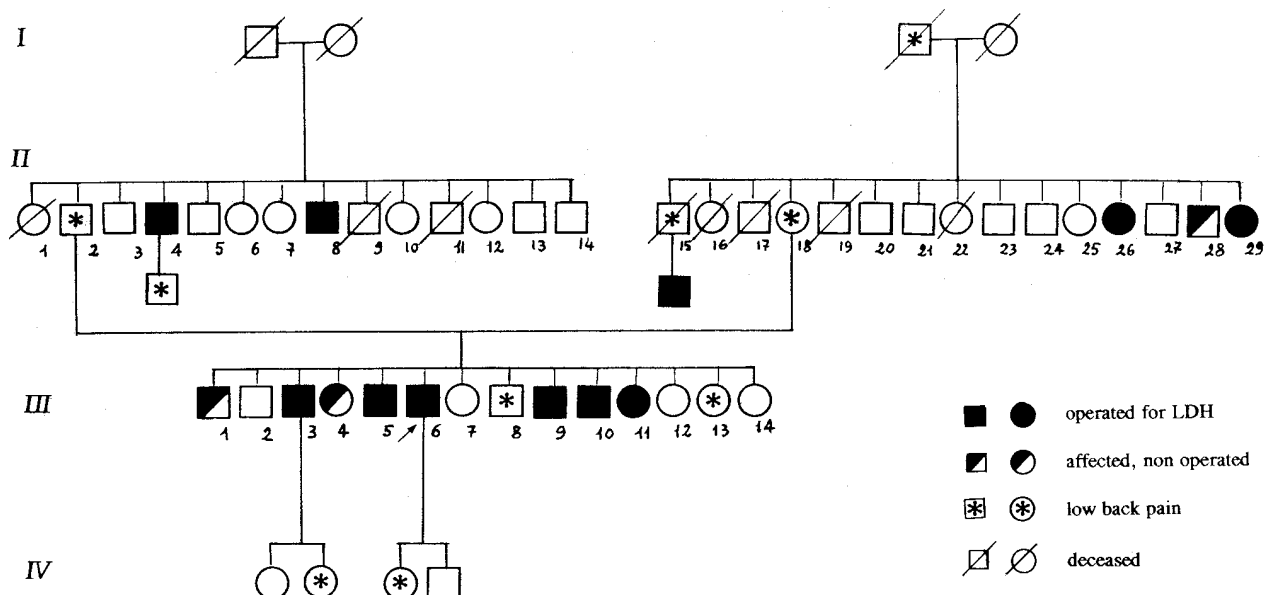


Fig. 2. — Pedigree of the family. The proband is indicated by an arrow.

backache and the onset of radicular pain ranged from five months (III, 6, 10) to 12 years (III, 3), but was usually one to two years (III, 2, 11). A mild physical effort was implicated in the onset of symptoms by four patients in the surgical series (III, 3, 5, 9, 10). The oldest among the siblings operated (III, 6) blamed intensive travel by car (about 50,000 km/year). None reported injury of the spine.

As regards associated spinal diseases, the single female patient (III, 11) operated on for disc herniation had been treated for idiopathic scoliosis during adolescence.

The level of disc herniation in the six siblings operated on was as follows: at L4-L5 left in one patient (III, 9), at L5-S1 in four patients (III, 5, 6, 10, 11) (half left and half right), and two levels (L3-L4 and L4-L5 left) in different operating sessions in one patient (III, 3). At operation the volume of the extruded disc was found to be very large in three patients (III, 3, 5, 6), while in one suffering from the cauda equina syndrome there was a massive extrusion of the L5-S1 disc.

The level and position of the disc prolapse were assessed preoperatively in four siblings by myelography and in two by CT scan.

In the two nonoperated patients the level of the hernia was respectively L5-S1 left in one (woman

treated at the age of 23 years by a plaster jacket) and L4-L5 right in the other (man aged 48).

At the time of operation disc space narrowing and loss of the normal lumbar lordosis were the most common radiological findings. Mild osteoarthritis was present in the patients over 35 years (III, 3, 5, 6). In three patients (III, 3, 10, 11) there was a very slight lumbar scoliosis. A bilateral short lumbar rib was seen in the female patient (III, 4) with a non-operated disc prolapse, while a man of the surgical series (II, 4) showed hemisacralization of L5, with a false joint between the hypertrophic transverse process of L5 and the ala of the sacrum. The shape and the diameters of the lumbar spinal canal appeared to be normal in those patients assessed by CT scans or by myelography.

The results of the operation were considered excellent or good in two (III, 6, 11), fair in two (III, 3, 9) with recurrent low back or leg pain, and poor in the two others (III, 5, 10).

### FAMILY HISTORY

Among the thirteen siblings of the father, two men had undergone surgery for lumbar disc herniation: one of them (II, 8) at 24 years and the other (II, 4, a farmer) at 50 years. In this latter

the first symptoms began at the age of 28 years, and a large extruded herniation was removed at level L4-L5 left. Radiologically there was mild osteoarthritis, with narrowing of the lowest two disc spaces and right hemisacralization of the fifth lumbar vertebra and a slight lumbar scoliosis, with osteophytes on the concave side.

Among the fourteen siblings of the mother, two females were operated for lumbar disc herniation at the age of 36 and 38 years, respectively (II, 26, 29). In the first, a domestic worker who had suffered from low back pain for a year, a large extrusion was found between L5 and S1 right, with adhesions to the spinal root. In the second, a housewife with several years' history of low back pain, again a large herniation was excised from the same level and the same side. Radiologically there was narrowing of the L5-S1 intervertebral space with moderately severe osteophytosis at L4 and L5 and a short twelfth pair of ribs.

A brother of theirs (II, 28), born in 1934, is being treated nonoperatively for occasional radicular pain in the territory of the left fifth lumbar root, and computed tomography has shown disc prolapses at L4-L5 and L3-L4. Another brother, now deceased (II, 15), suffered from chronic low back pain, and a son of his, a bricklayer, underwent discectomy at the age of 35 years for a left disc herniation between the fourth lumbar vertebra and the fifth sacralized vertebra. On x ray there was also slight left lumbar scoliosis. In the same subject multiple posterior disc protrusions (at levels L2-L3, L3-L4 and particularly L4-L5) were shown by preoperative myelography. The operation did not relieve his left foot extensor muscle weakness completely.

Among the young members of the fourth generation, the 20- and 19-year-old daughters of two of the male patients who underwent surgery for herniated lumbar disc (III, 3, 6) have, for about one year, had intermittent low back pain, with some buttock irradiation in the older, who on x ray shows sacralization of the fifth lumbar vertebra and a mild left lumbar scoliosis.

## DISCUSSION

No comparable family of back pain sufferers has been reported in the literature. This relates

to the fact that such large families have become very uncommon in Europe and elsewhere since the Second World War.

Schmorl (1931) (7) first suggested there may be an individual predisposition to disc degeneration. He showed at autopsy the presence of fissures and ruptures in the lumbar discs of patients in their twenties and noted marked degenerative changes in individuals who had never performed manual labor.

Hereditary factors have been suspected and considered important in intervertebral disc disease (and for many other vertebral disorders) by a number of authors (3, 5, 14, 15). Among them Taylor (10) supposed the coexistence of some general disorder of connective tissue. Wilson's studies (13) on 92 patients from 36 families in three generations with symptomatic lumbar disc disease brought the author to the conclusion that a dominant gene could be responsible for premature radiographic narrowing of the discs seen in various members of families and related to more rapid aging than normal. Heredity has also been invoked in the development of disc herniation in dogs (2, 14).

In the present series of members of the same family eight of the 14 siblings of the third generation suffered from lumbar disc herniation (six out of eight were operated on), while six other cases of the same disease were present in their second- and third-degree relatives. Low back pain was a frequent complaint in members of both the second and third generations, and the maternal grandfather (I, 3), a farmer, was said to have been affected by low back pain and sciatica from his early adult life. Among the members of the fourth generation low back pain is present in two girls aged 20 and 19 years, respectively.

Occupational and mechanical factors did not significantly influence disease occurrence. There may be some correlation with joint laxity, which was present to a mild or moderate degree in some affected members. A failure of differentiation of the lumbosacral vertebrae might have had some relevance in some of the patients.

In the majority of the affected members of the family the disc disease presented with characteristics in common, indicating a particular suscep-

tibility or inborn weakness of the lumbar discs to normal stresses. Unusual factors were the early onset of symptoms in the absence of trauma and the early age of the patients at operation, most of whom were in their third decade, while the disease commonly affects individuals around 40 years (7). Also unusual was the large volume of the disc prolapse found at operation, giving origin to a partial cauda equina syndrome in two males (III, 5, 10), and the frequent presence on myelograms or CT scan of asymptomatic disc protrusions at different levels. The hernia was removed surgically at two levels in two of the eight siblings of the second generation, each time at different operative sessions.

The success of the operation was generally lower than expected, and low back pain was a frequent sequela, indicating involvement of discs at multiple levels.

In order to explain the high familial aggregation of cases of disc herniation observed by the author, two possible hypotheses might be proposed.

According to the first hypothesis the high proportion of affected members in the third generation could depend on the transmission to them by both branches of the family of a genetic predisposition to premature degeneration of the disc tissue or soft-tissue weakness. The degenerative disease itself has a multifactorial nature and is a prerequisite for disc prolapse, through many interacting factors, some genetic and some nongenetic (environmental).

Alternatively, it may be supposed that at least some of these cases of disc herniation result from a defective autosomal dominant major gene with low penetrance, which makes these individuals more at risk than the normal.

## REFERENCES

1. Bisla R. S., Marchisello P. J., Lockshin M. D., Hart D. M., Marcus R. E., Granda J. Auto-immunological basis of disc degeneration. *Clin. Orthop.*, 1976, 121, 205-211.
2. Butler W. F. Comparative anatomy and development of the mammalian disc. In: Ghosh P. Ed., *Biology of the intervertebral disc*. Vol. I, Boca Raton, Florida, CRC Press, 1988, 83-108.
3. Grobler L. J., Simmons E. H., Barrington T. W. Inter-

- vertebral disc herniation in the adolescent. *Spine*, 1979, 4, 267-268.
4. Gunzburg R., Fraser R. D., Fraser G. A. Lumbar intervertebral disc prolapse in teenage twins. A case report and review of the literature. *J. Bone Joint Surg.*, 1990, 72-B, 914-916.
5. Lawrence J. S. *Rheumatism in populations*. London, Heinemann, 1977. Quoted by Gunzburg (Ref. 4).
6. Matsui H., Tsuji H., Terahata N. Juvenile lumbar herniated nucleus pulposus in monozygotic twins. *Spine*, 1990, 15, 1228-1230.
7. Schmorl G. Beiträge zur pathologischen Anatomie der Wirbelbandscheiben und ihre Beziehungen zu den Wirbelkörpern. *Arch. Orthop. Unfallchir.*, 1931, 29, 389-416.
8. Spengler D. M. *Low back pain. Assessment and management*. Grund and Stratton, New York, 1982, 88.
9. Taylor T. K. F. Lumbar intervertebral disc prolapse in children and adolescents. *J. Bone Joint Surg.*, 1982, 64-B, 135-136.
10. Taylor T. K. F., Akeson W. H. Intervertebral disc prolapse: a review of morphologic and biochemical knowledge concerning the nature of prolapse. *Clin. Orthop.*, 1971, 76, 54-79.
11. Varlotta G. P., Brown M. D., Kelsey J. L., Golden A. L. Familial predisposition for herniation of a lumbar disc in patients who are less than twenty-one years old. *J. Bone Joint Surg.*, 1991, 73-A, 124-128.
12. White A. A., Panjabi M. M. *Clinical biomechanics of the spine*. J. B. Lippincott Co., Philadelphia, Toronto, 1978, p. 277.
13. Wilson J. C. Hereditary premature aging of lumbar intervertebral joints. *J. Bone Joint Surg.*, 1969, 51-A, 1033.
14. Wiltse L. L. The effect of the common anomalies of the lumbar spine upon disc degeneration and low back pain. *Orthop. Clin. North Am.*, 1971, 2, 569-582.
15. Wiltse L. L. *Lumbosacral strain and instability*. Symposium on the Spine. Am. Acad. Orthop. Surg., The C. V. Mosby Company, Saint Louis, 1969, pp. 54-83.
16. Zamani M. H., MacEwen G. D. Herniation of the lumbar disc in children and adolescents. *J. Ped. Orthop.*, 1982, 2, 528-533.

## SAMENVATTING

*R. SCAPINELLI. Lumbale hernia nucleii pulposi bij 8 broers en zusters met positieve erfelijkheid voor discuspathologie.*

De auteur heeft een discushernia kunnen vaststellen bij meerdere leden van een kroostrijke familie, met de grootste incidentie bij mannen van de 3de generatie, waar 8 broers en zusters op gelijke wijze aan HNP leden en waarvan er 6 geopereerd werden, meestal tijdens het 3de decennium van hun leven. Een groot aantal mensen

van dezelfde familie leed aan chronische lendenpijn. In de meerderheid van de gevallen mochten geen uitwendige factoren een relevante rol spelen bij de ontwikkeling van de aandoening. De auteur gelooft dat een genetische aanleg tot vroegtijdige discusdegeneratie mag weerhouden worden als oorzaak van een zo belangrijke verzameling patiënten met discuspathologie.

#### RÉSUMÉ

*R. SCAPINELLI. Hernie discale lombaire chez 8 enfants d'une même famille avec hérédité d'affection discale.*

L'auteur a pu observer une hernie discale chez de nombreux membres d'une grande famille avec prédo-

minance chez les sujets mâles de la 3<sup>e</sup> génération, où 8 frères et sœurs présentaient la même lésion et dont 6 furent traités chirurgicalement pour la plupart pendant la 3<sup>e</sup> décennie de la vie. Un nombre important de malades de la même famille présentait des lombalgies. Dans la majorité des cas et les facteurs externes ne jouaient apparemment pas un rôle significatif dans la genèse de l'affection. L'auteur estime qu'une prédisposition génétique à une dégénérescence discale précoce peut être invoquée pour expliquer cet étonnant nombre de malades, présentant une pathologie discale, dans une même famille.