

MYXOMA CAUSING PARALYSIS OF THE POSTERIOR INTEROSSEOUS NERVE

A. VALER, L. CARRERA, G. RAMIREZ

A case of posterior interosseous nerve paralysis at the level of the Frohse arcade, caused by of an intramuscular myxoma, is reported. Review of the literature shows this to be an exceptional presentation of this tumor as a cause of a compressive peripheral neuropathy. Twelve months after surgical treatment, total neurological recovery was observed.

Keywords : posterior interosseous nerve ; paralysis ; myxoma.

Mots-clés : nerf interosseux posterior ; paralysie ; myxome.

INTRODUCTION

The different causes of posterior interosseous neuropathies including compression by a variety of soft tissue masses, the most common of which are lipomas, have been discussed in detail in the literature, but no description has been found of intramuscular myxoma causing damage to the posterior interosseous nerve.

CASE REPORT

A 42-year-old secretary had suffered for 5 months from progressive inability to extend the fingers of her right hand.

There was no history of trauma. Examination showed marked weakness of the extensor digitorum communis, extensor indicis, extensor digiti minimi (power 1, Medical Research Council Grading), extensor pollicis longus and abductor pollicis longus (power 2). Sensation was normal. No lump was felt. The electromyogram revealed

normal sensory nerve action potentials in all areas tested. The muscle testing demonstrated signs of denervation on stimulation of the right extensor digitorum communis and the extensor indicis, there being no fibrillation or fasciculation potentials in the triceps and brachioradialis of this extremity (fig. 1). These findings were consistent with a right posterior interosseous neuropathy. Radiographic examination showed no abnormality.

At surgery, the deep radial nerve was found to be flattened and splayed out over a well-defined tumor mass causing constriction of the nerve at the upper border of the supinator (fig. 2). The fibrous arcade of Frohse was sectioned, the posterior interosseous nerve was dissected off the mass and the tumor was excised (fig. 3). On gross inspection, the tumor measured 2 × 3 cm and had a glistening mucoid appearance. The cut surface was described as slippery and translucent, and it was composed of abundant gelatinous material. Histological examination showed it to be an intramuscular myxoma (fig. 4).

The patient had no postoperative complications. She had progressive return of function so that 12 months postoperatively she had the ability to fully extend the thumb and fingers. Signs of reinnervation in the affected muscles were present in the electromyogram 6 months after surgery (fig. 1).

Department of Orthopaedic Surgery, Hospital Vall d'Hebron, E-08015 Barcelona, Spain.

Correspondence and reprints : A. Valer, Gran Via 521, 2º, 2ª, E-08015 Barcelona, Spain.

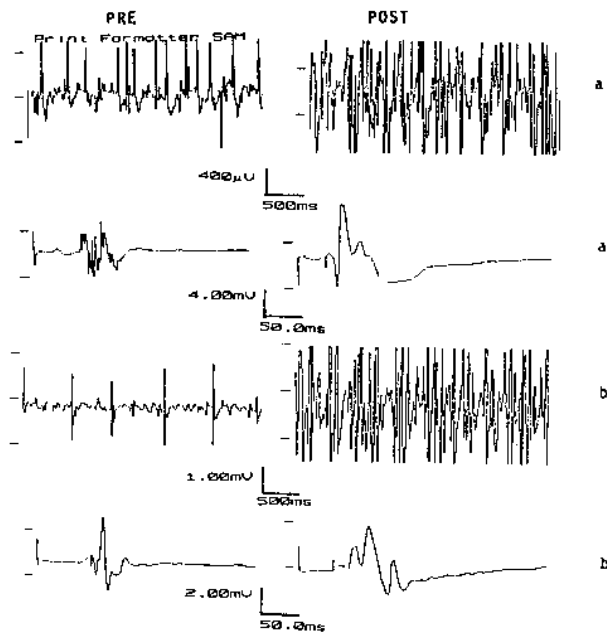


Fig. 1. — E.M.G. of the extensor digitorum communis (a) and extensor indicis (b).
Preoperative : scarce motor unit potentials of low amplitude ;
postoperative : reinnervation potentials of greater amplitude and shorter latency periods.

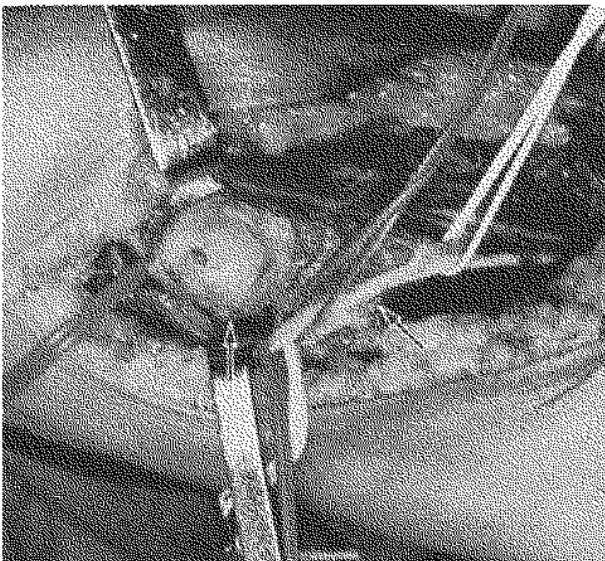


Fig. 2. — The posterior interosseous nerve has been released and the myxoma dissected (arrows).

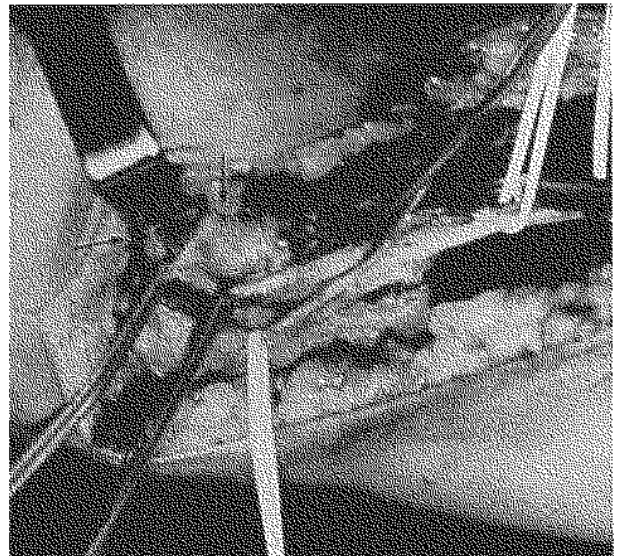


Fig. 3. — More distal release of the posterior interosseous nerve (arrow) after section of the arcade of Frohse.

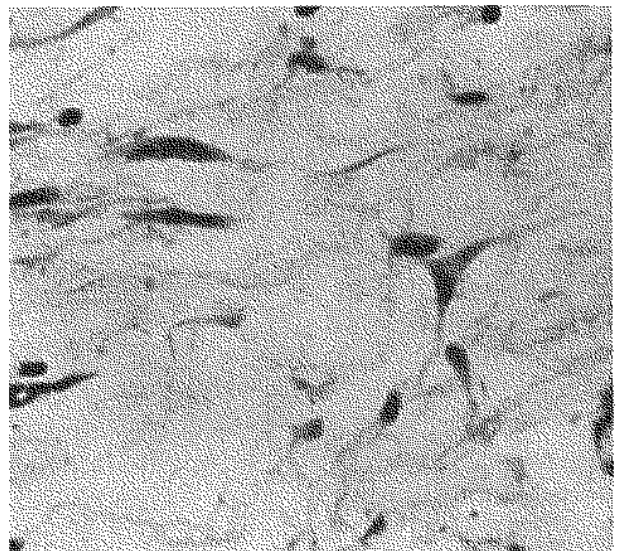


Fig. 4. — Intramuscular myxoma. Paucity of cells and of vascular structures within a mucoid matrix (Hematoxylin and eosin $\times 160$).

DISCUSSION

Spontaneous paralysis of the muscles supplied by the posterior interosseous nerve is uncommon. Paralysis has been ascribed to a variety of causes (4). Lipomas arising in the region of the elbow are the most common benign tumors causing posterior interosseous nerve entrapment (1). In our case an intramuscular myxoma in the substance of the supinator muscle was found, compressing the posterior interosseous nerve.

Intramuscular myxoma has been considered to be rare. Specific clinical manifestations of compressive neuropathy were not seen in any of the 34 examples of intramuscular myxoma collected by Enzinger (2), and the 18 cases studied by Kindblom *et al.* (3). However, compression of peripheral nerves, particularly of the lower extremity, has been described in cases of multiple intramuscular myxomas associated with fibrous dysplasia (5).

Electrophysiologic studies are very useful or even diagnostic in patients with posterior interosseous neuropathy unrelated to trauma since most soft tissue tumors are not palpable preoperatively. Early operations to remove the offending factors causing the neuropathy are usually followed by return of function as occurred in the case presented here.

REFERENCES

1. Barber K. W., Bianco A. J., Soule E. H., MacCarthy C. S. Benign extraneural soft-tissue tumors of the extremities causing compression of nerves. *J. Bone Joint Surg.*, 1962, 44-A, 98-104.
2. Enzinger F. M. Intramuscular myxoma. A review and follow-up study of 34 cases. *Am. j. Clin. Pathol.*, 1965, 43, 104-13.
3. Kindblom L. G., Stener B., Angervall L. Intramuscular myxoma. *Cancer*, 1974, 34, 1737-44.
4. Stewart J. D. Focal peripheral neuropathies. New York, Elsevier Science Publishing, 1987, pp. 199-205.
5. Wirth W. A., Leavitt D., Enzinger F. M. Multiple intramuscular myxomas. Another extraskelatal manifestation of fibrous dysplasia. *Cancer*, 1971, 27, 1167-73.

SAMENVATTING

A. VALER, L. CARRERA, G. RAMIREZ. Paralyse van de n. interosseus posterior door een intramusculair myxoma.

Een geval van paralyse van de n. interosseus posterior wordt gerapporteerd. Een intramusculair myxoma t.h.v. de arcade van Frohse werd verantwoordelijk geacht. Het blijkt dat deze uitzonderlijke lokalisatie van deze zeldzame tumor aan de basis ligt van de compressie neuropathie.

Twaalf maand na resectie is de neurologische recuperatie volledig.

RÉSUMÉ

A. VALER, L. CARRERA, G. RAMIREZ. Myxome intramusculaire, cause d'une paralysie du nerf interosseux postérieur.

Un cas de paralysie du nerf interosseux posterior au niveau de l'arcade de Frohse est présenté. Un myxome intramusculaire en était la cause. Suite à l'étude bibliographique, le caractère exceptionnel de cette tumeur a été reconnu. Elle était responsable d'une neuropathie compressive périphérique.

Douze mois après traitement chirurgical, la récupération neurologique fut totale.