

EFFECT OF DYNAMIZATION IN OPEN INTERLOCKING NAILING OF FEMORAL FRACTURES. A PROSPECTIVE RANDOMIZED COMPARATIVE STUDY OF 50 CASES WITH A 2-YEAR FOLLOW-UP

M. N. BASUMALLICK¹, A. BANDOPADHYAY²

This prospective randomized comparative study evaluated the role of dynamization of interlocking nails after open reduction and internal fixation of femoral shaft fractures. Fifty femoral shaft fractures were treated by open interlocking nailing and were statically locked. Twenty six of these 50 patients were randomly selected for dynamization and the other 24 were treated without dynamization. The patients were followed up for at least 2 years. The 26 cases which were dynamized went on to union between 13 and 28 weeks (average 19.2 weeks) with two poor results, including one nonunion. The cases that were not dynamized went on to union between 16 and 30 weeks (average 23.5 weeks) with two poor results, including one nail breakage. Though final results are comparable, the study suggests that dynamization after open interlocking nailing significantly shortens the mean time to union, though it does not significantly affect the union rate of the femoral shaft fractures.

Keywords : interlocking nailing ; dynamization ; femoral fractures.

Mots-clés : enclouage verrouillé ; dynamisation ; fractures du fémur.

INTRODUCTION

While interlocking nailing of femoral shaft fractures has become extremely popular over the past two decades (15), opinions regarding the need for routine dynamization vary widely – those advocating dynamization include the early proponents of the method (9, 10, 11) as well as authors of recent

publications (2, 8, 17). On the other hand, there are those who think that routine dynamization is unnecessary (3, 4, 12, 16, 20) and some even implicate it as a cause of delayed union (21, 22, 23).

However, in all these reported studies, most of the cases were treated by closed nailing, with only a handful of cases of open nailing, the latter too small in number to be of statistical significance in studying the effect of dynamization after open nailing. Since open reduction has become a rarity, the role of dynamization after open reduction has never been documented. However, it is undeniable that open reduction is still required, albeit infrequently, in some cases of femoral shaft fractures, especially in difficult reductions and in cases with implants from previous surgery (16). Open nailing was done in all the cases in the present study due to non-availability of image intensifier fluoroscopy in our institution at the time when these operations were done. The implant used was a modified Grosse-Kempf nail with an external jig system for proximal and distal locking which allowed us to interlock without fluoroscopic control.

The purpose of the present study was to explore the impact of dynamization in femoral shaft fractures treated by open reduction and interlocking

¹ R. G. Kar Medical College, Calcutta, India.

² Shree Vishudhanand Hospital and Research Institute, Calcutta, India.

Correspondence and reprints : M. N. Basumallick, 63/21/4, Dumdum Road, 'Surermath', Calcutta, India. Pin-700074. E-mail : manabm@mantramail.com.

nailing. We expect the results to be a reference for those rare cases in which open reduction might be required, despite image intensifier fluoroscopy being available.

MATERIAL AND METHOD

Fifty-four patients with femoral shaft fractures were treated by open reduction and modified Grosse-Kempf interlocking intramedullary nailing at the authors' institution between January 1997 and December 1998. The age of the patients varied between 16 and 60 years. There were 40 males and 14 females.

Five of these fractures were in the proximal one third, 36 were in the middle one third and 13 fractures were in the lower one third. All were closed femoral diaphyseal fractures. Thirty-seven fractures were 2A, 11 were 2B and 6 were 2C according to the AO classification system. All of these fractures were closed.

Pre-operatively, skeletal traction was applied to all patients awaiting surgery. The interval between the injury and the operation was 10 days on average (range 2 to 36 days). The average operating time was 70 minutes (range 55 to 110 minutes).

All the patients had open nailing, interlocked initially in the static mode. The implant used was a modified Grosse-Kempf nail with a Grosse-Kempf model external interlock-targeting device for both the proximal and distal holes. The operation was done with the patient in lateral decubitus. In all cases 2 proximal and 2 distal locking screws were put in. Interlocking was confirmed by radiography in the operating room. Additional fixation with cerclage wiring was used in 4 cases to fix large butterfly fragments in type 2B fractures. Primary bone grafting was done additionally in 5 cases of type 2C fracture. The patients were then randomly selected for dynamization, by the use of sealed envelopes at the time of discharge.

Post-operatively, the patients were allowed active knee and hip mobilization in bed as soon as pain subsided and non-weight bearing ambulation with crutches after stitch removal. They gradually progressed to full weight bearing as pain subsided and discarded all support when the fractures were declared to have united clinically and radiologically, whichever was later.

The cases were evaluated clinically from time to time by one independent observer blinded regarding clinical and radiological evidence of union. His decision was considered binding on the investigation of the study.

Clinical criteria of union were : absence of local tenderness and pain on stressing the fracture site or on bearing weight fully on the operated limb.

Radiological healing of the fracture was defined as presence of callus around the fracture circumference with density similar to that of adjacent cortex, or obliteration of fracture line, whichever was earlier.

Healing of the fracture was considered complete when both clinical and radiological criteria of union were fulfilled to the satisfaction of the authors and the independent observer.

The patients were followed up for at least 2 years post-operatively.

A total of 27 cases underwent dynamization – 20 males and 7 females. One case was lost to follow-up. Among the final 26 cases, there were 20 males and 6 females with mean age 36.7 years (range 16-60 years). There were 17 type 2A fractures, 5 type 2B fractures and 4 type 2C fractures. Three cases of type 2B fracture were given additional cerclage wiring. Three cases of type 2C fracture were given additional bone grafting. Dynamization was done between 8 and 12 weeks for type 2A fractures and at 12 weeks for type 2B and type 2C fractures. The screws farthest from the fracture were removed. In all, 26 femoral fractures were dynamized. One patient originally selected for dynamization did not turn up for follow-up and was excluded from the study.

A total of 26 cases were selected for non-dynamization – 19 males and 7 females. Two cases were lost to follow-up. Among the final 24 cases, there were 17 males and 7 females with mean age 37 years (range 18-57 years). There were 19 type 2A fractures, 4 type 2B fractures and 1 type 2C fracture. Two cases of type 2B fracture were given additional cerclage wiring. One case of type 2C fracture was given additional bone grafting.

One patient died from an unrelated disease (congestive cardiac failure in a known case of dilated cardiomyopathy) six days after operation. Three patients did not turn up for follow-up (1 was destined for dynamized mode, 2 were destined for non-dynamized mode). These 4 patients were not included in the assessment of results.

The results were graded at the end of 2 years into 4 groups : excellent, good, fair and poor. The criteria of classification were as proposed by Thoressen *et al.* (16) with the addition of nonunion at 9 months or nail breakage as criteria for a poor result (table I).

RESULTS

A) Of the 24 patients with femoral fractures in whom dynamization was not carried out, union

Tab. I. — Criteria for classification of results (modified from Thoresen *et al.* (1985))

Criteria	Result			
	Excellent	Good	Fair	Poor
• Malalignment of femur (degrees)				
Varus/Valgus	5	5	10	> 10
Antecurvatum / Recurvatum	5	10	15	> 15
Internal rotation	5	10	15	> 15
External rotation	10	15	20	> 20
Shortening of femur (cm)	1	2	3	> 3
• Knee motion (degrees)				
Flexion	> 120	120	90	< 90
Extension deficit	5	10	15	> 15
• Pain / Swelling	None	Minor	Significant	Severe
• Nonunion/Nail breakage	Absent	Absent	Absent	Present

occurred in 23 between 16 and 30 weeks (average : 23.45 weeks) ; thus, the union rate was 95.8%. Nineteen patients had excellent results, 2 had good results, 1 had a fair result and 2 had poor results.

Of the 2 patients who had good results, one had internal rotation malalignment of 10° because of nonanatomic reduction due to comminution. The second case had persistent mild pain over the upper end of the nail, which projected about 1.5 cm beyond the tip of the greater trochanter.

One patient with a fair result had knee stiffness (knee motion 0°-90°) and pain and swelling of the knee.

Of the 2 patients who had poor results, 1 had nail breakage before union at 24 weeks— this patient had to be reoperated. Remarkably, nail breakage was followed by enormous callus formation during the period before operation, which was done one month after the breakage (fig. 1). This patient was later treated by open removal of implants, repeat interlocked nailing with bone grafting, dynamization at 8 weeks and went on to union uneventfully. The second patient developed chronic osteomyelitis with knee stiffness (knee motion 0°-30°) although the fracture went on to union.

B) Among the 26 femoral fractures which were dynamized, union occurred between 13 and 28 weeks (average : 19.2 weeks) in 25 out of 26 patients. The union rate was 96.2%. There were 21 excellent, 2 good, 1 fair and 2 poor results.

Of the 2 patients who were graded as good, 1 had knee stiffness resulting in loss of knee flexion beyond 110° – this was probably due to delay in surgery and poor patient motivation. The second patient had a shortening of 1.5 cm, measured clinically, as the distance between the tip of the greater trochanter and the lateral knee joint line. He had a type 2A fracture and delayed surgery (27 days) because of systemic illness. Radiographs at 12 weeks showed significant bone resorption at the fracture site and at this time the nail was dynamized. Collapse occurred after dynamization leading to shortening. Union occurred at 28 weeks (fig. 2).

One patient who was graded as fair had knee stiffness, with knee flexion restricted to 90°. This might again be due to delayed surgery and a more delayed rehabilitation program.

Two results were graded as poor. One had chronic osteomyelitis with knee stiffness (knee motion : 0°-40°). However, in this patient the fracture united at 13 weeks, due to massive periosteal reaction. The second patient was graded as poor because of nonunion declared at 9 months when bone grafting was done. The fracture went on to unite at 50 weeks.

In the entire series two femoral fractures had deep infection, one in each group. Both of them developed knee stiffness and were graded as poor results. There was a single case of malunion with a

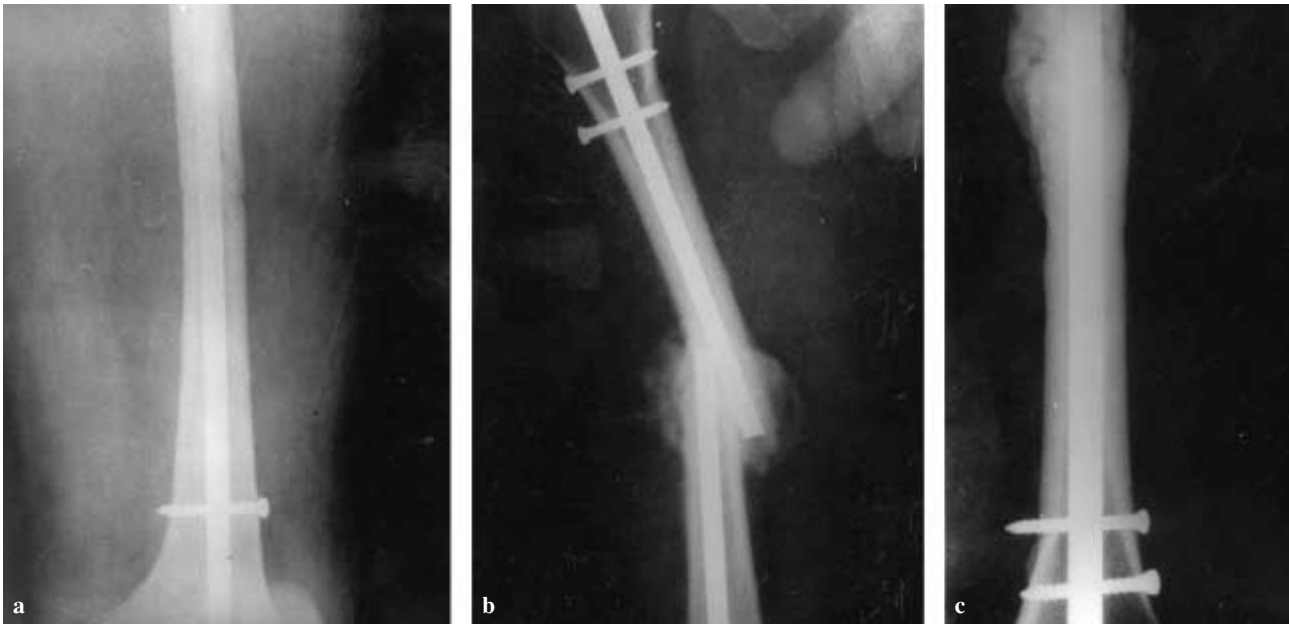


Fig. 1. — **a.** postoperative radiographs ; **b.** 30 weeks postoperative radiographs- 4 weeks after nail breakage ; **c.** 32 weeks after 2nd ORIF with interlocking nailing.

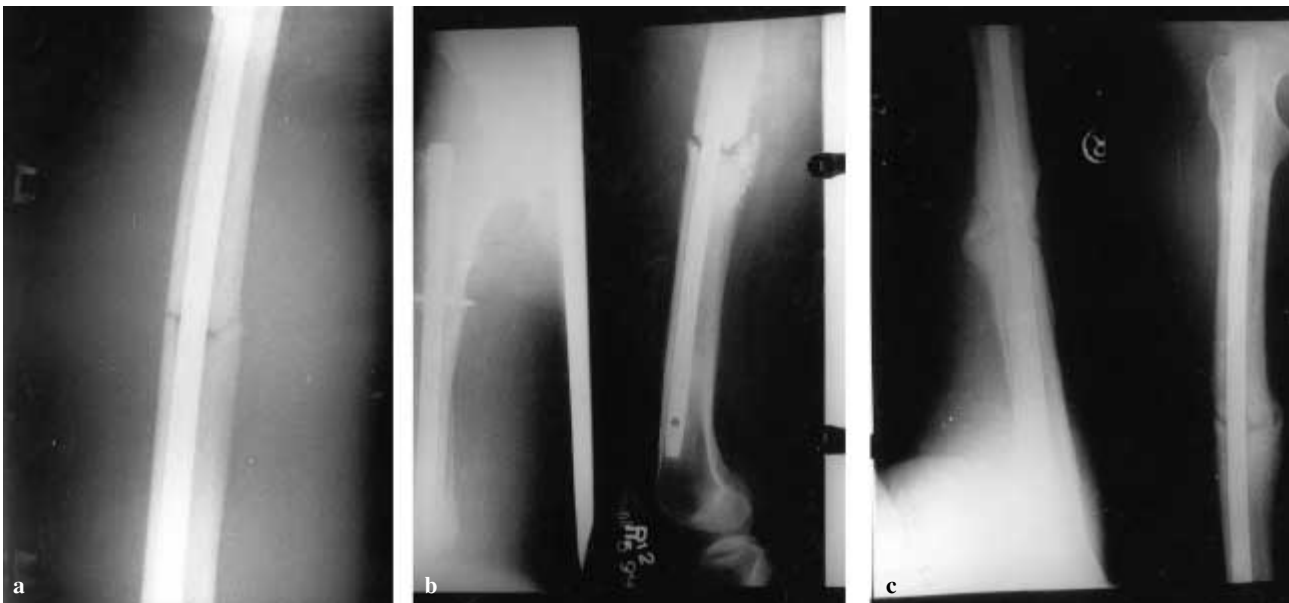


Fig. 2. — **a.** postoperative radiographs ; **b.** 12 weeks postoperative radiographs-date of dynamization ; **c.** 28 weeks postoperative radiographs.

10° rotational malalignment, probably due to faulty initial reduction.

Of the 50 patients who were finally part of the study (24 static nailing and 26 dynamic nailing),

only 16 patients were actively employed and could give their time of return to work (10 static nailing and 6 dynamic nailing). Time to return to work was 27.2 weeks in the 10 cases of static nailing (range

21-32 weeks) and 22.6 weeks in the 6 cases of dynamic nailing (range 21-25 weeks). A large number of the cases were not actively employed (14 housewives, 17 unemployed and 3 retired) and could not definitively recollect their time of return to normal activity.

DISCUSSION

Although closed interlocking nailing of femoral shaft fractures is the order of the day (15), most of the published series report small numbers of cases in which the fractures were either open or had to be opened, either to remove old implants or because of technical difficulty. The number of such cases of open nailing is too small however to be of statistical significance as a separate group. Therefore the experience with such open interlocking nailing is also limited, though every surgeon must have had the occasion to carry out such a procedure every now and then. Furthermore, there has been no documentation of the role of dynamization following open interlocking nailing.

The need for routine dynamization after static interlocking nailing is still controversial : there are people on both sides of the argument.

In the light of these two above-mentioned conditions, the present study tries to envisage the role of dynamization after open interlocking nailing of femoral shaft fractures. Though open interlocking nailing is infrequently done and interlocking without fluoroscopic control is quite rare nowadays, the present study of the role of dynamization is aimed at that select group in which open reduction is required.

Dynamization, or dynamic interlocking nailing, has been blamed for causing loss of reduction and shortening in comminuted femoral shaft fractures (3, 4, 6). Furthermore, a second operation is required for dynamization. The benefits of dynamization and the timing of it is still very controversial (3, 4, 6, 18, 20, 21, 21, 22). On the other hand, it has also been credited with accelerating the rate of union in delayed unions (3, 19, 20). Static nailing has the advantage of maintaining reduction, alignment and length especially in comminuted and segmental fractures (4, 6, 21, 22, 23) and the

disadvantage of a risk for implant failure at the proximal screw of the distal group (5).

In the present study there were no significant differences between the union rates in the dynamized and nondynamized groups (96.2% vs. 95.8%). Union rates quoted by various authors are 98.2% (20), 96% (12), 97% (19) or even 59% in a series of dynamized nails (21). Our groups were comparable with regard to age, sex and fracture types. The number of cases receiving additional fixation or bone grafting was also comparable in both groups. The percentages of fair and poor results in the two groups were also similar. However, the mean time to fracture union was significantly shorter in cases where dynamization was done (19.2 weeks) than in cases where routine dynamization was not done (23.5 weeks) [$p < .05$]. However, it is also true that our single case of shortening occurred after dynamization. This reinforces the general opinion that static nailing is capable of maintaining limb length better than following dynamization, especially in comminuted fractures. The average healing time of femoral shaft fractures after closed interlocking nailing is quoted by various authors as 4.5 months (9), 16 weeks (16), 17 weeks (6), 18 weeks (1). The mean time to union after dynamization in the present study (19.2 weeks) compares favorably with that achieved after closed nailing.

In 1978 Grosse *et al.* advised dynamization (9) in the 3rd post-operative month for simple fractures and in the 5th month for severely comminuted fractures. Others (3, 4, 14) also advocate dynamization between 12 and 14 weeks. However, there are still others (19, 20, 21) who opted for dynamization 6 to 7.8 months after operation and did not find dynamization beneficial. Dynamization 6 to 8 months after operation (21, 22, 23) may be either unnecessary or too late, or was probably being done specifically in cases of delayed union or non-union. In the present study, the fractures were dynamized between 8 and 12 weeks post-operatively, since it was felt that at this time there was enough fracture callus to guard against excessive mobility but still enough plasticity to allow compression of the fragments.

The incidence of malunion in the present study (only 1 out of 50-2%) is less than in most other

series 44% (12), 15% (13), and 6% (19). This can be attributed to the more accurate reduction achievable after open reduction and to the fact that the postoperative regime in the present study was more guarded than in most other series.

The incidence of infection in the present study (4%) is higher than that reported in most studies of closed nailing. This is an accepted problem after open reduction, but it did not affect the comparative result of the present study because it affected one patient in each of the two groups.

CONCLUSION

Though there is still controversy over the utility of dynamization in closed intramedullary interlocking nailing of the femur, the present series of open interlocking nailing with and without dynamization indicates that, while dynamization does not change the union rate of the fracture as compared to static nailing, it definitely shortens the mean time to union. Dynamization after open interlocking nailing is also capable of achieving healing times comparable to closed interlocking nailing. However, it has the disadvantage of causing femoral shortening in some instances. Open interlocking nailing itself is responsible for increasing the incidence of postoperative infection and should be resorted to only in cases in which closed nailing is not possible or suitable. Therefore, it is concluded that dynamization should be considered 8 to 12 weeks post-operatively in those cases of intramedullary interlocking nailing of femurs that require open reduction.

REFERENCES

- Anastopoulos G., Aimakopoulos A., Exarchou E., Pantazopoulos T. Closed interlocked nailing in comminuted and segmental femoral shaft fractures. *J. Trauma*, 1993, 35, 772-775.
- Brug E., Pennig D. Indications for interlocking nailing. *Unfallchirurg.*, 1990, 93 492-498.
- Brumbach R. J., Reilly J. P., Poka A., Lakatos R. P., Bathon G. H., Burgess A. R. Intramedullary nailing of femoral shaft fractures. Part I : Decision-making errors with interlocking fixation. *J. Bone Joint Surg.*, 1988, 70-A, 1441-1452.
- Brumbach R. J., Uwagi-Ero S., Lakatos R. P., Poka A., Bathon G. H., Burgess A. R. Intramedullary nailing of femoral shaft fractures. Part II : Fracture-healing with static interlocking femoral fixation. *J. Bone Joint Surg.*, 1988, 70-A, 1453-1462.
- Bucholz R., Rathjen K. Concomitant ipsilateral fractures of the hip and femur treated with interlocking nails. *Orthopedics* 8 :1402, 1985.
- Christie J., Court-Brown C., Kinniworth A. W., Howie C. Intramedullary locking nails in the management of femoral shaft fractures. *J. Bone Joint Surg.*, 1988, 70-B, 206-210.
- Campbell's Operative Orthopedics, ed. 8th, 1988, Mosby, Saint-Louis.
- Georgiadis G. M., Minster G. J., Moed B. R. Effects of dynamization after interlocking tibial nailing : an experimental study in dogs. *J. Orthop. Trauma*, 1990, 4, 323-330.
- Grosse A., Kempf I., Lafforgue D. Le traitement des fractures, pertes de substance osseuse et pseudarthroses du fémur et du tibia par l'enclouage verrouillé (à propos de 40 cas). *Rev. Chir. Orthop.*, 1978, 64 (Supplément 2), 33-35.
- Kellam J. F. Early results of Sunnybrook experience with locked intramedullary nailing. *Orthopaedics*, 1985, 8, 1387-1388.
- Kempf I., Grosse A., Beck G. Closed locked intramedullary nailing. *J. Bone Joint Surg.*, 1985, 67-A, 709-720.
- Majkowski R. S., Baker A. S. Interlocking nailing for femoral fractures : an initial experience. *Injury*, 1991, 22, 93-96.
- Pintore E., Maffuli N., Petricciulo F. Interlocking nailing for fractures of the femur and tibia. *Injury*, 1992, 23, 381-386.
- Riquelme A. G., Rodriguez A. J., Mino G. L., Sanmartin R. M. Treatment of the femoral and tibial fractures with Grosse and Kempf locking nails. *Clin. Orthop.*, 1992, 283, 86-89.
- Rockwood C. A. Jr., Green D. P., Bucholz R. W. *Fractures in Adults*. Lippincott J. B., Philadelphia, 1991, pp. 1689-1712.
- Thoresen B. O., Alho A., Ekeland A., Stromse K., Folleras G., Haukebo A. Interlocking intramedullary nailing in femoral shaft fractures. *J. Bone Joint Surg.*, 1985, 67-A, 1313-1320.
- Waddell J. P. Effect of dynamization of a static interlocking nail in promoting fracture healing. *Can. J. Surg.*, 1993, 36, 294.
- Winqvist R. A., Hansen S. T. Jr., Clawson D. K. Closed intramedullary nailing of femoral fractures. *J. Bone Joint Surg.*, 1984, 66-A, 529-539.
- Wiss D. A., Brien W. W., Stetson W. B. Interlocked nailing for treatment of segmental fractures of the femur. *J. Bone Joint Surg.*, 1990, 72-A, 724-728.
- Wiss D. A., Fleming C. R., Matta J. M., Clark D. Comminuted and rotationally unstable fractures of the

- femur treated with an interlocking nail. Clin. Orthop., 1986, 212, 35-47.
21. Wu C. C. The effect of dynamization on slowing the healing of femur shaft fractures after interlocking nailing. J. Trauma, 1997, 43, 263-267.
 22. Wu C. C., Chen W. J. Healing of 56 segmental femoral shaft fractures after locked nailing. Poor results of dynamization. Acta Orthop. Scand., 1997, 68, 537-540.
 23. Wu C. C., Shih C. H. Effect of dynamization of a static interlocking nail on fracture healing. Can. J. Surg., 1993, 36, 302-306.

SAMENVATTING

M. N. BASUMALLICK, A. BANDOPADHYAY. Het effect van dynamisatie bij open verankerde mergnageling van dijbeenbreuken: prospectieve vergelijkende en gerandomiseerde studie van 50 gevallen met 2jaar opvolging.

Vijftig dijbeenschaftbreuken werden behandeld met open reductie en statisch verankerde intramedullaire nageling. Willekeurig werden 26 gevallen geselecteerd voor dynamisatie; 24 bleven statisch verankerd. Alle gevallen werden minstens 2 jaar opgevolgd

Consolidatie van de gedynamiseerde breuken werd verkregen na 13 tot 28 weken (gemiddeld 19.2 weken). Twee eindigden met een slecht resultaat, waarvan één door pseudarthrosis.

Bij de niet-gedynamiseerde gevallen was de heling bereikt na 16 tot 30 weken (gemiddeld 23.5 weken) ook twee slechte resultaten, waaronder één met nagelbreuk. De uiteindelijke resultaten zijn vergelijkbaar in beide groepen; dynamisatie bij open statisch verankerde intramedullaire dijbeenschaft nageling lijkt de heling flink te verkorten, nochtans zonder de kansen op consolidatie te verbeteren.

RÉSUMÉ

M. N. BASUMALLICK, A. BANDOPADHYAY. Traitement des fractures diaphysaires du fémur par enclouage verrouillé à foyer ouvert avec ou sans dynamisation : étude prospective randomisée.

Les auteurs ont cherché à évaluer par une étude prospective randomisée l'influence de la dynamisation ou de l'absence de dynamisation après enclouage verrouillé réalisé à foyer ouvert pour des fractures diaphysaires du fémur. Cinquante fractures diaphysaires du fémur ont été traitées par enclouage à foyer ouvert, avec verrouillage statique. Par randomisation, 26 des 50 patients ont été désignés pour être dynamisés, les 24 autres pour être traités sans dynamisation. Ils ont été suivis un minimum de deux ans. Les 26 cas dynamisés ont consolidé en 13 à 28 semaines (moyenne : 19,2 semaines) ; il y a eu dans ce groupe deux mauvais résultats dont une pseudarthrose. Les cas non dynamisés ont consolidé après 16 à 30 semaines (moyenne : 23,5 semaines) ; il y a eu dans ce groupe deux mauvais résultats dont une fracture de clou. Bien que le résultat final soit comparable, cette étude suggère que la dynamisation après enclouage verrouillé à foyer ouvert réduit significativement le délai de consolidation, sans affecter de façon significative le taux de consolidation après fracture diaphysaire du fémur.