

# GIANT LIPOFIBROMA OF THE HAND. A CASE REPORT

A. ALVAREZ JORGE, M. ULLOA CEREZALES, F. MARTELO VILLAR

The authors report a rare case of giant soft tissue tumor of the hand (histologically a fibrolipoma), invading the entire midpalm and extending into the third finger, with relatively few clinical symptoms. They discuss the differential diagnosis with other tumor masses of the hand and describe the surgical technique implemented. The literature on lipomas affecting the hand is briefly reviewed.

**Keywords :** hand ; tumor ; lipoma ; lipofibroma.  
**Mots-clés :** main ; tumeur ; lipome ; lipofibrome.

## INTRODUCTION

Lipomas are well encapsulated tumors which seldom recur after complete primary resection. The shape of these tumors is generally determined by the boundaries of the anatomical space they occupy, but they tend to be rounded in the absence of such a limitation. Fatty tissue tumors have the ability to invade small anatomical recesses, resulting in masses very variable in size and shape. The latter is especially true in the case of lipomas of the hand, which seem to be very uncommon (2, 4).

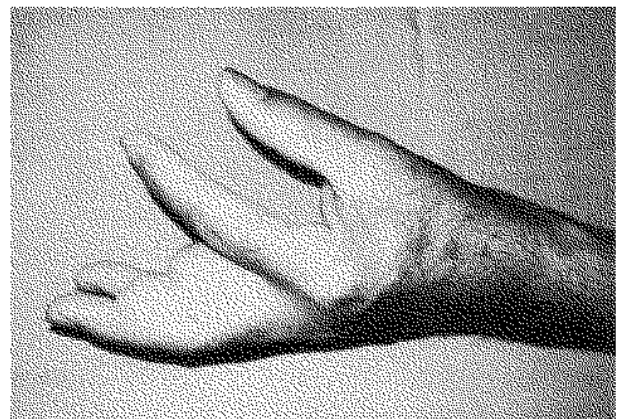
According to Mason, lipomas are classified into two groups : superficial or subcutaneous and deep or subfascial (1, 7).

The clinical diagnosis of lipomas of the hand is often difficult, because these tumors are located below the tense elastic palmar aponeurosis of the hand, and their appearance on physical examination is entirely different from that of subcutaneous lipomas. Palmar lipomas can be observed in different locations, wherever there is an opening or defect in the palmar fascia. Owing to the stringent limits of anatomical spaces in the hand, lipomas may appear tense, as opposed to subcutaneous lipomas, and differential diagnosis with a ganglion may be difficult.

## CASE REPORT

The patient, a 62-year-old man, had observed a slow-growing, soft subcutaneous mass in his left hand, affecting the midpalm and extending into the third finger, seven years before admission. A plastic surgeon diagnosed a small, uncomplicated lipoma, which did not compromise the performance of the affected hand. Surgical resection was discouraged.

Five months before admission, he began to feel clumsiness and fullness, with numbness affecting the second and third fingers of his left hand. Physical examination disclosed a large mass affecting the entire mid-palm and the third finger, which could not be fully flexed (fig. 1). A presumptive diagnosis of giant synovial cyst or lipo-



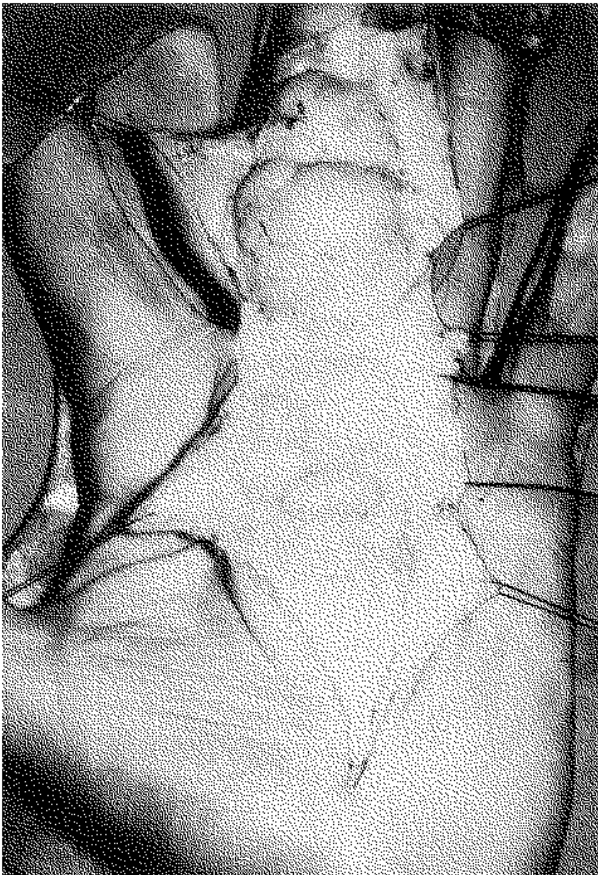
*Fig. 1.* — Lateral view of the hand shows the functional impairment.

Department of Plastic and Reconstructive Surgery, Hospital Juan Canalejo, 15006, A Coruña, Spain.

Correspondence and reprints : A. Alvarez Jorge, Department of Plastic and Reconstructive Surgery, Hospital Juan Canalejo, Xubias de Arriba, 84, 15006, A Coruña, Spain.

fibroma was established, and surgical exploration was decided upon.

Surgery was performed under brachial plexus anesthesia, and using magnifying glasses (2.5×). A Z-shaped incision was carried out along the third finger and palm, disclosing a large subcutaneous, multilobulated, fatty tumor, extending medially beneath the palmar fascia. The operating field was extended proximally to the carpal tunnel, to remove the whole tumor without damaging hand vessels or nerves (fig. 2).



*Fig. 2.* — Surgical exposure of the multilobulated tumor. The tumor extended proximally into the carpal tunnel, and distally at the IFD level of the third finger.

The tumor extended proximally beyond the carpal tunnel at the wrist, and distally into the lumbrical channels, wrapping around neurovascular bundles, but did not invade the tendon sheaths.

After surgery, a compressive dressing was applied, and no drains were left in situ.

Tumor size was 20 × 4.5 × 2.5 cm, and a histologic diagnosis of lipofibroma was established. Full functional recovery of the hand was evident in a few weeks. No evidence of recurrence has been detected 30 months later.

## DISCUSSION

Lipomas appear to affect the hand very infrequently. Adair *et al.* reviewed 352 lipomas in 134 patients, and found only two lipomas of the hand (1). Also, Phalen *et al.* reviewed 112 pathologically confirmed lipomas, and 12 were located in the hand, but only one affected the palm (7). Otherwise only 7 lipomas were described in a wide series of 500 benign subcutaneous tumors affecting the wrist and hand, collected by the Cleveland Clinic over ten years (7). White and Hanna reported on 51 patients with lipomas affecting the upper extremities; of these, 5 affected the wrist, 6 implicated the palm and 2 were located in the fingers (8). Nonetheless, the possibility remains that these tumors often are not reported.

Lipomas affecting the volar aspect of the wrist may result in compression of the median nerve. Patients frequently report fullness and clumsiness in the affected hand, but a limitation of movement of the hand or wrist, as observed in our case, is not generally described (4, 5, 6).

Surgical removal of these tumors is apparently simple, favored by their encapsulation. However, in the present case, the tumor extended into the palmar fascia and interosseous muscles, stretching the neurovascular bundles of the third finger, even though sensibility at the level of that finger was preserved.

Incomplete removal may be a significant cause of recurrence (3).

In conclusion, the diagnosis of hand lipomas is straightforward, provided the clinician is aware of this possibility. Only enlarging or symptomatic hand lipomas clearly deserve resection but, in practice, surgical removal is frequently requested by the patient, to ensure an accurate diagnosis.

## REFERENCES

1. Adair F. E., Pack G. T. Farrior J. H. Lipomas. Am. J. Cancer, 1932, 16, 1104-1109.
2. Booher R. J. Lipoblastic tumors of the hand and feet : Review of the literature and report of thirty-three cases. J. Bone Joint Surg., 1965, 47-A, 727-731.
3. Butler E. D. Hamill J. P. Seipel R. S. DeLorimier A. A. Tumors of the hand : A ten-year survey and report of 437 cases. Am. J. Surg., 1960, 100, 293-301.
4. Kernohan J., Dakin P. K. Quain J. S., Helal B. An unusual "giant" lipofibroma in the palm. J. Hand Surg., 1984, 9-B, 347-348.
5. McEnery E. T. Jr, Schmitz R. L. Nelson P. A. Palmar lipoma : Report of a case. Arch. Surg., 1959, 79, 699-701.
6. Patel M. E. Silver J. W., Lipton D. E., Pearlman H. S. Lipofibroma of the median nerve in the palm and digits of the hand. J. Bone Joint Surg., 1979, 61-A, 393-397.
7. Phalen G. S., Kendrick J. I., Rodriguez J. M. Lipomas of the upper extremity. Am. J. Surg., 1971, 121, 298-305.
8. White W. L. Hanna D. C. Troublesome lipomata of the upper extremity. J. Bone Joint Surg., 1962, 44-A, 1353-1358.

## SAMENVATTING

*A. ALVAREZ JORGE, M. ULLOA CEREZALES, F. MARTELO VILLAR. Reuzegroot lipofibroma van de hand.*

De auteurs beschrijven een reuzegrote weke-delen tumor (histologie : fibrolipoma) die midpalmair invadeert, met uitbreiding naar de derde vinger, met relatief weinig klinische symptomen. De differentieel diagnose, de chirurgische techniek en de literatuur wordt besproken.

## RÉSUMÉ

*A. ALVAREZ JORGE, M. ULLOA CEREZALES, F. MARTELO VILLAR. Lipofibrome géant de la main. Description d'un cas.*

Les auteurs présentent le cas d'une tumeur géante des tissus mous de la main (lipofibrome), qui envahissait la totalité de la région palmaire moyenne, s'étendant au médius. Les signes cliniques étaient très discrets. Le diagnostic différentiel par rapport à d'autres masses tumorales au niveau de la main est discuté. Finalement, les auteurs présentent une brève revue de la littérature concernant les lipomes localisés à la main.