

TRANSCUTANEOUS ELECTRICAL STIMULATION (TCES) FOR THE TREATMENT OF ADOLESCENT IDIOPATHIC SCOLIOSIS : PRELIMINARY RESULTS

by M. ANCIAUX, A. LENAERT, M. L. VAN BENEDEN, W. BLONDE and M. VERCAUTEREN (†)

The authors report on the results of a preliminary study on the treatment of progressive idiopathic scoliosis by electrical surface stimulation.

The study, involving 30 spinal curvatures, showed stabilization of the median primary curvature (30°) in the course of treatment, the median duration of which was 12 months. Overall, 73.2% of the curvatures treated, responded favorably (stabilization or regression of the curve); however, 26.8% of the curvatures progressed in spite of the transcutaneous electrical stimulation treatment. The only complication noted was contact eczema in 20% of the cases. The authors feel that surface electrical stimulation treatment can be regarded as an acceptable alternative to a brace in the treatment of idiopathic scoliosis, and at this stage it deserves a place in the conservative therapeutic approach to idiopathic scoliosis.

Keywords : electrical stimulation ; idiopathic scoliosis.

Mots-clés : stimulation électrique ; scoliose idiopathique.

SAMENVATTING

M. ANCIAUX, A. LENAERT, M. L. VAN BENEDEN, W. BLONDE en M. VERCAUTEREN (†). Behandeling van progressieve idiopathische scoliose met transcutane elektrostimulatie. Eerste resultaten.

De auteurs geven de resultaten weer van een studie handelend over de behandeling van progressieve idiopathische scoliose met transcutane elektrostimulatie. De studie, handelend over 30 primaire curven, toont een stabilisatie van de mediane primaire curve (30°) tijdens de behandeling. De mediane behandelingsduur bedroeg 12 maand.

In 73,2% der gevallen werd een bevredigend resultaat bekomen (stabilisatie of regressie van de curve); 26,8% der curven toonden echter een progressie ondanks het toepassen van de transcutane elektrostimulatie.

Contacteczem was de enige belangrijke nevenwerking en deed zich voor in 20% der gevallen.

De auteurs menen dat de transcutane elektrostimulatie kan beschouwd worden als een aanvaardbaar alternatief voor de behandeling van idiopathische evolutieve scoliose met orthopedische corsetten.

RÉSUMÉ

M. ANCIAUX, A. LENAERT, M. L. VAN BENEDEN, W. BLONDE et M. VERCAUTEREN (†). Traitement des scolioses idiopathiques évolutives par l'électrostimulation transcutanée (ESTC). Premiers résultats.

Les auteurs rapportent les premiers résultats du traitement des scolioses idiopathiques évolutives par ESTC, portant sur 30 courbures. Après une durée moyenne de traitement de 12 mois, ils ont obtenu une stabilisation de la courbure primitive moyenne (30°).

Au total, les résultats favorables sont de 73,2% (stabilisation ou régression de la courbure); par contre 26,8% des courbures ont évolué malgré l'ESTC.

La seule complication observée fut un eczéma de contact dans 20% des cas.

Les auteurs estiment que l'ESTC peut être considérée comme une alternative valable au traitement des scolioses idiopathiques par corset orthopédique et

From the Department of Orthopedic Surgery and Physical Medicine, University Hospital, Ghent (Belgium).

qu'elle peut dès à présent prendre place dans l'arsenal thérapeutique non chirurgical des scolioses idiopathiques.

INTRODUCTION

Since its introduction by Axelgaard and Brown (2, 3, 4, 5) in the 1970s, TCES has been widely used in the treatment of adolescent idiopathic scoliosis and has been the subject of several clinical studies (table I).

The encouraging results reported in the literature stimulated us to initiate this treatment program in our service in an attempt to find a viable and equally effective alternative to orthopedic bracing (type Milwaukee, Boston or Lyon), free of the brace-related physical and psychological problems. To this end, TCES was applied to virtually all patients who were considered candidates for brace treatment.

METHOD

Patient Selection Criteria

TCES was used in adolescents showing progressive idiopathic scoliosis who were considered

candidates for orthopedic bracing according to criteria used in our department. These criteria are : a primary curvature of 20 to 45° (Cobb measurement) with a proven curve progression of more than 5° for curvatures of 30° or less, the patient should not have reached skeletal maturity as defined by the Risser sign and complete ossification of the vertebral epiphyses.

Since several authors (2, 9, 24) have shown that the choice of strict selection criteria relating to curve progression as devised by Axelgaard (2) does not affect the outcome of TCES treatment, we did not subject our patients to a strict inclusion protocol but considered the mean parameters of the population treated, as suggested by these authors.

Stimulation Technique and Treatment Protocol

We have opted for transcutaneous stimulation of the paravertebral muscles on the convex side of the primary curve, the electrode location being intermediate with respect to the midsagittal plane (fig. 1).

Table I. — Transcutaneous electrical stimulation. Clinical studies

	n	Curvature	Age	Maturity			$\Delta t/\text{Freq. } \theta$	F-U	Success rate
				Risser sign	Skeletal age	Growth potential			
Mc Collough	79 16	22° (15-31°)	12.4 yrs	—	—	≥ 2 yrs	8 hrs/night	27 mos	85% ($< 4^\circ /$)
Bradford	83 25	(20-40°)	?	< 3	—	—	8 hrs/night	30 mos	68% ($< 5^\circ /$)
Brown, Axelgaard Howson	548 84	25° 33,9°	12.8 yrs 13.3 yrs	— —	12.5 yrs 13.3 yrs	—	8 hrs/night	12 mos	752% ($\leq 5^\circ /$)
De Mauroy, Stagnara	21 85	25° (14-37°)	?	—	12.2 yrs	—	8 hrs/night	?	80% ($\leq 5^\circ /$)
Altekruse Heine	106 85	21°	11.3 yrs	< 2	—	—	8 hrs/night	20.2 mos	82% ($\leq 5^\circ /$)
Mc Collough	86 91 118 170	(20-29°) (20-29°) $\geq 5^\circ /$ (30-40°)	13 yrs 12.8 yrs 12.8 yrs	—	—	≥ 2 yrs	8 hrs/night	17.2 19.1 14.7 mos	90% 90% ($< 5^\circ /$) 78%

* Cobb measurement of median curvature.

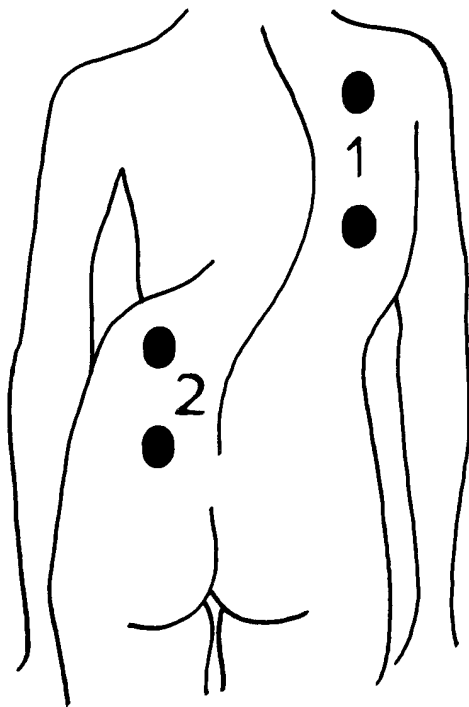


Fig. 1. — Intermediate electrode placement. 1 : primary thoracic curvature ; 2 : primary lumbar curvature.

A portable stimulator, developed in our service, delivers trains of neofaradic rectangular monophasic pulses with a frequency of 100 Hz, a pulse width of 0.2 msec and a duty cycle of 4 sec on and 6 sec off (fig. 2). The amplitude of the current is regulated so as to produce good muscular contraction. Self-adhesive electrodes are placed equidistant from the apex of the curve. The most effective electrode position is determined by means of a standard stimulator under visual and tactile control of muscular contraction. TCES is applied each night for at least 8 hours.

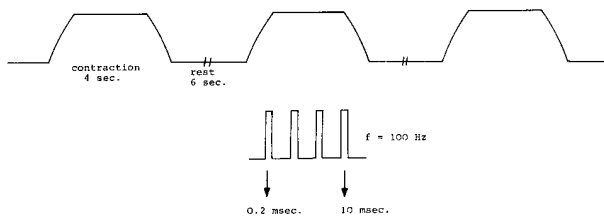


Fig. 2. — Stimulating current.

The patient is instructed to gradually increase the duration and intensity of stimulation during the first week of TCES treatment, until a minimum of 8 hours of nighttime stimulation at the given intensity is achieved.

Stimulation is discontinued abruptly once skeletal maturity is reached. Maturity criteria include Risser sign 4 or 5, ossification of all vertebral epiphyses and time elapsed since menarche.

Clinical and Radiological Assessments

TCES treatment is initiated after a thorough physical examination of the patient. Initial roentgenograms include lateral and anteroposterior films. A first followup visit takes place after 2 weeks of treatment to verify whether TCES is applied properly by the patient and parents. Corrections are made if necessary. The patient then returns to the clinic once every 3 months.

Once biannually, the checkup also includes a followup roentgenogram. At each visit the evolution of the curve is assessed as well as the correctness of electrode placement. Complications are addressed as needed, and patient compliance is recorded.

Interpretation of Results

The results have been assessed by means of radiographic measurement of curve progression using the Cobb method. The following criteria have been adopted : an increase in curve magnitude of more than 5° is considered a progression, a reduction in curve size of more than 5° represents a regression, and a maximum variation of 5° is classified as a stabilization. In the present preliminary study we have evaluated the effect of TCES in the course of treatment by looking for the evaluation of the median curvature in the TCES population and the percentage of curve progression, stabilization and regression in the entire population. We have taken into account the most recent results obtained both in patients still under treatment and in dropouts and the last results in the course of treatment for the patients who reached skeletal maturity. No evaluation was made after the interruption of TCES.

PATIENT POPULATION

The preliminary study comprised 32 female patients under TCES treatment, of whom 28 were retained for analysis of the therapeutic outcome. Four patients had to be withdrawn : 2 because of skin problems necessitating discontinuation of treatment and 2 because they were lost to follow-up. Two of the 28 patients considered had a primary double curvature. Each curve was stimulated and assessed separately.

A total of 30 stimulated curves were evaluated. There were 18 thoracic, 10 lumbar and 2 thoracolumbar curvatures (table II).

Table II. — Distribution of the stimulated curvatures

° Cobb	N	Th	L	ThL
16-20	2	1	1	—
21-25	6	3	3	—
26-30	7	3	3	1
31-33	8	6	2	—
26-40	4	2	1	1
41-45	3	3	—	—
n	30	18	10	2

Th : thoracic ; L : lumbar ; ThL : thoracolumbar.

The parameters defining the population treated are grouped in table III. Our prototypic patient was a young girl aged 14 yrs., 1 mo., in whom menarche occurred at the age of 14. At the onset of treatment, Risser sign was 1-2 and the curve measured 30° (Cobb).

DURATION OF TREATMENT

In this preliminary study, the median duration of treatment was 12 months (interquartile range 9 months, extremes 3-28 months).

At the time of the analysis of the results, 19 patients were still being treated, whereas TCES had been discontinued in the remaining 11 patients. Three patients had reached skeletal maturity ; in the remaining 8 patients TCES treatment had been terminated before completion : in 3 patients because the curvature had worsened to such an extent that surgery was required, in 1 patient on account of noncompliance, and in 2 patients because of contact eczema ; the last 2 patients discontinued treatment at their own discretion against our advice.

Table III. — Population treated

n = 30	Median value	Interquartile range	minimum-maximum	%
Age	14 yrs 1 mo	20 mos	13 yrs 4 mos – 16 yrs 9 mos	—
Sex				
0	—	—	— —	100
0	—	—	— —	0
Menarche				
Age	14 yrs	20 mos	11 yrs 9 mos – 16 yrs 4 mos	—
Yes	—	—	— —	37.7
No	—	—	— —	63.3
Duration	6 mos	11 mos	0-24 mos	—
Risser sign	1.75	3	0-4	—
0-1	—	—	— —	46.7
1-2	—	—	— —	20
2-3	—	—	— —	23.3
3-4	—	—	— —	10
Primary curvature	30°	11°	17°-42°	—

Whenever TCES had to be interrupted, prematurely or at skeletal maturity, the most recent results in the course of treatment were retained to determine the duration of treatment and to evaluate curvature progression.

RESULTS

In the course of our preliminary study, the median curvature of the population treated progressed from 30° * to 32.5° ** (fig. 3).

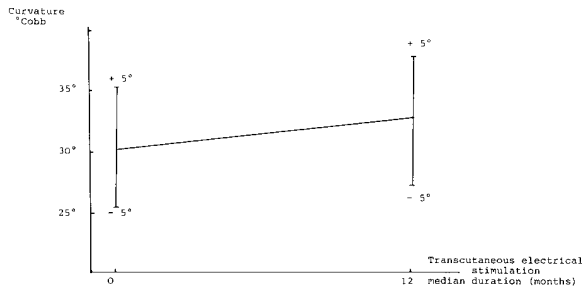


Fig. 3. — Median curvature progression rate under TCES.

No statistically significant difference was found when the amplitudes of the initial and final curvatures were compared using the Wilcoxon test, which indicates a stabilization of the primary median curvature under TCES.

Overall, arrest in progression of the curvature was achieved in 56.6% (17/30) of all cases and a regression in 16.6% (5/30), a success rate of 73.2%. Worsening occurred in 26.6% (8/30) of the curves under TCES treatment; 4 patients required surgery (posterior fusion with the Cotrel-Dubouset (3 cases) or Harrington (1 case) instrumentation).

COMPLICATIONS

The only major complication encountered was contact eczema in 4 of the 28 patients considered in this study.

If we include the 2 patients who withdrew from the program for the same reason, contact eczema

* Interquartile range 11°.
 ** Interquartile range 17°.

developed in 20% (6/30) of the cases. It was always confined to the sites of stimulation. A total of 4 patients had to abandon TCES for skin problems. In the remaining patients treatment could be continued by changing the type or location of the electrodes.

**TCES
 VERSUS ORTHOPEDIC BRACING**

In an attempt to find an alternative to an orthopedic brace for the treatment of adolescent idiopathic scoliosis, we compared the outcome of these two modes of treatment.

Since controlled comparative studies were not available, we compared our results with those reported in 2 studies (8, 15) that we considered representative of brace treatment.

In a first study (fig. 4) Cochran and Nachemson (8) found the Milwaukee brace to be effective in halting the progression of the primary curvature at the termination of treatment.

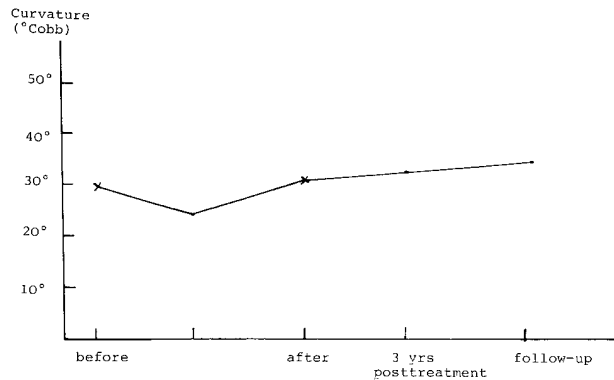


Fig. 4. — Evaluation of Milwaukee brace treatment of adolescent idiopathic scoliosis : stabilization of primary curvature at treatment termination (Cochran and Nachemson [8]).

In a second study dealing with a Milwaukee or Boston brace program for progressive idiopathic scoliosis, Miller, Nachemson and Schultz (15) observed a stabilization or regression of the primary curvature in 61.8% and 20.9% respectively, and a progression in 17.3% of the cases.

Using the chi-square test, we found no statistical difference between their results and ours.

Table IV. — Comparison between TCES and bracing : populations treated

	N	Age	Menarche		Curvature				Followup
			Age	%	Amp ° Cobb	Loc % Th L ThL			
TCES*	30	14 yrs 1 mo (20 mos)	14 yrs (20 mos)	63.3	30°	60	33.3	6.7	12 mos (9 mos)
Bracing** (Milwaukee- Boston) Miller <i>et al.</i> (15)	173	14.1 yrs (1.8 yrs)	12.9 yrs (1.1 yrs)		24.4 (4.8)	70	30	—	3.5 yrs (1.5 yrs)

* median values (interquartile range)

** mean values (standard deviation).

Moreover, a comparison of the populations treated (table IV) revealed that the median curvature in their group of patients (24.4°) was smaller than in our population (30°).

Furthermore, Miller *et al.* conducted a retrospective study of patients who completed a brace program, which implies that brace patients who ultimately required surgery were not considered in the results. In our study however, treatment failures who later underwent posterior fusion were included.

In conclusion it can be stated that the results of TCES treatment are comparable to outcomes of brace patients, although reliable data on maintenance of correction after completion of TCES are not available as yet. We have in fact compared our preliminary results obtained in the course of TCES with those achieved in patients having completed a brace program.

DISCUSSION

The results obtained in this preliminary study are comparable to those of other long-term follow-up studies (table I) and similar to the outcome of brace patients.

Therefore we feel that TCES is a valuable conservative treatment for progressive idiopathic scoliosis. Moreover, the efficacy of orthopedic bracing has not been substantiated by double-blind studies. The only major complication was contact eczema requiring cessation of treatment in 4 patients.

Otherwise, TCES was well tolerated. Sleep disturbances and stimulus intolerance were not observed. However, 3 patients refused further TCES treatment which proves that compliance is not as good as anticipated, although several studies (10, 12, 13) have shown that TCES is physically and psychologically more acceptable to the patient than bracing and that TCES patients are more compliant with the treatment.

CONCLUSION

We find that TCES deserves a place in the therapeutic arsenal of progressive idiopathic scoliosis. It is a valuable alternative to a brace, while the treatment indications are the same.

Admittedly, the true efficacy of TCES must await further controlled double-blind studies, but the ethical problems associated with such studies are substantial.

REFERENCES

1. ALTEKRUSE F., HEINE J. Erfahrungen mit der lateralen elektrischen Oberflächenstimulation bei der Behandlung der progredienten idiopathischen Skoliose. *Z. Orthop.*, 1985, 123, 338-346.
2. AXELGAARD J., BROWN J. C. Lateral electrical surface stimulation for the treatment of progressive idiopathic scoliosis. *Spine*, 1983, 8, 242-260.
3. AXELGAARD J., NORDWALL A., BROWN J. C. Correction of spinal curvatures by transcutaneous electrical muscle stimulation. *Spine*, 1983, 9, 463-481.

4. AXELGAARD J. Transcutaneous electrical muscle stimulation for the treatment of progressive spinal curvature deformities. *Int. Rehab. Med.*, 1984, 6, 31-46.
5. AXELGAARD J., BROWN J. C., SWANK S. M. Transcutaneous electrical stimulation in the treatment of scoliosis and kyphosis. *Acta Orthop. Yugosl.*, 1984, 15 (supplement), 46-50.
6. BRADFORD D. S., TANGUY A., VANSELOW J. Surface electrical stimulation in the treatment of idiopathic scoliosis : preliminary results in 30 patients. *Spine*, 1983, 8, 757-764.
7. BROWN J. C., AXELGAARD J., HOWSON D. C. Multicenter trial of a non-invasive stimulation method for idiopathic scoliosis. *Spine*, 1984, 9, 382-387.
8. COCHRAN T., NACHEMSON A. Long-term anatomic and functional changes in patients with adolescent idiopathic scoliosis treated with the Milwaukee brace. *Spine*, 1985, 10, 127-133.
9. DE MAUROY J. C., STAGNARA P. Stimulation électrique nocturne transcutanée des scolioses. *Ann. Réadapt. Méd. Phys.*, 1985, 27, 225-232.
10. ECKERSON L. F., AXELGAARD J. Lateral electric surface stimulation as an alternative to bracing in the treatment of idiopathic scoliosis : treatment protocol and patient acceptance. *Physical Therapy*, 1984, 64, 483-490.
11. HEINE J. Erwiderung zu der Stellungnahme von K. Zielke zu unserem Beitrag : Erfahrungen mit der lateralen elektrischen Oberflächenstimulation bei der Behandlung der progedienten idiopathischen Skoliose. *Z. Orthop.*, 1986, 124, 319-322.
12. KAHANOVITZ N., SNOW B., PINTER I. The comparative results of psychologic testing in scoliosis patients treated with electrical stimulation or bracing. *Spine*, 1984, 9, 442-444.
13. KAHANOVITZ N., WEISER S. Lateral electrical surface stimulation compliance in adolescent female scoliosis patients. *Spine*, 1986, 11, 753-755.
14. MCCOLLOUGH N. C. Non-operative treatment of idiopathic scoliosis using surface electrical stimulation. *Spine*, 1986, 11, 802-804.
15. MILLER J. A. A., NACHEMSON A. L., SCHULTZ A. B. Effectiveness of braces in mild idiopathic scoliosis. *Spine*, 1984, 9, 632-635.
16. SULLIVAN J. A., DAVIDSON R., RENSHAW T. S., EMANS J. B., JOHNSTON C. H., SUSSMAN M. Further evaluation of the scolitron treatment of idiopathic adolescent scoliosis. *Spine*, 1986, 11, 903-906.
17. ZIELKE K. Stellungnahme zu dem Beitrag : Erfahrungen mit den lateralen elektrischen Oberflächenstimulation bei der Behandlung der progedienten idiopathischen Skoliose (J. Heine. *Z. Orthop.*, 1985, 123, 338-346). *Z. Orthop.*, 1986, 124, 313-318.

M. ANCIAUX

Department of Orthopedic Surgery
and Physical Medicine
Ghent University Hospital
De Pintelaan 185
B-9000 Ghent (Belgium)