

THE GEOMEDIC KNEE PROSTHESIS A LONG-TERM FOLLOW-UP STUDY

C. J. M. VAN LOON¹, H. P. HU¹, J. R. VAN HORN², M. C. DE WAAL MALEFIJT¹

A retrospective long-term follow-up study of 189 Geomedic total knee arthroplasties in 143 patients was performed. One hundred and eighteen knees were replaced in patients with rheumatoid arthritis and seventy-one knees were replaced in patients with osteoarthritis. Fifty-seven knees were examined clinically with an average follow-up of 11 years. Seventy percent of these knees were painless. Lucent lines at the tibial bone-cement interface were observed in 62% of the follow-up radiographs (81 knees, mean follow-up : 10.5 years). Thirty-four prostheses (18%) were removed, with loosening of the tibial component as the main cause. Retropatellar pain was not a significant problem. The 13-year survival rate was 78%, with implant removal as an endpoint. Radiographically loosened components included, the 13-year survival rate was 58%.

Keywords : geomedic knee prosthesis ; total knee arthroplasty.

Mots-clés : prothèse de genou géométrique ; arthroplastie totale du genou.

INTRODUCTION

The Geomedic knee prosthesis was introduced in 1972 by Coventry *et al.* (1). It was a first generation, semiconstrained, nonhinged knee prosthesis, without a patellar button. As a result of the difference in shape and diameter between the tibial and femoral components, flexion-extension and some rotational movements were possible (2). The design permitted retention of the cruciate and collateral ligaments (1). Nowadays the Geomedic prosthesis is no longer in use, but it was a fairly common prosthesis in the 1970's.

The purpose of this study is to evaluate the long-term clinical and radiographic results of the Geomedic knee prosthesis. Revision and prosthesis survival are discussed and compared with previous studies.

PATIENTS AND METHODS

From May 1973 through April 1982, 189 Geomedic total knee arthroplasties (TKA) were performed in 143 patients (122 female and 21 male) at the St. Radboud Hospital Nijmegen, all operated by the same technique described by Coventry *et al.* (1, 2). The indication for surgery was rheumatoid arthritis (RA) in 118 cases (82 patients) and osteoarthritis (OA) in 71 cases (61 patients). At the time of operation, the average age of the RA-patients was 58 years (range : 22-78 years) and of the OA-patients 64 years (range : 22-83 years).

In 19 knees the posterior cruciate ligament was not present or was removed. In 17 cases both cruciate ligaments were absent or were not retained.

Questionnaires were sent to the family doctors in order to trace the patients. It appeared that 45 patients (62 knees) had died, 11 patients (22 knees) could not be traced, and 7 patients (14 knees) were unable to travel because of poor physical condition. Thirty-four knees in 33 patients were reoperated for prosthesis removal (28 were revised to another TKA, and 6 had an arthrodesis).

¹ Institute of Orthopedic Surgery, St Radboud Hospital, University of Nijmegen, The Netherlands.

² Medisch Spectrum Twente, Enschede, The Netherlands.

Correspondence and reprints : C. J. M. van Loon, Multatuliplaats 19A, 6531 Nijmegen, The Netherlands.

Fifty-seven knees (47 patients) were available for follow-up examination with a mean follow-up period of 11.3 years (range : 7-14.7 years). The Knee Society clinical rating system (6) was used for the clinical evaluation score.

Eighty-one of the 189 cases, which had a follow-up period for radiographs of at least 7 years, were included in the radiographic study. These cases included all 57 knees that were clinically evaluated. The follow-up averaged 10.5 years (range : 7-14.7 years). For the other cases the radiographs were lost or destroyed, or the follow-up period for radiographs was less than 7 years.

The postoperative radiographs were compared with the last radiographs available. The position of the components was determined in the postoperative radiographs and compared with the position in the last xray available. Radiolucent lines at the tibial bone-cement interface were graded from 1 to 4, with grade 1 implying a radiolucent line involving 25% of the interface, grade 2 : 50% and grade 3 : 75% of the interface. Grade 4 was rated when circumferential radiolucency was recorded. The width of radiolucent zones could not be recorded properly. Evaluation of the femoral bone-cement interface was not possible, because of overprojection of the metallic femoral component. A loosened component was defined as the presence of fracture of bone, component breakage, collapse of the component or other significant change in component position, developing over time.

All 189 knees were included in the survival analysis. Prosthesis survival was estimated by means of the actuarial method. Two analyses were performed ; one with implant removal as an endpoint. In the other, the endpoint was implant removal or a radiographically loosened component without removal. For the patients who could not be traced, the most recent follow-up date was used as a statistical endpoint.

RESULTS

Complications

The following medical complications each occurred in one patient : deep vein thrombosis, pulmonary embolus, pneumonia and hematemesis. Forty-two operative complications developed : Decreased range of motion necessitating manipulation under general anesthesia in 19 ; Febris ECI in 13 ; peroneal nerve palsy in 5 ; delayed wound healing in 3 and wound hematoma in 2.

Clinical results

At follow-up the average knee score was 84 for RA- and 88 for OA-knees. The results are shown in table I. The average range of motion was 100° (range : 65-140°) in both groups of knees. Flexion contracture greater than 10° was present in 4 knees (7%), all of which were in RA-patients. Fifteen knees (26%) caused mild pain on climbing stairs, and 2 knees (4%) caused considerable pain occasionally. The other 40 knees (70%) were free of pain. Eighteen patients (32%) experienced patellofemoral discomfort on manual compression. Nine knees (16%) had an anterior/posterior instability of 5-10 mm. All the other knees showed less instability in the anterior/posterior direction. The mediolateral instability was 0-5° in 39 knees (68%), 6-9° in 13 knees (23%), 10° or more in 5 knees (9%).

Table I. — Knee score of 57 knees (47 patients) with a Geomedic knee prosthesis at follow-up
The knees were scored according to the Knee Society clinical rating system

	RA (n = 28)	OA (n = 29)
	mean (range)	mean (range)
Knee score	84 (57-100)	88 (62-99)
Functional score	39 (0-100)	57 (0-100)

The functional scores were considerably lower (table I). Eleven patients (13 knees = 23%) could walk without limitation, while 4 patients (6 knees = 11%) were completely unable to walk. Nine patients with RA (13 knees = 46% of the RA knees) were unable to climb stairs, versus 3 patients with OA (4 knees = 14% of the OA knees). Only 12 patients (14 knees = 25%) were able to climb stairs without the use of the ban-nister. Twenty-nine patients (51%) were able to walk without the use of a cane, crutches or a walker.

Radiographic results

Immediately postoperatively, the femoral component showed a valgus position of more than

10° in 2 knees (2%). At follow-up, none of the femoral components had a changed position. Two knees (2%) showed signs of severe osteolysis around the femoral component at the time of follow-up. Fractures of the femoral condyles were not recorded.

A postoperative valgus/varus position of the tibial component of more than 5° was seen in 5 knees (6%), while 13 tibial components (16%) were noted to be in an anterior/posterior tilt position of more than 5°. A combination of the latter two positions was observed in 2 knees (2%). Seventy-five percent of the knees showed an optimal postoperative position of the tibial component. A changed position of the tibial component at the time of follow-up was noted in 11 knees: Medial collapse in 5; posterior collapse in 1; anterior collapse in 1; complete collapse in 1; other in 3. In these 11 knees (14%), the tibial component was judged as loosened. Breakage of the tibial component or fracture of the tibial condyle did not occur. Radiolucent zones around the tibial component were present in 50 knees (62%) at the last follow-up radiographs (grade 1: 12%; grade 2: 20%; grade 3: 16% and grade 4: 14%).

Osteoarthritis of the patellofemoral joint was marked mild in 9 knees (11%), moderate in 22

knees (27%) and severe in 48 knees (59%) in follow-up radiographs.

Revision

Of the total of 189 Geomedic TKAs, 34 prostheses (18%) in 33 patients were removed: Twenty-eight knees were revised to another knee arthroplasty (10 to a GSB, 9 to a Guepar, 5 to another Geomedic and 4 to a Kinematic prosthesis), and 6 had an arthrodesis. The average time to removal was 4.2 years (range: 0.2-12 years). Eighteen prostheses (15%) were removed in patients with RA and for the OA-patients this number was sixteen (23%). The main reasons for removal of the prosthesis are presented in table II. Five cases of deep infection led to removal of the prosthesis. Three infections occurred within 6 months, 1 after 3 years and another after 10 years.

Survival analysis

The 13-year survival rate with implant removal as an endpoint was 78%. Radiographically-loosened components included, the survival rate was 58% at 13 years. The results are shown in fig. 1.

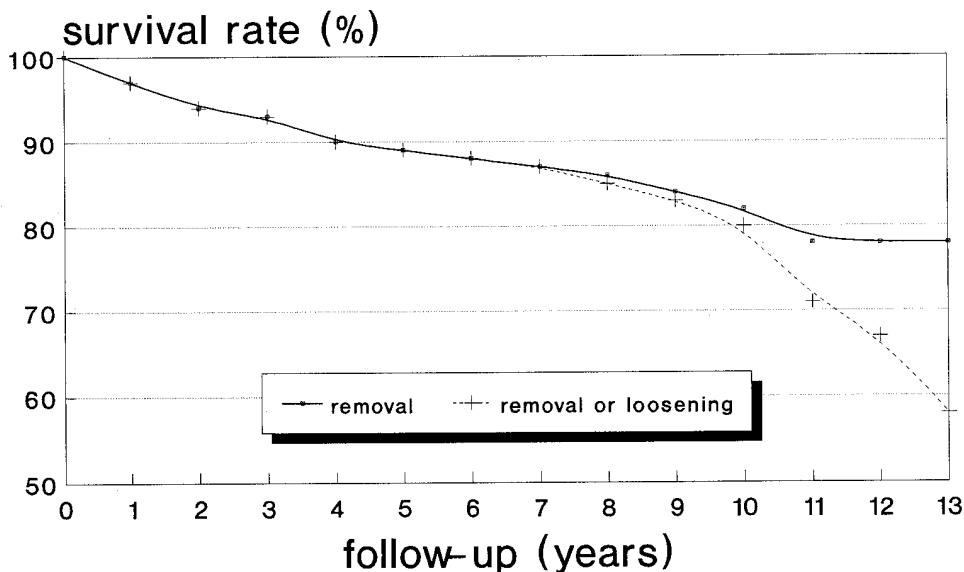


Fig. 1. — Survival analysis of 189 Geomedic knee prostheses (143 patients).

Table II. — Analysis of the main reasons for removal of 34 Geomedic knee prostheses (33 patients) Some prostheses were removed for more than one reason

Main reason for removal of the TKA	number
Loosening of the tibial component	13
Loosening of the femoral component	2
Loosening of both components	3
Retropatellar pain	3
Persistent pain of unknown origin	5
Deep infection	5
Instability	3
Total	34

DISCUSSION

In our study 189 TKA's were evaluated. The average follow-up period for clinical evaluation was 11 years. Three other long-term follow-up studies of the Geomedic knee prosthesis were found in the literature. Riley (10) reviewed 51 TKA's with a mean follow-up of 7 years, while Riley and Woodyard (9) reported a study of 71 Geomedic prostheses, with a follow-up period up to a maximum of 8.5 years. The study of Rand and Coventry (8), in which they reviewed 193 TKAs, is the only study with a similar mean follow-up period as in our series. Although, in our study, many patients had died and some were lost to follow-up, lessons can be learned from this study of a first generation knee prosthesis.

We found a relatively high knee score, with 40 painless knees (70%) and an average range of motion of 100°. The average functional score, however, was low, especially in the patients with RA. This group of patients had reduced walking and stair climbing ability, due to RA with multiple joints involved.

The overall revision rate was 18%, which is comparable to the failure rate found by Riley and Woodyard (9). The failures in their study included patients with severe pain, attributable to the implant. Rand and Coventry (8) reported a 20% revision rate, but their study only included patients with OA. The revision rate in patients with OA in our study was 23%. These patients are more mobile and tend to stress the knee more, while

patients with RA are often limited in their activities. Other authors also found higher failure rates among patients with OA (5, 3).

In our study, the most common cause for implant removal was loosening of the tibial component (7%). In an additional 8 cases, the tibial component was radiographically judged as loosened. However, these patients were not reoperated, either because their poor physical condition did not permit another operation or because they were satisfied with their present status.

The presence of radiolucent zones around the tibial component in 62% of the knees was considerable. Torisu and Morita (12) reported radiolucent zones in 81% of 56 geometric prostheses with an average follow-up period of 6 years and 7 months.

Other authors found similar results regarding loosening of the tibial component (2, 5, 11, 3, 13, 10, 9, 8). This can be explained by the biomechanical characteristics of the Geomedic knee prosthesis. Lew and Lewis (7) found that large tension forces, up to 4 times normal, develop in the posterior cruciate ligament during flexion beyond 60°. In addition, the anterior part of the tibial component tends to tilt upward.

Retropatellar pain was the main cause for removal of the prosthesis in 3 cases. Eighteen of the knees examined clinically (32%) showed patellofemoral discomfort on manual compression, however other activities did not cause any pain in many of these knees. Patellofemoral osteoarthritis was present in 97% of all knees that were radiographically examined, which is similar to the results of the study by Torisu and Morita (12). It appears that the long-term results were not affected by progressive degeneration of the patellofemoral joint or the absence of a patellar button. Similar findings have been reported previously (4, 12, 13).

The 13-year survival rate of 78%, with implant removal as an endpoint, was comparable to the results found by Rand and Coventry (8). The survival rate at 13 years with implant removal or a radiographically loosened tibial component as an endpoint was 58%. This suggests that the actual probability of retaining a nonloosened Geomedic prosthesis beyond 10 years is considerably lower.

The long-term clinical and radiographic results imply that, even though the design's biomechanical characteristics were not ideal, the Geomedic knee prosthesis was an acceptable treatment for patients with rheumatoid arthritis or osteoarthritis of the knee joint. Since loosening of the tibial component is the main reason for revision, new designs are directed at better fixation of the tibial component.

Acknowledgement

The authors wish to thank A. Nooitgedagt, M.D., Ir. H. Peeters, and R. H. Jansen, M.D.

REFERENCES

1. Coventry M. B., Finerman G. A. M., Riley L. H., Turner R. H., Upshaw J. E. A new geometric knee for total knee arthroplasty. *Clin. Orthop.*, 1972, 83, 157-162.
2. Coventry M. B., Upshaw J. E., Riley L. H., Finerman G. A. M., Turner R. H. Geometric total knee arthroplasty, I. Conception, design, indications and surgical technique II. Patient data and complications. *Clin. Orthop.*, 1973, 94, 171-184.
3. Cracchiolo A., Benson M., Finerman G. A., Horacek K., Amstutz H. C. A prospective comparative clinical analysis of the first-generation knee replacements: polycentric vs. geometric knee arthroplasty. *Clin. Orthop.*, 1979, 145, 37-46.
4. Hunter J. A., Zoma A. A., Scullion J. E., Protheroe K., Young A. B., Sturrock R. D., Capell H. A. The geometric knee replacement in polyarthritis. *J. Bone Joint Surg.*, 1982, 64-B, 95-98.
5. Ilstrup D. M., Coventry M. B., Skolnick M. D. A statistical evaluation of geometric total knee arthroplasties. *Clin. Orthop.*, 1976, 120, 27-32.
6. Insall J. N., Dorr L. D., Scott R. D., Scott W. N. Rationale of the Knee Society clinical rating system. *Clin. Orthop.*, 1989, 248, 13-14.
7. Lew W. D., Lewis J. L. The effect of knee-prosthesis geometry on cruciate ligament mechanics during flexion. *J. Bone Joint Surg.*, 1982, 64-A, 734-739.
8. Rand J. A., Coventry M. B. Ten-year evaluation of geometric total knee arthroplasty. *Clin. Orthop.*, 1988, 232, 168-173.
9. Riley D., Woodyard J. E. Long-term results of Geomedic total knee replacement. *J. Bone Joint Surg.*, 1985, 67-B, 548-550.
10. Riley L. H. Jr. Total knee arthroplasty. *Clin. Orthop.*, 1985, 192, 34-39.
11. Skolnick M. D., Coventry M. B., Ilstrup D. M. Geometric total knee arthroplasty. *J. Bone Joint Surg.*, 1976, 58-A, 749-753.
12. Torisu T., Morita H. Roentgenographic evaluation of geometric total knee arthroplasty with a six-year average follow-up period. *Clin. Orthop.*, 1986, 202, 125-134.
13. Wilson F. C., Fajgenbaum D. M., Venters G. C. Results of knee replacement with the Walldius and geometric prostheses. A comparative study. *J. Bone Joint Surg.*, 1980, 62-A, 497-503.

SAMENVATTING

C. J. M. VAN LOON, H. P. HU, J. R. VAN HORN en M. C. DE WAAL MALEFIJT. De Geomedic knie arthroplastiek.

Honderd negenentachtig Geomedic total knee arthroplastieën werden retrospectief op lange termijn resultaten geëvalueerd bij 143 patiënten. Honderd achttien prothesen waren geplaatst bij patiënten met reumatoïde arthritis en 71 bij patiënten met gonarthrosis. Zevenenvijftig knieën, met een gemiddelde follow-up periode van 11 jaar, werden klinisch onderzocht. Zeventig procent van de knieën was pijnvrij. In 62 procent van de follow-up röntgenfoto's (81 knieën, gemiddelde follow-up periode: 10,5 jaar) waren radiolucente lijnen op het tibiale bot-cement scheidingsvlak aanwezig. Vierendertig prothesen (18%) werden verwijderd, met loslating van de tibiale component als belangrijkste oorzaak. Retropatellaire pijn was geen significant probleem. De 13 jaar survival rate was 78% met implantaat verwijdering als eindpunt. Met inbegrip van radiografisch losgelaten componenten was de 13 jaar survival rate 58%.

RÉSUMÉ

C. J. M. VAN LOON, H. P. HU, J. R. VAN HORN et M. C. DE WAAL MALEFIJT. La prothèse de genou Géométrique. Revue des résultats à long terme.

Cent quatre-vingt neuf prothèses de genou Géométriques, chez 143 malades, furent réévaluées à long terme. Pour 118 prothèses, l'indication était une arthrite rhumatoïde et pour 71, une gonarthrose. Septante-cinq genoux, avec un recul moyen de 11 ans, furent examinés cliniquement. Septante % des genoux étaient indolores. Sur 62% des radiographies à long terme (81 genoux, recul moyen de 10,5 ans), un liséré radiotransparent était visible à l'interface ciment-os du tibia. On note trente-quatre (18%) ablations de prothèse pour descellement important du composant tibial. La douleur rétropatellaire ne fut jamais importante: la survie moyenne de 13 ans représente 78% des prothèses qui furent finalement être enlevées. Si l'on inclut les descellements constatés radiologiquement, la survie de 13 ans représente 58%.