

THE APPLICATION OF MODERN IMAGING METHODS IN ORTHOPEDIC SURGERY

W. H. M. CASTRO, J. JEROSCH, M. SCHILGEN, W. WINKELMANN

In this paper the application of ultrasonography, computed tomography, magnetic resonance imaging and bone scintigraphy in the diagnosis of orthopedic diseases is discussed. Because of the advances in the diagnosis made possible by these investigations, diagnosis is often made earlier with the consequence that therapeutic modalities can be used in a better way. As a result, late complications of orthopedic diseases can be influenced in a positive way.

Keywords : ultrasonography ; computed tomography ; magnetic resonance imaging ; bone scintigraphy.

Mots-clés : échographie ; tomodensitométrie ; résonance magnétique nucléaire ; scintigraphie osseuse.

INTRODUCTION

Imaging modalities play an important role in the diagnosis and documentation of orthopedic diseases. For routine diagnosis of diseases of soft tissues and bony structures conventional radiology is almost always satisfactory. Concomitant examinations like ultrasonography, computed tomography, magnetic resonance imaging (MRI), and new techniques in nuclear medicine make it possible to achieve a diagnosis at an earlier stage. As a consequence, the therapy starts sooner and later complications of the diseases can be avoided in some instances.

Using mainly our own clinical material, we document the value of several modern imaging techniques in orthopedic diagnoses.

ULTRASONOGRAPHY

Ultrasonography is an established standard technique in the diagnosis of hip dysplasia and congenital hip dislocation. Results of the clinical examination of neonatal hip stability by the so-called Ortolani test are difficult to reproduce because of the high interobserver variance. In contrast, with ultrasonography the position of the femoral head can be demonstrated and stability can be documented. Also, in contrast to x ray examination, the cartilage structures important for the development of the hip joint can be visualized. Our investigation included 1369 neonates with a total of 4341 sonographic examinations of the hip joint. We have found that in comparison to the 1970's, the age in which therapy was started for congenital hip dysplasia decreased by 50%, to 14 weeks. This is in accordance with the literature (8, 16). As a result of this decrease the results of treatment improved. However, at the end of therapy a radiological examination is still recommended, because the increasing ossification of the femoral head makes sonographic imaging of the acetabulum impossible when the child is about one year of age. This x ray can also be used as a comparison for further x rays at a later age.

Orthopedic Department, Westfälische Wilhelms-Universität Münster, Albert Schweitzer-Strasse 33, D-48129 Münster (Germany).

Correspondence and reprints : W. Winkelmann.

In the diagnosis of knee problems, ultrasonography readily demonstrates Baker cysts, bursitis, meniscal cysts and intraarticular effusions. Much more difficult is the demonstration of the menisci and the cruciate ligaments. In a prospective study (10) the value of ultrasonography to detect meniscal lesions was assessed. The gold standard in this study was arthroscopy. For medial meniscal lesions sensitivity was 88%, specificity 93%, accuracy 83% and positive predictive value 91% (fig. 1). For lesions of the lateral meniscus the results were significantly inferior: sensitivity 50%, specificity 97%, accuracy 89% and positive predictive value 22%. None of the ruptured cruciate ligaments could be detected preoperatively by ultrasonography. In shoulder diseases the value of ultrasonography is enormous. The soft tissues covering the skeletal parts of the shoulder joint can be visualized very clearly (2). Acute bursitis and full thickness and partial thickness ruptures of the rotator cuff can be detected with a high diagnostic value. Ultrasonography is also very important for the examination of the unstable shoulder joint (11). Differentiation between anterior, posterior and multidirectional instabilities is possible using ultrasonography. Also secondary signs of shoulder instability, such as Hill-Sachs lesions and posttraumatic joint effusions can be documented.

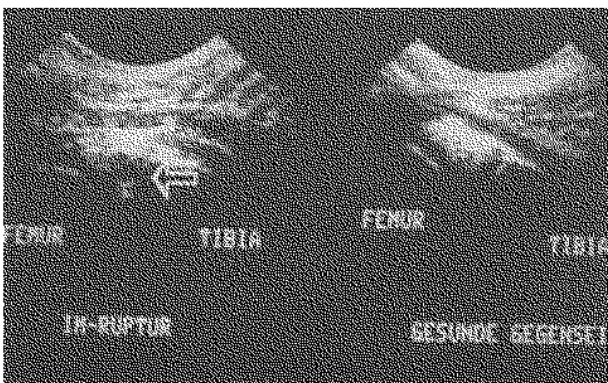


Fig. 1. — Ultrasonographic image of a lesion of the medial meniscus. The dark area in the echogenic structure (white arrow) represents the rupture. The lesion was confirmed arthroscopically.

COMPUTED TOMOGRAPHY

Computed tomography can demonstrate any part of the body in cross section. The difference of contrast resolution between physiologic and pathologic parts of tissue can be intensified by different 'tissue windows' and/or by intravenous, intraspinal, intraarticular or intradiscal use of a contrast medium. By measurement of the tissue density (in Hounsfield units) the course of histologic changes (e.g. during therapy) can be documented. In the diagnosis of osteoporosis computed tomography is also of value. Changes in parts of the body difficult to observe, such as the upper cervical spine or the pelvis, can be spatially demonstrated. In spinal fractures computed tomography visualizes very clearly bone fragments which compress the neural structures. Three-dimensional reconstruction of osseous tissue is now possible, which is a great improvement for preoperative planning, especially in tumor surgery.

When conservative therapy has failed in patients with herniated discs, besides conventional open surgery, treatment with several percutaneous modalities such as automated or non-automated percutaneous discectomy, chemonucleolysis or laser therapy is possible. An exact differentiation of the herniated disc is mandatory before the treatment of choice is selected. With CT-discography such an exact differentiation is possible. After injecting the dye into the center of the disc several discographic patterns can be documented, and reproduction of pain can also be evaluated. Afterwards the computed tomography shows the distribution of the dye inside the herniated disc. Physiologic and various pathologic disc patterns can be defined. Schulitz and coworkers (14) showed that the sensitivity, specificity and positive predictive value of CT-discography for the diagnosis of herniated discs is higher than those of magnetic resonance imaging. In a prospective study (4) we found that the use of the automated percutaneous lumbar discectomy (APLD) based on CT-discography has certain restrictions. The success rate in patients with a disc protrusion seen on CT-discography with a broad dye base (like a 'pear'; fig. 2a) was 80%. When a narrow dye base disc protrusion (like an 'hour glass'; fig. 2b)

was treated with the APLD-method the outcome was significantly less favorable.

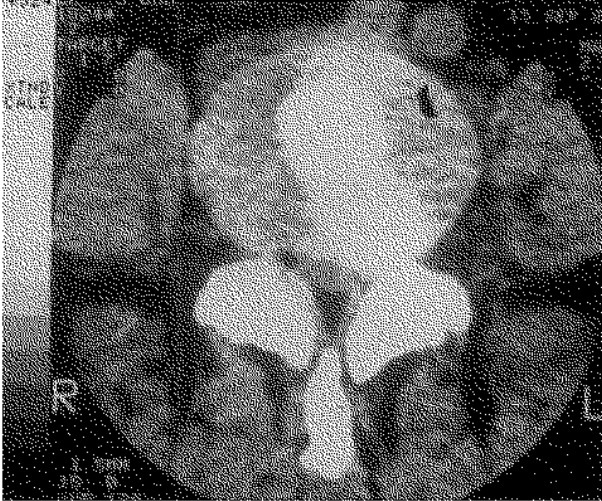


Fig. 2a

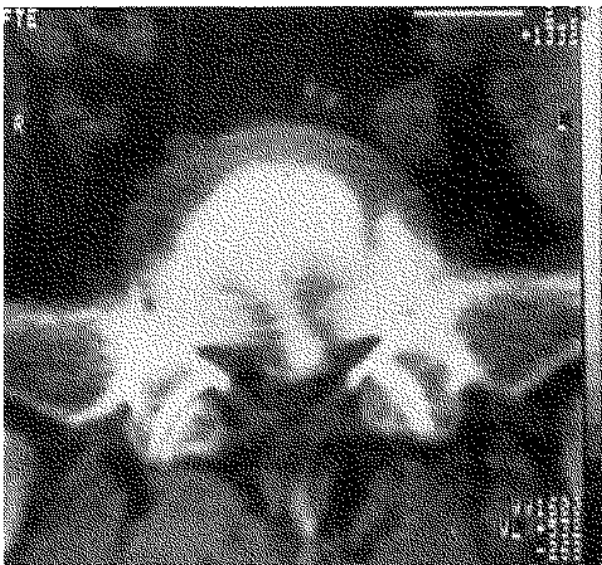

Fig. 2b

Fig. 2a and b. — Fig. 2a (left): CT-discography of a disc protrusion with a broad dye base (like a 'pear'); Fig. 2b (right) shows CT-discography of a disc protrusion with a narrow dye base (like an 'hour glass') (with permission 'Ned. Tijdsche Geneeskd').

MAGNETIC RESONANCE IMAGING

Among imaging modalities magnetic resonance imaging (MRI) is certainly the greatest invention

since x rays were developed. By MRI every region of the body can be visualized in different sections or even 3-dimensionally in a noninvasive way and without radiation exposure. By special application techniques (different sequences) the contrast between healthy and pathologic tissue is visible in most cases.

Especially for diagnosis and treatment planning of tumors of soft tissues and bone MRI is most efficient. The boundary between the tumor tissue and the surrounding edema can be demonstrated, and tumor size and extension in bone and soft tissues can be determined. The soft tissue contrast is about 10 times higher than that of computed tomography. Due to the high sensitivity to any tissue alteration MRI is obligatory before biopsy of a tumor. Biopsy inevitably causes environmental tissue changes making the determination of the original tumor margins impossible. Due to additional-intravenous application of the paramagnetic substance gadolinium (Gd-DTPA) as 'MR contrast medium' and the following time-dependent change in signal intensity some conclusions as to the malignancy of the tumor can be made (7). However, experience in this technique is limited. Therefore, radiography, the method of choice for decades, is still fundamental, particularly with respect to classification of the tumor.

In using MRI for inflammatory bone and joint diseases one should always compare the results with those of other noninvasive methods (e.g. scintigraphy). MRI has a higher sensitivity for changes in the bone marrow, and periosteal edema and other accumulations of fluid give off a higher signal intensity than the surrounding structures. Also the internal articular structures, especially cartilage, are clearly delineated (13).

In the diagnosis of the early stages of ischemic bone necrosis MRI visualizes changes which radiographically are not recognized. In the later stages the 3-dimensional reconstruction allows a better documentation of the extension of the bone defect. As a result operative therapy can be better planned.

MRI is important for the treatment of osteochondrosis dissecans, because of its good visualization of the joint cartilage. The stage of the disease as well as the loosening of the cartilage can be documented clearly (5). As a consequence

the therapy can be adapted to these changes (figs. 3a and b).

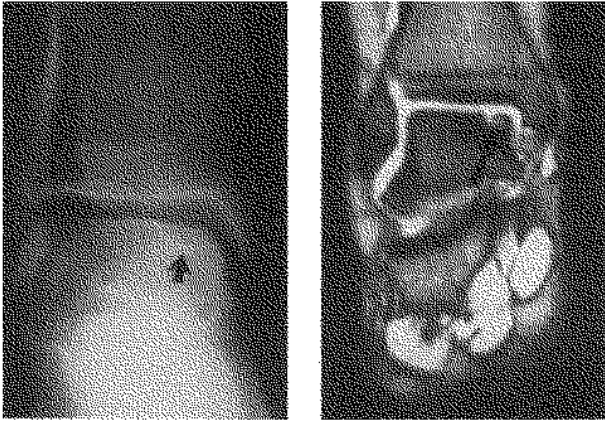


Fig. 3a

Fig. 3b

Fig. 3a and b. — Left (Fig. 3a) x ray of an osteochondrosis dissecans lesion at the medial talus (black arrow). Right (Fig. 3b), the MR-image (STIR : sequence ; TR 1600 msec/ TE 110 msec). The extension of the bone lesion can be very clearly demonstrated with MRI.

In a prospective study (6) the value of MRI in the diagnosis of 53 patients with disorders of the knee was determined. Arthroscopy was the gold standard. The most striking result was the high negative predictive value for meniscal tears as well as for cruciate ligament lesions (96% and 92%). This means that if MRI shows no abnormalities it is very likely that the patient indeed has no disorder of the affected knee. As a consequence, the number of diagnostic arthroscopies may be reduced.

In the shoulder joint the statistical data for ruptures of the rotator cuff (fig. 4) are high : sensitivity 95%, specificity 91% and accuracy 93% (9). In the unstable shoulder joint MRI gives a perfect visualization of the important anterior labrum-capsule complex.

MRI is a very useful modality in the diagnosis of degenerative and inflammatory spinal disorders. Also the extent of malignant tumors can be demonstrated very accurately by this technique, and infiltration in dural and neural structures can be defined. In failed back surgery patients MRI is helpful for the differentiation between recurrent

herniated disc and scar tissue with or without retraction of the dural structures (fig. 5a, b, c). Our own data not yet published showed that in 90.5% of patients with a failed back surgery syndrome the MRI findings were in agreement with the findings at surgery.

In conclusion, for many orthopedic problems MRI increases the efficiency of diagnosis and as a consequence optimizes therapy.

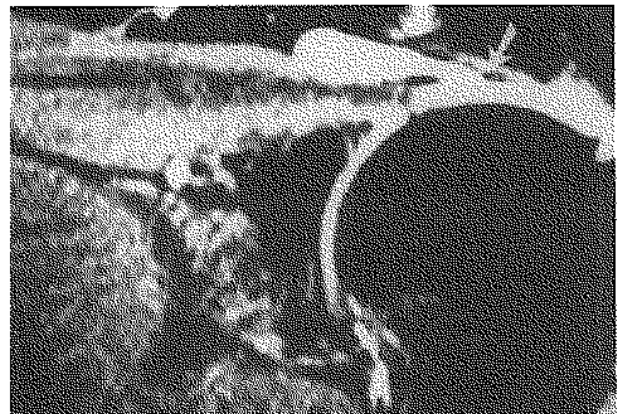


Fig. 4. — MR-image of the shoulder joint (frontal plane ; STR sequence ; TR 1600 msec/ TE 110 msec). A lesion of the rotator cuff is demonstrated. At the level of the rupture, synovial fluid leaves the joint space (white arrow).

BONE SCINTIGRAPHY

Although this diagnostic modality is rather nonspecific it is still one of the most important imaging procedures in orthopedic surgery. The uptake of the radionuclide in bone is related to the bone metabolism and blood supply. Any disturbance of normal bone metabolism is reflected as increased or decreased activity.

Nowadays for routine procedures the radionuclide technetium-99m is used, and in cases of inflammatory disorders of the bone, gallium-67-citrate and indium-111-ocine. The activity of the affected part of the body is usually demonstrated from anterior to posterior by multistage scintigraphy. A tomographic presentation is also possible by means of a rotating gamma camera (SPECT = single photon emission computed tomography).

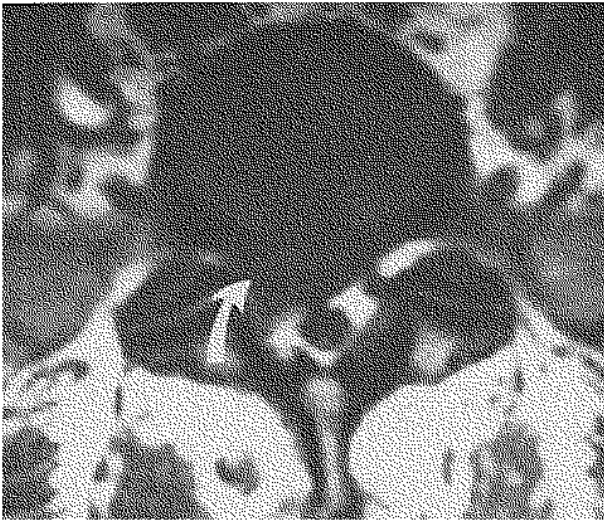


Fig. 5a

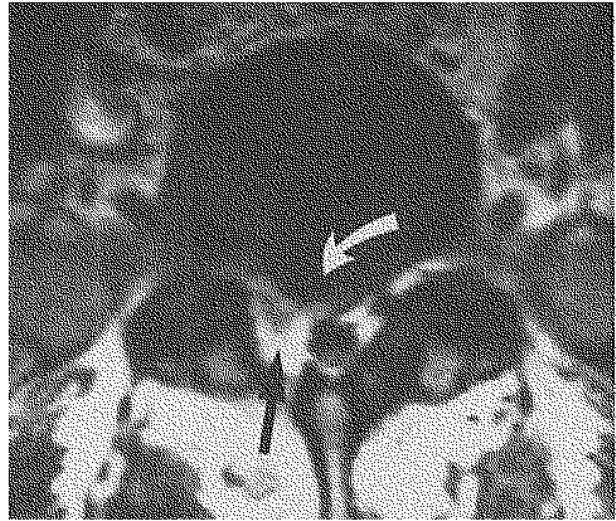


Fig. 5b

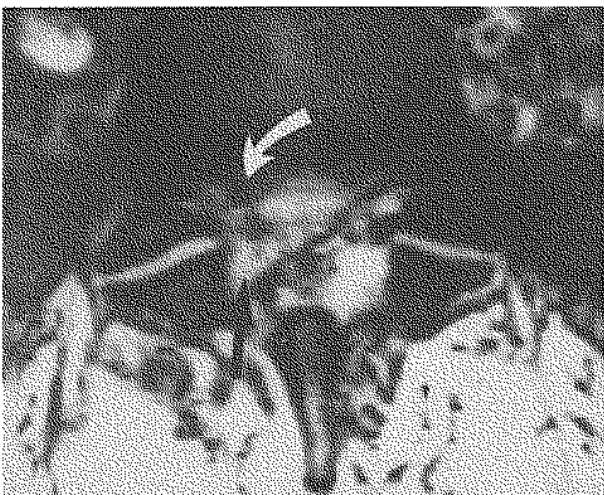


Fig. 5c

Fig. 5a, b and c. — Three MR-images of the same segment of the lumbar spine. Only the sequences are different.

Fig. 5a, T₁-weighted spin-echo sequence (SE ; TR 500 msec/TE 20 msec) demonstrates the condition after nucleotomy. Differentiation between the recurrent herniated disc and postoperative scar tissue (white arrow) is difficult.

Fig. 5b, T₁-weighted spin-echo sequence (SE ; TR 500 msec/TE 20 msec) after the administration of gadolinium-DTPA (Gd-DTPA) intravenously. The differentiation is easier : the white arrow shows a recurrent herniated disc and the black arrow indicates scar tissue. In this 58-year-old patient the diagnosis of a recurrent herniated disc with scar tissue was confirmed at surgery.

Fig. 5c, partial saturation with phase contrast (PS ; TR 500 msec/TE 10 msec), also shows this differentiation clearly (the white arrow shows recurrent herniated disc and the black arrow shows scar tissue).

In the prevention and early diagnosis of diseases of the locomotor apparatus bone scintigraphy is frequently indicated. Approximately 30% of the patients with skeletal metastases have pathologic scintigrams at a time when conventional x rays are still normal (fig. 5a, b, c). On the other hand however, it is typical of anaplastic tumors and multiple myeloma that due to absent osteoblastic activity even large osteolytic foci in bone are not demonstrated by scintigraphy.

Bone scintigraphy is excellent in the early diagnosis of ischemic bone necrosis such as Perthes

disease or adult femoral head necrosis (15). Loosening of implants (endoprostheses) are often demonstrated early by scintigraphy. However, differentiation between septic and aseptic loosening is not always possible even with gallium-67-citrate or indium-111-leucocyte scintigraphy. Bone scintigraphy can also be used in the early diagnosis and follow-up of various soft tissue disorders, particularly of ectopic soft tissue calcification (1).

The distinction between physiologic and pathologic activity only succeeds in osseous processes measuring more than 2 cm in diameter, particu-

larly in regions of high physiologic activity. In cases of solitary focal uptake without characteristic radiological findings benign and malignant bone tumors usually cannot be differentiated. Benign tumors naturally have less uptake than malignant tumors. Nevertheless, some benign types such as giant-cell tumors have as much uptake as malignant tumors because of their aggressive growth or because of an additional pathologic fracture (e.g. in juvenile bone cysts).

Early acute osteomyelitis may appear on the scintigram as a 'cold lesion' due to disturbed blood supply. The incidence of false-negative scintigrams is estimated at between 5% and 60%. Particularly in childhood, osteomyelitic processes often occur in the epi- or metaphyseal regions near the growth plates. The high physiologic activity in these regions masks decreased activity due to deficient blood supply. In these cases gallium-67 citrate, as is used in 'inflammation scintigraphy', is indicated (12, 17). Also chronic osteomyelitis can be detected by this procedure. In addition, gallium-67-citrate scintigraphy permits reliable therapeutic follow-up, e.g. of the response to antibiotic treatment in osteomyelitis. The value of leucocyte scintigraphy, on the other hand, decreases in relation to the chronicity of the inflammation.

Other indications for bone scintigraphy are stress fractures, the evaluation of fracture healing, metabolic bone disorders such as Sudeck's or Paget's disease and rheumatic diseases such as rheumatoid arthritis or ankylosing spondylitis.

CONCLUSION

In the past few years, the development of new imaging methods in orthopedic surgery has been tremendous. New and better techniques have improved the early detection of pathologic conditions. As a consequence the possibility to treat these disorders at an early stage has increased. Because of this, late complications can be avoided.

All of the above-mentioned imaging modalities are still in progress. New coil techniques for MRI, the development of magnetic resonance spectroscopy (MRS) and positron emission tomography (PET) are subjects of intense research and will

create new possibilities in improving the diagnosis of orthopedic diseases.

Acknowledgement

The authors thank Prof. A. J. van der Linden, Chairman of the Orthopedic Department, State University of Maastricht, the Netherlands, for his critical analysis of the manuscript.

LITERATURE

1. Alazraki N. P. Soft tissue localization of bone imaging radiopharmaceuticals. In: Siegel B. A., Nuclear Radiology Syllabus, American college of radiology, 1978.
2. Castro W. H. M., Jerosch J. Echografisch schouderonderzoek. Ned. Tijdsch. Geneesk., 1990, 134, 323-327.
3. Castro W. H. M., Schöppe K., Schulitz K. P. Percutane nucleotomie: indicatiestelling en voorlopige resultaten. Ned. Tijdsch. Geneesk., 1989, 133, 2611-2615.
4. Castro W. H. M., Jerosch J., Hepp R. et al. Restrictions for indication of automated percutaneous lumbar discectomy. (APLD) based on CT-discography. Spine, 1992, 17, 1239-1243.
5. Castro W. H. M., Jerosch J. De waarde van MRI bij de diagnostiek van osteochondritis dissecans. Presented at the autumn meeting of the 'Nederlandsche Orthopaedische Vereniging', Tilburg, 1989.
6. Castro W. H. M., Jerosch J., Assheuer J. Der Aussagewert der Computertomographie und Kernspintomographie bei der präoperativen Diagnostik von Meniskusläsionen und Bandläsionen des Kniegelenkes. Chirurg, 1991, 62, 394-398.
7. Erlemann R., Reiser M. F., Peters P. E. et al. Musculoskeletal neoplasms: static and dynamic Gd-DTPA-enhanced MR imaging. Radiology, 1989, 171, 767-773.
8. Graf R. Sonographie der Säuglingshüfte. Enke-Verlag, Stuttgart, 1989.
9. Jerosch J., Castro W. H. M., Assheuer J. Einsatzmöglichkeiten der Kernspintomographie bei degenerativen Erkrankungen des Schultergelenkes. Orthop. Praxis, 1990, 8, 486-492.
10. Jerosch J., Castro W. H. M., Sons H. U. et al. Der Aussagewert der Sonographie bei Verletzungen des Kniegelenkes. Ultraschall, 1989, 10, 275-281.
11. Jerosch J., Castro W. H. M., Jantea Ch. et al. Möglichkeiten der Sonographie in der Diagnostik von Instabilitäten des Schultergelenkes. Ultraschall, 1989, 10, 202-205.
12. Lisbona R., Rosenhall L. Observations on the sequential use of ^{99m}Tc-phosphate complex and ⁶⁷Ga imaging in osteomyelitis, cellulitis and septic arthritis. Radiology, 1977, 123, 123-129.
13. Peters P. E., Matthiaß H. H., Reiser M. Magnetresonanztomographie in der Orthopädie. Enke-Verlag, Stuttgart, 1990.

14. Schulitz K. P., Schöppe K., Wehling P. The correlation between CT-discography, MRI and surgical findings in sequestered and non-sequestered herniation. Presented at the 'International Society for the Study of the Lumbar Spine'. Miami (Florida), 1988.
15. Schittich L., Gradinger R., Hipp E. Legg-Calve-Perthes'sche Erkrankung im MRI : Möglichkeiten und Grenzen. *Z. Orthop.*, 1990, 128, 404-410.
16. Sellier T., Mutschler B. Sonographisches Hüftscreening bei Neugeborenen. Ergebnisse, Verlaufsbeobachtungen und therapeutische Konsequenzen. *Ultraschall*, 1977 (Suppl. 1), 75.
17. Schauwecker D. S., Park H. M., Mock B. H. et al. Evaluation of complicating osteomyelitis with Tc-99m MDP, In-111 granulocytes and Ga-67 citrate. *J. Nucl. Med.*, 1984, 25, 849-853.

SAMENVATTING

W. H. M. CASTRO, J. JEROSCH, M. SCHILGEN, W. WINKELMANN. De toepassing van moderne beeldvormende onderzoeksmethoden in de orthopedie.

Aan de hand van grotendeels eigen onderzoeksmateriaal worden de echografie, computertomografie, magnetic resonance imaging en botsintigrafie, in zoverre in hun huidige toepasbaarheid voor de orthopaedie van belang,

nader belicht. De mogelijkheden die deze vier onderzoeksmethoden bieden bij de diagnostiek van aandoeningen van het steun- en bewegingsapparaat, hebben bijgedragen aan een vroege herkenning van pathologische processen waardoor therapeutische mogelijkheden beter en eerder kunnen worden benut. Dit alles zal de late gevolgen van de betreffende afwijkingen zeker gunstig beïnvloeden.

RÉSUMÉ

W. H. M. CASTRO, J. JEROSCH, M. SCHILGEN, W. WINKELMANN. Application à l'orthopédie des techniques actuelles d'imagerie.

À l'aide de nombreux documents personnels, les auteurs examinent l'apport de l'échographie, de la tomodesitométrie, de la résonance magnétique nucléaire et de la scintigraphie osseuse à l'orthopédie. Ces 4 techniques ont considérablement amélioré les possibilités diagnostiques des affections de l'appareil locomoteur et permis un diagnostic plus précoce de nombreuses affections et partant l'instauration immédiate d'une thérapeutique adéquate, qui en limite les séquelles, d'affections.