

THE USE OF SKULL BONE IN MAXILLOFACIAL RECONSTRUCTION AND ITS POTENTIAL USE IN ORTHOPEDIC SURGERY

B. L. I. VAN BUTSELE¹, M. Y. MOMMAERTS^{1,2}, L. F. NEYT¹, C. A. S. DE CLERCQ¹,
J. V. ABEJLOOS¹, D. R. WITHOFS¹, W. I. JACOBS²

The calvarium provides a source of bone grafts that are widely applied in maxillofacial surgery, with minimal donor-site morbidity and less resorption than endochondral grafts. A technique of harvesting monocortical bone is described and possible indications in orthopedic surgery are proposed. Thus, we suggest that skull bone can be used in orthopedic surgery in some instances, resulting in less donor-site morbidity than when autogenous bone from other sources is used.

Keywords : bone grafts ; maxillofacial surgery ; orthopedic surgery.

Mots-clés : greffe osseuse ; chirurgie maxillo-faciale ; orthopédie.

INTRODUCTION

The use of bone grafts is an important aspect in both maxillofacial and orthopedic surgery. There is currently a wave of enthusiasm among maxillofacial surgeons for the use of skull bone.

The calvarium is a valuable alternative to rib and ilium for many indications. This article presents an overview of applications of skull bone in the maxillofacial area, the technique of harvesting monocortical bone, and its possible indications in orthopedic surgery.

PATIENTS AND METHODS

From September 1, 1990 until November 15, 1992, thirty-three patients received autologous monocortical calvarial bone grafts at the Division of Maxillo-Facial Surgery, A.Z. Sint-Jan, Bruges, and the Division of

Oral and Maxillo-Facial Surgery, A.Z. Sint-Elisabeth, Herentals.

Applications included restoration of the continuity of the orbital floor by a calvarial bone inlay after a midfacial fracture (10 patients), stabilization of a repositioned maxilla after Le Fort I-type (1 patient) and Le Fort II-type osteotomy (1 patient) for facial dysmorphism, and secondary bone grafting in cleft lip and palate patients with cancellous bone (5 patients) (fig. 1). In one of these 5 patients, the grafting took place with calvarial bone mixed with freeze dried bone after a Le Fort I-type osteotomy. Other indications were recon-

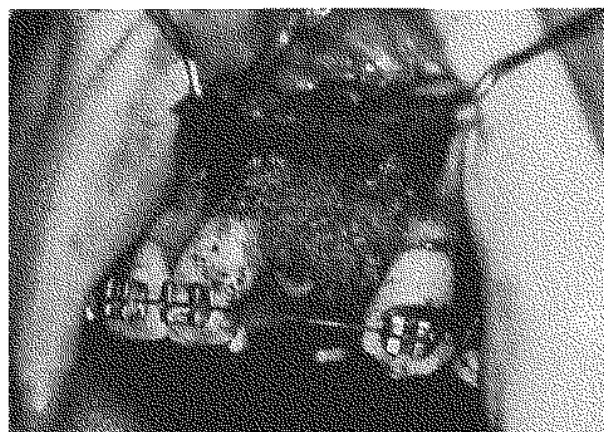


Fig. 1. — Cancellous calvarial bone in the alveolar and palatal defect of a unilateral cleft lip and palate patient.

¹ Department of Surgery, Division of Maxillo-Facial Surgery, A.Z. Sint-Jan, B-8000 Bruges, Belgium.

² Department of Surgery, Division of Oral and Maxillo-Facial Surgery, A.Z. Sint-Elisabeth, B-2200 Herentals, Belgium.

Correspondence and reprints : M. Mommaerts.




Fig. 2a

Fig. 2b

Fig. 2c

Fig. 2d

Fig. 2. — a. Preoperative profile view of a patient with reduced lower facial height, "witch chin", and deep mentolabial fold, mimicking premature aging.
 b. Cortical bone strips marked on the skull.
 c. Intraoral view after interpositional bone grafting. Two layers of bone strips are sandwiched in the horizontal osteotomy gap and secured with titanium screws (arrows).
 d. Profile view 6 months postoperatively.

struction of the zygomatic arches and orbitoplasty in a patient with Treacher Collins syndrome (1 patient), insertion of a graft over the dorsum of the nose in saddle nose deformity (2 patients), interpositional grafting in a genioplasty correcting a deep mentolabial fold and "witch chin" (1 patient) (fig. 2), and correcting late enophthalmia after orbital fracture (1 patient). Cancellous bone was used for filling a defect after reduction of a fronto-naso-ethmoidal fracture (1 patient). Bony reconstruction was achieved after hemimaxillectomy with a temporalis muscle flap as the oral layer (1 patient) or a rotation flap from the palate (1 patient). Mandibular continuity was restored after partial mandibulectomy for pseudarthrosis and osteomyelitis (1 patient) (fig. 3). Bony augmentation of an atrophic mandible in the symphyseal part was performed as a sandwich procedure with placement of titanium implants in the same operative session (1 patient). Three patients underwent the same procedure with second-staged placement

of titanium implants, and one patient had reconstruction of the alveolar process of the maxilla by onlay bone grafting followed by bridgework (1 patient). Other procedures included transverse splitting of a residual alveolar process after trauma, with interpositional bone grafting followed by placement of four titanium implants 3 months later (1 patient), and augmentation and advancement of an edentulous maxilla, after a Le Fort I-type osteotomy with interpositioning of calvarial bone plates, combined with a submucous vestibuloplasty (1 patient).

Surgical technique of harvesting monocortical skull bone

All patients had preoperative posteroanterior and lateral skull radiographs taken to estimate the relative amount of diploic bone between the inner and outer tables of the skull, and to screen for local pathology or the presence of large intraosseous venous sinuses.



Fig. 3a

Fig. 3b

Fig. 3c

Fig. 3. — a. Calvarial cortical bone plate with titanium screws to bridge a defect after partial sagittal mandibulectomy for pseudarthrosis.
 b. Intraoral view of the grafted defect.
 c. Tomograph two weeks postoperatively.

The technique of harvesting monocortical bone was derived from Tessier's technique (7). Bone was always taken from the parietal side over the patient's nondominant hemisphere. After minimal or no shaving and draping in a sterile fashion, the cranium is exposed by a 4 to 6-cm vertical scalp incision crossed in the middle by a 4- to 6-cm horizontal incision. Hemostasis is obtained by bipolar electrocoagulation. The periosteum is reflected together with the galea and skin as a composite flap. With a pear-shaped burr, a gutter is made down to the diploë. Brisk bleeding signifies that the diploë has been entered (fig. 4a). With a fine Lindemann burr, strips of 1 by 4 cm or 3 by 3 cm are marked in situ. Grafts of these dimensions can then be taken safely without the risk of fracturing the graft or entering the inner cortical table. The outer edge of the gutter is beveled, to allow easy introduction of a straight or preferably a curved osteotome into the diploë (fig. 4b). Gentle tapping with the mallet advances the osteotome through the diploë, and the outer cortical table can be removed (fig. 4c). Then, cancellous diploic bone can be harvested using small chisels, rongeurs or a curette. Hemostasis is accomplished with fibrin glue (Tissucol, Immuno N.V., Brussels). A two-layer scalp closure is performed using 3-0 Vicryl (Ethicon, Ethnor S.A., Neuilly, France) for the periosteum and galea, and apposition hooks (Appose ULC, 6.9 mm \times 3.8 mm, Davis and Geck, Cyanamid Medical Device Co., Anyang, Korea) for the skin (fig. 4d). The wound is rinsed with an antibiotic solution and covered with a nonadhesive dressing.

RESULTS

The calvarium provides slightly curved grafts, which is an advantage in many instances. Three strips of 1 by 4 cm can easily be taken. The

amount of cancellous bone (diploë) available is about 1 ml if a graft of 1 by 4 cm is taken.

Complications were rare. Three hematomas occurred, which resolved after needle aspiration in all three patients and which resulted once in a prolonged hospital stay of 2 days. In one patient we observed wound dehiscence in the palate, purulent drainage through the nose and resorption of the graft of calvarial bone that had been mixed with freeze dried bone and that was placed 14 days earlier for closure of an alveolar cleft. Freeze dried bone had to be added to the calvarial graft, because the amount of grafting material needed had been underestimated. The infection was probably due to inadequate closure of the nasal mucosa.

In one patient where the orbital floor was reconstructed with calvarial bone, complete integration of the graft at the time of removal of the infraorbital osteosynthesis plate was observed.

DISCUSSION

The use of skull bone grafting in craniomaxillofacial surgery includes many indications that previously were reserved for rib and iliac bone.

Donor-site morbidity after harvesting rib and iliac bone is considerable (4). Grafting with skull bone causes little if any postoperative pain in the donor-site area, no secondary deformity at the donor-site, and a nonvisible scar, as the incision is placed within the hairbearing skin. Another advantage includes the abundance of material as compared with other sources in children.

According to its origin, bone may be divided into chondral and mesenchymal forms. In the

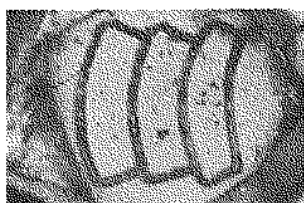


Fig. 4a




Fig. 4b



Fig. 4c



Fig. 4d

Fig. 4. — a. Brisk bleeding signifies that the diploë has been entered.
b. Gentle tapping with the mallet advances the osteotome through the diploë.
c. The outer cortical table can be removed.
d. The skin is closed with apposition hooks.

growth of any long bone, a chondral bone, is occasioned by cartilaginous growth of the epiphysis, which is gradually replaced by new bone from the diaphysis. Membranous bone is formed by the replacement of a membrane of preexisting condensed mesenchyme. A greater graft volume survival with membranous bone from the skull as compared to endochondral bone from the iliac crest or rib has been observed in the craniofacial region (10). It has also been demonstrated that membranous grafts are vascularized earlier than endochondral grafts (3). Disadvantages of skull bone are the relatively small amount of cancellous bone available in adults and the brittleness of the bone, which does not facilitate the shaping of the grafts once they are taken.

Possible complications include hematoma, seroma, scalp wound dehiscence, dural tear, arachnoidal bleeding and donor-site infection. Initially, when this technique is used, the help of a neurosurgeon may be sought until the surgeon feels comfortable with the procedure. Skull bone can be used as a bicortical or unicortical graft, bone dust, skull chips or shaving grafts, or as a pedicled bone flap. The use of pedicled skull bone has been advocated in the treatment of Treacher Collins syndrome for the correction of the malar deficiency (5, 8).

The use of cancellous cranial bone in secondary bone grafting of alveolar clefts remains controversial. In the opinion of Wolfe (9) it is the material of choice for the 7- to 11-year group, although others argue against its use. Jackson *et al.* (1) state that the lack of bone density allows periodontal defects to form on teeth adjacent to the cleft and inhibits tooth eruption. Kortebein *et al.* (2) felt that their inferior results with skull bone were probably related to the high ratio of less cellular cortical bone to cancellous bone, that resulted from not specifically separating cortical from cancellous components.

Traditional bone grafts in orthopedic surgery are taken from the ilium or tibia. These two bones provide cancellous and cortical grafts respectively. The dorsal and volar distal radius and the olecranon provide small cancellous bone grafts, which can be used in hand surgery. After a segment of

cortical bone has been removed, small amounts of cancellous bone can be harvested with a curette.

The subcutaneous anteromedial aspect of the tibia is the donor-site of choice for providing cortical grafts, which is preferred when strength is necessary in a graft for bridging a defect in a long bone or even for the treatment of pseudarthrosis. In adults, after removal of a cortical graft, the condyles of the tibia supply cancellous bone. There are disadvantages to the use of the tibia as a donor area : (a) a normal limb is jeopardized, (b) removal of the graft adds to the length and magnitude of the procedure, (c) convalescence may be prolonged.

The ilium provides abundant cancellous bone. Here also, donor-site morbidity may be considerable. Laurie *et al.* (4) in a combined retrospective and prospective study on iliac donor-site morbidity in 60 patients found moderate postoperative pain lasting from 2 weeks to 2 months, with an average of 6 weeks in all patients, and 10% had pain after 2 years. No patients had gait disturbances after 1 year.

Cortical bone grafts are primarily useful for fixation ; cancellous bone grafts are primarily advantageous for osteoinduction. Since relatively inert metals have become available, fixation as a rule is best performed by internal or external metallic devices. Chips of cancellous bone are the best osteogenic material available. They can be used for filling defects resulting from cysts or tumors, for wedging in osteotomies, and to hasten healing by bridging a defect after fixation with cortical bone or metallic devices.

Possible indications of skull bone in orthopedic surgery include all conditions where relatively large amounts of cortical bone and/or relatively small amounts of cancellous bone are necessary, including all conditions in hand surgery where bone grafting is necessary, cancellous bone grafting for scaphoid nonunion, and cancellous or corticocancellous grafts for wrist arthrodesis. Additional indications include the treatment of atrophic (avascular) nonunion of fractures of long bones, which require decortication and bone grafting for healing ; if the bone loss is not too massive (type A nonunions in the classification of Paley *et al.* (6)

the calvarium can provide enough cortical and cancellous bone for grafting the defect.

From our experience in maxillofacial surgery, we conclude that the technique of calvarial bone grafting may be useful in the armamentarium of the orthopedic surgeon.

REFERENCES

1. Jackson I. T., Helden G., Marx R. Skull bone grafts in maxillofacial and craniofacial surgery. *J. Oral Maxillofac. Surg.*, 1986, 44, 949-955.
2. Kortebein M. J., Nelson C. L., Sadove A. M. Retrospective analysis of 135 secondary alveolar cleft grafts using iliac or calvarial bone. *J. Oral Maxillofac. Surg.*, 1991, 49, 493-498.
3. Kusiak J. F., Zins J. E., Whitaker L. A. The early revascularization of membranous bone. *Plast. Reconstr. Surg.*, 1985, 76, 510-516.
4. Laurie S. W., Kaban L. B., Mulliken J. B., Murray J. E. Donor-site morbidity after harvesting rib and iliac bone. *Plast. Reconstr. Surg.*, 1984, 73, 933-938.
5. Mc Carthy J. G., Zide B. M. The spectrum of calvarial bone grafting: introduction of the vascularized calvarial bone flap. *Plast. Reconstr. Surg.*, 1984, 74, 10-18.
6. Paley D., Catagni M. A., Argagni F., Villa A., Benedetti G. B., Cattaneo R. Ilizarov treatment of tibial nonunions with bone loss. *Clin. Orthop.*, 1989, 241, 146-165.
7. Tessier P. Personal communication, 1985.
8. Van der Meulen J. C. H., Hauben D. C., Vaandrager J. M., Birgenhager-Frenkel D. H. The use of a temporal osteoperiosteal flap for the reconstruction of malar hypoplasia in Treacher Collins syndrome. *Plast. Reconstr. Surg.*, 1984, 74, 687-693.
9. Wolfe S. A., Berkowitz S. The use of cranial bone grafts in the closure of alveolar and anterior palatal clefts. *Plast. Reconstr. Surg.*, 1983, 72, 659-668.
10. Zins J. E., Whitaker L. A. Membranous versus endochondral bone: implications for craniofacial reconstruction. *Plast. Reconstr. Surg.*, 1983, 77, 778-785.

SAMENVATTING

B. L. I. VAN BUTSELE, M. Y. MOMMAERTS, L. F. NEYT, C. A. S. DE CLERCQ, J. V. ABELOOS, D. R. WITHOFS, W. I. JACOBS. Het gebruik van botgreffen uit de schedel in maxillofaciale reconstructie en hun mogelijk gebruik in de orthopedische heelkunde.

Botgreffen van het calvarium worden vaak gebruikt in de maxillofaciale heelkunde, met minimale morbiditeit t.h.v. de plaats van afname en minder resorptie dan endochondrale greffen. Een techniek voor het afnemen van monocorticale greffen wordt beschreven en mogelijke indicaties in de orthopedische chirurgie worden voorgesteld. We suggereren dus dat bot van het calvarium kan gebruikt worden in de orthopedische chirurgie voor verscheidene indicaties, met minder morbiditeit dan indien bot van andere donorplaatsen zou worden gebruikt.

RÉSUMÉ

B. L. I. VAN BUTSELE, M. Y. MOMMAERTS, L. F. NEYT, C. A. S. DE CLERCQ, J. V. ABELOOS, D. R. WITHOFS, W. I. JACOBS. Les greffes d'os crâniens dans les techniques de reconstruction en chirurgie maxillofaciale et en chirurgie orthopédique.

Les greffes osseuses crâniennes sont souvent utilisées en chirurgie maxillofaciale. La morbidité en est mineure et il y a moins de résorption que pour les greffes d'os endochondral. Les auteurs présentent une technique de prélèvement de greffe monocorticale, et ses applications en chirurgie orthopédique. Leur expérience en chirurgie maxillofaciale démontre que l'os crânien peut être utilisé en chirurgie orthopédique avec une morbidité moindre que celle d'autres sites de prélèvement.