

CLASSIFICATION OF BONE HEALING AFTER INTERTROCHANTERIC OSTEOTOMIES CONSEQUENCES FOR THE SURGICAL PROCEDURE AND POSTOPERATIVE REHABILITATION

J. SCHMIDT, D. KUMM, S. NAUGHTON

Intertrochanteric osteotomies produce a rate of 1 to 7% delayed union and pseudarthrosis, mainly as a result of the quality of the surgical procedure employed. In this retrospective and prospective study we have divided the models of bone healing after intertrochanteric osteotomy into 4 groups based on the postoperative x rays, and have taken into account only the factors of sclerosis, radiolucency and fragment contact in the osteotomy plane. This grouping enables us to evaluate the quality of the surgical procedure and to predict the postoperative course at an early stage, thus facilitating timely modification of the postoperative rehabilitation.

Keywords : intertrochanteric osteotomy ; bone healing.
Mots-clés : ostéotomie intertrochantérienne ; cicatrisation osseuse.

1. INTRODUCTION

Intertrochanteric osteotomies are usually performed for the correction of coxa valga or ante-torsion in hip dysplasia (fig. 1a), or for flexion and valgus displacement in femoral head necrosis (fig. 1b). The main complications associated with this procedure are delayed union of the osteotomy and pseudarthrosis in 1 to 7% of all patients (1, 2, 3, 7). Except for Hertel and Hassenpflug (3), the literature provides no precise definition of the term "bone union".

This complication produces severe consequences such as reoperation or prolonged rehabilitation. We therefore tried to identify prognostic factors for delayed union or pseudarthrosis. Up to now, only the correct position of the angled blade plate and of the fragments shown on the postoperative

x rays have been analyzed in order to evaluate the quality of the surgical procedure.

No firm criteria have previously been identified against which we could judge either the quality of the biomechanical requirements for a correct intertrochanteric osteotomy, or especially the tension in the angled blade plate and the compressive strain in the osteotomy gap.

In this study we have concentrated on the osteotomy gap and on trying to acquire more information on the biomechanical quality of the surgical procedure. With Wolff's law (10) and the work of Pauwels (5) in mind, we postulated that the development of radiolucency with or without bone sclerosis in the region of the osteotomy, results from an undesirable distribution of the compressive strain in the gap.

If it were possible to define a classification based on phenomena such as sclerosis and radiolucency and if this classification could be correlated to delayed bone union and pseudarthrosis, it ought to be possible to judge the quality of the surgical procedure. If application of this classification were possible at an early stage, postoperative care could be modified in time to avoid complications.

2. MATERIALS AND METHODS

2.1. Retrospective Study

First of all, we analyzed 100 consecutive cases involving intertrochanteric osteotomies performed at the

Klinik und Poliklinik für Orthopädie der Universität zu Köln, Joseph-Stelzmann-Str. 9, D-50924 Köln, Germany.

Correspondence and reprints : J. Schmidt.

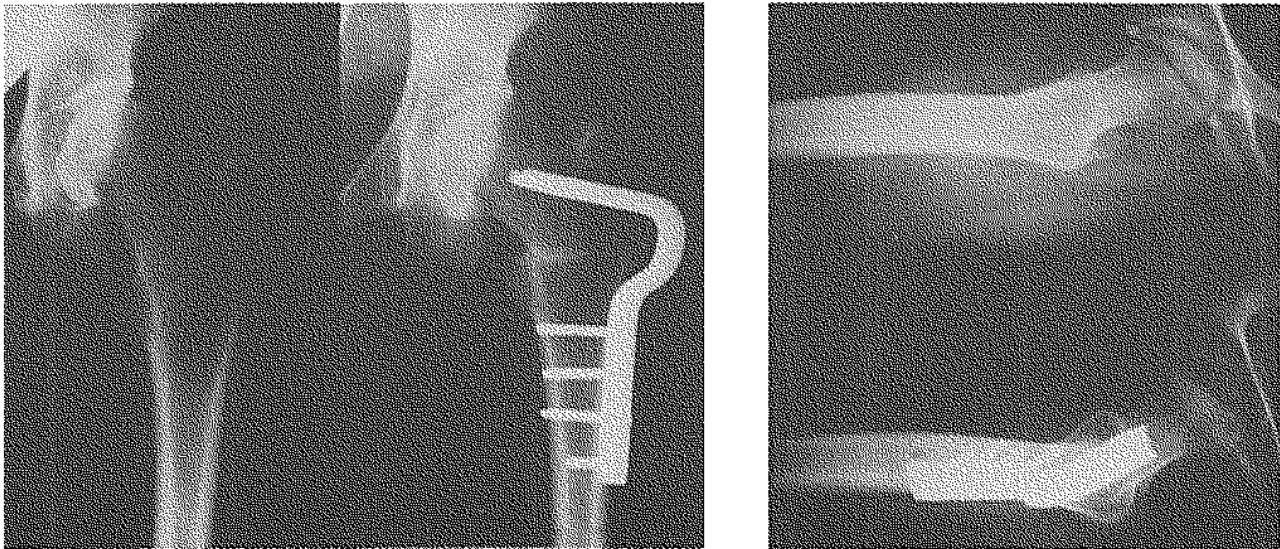


Fig. 1. -- Intertrochanteric varus osteotomy in hip dysplasia in the AP view (a) and a flexion-valgus osteotomy in femoral head necrosis in the "Lauenstein" position (90° flexion, 45° abduction, neutral rotation) (b) with 90° angled blade plates.

orthopedic clinic of the University of Cologne before December 31, 1989 with the AO-Standard technique (9). In order to secure a homogeneous population, the following criteria were applied: patients over 18 years of age, no femoral head necrosis and a postoperative history of at least 1 year. For 94 patients x rays taken 3 months after surgery were available. Tracings were made of each x ray. These were confined to the parameters of sclerosis, fragment contact and radiolucency. Our groupings were then defined on the basis of these tracings, without further reference to any other aspect of the surgical procedures. These groupings were subsequently correlated with the development of pseudarthrosis and delayed bone union. Pseudarthrosis was diagnosed if no bone healing had occurred within 6 months and a second operation had been performed due to this complication. Bone union was considered to have been delayed if bone healing had not taken place within 6 months but the conservative treatment was continued, and if the patient had not been able to bear his full weight on this joint within this period.

We tried to measure the postoperative varization. Because no standardized x rays were available for these measurements, we used the results only in varizations of more than 3° after operation.

Complete case histories, including x rays taken at 6, 12, and 26-52 weeks postoperatively were available for 63 of these 94 patients. Using these 63 cases, we investigated the reliability of our classification at an early stage of postoperative rehabilitation (6 weeks).

2.2. Prospective study

Starting in 1988, we performed and prospectively documented a parallel series of intertrochanteric osteotomies, applying a modified technique with the intertrochanteric functional prebending (IFP) of the blade plate (8). In this technique a lateral gap of exactly 6° is achieved by certain sawing aids before employing an interfragmentary compression of 1000 N. The first author either performed the operations himself or assisted the surgeon, thus selecting the patients. To date 21 patients with complete clinical and radiological histories have been documented on the day of surgery, and 2 to 3, 6 and 12 weeks postoperatively. The results of this group were compared with the retrospective study.

3. RESULTS

3.1. Retrospective Study

Ninety-four sets of x rays taken 3 months after an intertrochanteric osteotomy were classified into four groups using the method mentioned above.

Group I showed a solid narrow band of sclerosis. Any traces of the area of osteotomy appeared, if at all, only as a very thin radiolucent line (fig. 2).

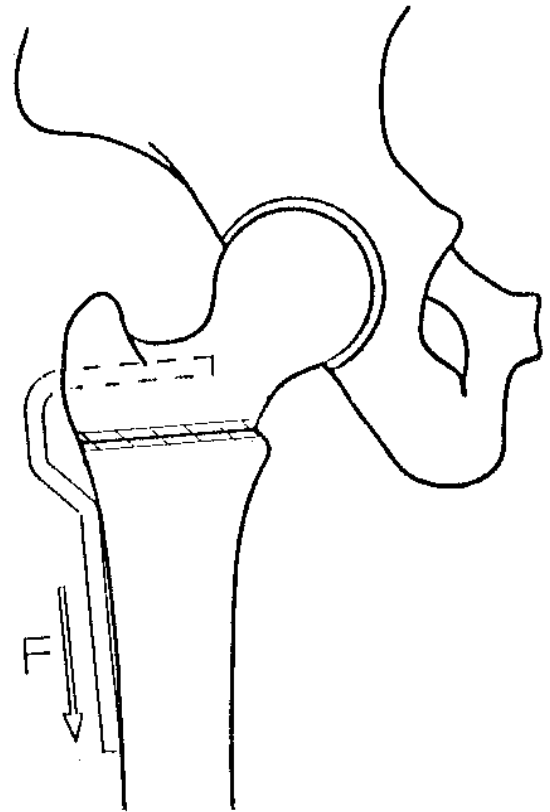
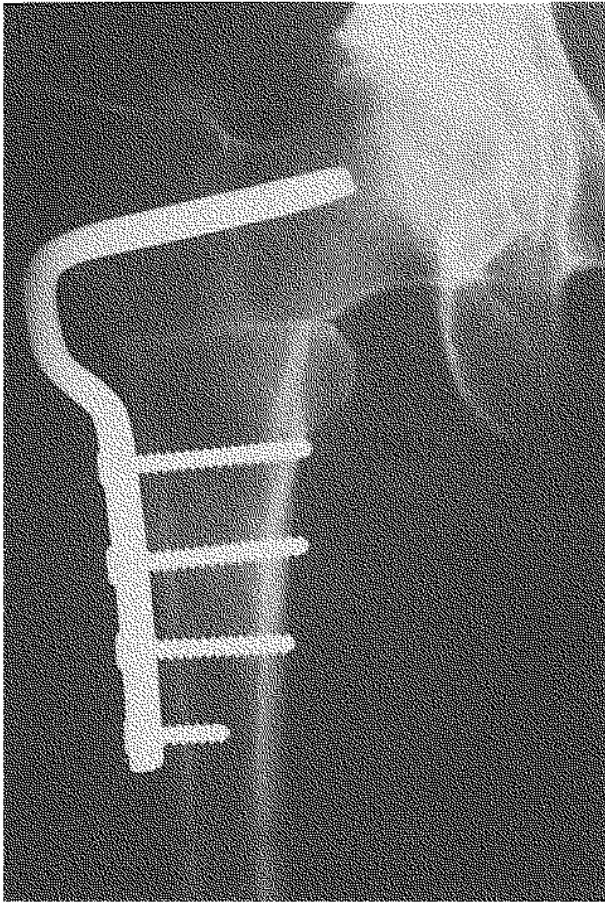


Fig. 2. — Diagram and x ray of group I.

- Group II displayed triangular sclerosis in the medial part of the osteotomy plane, but no medial gap or radiolucency (fig. 3).
- Group III displayed a broad band of sclerosis with a wide area of radiolucency, probably indicating a gap in the osteotomy plane (fig. 4).
- Group IV exhibited small triangular sclerotic areas in both the medial and lateral parts of the osteotomy plane, with no gap but possibly a very thin radiolucent line confined to the osteotomy plane (fig. 5).

The correlation between the distribution of the different groups and the development of pseudarthroses (PA) and delayed unions (DU) is shown in table I. The incidence of these complications is 11.7%. With a statistical probability of 90%, between 8 and 16% of all patients belonging to groups II and III will develop either a pseudarthrosis or a delayed union.

Table II shows the distribution of the 63 patients with x rays taken 6 and 12 weeks postoperatively between the groups, according to their complications. In 14 cases we discovered a shift within the different groups between the 6th and 12th postoperative week, mainly into group III (Table III).

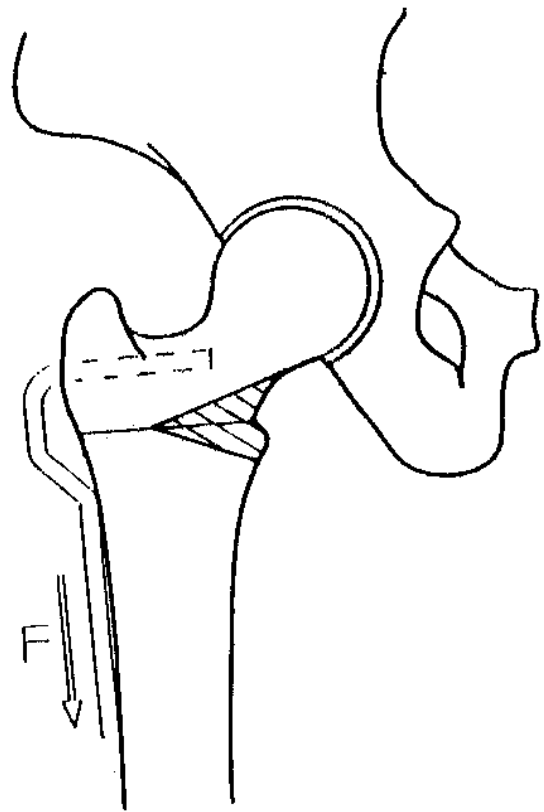
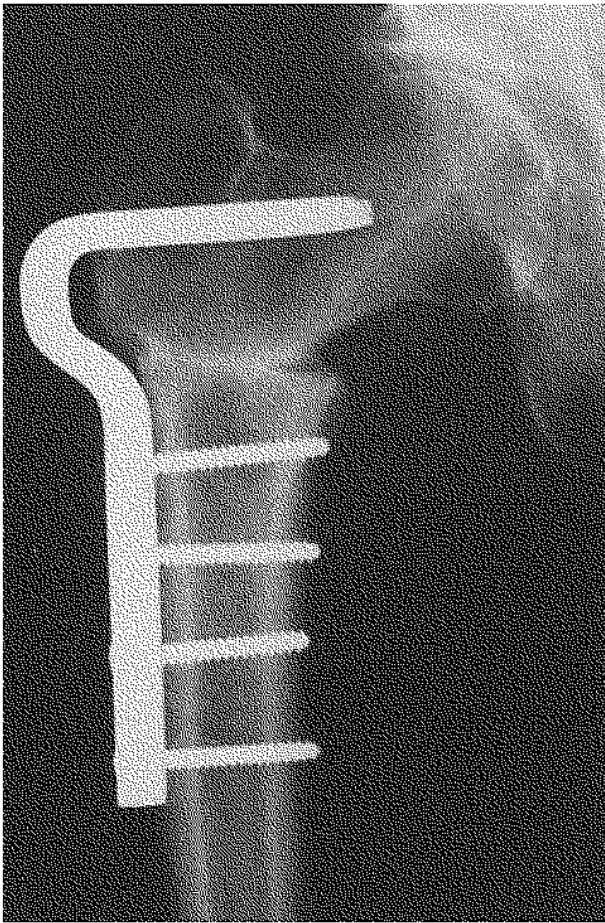


Fig. 3. — Diagram and x ray of group II.

Table I. — Classification of intertrochanteric osteotomies based on the x rays taken 12 weeks after the operation in the area of the osteotomy plane (PA = pseudarthrosis, DU = delayed union)

Group	I	II	III	IV	
N	17	52	20	5	94
PA	0	2	3	0	5
DU	0	3	3	0	6

Table II. — Classification of 63 patients with intertrochanteric osteotomies 6 and 12 weeks after the operation

Group	I	II	III	IV	
6 weeks after operation					
N	16	29	13	5	63
PA	0	1	3	0	4
DU	0	3	0	0	3
12 weeks after operation					
N	13	37	10	3	63
PA	0	1	3	0	4
DU	0	3	0	0	3

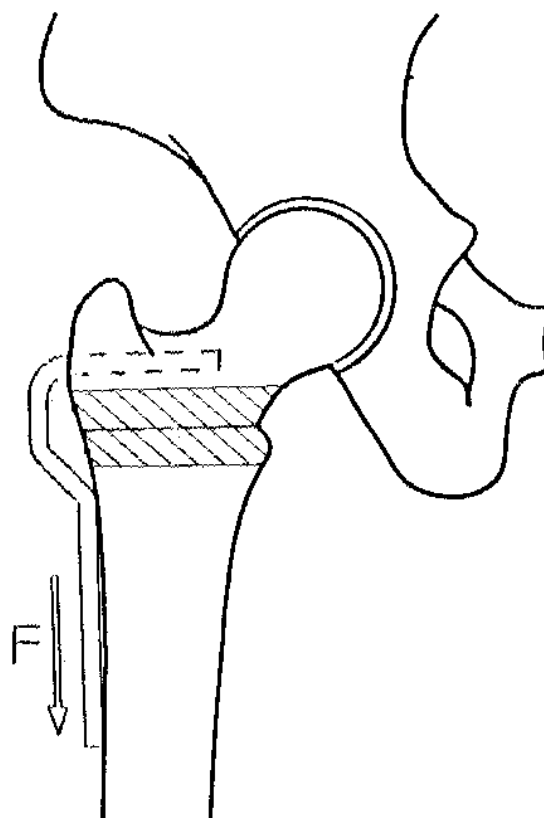
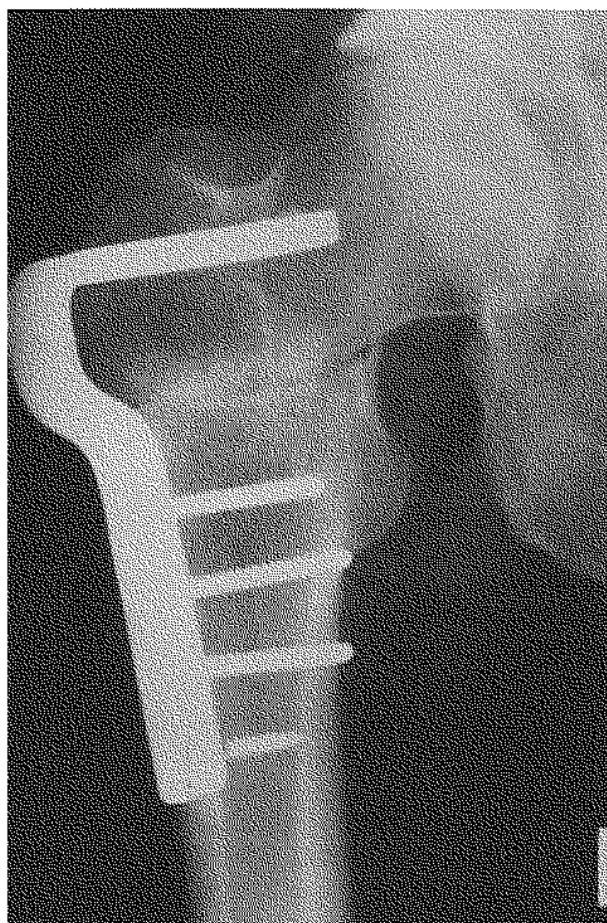

Fig. 4. — Diagram and x ray of group III.

Table III. — Shift between the groups of 63 patients with intertrochanteric osteotomies from 6 to 12 weeks after the operation

Group	N	shift	to Group			
			I	II	III	IV
I	16	6	—	5	1	0
II	29	2	1	—	1	0
III	13	4	0	4	—	0
IV	5	2	1	1	0	—

Table IV. — Classification of intertrochanteric osteotomies performed using the IFP technique 2-3, 6 and 12 weeks after the operation

Group	I	II	III	IV	no class.	n
2-3 weeks after operation						
	19	1	0	0	1	21
6 weeks after operation						
	19	2	0	0	0	21
12 weeks after operation						
	20	1	0	0	0	21

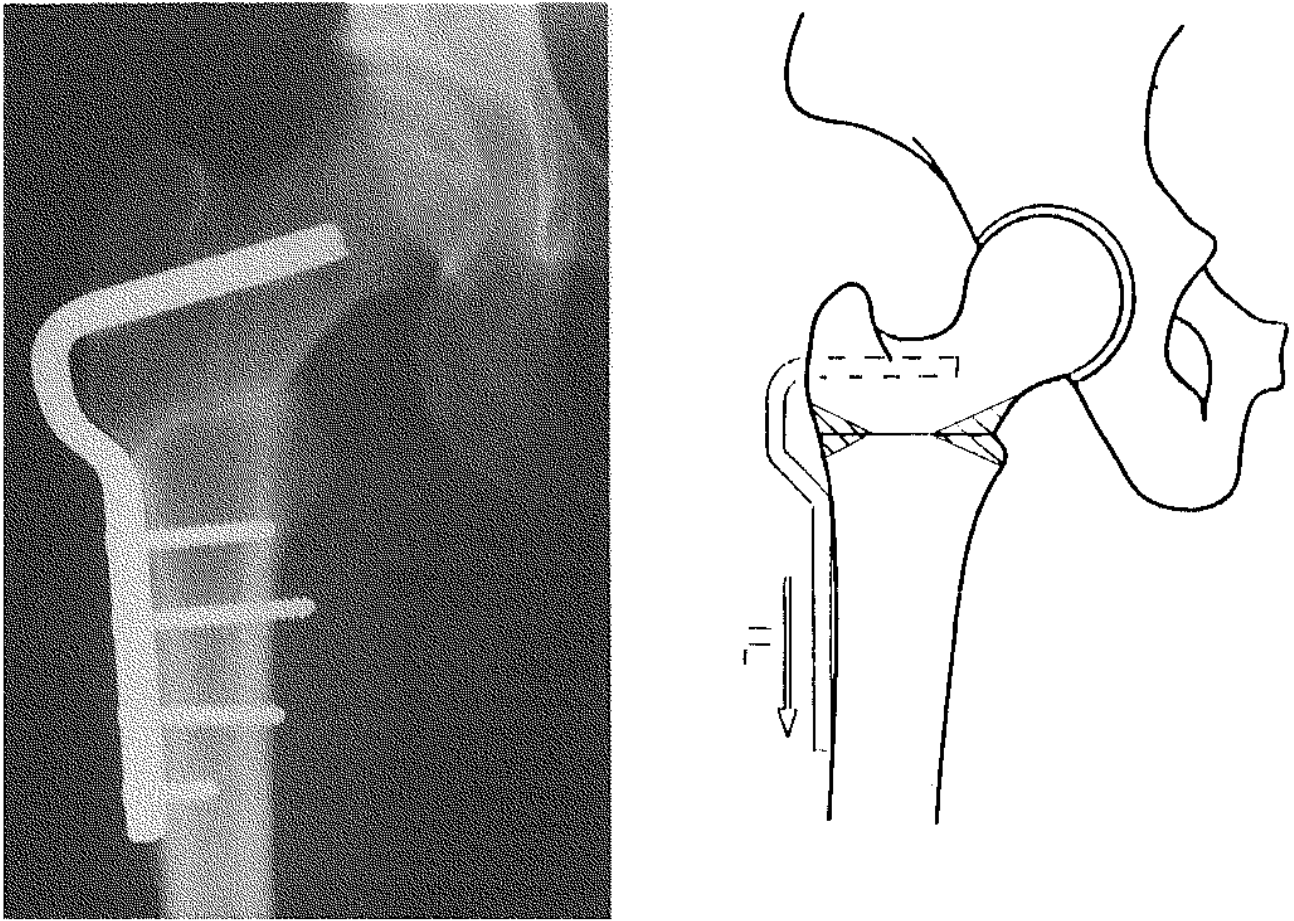


Fig. 5. — Diagram and x ray of group IV.

3.2. Prospective Study

These patients were examined 2-3, 6 and 12 weeks postoperatively (table IV). No pseudarthrosis or delayed union occurred in this group.

Three weeks after surgery one case could not be classified. This case, because of later assessments, was transferred to group I. One shift from group II to I could be documented in this study.

4. DISCUSSION

Bone healing after intertrochanteric osteotomy may be classified into 4 different types. Due to the fact that bone reacts to compression (within certain limits) with sclerosis (5), and that absence

of compression (10) as well as pathologically high compression or movement within the osteotomy plane also leads to bone resorption (6), and the fact that the distribution of the compression depends on the surgical procedures employed (9), we are able to interpret each type of healing.

In group I we postulate homogeneous compression throughout the whole osteotomy plane. This agrees with the biomechanical measurements taken during the IFP-procedure (9). Furthermore, 20 patients of 21 who had undergone IFP-procedure were categorized as group I.

The patients of group II showed the osteotomy plane at an angle of less than 90° to the axis of the femur. Therefore it can be considered that the principle of IFP did not work. The optimum

stability of this group corresponded to the results of earlier experiments and with the missing additional varization after operation. No complications occurred here. This type of healing ought to be attempted as it appears to be a successful surgical procedure.

Group IV appears to provide similar stability as no complications arose here either. Although this group may well be classified as a subgroup of group I, it can easily be distinguished due to its radiological manifestations.

The commonest group in the retrospective study is group II. The medial sclerosis is the result of medial compression during the postoperative rehabilitation. In this group the tension in the angled blade plate is lower than the compression in the medial part of the osteotomy plane. As this surgical procedure operates exactly like a tension band osteosynthesis (4), permitting movement in the osteotomy plane, we have a higher risk of delayed union or pseudarthrosis (5 out of 52). The worst results were found in group III which produced 6 complications in 20 cases. Broad areas of radiolucency and sclerosis developed as a result of instability. We judged these radiological manifestations to be the result of an inadequate surgical procedure.

Indication, age, weight, occupation, preoperative pain and the general condition of the patients did not seem to influence the healing process. Obviously these parameters are of no use in evaluating the osteotomy. Therefore the roentgenographic aspect appears to be more reliable.

Using the x rays as a basis, all cases can be classified 6 weeks after surgery. Since only 14 of 63 cases changed group after 6 weeks and only 2 of these moved to group III, the dangerous group, the course of rehabilitation is predictable at this time and the rehabilitation of patients in group III can be modified, i.e. forced hip flexion and weight bearing decreased. In these cases postoperative radiographic check-ups should be done every three weeks until definite bony union. It is probably even possible to make this prediction as early as 2-3 weeks after the operation and, if the patient is in group I or IV at this time, it may be assumed that recovery will take its normal postoperative course.

5. CONCLUSION

On the basis of the x rays, 4 groups of bone healing can be classified. These groups indicate the quality of the surgical procedure. Group I, with minor sclerosis and no radiolucency or gap, should be considered as optimum. This can be achieved using the IFP-osteosynthesis technique. The most common group (II) exhibits medial sclerosis due to the principle of a tension band osteosynthesis. In the worst group (III) we saw broad areas of radiolucency and sclerosis as a result of interfragmentary instability. Prediction is possible 6 weeks, or perhaps 2-3 weeks after the operation, allowing postoperative rehabilitation to be modified at this early stage.

REFERENCES

1. Grundhöfer B. Die Bedeutung der intertrochanteren varisierenden Osteotomie bei der Behandlung der fortgeschrittenen Coxarthrose. *Arch. Orthop. Unfall-Chir.*, 1973, 74, 345-351.
2. Hansen F. W., Hansen-Leth C., Jensen G. Intertrochanteric osteotomy with A. O. technique in arthrosis of the hip. *Acta Orthop. Scand.*, 1973, 44, 219-229.
3. Hertel F., Hassenpflug J. Pseudarthrosen und verzögerte Osteotomieheilung nach intertrochanteren Osteotomien. Ursachen und Behandlung. *Z. Orthop.*, 1982, 120, 627.
4. Müller M. E., Allgöwer M., Schneider R., Willenegger H. *Manual der Osteosynthese*. 2. Springer, Berlin, Heidelberg, New York, 1977, 366-369.
5. Pauwels F. *Atlas zur Biomechanik der gesunden und kranken Hüfte*. Springer, Berlin, Heidelberg, New York, 1973, 4-7.
6. Perren S. M., Huggler A., Russenberger M., Allgöwer M., Mathys R., Schenk R., Willenegger H., Müller M. E. The reaction of cortical bone to compression. *Acta Orthop Scand. Suppl.*, 1969, 125, 19-28.
7. Reichel F., Schweigert C., Müller-Stephan H. Operationstechnische Fehler bei intertrochanteren, varisierenden Osteotomien. *Beitr. Orthop. Traumatol.*, 1976, 23, 610-622.
8. Schmidt J. Operative procedure using the improved osteosynthesis technique for intertrochanteric osteotomies. Preliminary report. *Arch. Orthop. Trauma Surg.*, 1991, 110, 257-259.
9. Schmidt J., Dau A. Comparison of the primary stability of intertrochanteric osteotomies referred to different operative procedures — experimental results. *Int. Orthop.*, 1994, 18, 102-108.
10. Wolff J. Über die Theorie des Knochenschwundes durch vermehrten Druck und der Knochenanbildung durch Druckentlastung. *Langenbecks Arch. klin. Chir.*, 1891, 42, 302-324.

SAMENVATTING

J. SCHMIDT, D. KUMM, S. NAUGHTON. Classificatie van botheling na intertrochantaire osteotomie. Praktische gevolgen voor de chirurgische techniek en de post-operatieve revalidatie.

Intertrochantaire osteotomieën geven aanleiding tot 1 tot 7% vertraagde consolidaties of pseudarthrosen, hoofdzakelijk in verband met de gebruikte chirurgische techniek. In deze retrospectieve en prospectieve studie werden de verschillende typen botcicatrisatie na intertrochantaire osteotomie in 4 groepen verdeeld, volgens het postoperatief radiologisch aspect, waarbij rekening gehouden wordt met de volgende factoren: sclerose, botdensiteit en contact van de fragmenten in de osteotomiehaard. Door deze indeling in groepen is een evaluatie van de chirurgische techniek en van de vooruitzichten tijdens de postoperatieve periode mogelijk, met preciese timing en planning van de post-operatieve revalidatie.

RÉSUMÉ

J. SCHMIDT, D. KUMM, S. NAUGHTON. Classification du processus de cicatrisation osseuse après ostéotomie intertrochantérienne. Application à la technique chirurgicale et à la rééducation post-opératoire.

Les ostéotomies intertrochantériennes sont grevées d'un taux de 1-7% de retard de consolidation ou de pseudarthrose, résultant avant tout de la qualité de la technique chirurgicale. Dans cette étude rétrospective et prospective, les auteurs ont divisé le type de cicatrisation osseuse, après ostéotomie intertrochantérienne en 4 groupes, d'après l'aspect radiographique postopératoire et ont tenu compte de différents facteurs: sclérose, transparence osseuse et contact des fragments dans le foyer d'ostéotomie. Ces critères permettent d'évaluer la qualité de la technique chirurgicale et de prévoir précocement le décours post-opératoire, améliorant ainsi la planification de la rééducation.