

# ANEURYSMAL BONE CYST LONG-TERM RESULTS AND FUNCTIONAL EVALUATION

C. J. M. VAN LOON<sup>1</sup>, R. P. H. VETH<sup>1</sup>, M. PRUSZCZYNSKI<sup>2</sup>, J. A. M. LEMMENS<sup>3</sup>, J. R. VAN HORN<sup>4</sup>

A study was performed on 13 patients with 16 primary aneurysmal bone cysts (ABC) to assess long-term results and functional outcome. The average age at diagnosis was 19.8 years. The anatomical sites were femur (4), tibia (5), humerus (2), fibula (2) and other (3). Four ABC's required no treatment. One patient underwent radiotherapy for an ABC of the spine. Eleven ABC's were treated surgically, mostly by intracapsular resection and bone grafting. Three patients had a total of 6 recurrences, which needed further treatment. At the time of follow-up (average period : 102 months), the average functional evaluation rate of 13 patients was 96%. These functional results were graded as excellent in 9 patients and good in 4.

**Keywords :** aneurysmal bone cyst ; bone cyst ; cryosurgery.

**Mots-clés :** kyste osseux anévrismal ; kyste osseux ; cryothérapie.

## INTRODUCTION

Aneurysmal bone cyst (ABC) is an uncommon benign lesion of unknown origin (1, 3, 4, 5, 9, 10, 13, 14). It is a generally recognized primary entity (3, 4, 5, 10), although ABC can occur secondary to other lesions (1, 2, 5, 10, 13). ABC can develop in any bone, but most commonly affected are the long bones and vertebral column (1, 2, 3, 4, 8, 9, 10, 13, 14). Adolescents are predominantly involved (1, 2, 3, 4, 8, 9, 10, 13, 14), with a preference for females (2, 3, 4, 8, 9, 13, 14). The treatments used were curettage (2, 3, 4, 5, 8, 9, 10, 14), curettage and bone grafting (2, 3, 4, 5, 8, 9, 10, 12, 14), radiotherapy (2, 3, 4, 5, 8, 9, 10, 14), embolization (3), marginal or wide

resection (2, 3, 4, 5, 8, 9, 10, 14) and amputation (2, 14). Adjuvant therapy has been described with phenol (4), liquid nitrogen (2, 4, 12, 14) and cement (4, 12). The prognosis is usually excellent (4, 5, 9), although Campanacci *et al.* (3) described 1 patient who died as a result of complications of compression of the bladder and bowels by a large ABC of the spine.

The purpose of this study was to evaluate long-term results and functional outcome of the cases of primary ABC, treated at the Nijmegen University Hospital.

## PATIENTS AND METHODS

Between 1974 and 1991, 16 ABC's in 13 patients (9 male and 4 female) were treated at the Nijmegen University Hospital. The ABC's were all primary tumors, without clinical, radiographical or histological evidence of accompanying lesions. The average age at diagnosis was 19.8 years (range : 3-48 years). The anatomical sites were : femur in 4 cases, tibia in 5, humerus in 2, fibula in 2 and other in 3. One patient (patient 2) had 4 ABC's, located in both tibias and both fibulas. According to the staging system for benign lesions of the Musculoskeletal Tumor Society (MSTS) (6), there were 2 inactive (stage 1), 11 active (stage 2), and 3 aggressive (stage 3) lesions. Two

<sup>1</sup> Department of Orthopedics.

<sup>2</sup> Department of Pathology.

<sup>3</sup> Department of Radiology, University Hospital, P. O. Box 9101, 6500 HB, Nijmegen, The Netherlands.

<sup>4</sup> Department of Orthopedics, University Hospital, Groningen, The Netherlands.

Correspondence and reprints : R. P. H. Veth.

Table I. — Data on 13 patients with aneurysmal bone cyst

Patient (%)	Sex, age at diagnosis	Site	Stage	Treatment	Local recurrence (after months)	Follow-up (months)	Functional evaluation
1	F, 12	proximal femur	2	1. intracapsular resection	15	31	100
2	M, 22	left diaphysis tibia	2	2. intracapsular resection + cryosurgery + bone grafting		29	97
		right diaphysis tibia	2	intracapsular resection + cryosurgery + bone grafting		29	
		left and right	2	intracapsular resection + cryosurgery + bone grafting		29	
		diaphysis fibula		none			
3	M, 17	distal femur	2	intracapsular resection + bone grafting		96	100
4	M, 15	pedicle T 11	3	radiotherapy (42 Gray)		78	*
5	M, 13	pubis	1	none		133	97
6	F, 18	distal tibia	2	intracapsular resection + bone grafting		152	93
7	M, 9	proximal humerus	3	1. intracapsular resection + bone grafting	7		
				2. intracapsular resection + bone grafting	13		
				3. intracapsular resection + bone grafting	114		
				4. wide resection + implantation of vasc. fibula + plate			
8	M, 3	distal tibia	2	1. intracapsular resection	8	221	83
				2. intracapsular resection + bone grafting	40		
				3. intracapsular resection + bone grafting			
9	F, 15	humeral diaphysis	3	wide resection + implantation of vasc. fibula + ext. fix.		151	100
10	F, 21	distal femur	2	intracapsular resection + bone grafting		116	93
11	M, 43	distal femur	2	intracapsular resection + bone grafting		44	97
12	M, 21	distal tibia	2	intracapsular resection + cementation		149	100
13	M, 48	sacrum	1	intracapsular resection + bone grafting		236	100
				none		114	93

\* functional results are discussed in text.

patients presented with a pathological fracture, while 11 patients had pain as the first symptom. In 1 case (patient 4), the ABC was located in the spine and progressed rapidly to compression of the spinal cord. After diagnostic work-up, biopsies were taken. The histological diagnosis was made by experienced pathologists. The average period of follow-up was 102 months (range : 29-236 months). The details of the patients are summarized in table I.

Four ABC's received no treatment. The cyst appeared to be inactive during observation in 2 cases. In the patient with 4 ABC's, the fibular sites were not treated, because priority was given to the active tibial sites ; the fibular locations appeared more inactive. The indication for treatment of the fibular sites will be evaluated at a later time. Radiotherapy was used in 1 patient with symptoms of partial medullary compression. A total dose of 42 Gray was given, after which the symptoms subsided and the lesion healed. The other 11 ABC's had initial surgical treatment, consisting of intracapsular resection alone (2 cases), intracapsular resection and bone grafting (5 cases), intracapsular resection and cementation (1 case, fig. 1), intracapsular resection, cryosurgery and bone grafting (2 cases) and wide resection with implantation of a vascularized fibular graft with external fixation (1 case).

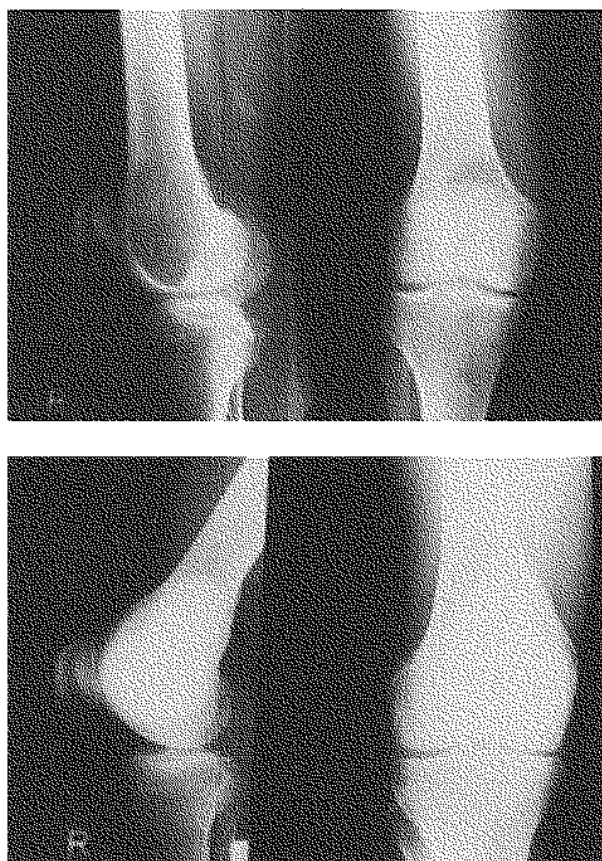
The medical files, radiographs and pathology reports of the patients were reviewed. Surgical staging, according to the MSTS-system (6), was done retrospectively. The patients were traced and asked to consent to follow-up examination. None of them refused. At the time of follow-up, history taking, physical examination and conventional radiography were performed. Functional evaluation according to the most recent MSTSS-system (7) of 12 patients was done by 1 observer (C.J.M.-v.L.). This scoring system involves 6 factors for upper and lower limbs : pain, function, and emotional acceptance are factors for both extremities. Support, walking ability, and gait are the remaining factors for the lower limb ; hand position, dexterity, and lifting ability complete the score for the upper limb. A maximum of 5 points for each factor gives a maximum total score of 30 points. The patient's score is divided by 30, resulting in a functional evaluation rate. Classification into 4 grades of the rating was done ; excellent : 5 of the 6 factors scored 5 points, independent of the score for the sixth factor ; good : 5 factors scored 3 points or more, the sixth factor may have scored 2 points or less ; fair : 5 factors scored 1 point or more, the sixth factor may have scored zero points ; poor : 2 or more of the factors scored zero points, independent of the score for the other factors. One patient with

an ABC of the spine was not functionally evaluated with the MSTS system, as the location was not in the limbs or limb girdles.

## RESULTS

### Complications

One patient had a small secondary fracture 3 months after intracapsular resection, cryosurgery and bone grafting. The fracture healed within 2 months with conservative treatment. Complications of cryosurgery were frozen skin (1 case) and transient hypesthesia from damage to the lateral femoral cutaneous nerve (1 case). One case of

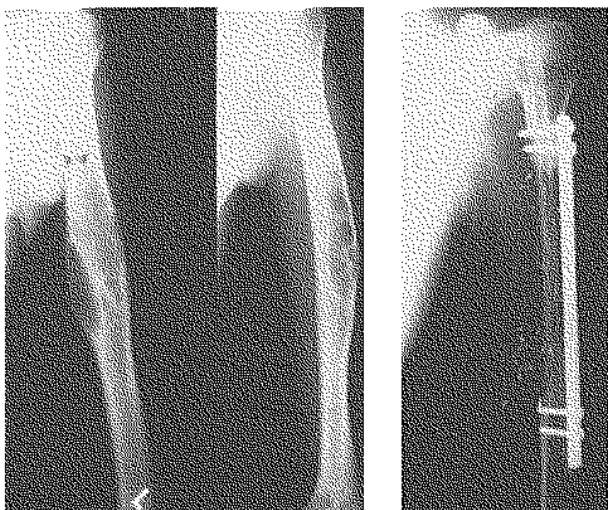


*Fig. 1.* — Case 13. 1a : Radiographs of the right knee of a 43-year-old male patient, showing a large aneurysmal bone cyst of the distal femur. b : Radiographs taken 12 years after intracapsular resection and filling of the cavity with cement. The cement is in a subchondral position. This patient scored 100% in the functional evaluation (grade : excellent).

urinary tract infection resolved with antibiotic therapy.

### Recurrence

Three patients had a total of 6 recurrences (1, 2 and 3 recurrences in 1 patient each). Additional treatment (a total of 6 operations) was required in these patients. This included intracapsular resection and bone grafting (4 operations), intracapsular resection, cryosurgery and bone grafting (1 operation), and wide resection with implantation of a vascularized fibular graft and plate (1 operation, fig. 2).



*Fig. 2.* — Case 8. a: Radiographs of the left humerus of a 19-year-old male patient with a third recurrence after treatments with intracapsular resections and bone grafting. b: Radiograph taken 6 years after wide resection and reconstruction with a vascularized fibular graft and plate fixation. The functional evaluation rate of this patient was 83% (grade: good).

### Functional results

At follow-up, the average functional evaluation rate was 96% (range: 83-100). Five patients scored the maximum of 100%. The location of the lesion in all of these patients (two with recurrence) was in the lower extremity. The patients had no pain and unrestricted function. They did not use support of any kind, and they had unlimited walking

ability, with a normal gait. The patients were enthusiastic about the treatment.

Five patients with the lesion in the lower limb had a lower rate, due to mild pain (2 patients), mildly restricted function (2 patients), submaximal emotional acceptance (2 patients), and slightly abnormal gait (1 patient). Two patients with an ABC located in the upper limb scored less than 100% because of decreased lifting ability and lack of enthusiasm about the result of the treatment. The rates were graded as excellent in 9 cases and good in 4. None of the patients had a fair or poor functional result. One patient with a spinal ABC had no pain or restriction. Walking was unlimited and without support. There was no spinal deformity or any other neurological signs. The patient was satisfied with the treatment, but not enthusiastic.

### DISCUSSION

Some of the other lesions to be found in conjunction with ABC are chondroblastoma, giant cell tumor, chondromyxoid fibroma, nonossifying fibroma, fibrous dysplasia, solitary bone cyst, enchondroma, osteoblastoma and conventional osteosarcoma (1, 2, 3, 4, 10, 13). Campanacci (3, 4) suggested altering the terminology for secondary ABC to “a principal lesion with hemorrhagic or cystic changes”, since (primary) ABC appeared to be a lesion with a specific identity. Cases with evidence of other lesions were excluded from this series, leaving only the cases of “true” ABC.

Unlike most reports (2, 3, 4, 8, 9, 13, 14), male patients were predominant in our series. Age distribution and localization were similar to previous reports (1, 2, 3, 4, 8, 9, 10, 13, 14).

Simple observation is permitted after biopsy, especially in small lesions (8). Grade 1 ABC's may heal without further treatment, as 2 cases in our study showed.

Radiotherapy was successfully used in the patient with ABC of the spine in our series. Six and a half years after radiotherapy (42 Gray), the patient had a good functional outcome, without neurological signs. Nevertheless, because of the risk of damaging growth plates (5,8) or gonads (3), or of inducing radiation myelopathy (9) or sar-

comatous transformation (5, 9), radiotherapy should be used only in cases of poorly accessible stage 2 or 3 ABC's. Although malignant transformation of ABC has been reported, virtually all such cases represented either radiation-induced sarcomas or telangiectatic osteosarcomas, misdiagnosed as ABC. An exceptional case of true malignant transformation of ABC was reported by Kyriakos and Hardy (11).

Recurrence rates after nonuniform types of treatment have been considerable in previous reports (2, 3, 8, 10, 14), up to 58% (5). In our study, 6 recurrences (38%) were found in 3 cases (19%), after different kinds of treatment. In a clinicopathological study of 105 cases, Ruiter *et al.* (14) found incompleteness of surgical removal and a higher mitotic index (7) or more mitoses per 50 fields (times 750) to be important prognostic factors for recurrence. More radical treatment (cryosurgery) for the cases of ABC with a high risk of recurrence was advised. Campanacci *et al.* (3) suggested different types of surgical therapy depending on activity (aggressive/active or inactive) and radiographic type of the ABC.

Based on the literature and on their experience over the last years (too many recurrences in patients treated with intracapsular resection without adjuvant therapy), the authors advocate cryosurgery as adjuvant therapy to complete intracapsular resection and bone grafting in cases of active and aggressive (stage 2 and 3) ABC. Cryosurgery as adjuvant therapy in the treatment of ABC was first described by Biesecker *et al.* (2), with 1 recurrence in 13 patients. In a study evaluating results of cryosurgery and cementation, Malawer and Dunham (12) reported a recurrence rate of only 4% in a group of 25 patients with aggressive benign tumors (3 ABC's) below 21 years of age. Cryosurgery produces tissue necrosis (2, 12), and thus decreases the risk of recurrence, avoids the need for major resections and preserves adjacent joint function (12). The procedure is inexpensive and effective. Care should be taken to avoid complications, such as freezing of skin and neurovascular structures near the ABC. Secondary fractures may occur after cryosurgery, as in 1 case (patient 2) in our study, due to trabecular necrosis (12). Filling the cavity with bone chips has been

the reconstruction of choice at our institution, although allogeneic bone chips are becoming scarce and costly in the Netherlands, due to the increasingly strict standards for bone donation.

To our knowledge, there are no reports in the literature of functional evaluation, with the most recent MSTS-system, after treatment for ABC. Although Enneking *et al.* (7) suggest using only the functional evaluation rate, we have added a grading system (excellent, good, fair, poor), because we feel that grading is more appealing than rating. The functional results of the patients in this series were excellent or good in all cases.

## CONCLUSIONS

The results of our study indicate that, despite frequent recurrence, the treatment of ABC's is successful and yields an excellent or good functional outcome over the long term. The use of cryosurgery will probably decrease the number of reoperations that are necessary after recurrence.

## REFERENCES

1. Bonakdarpour A., Levy W. M., Aegerter E. Primary and secondary aneurysmal bone cyst: A radiological study of 75 cases. *Radiology*, 1978, 126, 75-83.
2. Biesecker J. L., Marcove R. C., Huvos A. G., Mike V. Aneurysmal bone cysts. A clinicopathologic study of 66 cases. *Cancer*, 1970, 26, 615-625.
3. Campanacci M., Capanna R., Picci P. Unicameral and aneurysmal bone cysts. *Clin. Orthop.*, 1986, 204, 25-36.
4. Campanacci M. Bone and soft tissue tumors. Springer Verlag, Berlin, 1990, pp. 725-751.
5. Clough J. R., Price C. H. G. Aneurysmal bone cyst: Pathogenesis and long term results of treatment. *Clin. Orthop.*, 1973, 97, 52-63.
6. Enneking W. F. A system of staging musculoskeletal neoplasms. *Clin. Orthop.*, 1986, 204, 9-24.
7. Enneking W. F., Dunham W., Gebhardt M. C., Malawar M., Pritchard D. J. A system for the functional evaluation of reconstructive procedures after surgical treatment of tumors of the musculoskeletal system. *Clin. Orthop.*, 1993, 286, 241-246.
8. Farsetti P., Tudisco C., Rosa M., Pentimalli G., Ippolito E. Aneurysmal bone cyst. Long-term follow-up of 20 cases. *Arch. Orthop. Trauma Surg.*, 1990, 109, 221-223.
9. Hay M. C., Paterson D., Taylor T. K. F. Aneurysmal bone cysts of the spine. *J. Bone Joint Surg.*, 1978, 60-B, 406-411.

10. Koskinen E. V. S., Visuri T. I., Holström T., Roukkula M. A. Aneurysmal bone cyst. Evaluation of resection and of curettage in 20 cases. *Clin. Orthop.*, 1976, 118, 136-146.
11. Kyriakos M., Hardy D. Malignant transformation of aneurysmatic bone cyst, with analysis of the literature. *Cancer*, 1991, 68, 1770-1780.
12. Malawer M. M., Dunham W. Cryosurgery and acrylic cementation as surgical adjuvants in the treatment of aggressive (benign) bone tumors. Analysis of 25 patients below the age of 21. *Clin. Orthop.*, 1991, 262, 42-57.
13. Martinez V., Sissons H. A. Aneurysmal bone cyst. A review of 123 cases including primary lesions and those secondary to other bone pathology. *Cancer*, 1988, 61, 2291-2304.
14. Ruitter D. J., van Rijssel T. G., van der Velde E. A. Aneurysmal bone cysts. A clinicopathological study of 105 cases. *Cancer*, 1977, 39, 2231-2239.

### SAMENVATTING

*C. J. M. VAN LOON, R. P. H. VETH, M. PRUSZCZYNSKI, J. A. M. LEMMENS, J. R. VAN HORN.*  
*Lange termijn resultaten en functionele evaluatie van aneurysmatische botcyste.*

Zestien aneurysmatische botcysten (ABC) werden op lange termijn resultaten en functie geevalueerd bij 13 patiënten. De gemiddelde leeftijd ten tijde van de diagnose was 19,8 jaar. De anatomische lokalisaties waren femur (4), tibia (5), humerus (2), fibula (2), en andere (3). Vier ABCs vereisten geen behandeling. Een patiënt kreeg radiotherapie wegens een ABC van de wervelkolom. Elf ABCs werden chirurgisch behandeld,

meestal met intracapsulaire resectie en bot-grafting. Drie patiënten kregen in totaal 6 recidieven, die verdere behandeling behoeften. Bij follow-up (gemiddelde periode: 102 maanden) was de gemiddelde functionele ratio bij 12 patiënten 96%. Deze functionele resultaten werden bij 9 patiënten beoordeeld als excellent, en bij 4 patiënten als goed.

### RÉSUMÉ

*C. J. M. VAN LOON, R. P. H. VETH, M. PRUSZCZYNSKI, J. A. M. LEMMENS, J. R. VAN HORN.*  
*Kyste osseux anévrismal. Résultat à long terme et évolution.*

Les auteurs ont revu 13 patients qui présentaient 16 kystes osseux anévrismaux primitifs pour évaluer les résultats fonctionnels à long terme. L'âge moyen au moment du diagnostic était de 19,8 années. Les localisations anatomiques étaient au fémur (4), au tibia (5), à l'humérus (2), au péroné (2) ou sur d'autres pièces osseuses (3). Quatre kystes n'ont nécessité aucun traitement. Un patient a subi un traitement radiothérapique pour un kyste osseux anévrismal du rachis. Onze lésions ont été traitées chirurgicalement, surtout par résection intracapsulaire et greffe osseuse. Trois patients ont présenté au total 6 récurrences qui ont nécessité un traitement secondaire. Au moment de la révision (suivi moyen: 102 mois), la récupération fonctionnelle moyenne a été évaluée à 96%. Ces résultats fonctionnels ont été jugés excellents chez 9 patients et bons chez les 4 autres.