

# PERSISTENT MEDIAN ARTERY IN CARPAL TUNNEL SYNDROME

M. LISANTI, M. ROSATI, A. PARDI

**Persistent median artery of the forearm and wrist is not very frequently observed. Only a few cases of persistent median artery thrombosis associated with compression of the median nerve in the carpal tunnel have been reported : in these cases symptoms arise acutely and surgery consists in the excision of the thrombosed arterial branch. In a patient with recurrent carpal tunnel syndrome, with a patent median artery and duplication of the median nerve, we performed neurolysis of the nerve and repositioning of the artery to the ulnar side. Electromyography, arteriography and clinical examinations performed six months later showed that irritative phenomena of the median nerve had regressed and the artery was still patent.**

**Keywords :** median artery ; median nerve ; carpal tunnel.  
**Mots-clés :** artère médiano ; nerf médian ; tunnel carpien.

## INTRODUCTION

Carpal tunnel syndrome results mainly from the conflict between container and contents in the carpal tunnel structure, which is caused by :

- factors which reduce the carpal tunnel capacity and
- factors which enlarge the volume of the tunnel contents.

Only in a few cases have abnormal vascularization and persistent median artery in the carpal tunnel been found.

Pecket (5) postulates three different types of median nerve vascularization. The first one shows radial and ulnar arteries converging into the superficial and deep palmar arches, with the median

nerve supplied by the superficial palmar arch and an anastomosis between the two arteries as well as by the forearm muscular branches (70%). The second type shows the radial and ulnar arteries and a median artery that branches out directly from the brachial artery or from the bifurcation of the latter into radial and ulnar arteries. The median artery runs superficial to the median nerve, and at the palm it separates into the finger branches which supply the second, third and fourth fingers ; there is no evidence of either the superficial or deep palmar arches (10%). The third type shows the median artery associated with the superficial palmar arch (20%).

A persistent median artery in a median nerve compression syndrome of the carpal tunnel is rarely found during surgery, as a number of case studies show ; in even rarer cases a persistent median artery is associated with alterations in the development of the median nerve, such as bifurcation of the nerve with the artery lying between the two nerve branches, while the branching off of the nerve without the median artery is far more frequent.

We present a case of median nerve compression at the wrist with nerve bifurcation and persistence of a patent median artery of Pecket's second type.

## CASE REPORT

B. R., 35-year-old woman, showed no evidence of systemic pathology. About 3 years earlier she

---

2nd Orthopedic Department, University of Pisa, Italy.

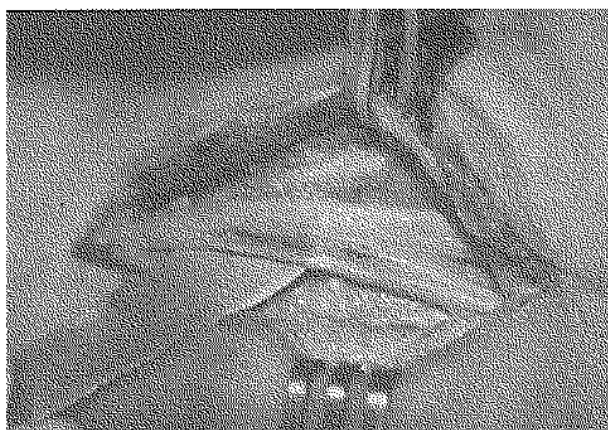
Correspondence and reprints : M. Lisanti, via Risorgimento, 36, 56100 Pisa, Italy.

had undergone neurolysis of the median nerve at both wrists in another institution. The symptoms quickly regressed on the right side while on the left side the sensory and motor symptoms persisted ; she was then admitted to our ward.

Physical examination showed wasting of the thenar eminence of the left hand associated with decreased thumb-index pinch action and inability to grip thin objects. Sensory examination showed hypoesthesia of the first three fingers, a positive Tinel sign at the wrist, irradiation of paresthesias in the median nerve territory and a positive Phalen test. Electromyography confirmed the involvement of the muscles of the left thenar eminence due to compression of the median nerve at the wrist.

We operated under plexus anesthesia with a pneumatic cuff at the base of the arm. Incising in the original scar, we found the healed retinaculum with the median nerve adherent to a vascular formation.

Temporary deflation of the pneumatic cuff showed pulsation and rapid filling of the vessel, thus leading to the diagnosis of a persistent median artery. When moving the artery to the radial side we noticed a deep imprint on the volar border of the nerve which had doubled in size inside the carpal tunnel (fig. 1). Not having at our disposal either a previous angiogram or a doppler sonogram, we did not know whether the radial and ulnar arteries were normal ; thus we decided to save the artery by moving it to the ulnar side.



*Fig. 1.* — After dividing the flexor retinaculum one can note the patent median artery and the duplication of the median nerve in the carpal tunnel.

We isolated it from the nerve by interposing a subcutaneous tissue graft. We subsequently sutured the wound and applied an elastic bandage. After surgery the patient reported that the nocturnal pain and paresthesias had disappeared, and 6 months later electromyography showed nearly full recovery of the nerve. Angiography after 6 months showed the median artery still in place on the ulnar side, patent and with a diameter similar to that of the ulnar artery, conforming with Pecket's (5) second type of forearm and hand vascularization (fig. 2).

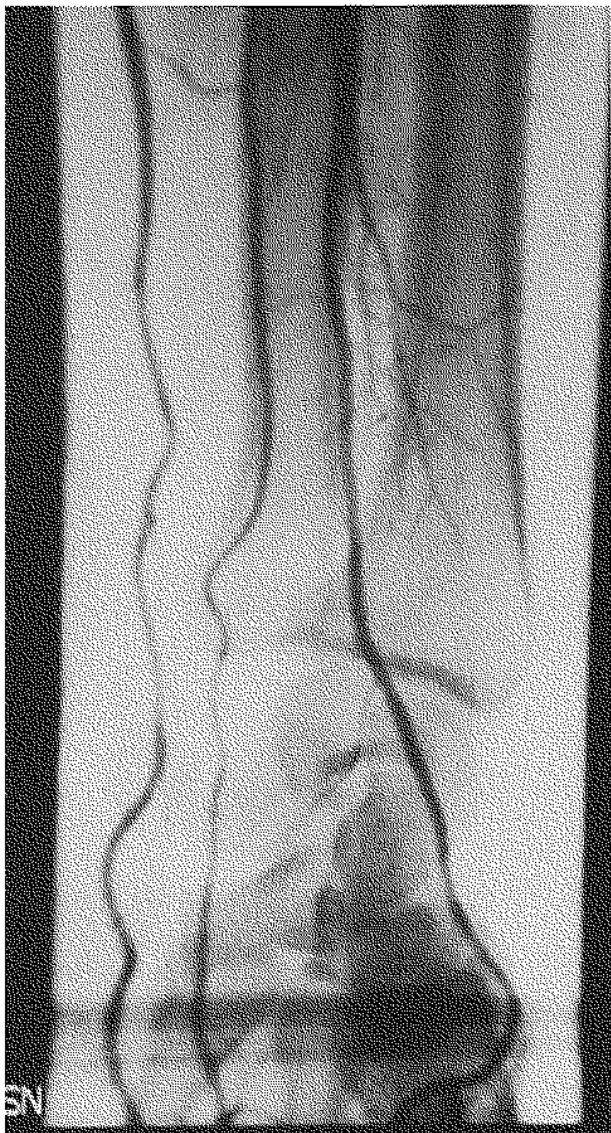## DISCUSSION

The occurrence of the median artery as an embryonic residue of the upper limb vascularization is extremely variable ; it is probably also influenced by racial factors : Srivastava and Panole found the median artery in 1.5% of Indians, while Coleman and McCormack (1) noted it in 3 to 7% in the USA, and in South Africa it is distributed among both White people of European origin and Blacks (27.4% and 27.1% respectively) (1). In Italy it constitutes an uncommon anatomic feature, only 3 cases out of many case reports (3).

The recorded clinical cases of carpal tunnel syndrome which underwent surgery and showed a median artery are generally ones with acute symptomatology, usually following trauma. These include manual laborers, and patients with surgical and histological evidence of median artery thrombosis (3). In our clinical case however, the artery was patent and functional. Only two similar cases have been recorded so far (3).

We did not excise the artery as other authors suggest because after sectioning the healed retinaculum we observed an enlargement of the contents of the tunnel ; besides the median artery was fully patent and we were not aware of the function of the radial and ulnar arteries. After deciding to save the median artery we moved it to the ulnar side because with the passing of time it had caused a clear-cut decubitus on the nerve which made us suspect an extrinsic compression by the artery pulsating on the nerve.

Nerve recovery after surgery, absence of a post-operative vascular crisis and subsequent arterio-



*Fig. 2.* — Arteriography shows a persistent median artery at the elbow and the wrist, with the same diameter as before and with good flow.

graphy showing a patent artery supported our decision.

On the basis of this case and others in the literature, we conclude that when diagnosing a case of median artery in the carpal tunnel the pneumatic cuff should be deflated and :

a) if the artery is thrombosed, this might be the origin of the symptoms. The artery may be removed without causing a further vascular crisis.

b) if the artery is pulsating and is of considerable size, it should be saved and, if necessary, moved from the median nerve, as we did in our case.

We wish to thank Mrs Daniela Bozzi for helping us to translate this paper.

## REFERENCES

1. Coleman S. S., Anson B. J. Arterial patterns in the hand ; based upon a study of 650 specimens. *Surg. Gynaecol. Obstet.*, 1961, 113, 409-413.
2. Henneberg M., George B. J. A further study of the high incidence of the median artery of the forearm in Southern Africa. *J. Anat.*, 1992, 181, 151-154.
3. Lanza F., Russo S., Pacelli M. Sindrome compressiva del nervo mediano al polso da persistenza dell'arteria mediana. *Riv. Chir. Mano*, 1985, 22, 457-459.
4. Levy M., Pauker M. Carpal tunnel syndrome due to thrombosed persisting median artery. *Hand*, 1978, 10, 65-68.
5. Pecket P., Gloobe H., Nathan H. Variations in the arteries of the median nerve with special considerations on the ischemic factor in the carpal tunnel syndrome. *Clin. Orthop.*, 1973, 97, 144-147.
6. Srivastava S. K., Pande B. S. Anomalous pattern of the median artery in the forearm of Indians. *Acta Anat.*, 1990, 138, 193-194.

## SAMENVATTING

*M. LISANTI, M. ROSATI, A. PARDI. Persistierende arteria mediana bij een carpal tunnel syndroom. Over een geval.*

Een persistierende arteria mediana thv. voorarm en pols wordt zelden gezien. Enige gevallen van thrombose van een persistierende arteria mediana geassocieerd aan een compressie van de nervus medianus bij een carpal tunnel werden gerapporteerd : bij deze gevallen treden de klinische tekenen acuut op. De behandeling bestaat uit de chirurgische verwijdering van de gethromboseerde arteria mediana.

De auteurs rapporteren het geval van een recidiverende carpal tunnel syndroom met goede doorgankelijkheid van een persistierende arteria mediana en duplicatie van de nervus medianus ; een neurolyse en een transpositie van de arteria naar ulnair werden uitgevoerd. Na 6 maanden bleken bij klinisch onderzoek en electromyografie de irritatieve verschijnselen veroorzaakt door de aantasting van de nervus medianus geregressieerd. Bij arteriografie was er een goede permeabiliteit van de arteria mediana gezien.

**RÉSUMÉ**

*M. LISANTI, M. ROSATI, A. PARDI. Syndrome du tunnel carpien avec persistance de l'artère médiane. Présentation d'un cas.*

La persistance de l'artère médiane à l'avant-bras et au poignet est rarement observée. On a rapporté quelques cas de thrombose d'une artère médiane persistante associée à la compression du nerf médian dans le tunnel carpien : dans ces cas, les symptômes apparaissent de

façon aiguë et le traitement chirurgical consiste dans l'excision du tronc artériel thrombosé.

Les auteurs rapportent un cas de syndrome du tunnel carpien récidivant, avec persistance d'une artère médiane perméable et duplication du nerf médian ; ils ont effectué une neurolyse et ont repositionné l'artère du côté cubital. Six mois plus tard, l'examen clinique et électromyographique montrait une régression des phénomènes irritatifs dûs à l'atteinte du nerf médian, tandis que l'artériographie montrait que l'artère restait perméable.