

# SKIN CLOSURE IN HIP SURGERY : SUBCUTICULAR VERSUS TRANSDERMAL A PROSPECTIVE RANDOMIZED STUDY

S. A. SAKKA, K. GRAHAM, A. ABDULAH

A randomized parallel-group clinical trial was conducted between March 1991 and December 1993 to compare the effectiveness of subcuticular suture using absorbable material (Dexon) and continuous transdermal blanket suture using nonabsorbable material (silk) in hip surgery. Eighty patients (48 females and 32 males) aged between 19 and 94 years (average 71.4 years) who underwent 97 hip operations were studied. Patients were followed up between 2 and 20 months. The two groups were evaluated with respect to infection rate, patient satisfaction with the scar, extra time and cost in removal of suture and the cosmetic appearance assessed by a plastic surgeon evaluating photos of patients' wounds using a specific scoring method without knowledge of the suturing method used. Five patients died during the study. There was no significant difference in superficial infection rate between the two groups (5% with positive bacteriological swab and 16% requiring extra antibiotics on clinical grounds). No deep infection was suspected in either group. The average score of patient satisfaction with the scar was 9.6/10 in the subcuticular group and 8.68/10 in the continuous mattress with a significant difference between the two groups ( $p < 0.05$ ). Cosmetic evaluation by the plastic surgeon using a 6-category scoring system showed a better cosmetic result in the subcuticular group with a significant difference ( $p < 0.01$ ). An average of 17 minutes of extra nursing time was needed for removal of suture material in the nonabsorbable group in addition to the cost of the suture removal set.

We conclude that absorbable subcuticular skin closure is an effective method and offers some advantages over the traditional transdermal suturing method in hip surgery.

**Keywords :** hip ; wound ; skin ; subcuticular ; transdermal.

**Mots-clés :** hanche ; plaie ; peau ; sous-cutané ; intradermique.

---

## INTRODUCTION

For over 50,000 years physicians have been searching for the ideal suture material and method (9). Recent advances has been achieved with absorbable suture material such as polyglycolic acid and polydioxanone. Closure of skin following surgery protects the underlying traumatized and devitalized structures from skin flora and external contamination. In hip surgery with modern operating techniques and the use of effective prophylactic antibiotics the infection rate is kept to a minimum (8). The choice of suture material has become increasingly influenced by cosmetic outcome, patients' preference and economic factors. Fasting and Bjerkreim (3) reported the advantages of subcuticular suture in pediatric orthopedics. In general orthopedic surgery Stockley and Elson (17) compared staples and nylon sutures while Clayer and Southwood (2) compared staples with nonabsorbable subcuticular prolene. To complete the comparative triangular analysis we set up this study to compare skin closure using subcuticular absorbable suture material (Dexon) with continuous

---

Department of Orthopaedic Surgery, Bedford Hospital, England.

Correspondence and reprints : S. A. Sakka, Scoliosis Unit, Royal National Orthopaedic Hospital, Brockley Hill, Stanmore, Middlesex, United Kingdom.

blanket suture using nonabsorbable material (silk) in hip surgery.

### PATIENTS AND METHODS

Patients who were admitted for elective primary total hip replacement or with a fractured neck of the femur had randomized wound closure either by subcuticular suturing using absorbable material (Dexon 3/0) completed with "steristrips" or by percutaneous transdermal continuous running suture using nonabsorbable material (silk 3/0). Deep layer closure including fat was identical in both groups. The operations were performed by two surgeons (S.A.S. and A.A.). Eighty patients (48 females and 32 males) with 94 hip operations were randomized. They were aged between 19 and 94 years (mean 71.4). Five patients who died during the study and one who underwent revision surgery were excluded from the study. Two patients with diabetes mellitus and one with eczema were included in the study. The skin was prepared with Betadine. No diathermy was used near the skin edges. Three doses of cefuroxime, 1.5g, 0.75, and 0.75, were given intravenously over 24 hours as a prophylactic antibiotic. In patients who were sensitive to penicillin, erythromycin was given as an alternative. The wound was inspected at one and two weeks and swabs for microbiological culture were taken when clinically indicated. All patients who received antibiotics from their general practitioners (GP) for suspected wound infection were noted. Similarly those who received antibiotics during their hospital stay either on clinical grounds or because of positive microbiological swab cultures were documented. The silk sutures were removed at two weeks. The average time required for the nursing staff to perform the task of removing the sutures was noted independently by a senior staff nurse. At a final follow-up (minimum of 8 weeks) the scar was inspected by one surgeon (S.A.S.) and the patients were asked to view their scar and score their satisfaction with the outcome on a scale of one to ten. At this stage two coloured clinical photographs were taken by the assessing surgeon and later reviewed and assessed by a plastic surgeon (K. G.). Details of the operation were not given to the plastic surgeon. The assessments were made according to a prearranged well-defined scoring system (table I).

### RESULTS

Five wounds, two in the subcuticular and three in the transdermal group had positive microbio-

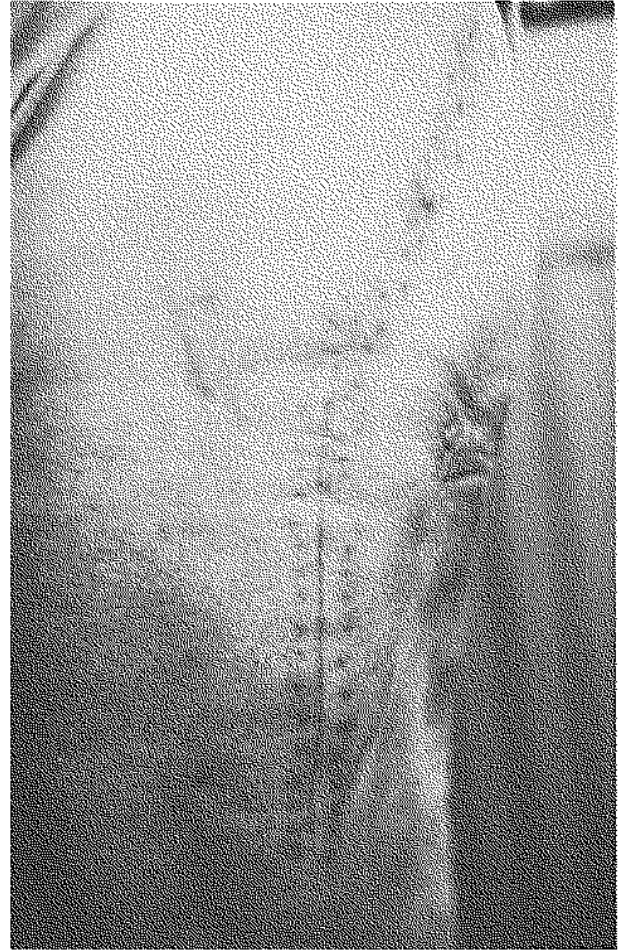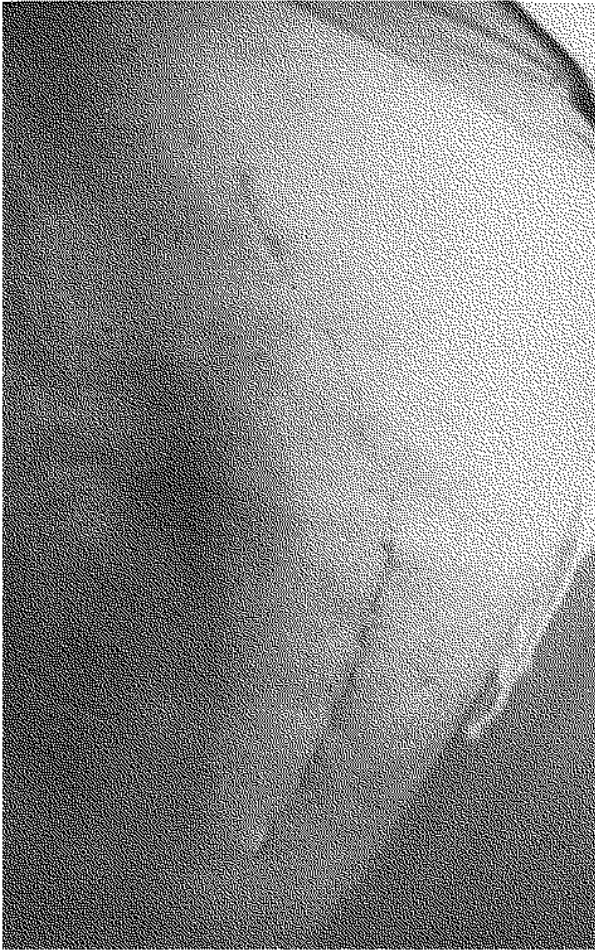
Table I. — Criteria and scoring system used in the cosmetic assessment

1. Width of the scar	
Not spread	1
Mildly "	2
Moderately spread	3
Widely "	4
2. Stretch marks	
None	0
Present mild	1
Moderate	2
Severe	3
3. Redness	
None	1
Present mild	2
Moderate	3
Severe	4
4. Thickness	
None	1
Present mild	2
Moderate	3
Severe	4
5. Pigmentation	
None	0
Present mild	1
Moderate	2
Severe	3
6. Puckering	
None	1
Present mild	2
Moderate	3
Severe	4
Maximum score 22 (worst), Minimum score 4 (best)	

logical wound swabs within two weeks (5%). Sixteen patients (16 wounds), 7 in the subcuticular and 9 in the transdermal group, received extra antibiotics on clinical grounds in relation to their wounds (16%). There was no significant difference ( $P > 0.05$ ) in infection rate between the two categories. No deep infection was suspected in either of the two groups during the study.

The average of patients' scores in the subcuticular group was 9.60 and 8.68 in the continuous transdermal group. There was a significant difference in the score between the two groups ( $p < 0.05$ ).

Independent assessment by the plastic surgeon showed a better cosmetic outcome in the subcuticular group with a score range of 4 to 6 (mean 5)



*Fig. 1.* — Cosmetic appearance of both methods in the same patient after bilateral hip replacement  
 a. Subcuticular with linear scar.  
 b. Transdermal with cross-hatching scar.

in comparison to the transdermal group with a range of 4 to 9 (mean 6.5). There was a significant difference between the two groups with a  $p$  value of  $< 0.01$ .

The average time taken by the nursing staff for removal of suture material in the continuous percutaneous group was 17 minutes.

All data were analyzed using either Chi-square or Wilcoxon test for significance.

### DISCUSSION

Prevention of infection following hip surgery is an important aim. Effective skin closure is a necessary factor in the prevention of infection.

Halsted was the first surgeon to introduce subcuticular suture in 1887 in order to reduce infection in his procedure for the repair of inguinal hernia, but it was J. S. Davis who was the first surgeon to see its full potential for wound esthetics (4). In 1977 Polglase and Nayaman (13) showed in experimental animals that subcuticular suture using Dexon is associated with a lower rate of wound infection when compared with those following transdermal sutures using silk. Comparative studies of different methods and suture materials showing the various advantages of subcuticular suture over transdermal suture and metal clips are reported in different disciplines of surgery (1, 5, 6, 7, 10, 12, 16, 18).

In orthopedics and trauma surgery the number of studies on wound closure is rather limited. Stockley and Elson (17) compared staples and nylon sutures while Clayer and Southwood (2) compared staples with nonabsorbable subcuticular prolene. In a postal questionnaire sent to a hundred consultant orthopedic surgeons in the U.K. (78% reply rate), we found that a third use staples, a third subcuticular and the rest transdermal nonabsorbable sutures (14). Prevention of infection following hip surgery is an important aim and hence effective skin closure is necessary. Clayer and Southwood (2) found no significant difference in infection rate between staple and subcuticular nonabsorbable prolene suture. Similarly Stockley and Elson (17) reported no difference in infection rate between staples and interrupted vertical mattress suture using nylon. In our study again we found no difference between the two groups. We attribute this to modern operating rooms, surgical aseptic technique and the use of effective prophylactic antibiotics.

Subcuticular suturing provides a better healing environment as no skin interruption is caused by the suturing tool (needle or clip), and better blood flow is maintained to the skin than when either the staples or the transcutaneous suturing method is used (19). Most of the studies prove inadequate in the cosmetic assessment of the suturing method in terms of the short follow-up before the maturation of scar and the lack of a thorough, consistent and objective method of assessment. Cosmetic assessment can be quantified by scoring (6). Bearing this in mind, we devised a scoring system with six well-defined criteria (table I).

Independent assessment by a plastic surgeon showed better cosmetic results with the subcuticular method. Furthermore patients endorsed this finding with better satisfaction with the scar in the subcuticular group. We accept that ideally the final assessment of the scar should be done uniformly more than a year after surgery to allow the scar to contract and fully mature. Unfortunately this was not possible to achieve in our clinical setting. Several studies showed patients' preference of subcuticular suturing to both transcutaneous and staples with special reference to pain at the time

of removal of suture material or metal clips (1, 3, 7, 10, 17). We found this difficult to evaluate objectively and therefore limited our study to the economic effect of removal of suture material. Extra nursing time and material are required with transdermal nonabsorbable sutures. Delay of patient discharge until suture material is removed or the need for an extra visit to the GP / OPD has been reported (9). This was noted in some of our patients but not quantifiably measured.

We conclude that absorbable subcuticular skin closure in hip surgery is an effective method and offers some advantages over the traditional transdermal suturing method.

#### *Acknowledgement*

We would like to thank T. B. H. Riley, and R. Rawlins for allowing us to conduct this trial on their patients. We also would like to thank the nursing staff and the audit department for their help in conducting this study.

#### **REFERENCES**

1. Cassie A. B., Chatterjee A. K., Haworth J. M. Pain quantum and wound healing: a comparison of interrupted inversion PDS and standard nylon sutures in abdominal skin closure. *Ann. R. Coll. Surg. Eng.*, 1988, 70, 339-342.
2. Clayer M., Southwood R. T. Comparative study of skin closure in hip surgery. *Aust. N. Z. J. Surg.*, 1991, 61, 363-365.
3. Fasting O. J., Bjerkreim I. Polyglycolic acid, Dexon subcuticular suture in paediatric orthopaedic surgery. *Acta Chir Scand.*, 1981, 147, 509-511.
4. Fisher G. T., Fisher J. B., Stark R. B. Origin of the use of subcuticular sutures. *Ann. Plast. Surg.*, 1980, 4, 144-148.
5. Glough J. V., Alexander-Williams J. Surgical and economic advantages of polyglycolic-acid suture material in skin closure. *Lancet*, 1975, 1, 194-195.
6. Harvey C. F., Hume C. J. A prospective trial of skin staples and sutures in skin closure. *Ir. J. Med. Sci.*, 1986, 155, 194-196.
7. Herron J. Skin closure with subcuticular polyglycolic acid sutures. *Med. J. Australia*, 1974, 2, 535-6.
8. Lober C. W., Fenske N. A. Suture material for closing the skin and subcutaneous tissues. *Aesth. Plast. Surg.*, 1986, 10, 245-247.
9. Mackenzie D. The history of sutures. *J. Dermatol. Surg.*, 1976, 2, 61.
10. MacKinnon A. E., Brown S. Skin closure with poly-

- glycolic acid (Dexon). Postgrad. Med. J., 1978, 54, 384-385.
11. Narayan A., Kumar S., Singh M. P., Shrama L. K. Early discharge after operation. Br. J. Surg., 1993, 80, 1587-1589.
  12. Onywauanyi O. N., Evbuomwan I. Skin closure during appendectomy : a controlled clinical trial of subcuticular and interrupted transdermal techniques. J. R. Coll. Surg. Edinb., 1990, 35, 353-355.
  13. Polglase A., Nayaman J. A comparison of the incidence of wound infection following the use of percutaneous and subcuticular sutures : An experimental study. Aust. N. Z. J. Surg., 1977, 47, 3.
  14. Sakka S. A., Howse J. P. Trends in wound closure in orthopedics. (Unpublished data).
  15. Sanders R. J. Subcuticular skin closure—description of technique. Dermatol. Surg., 1975, 1, 61-64.
  16. Stillman R. M., Bella F. J., Seligman S. J. Skin wound closure. The effect of various wound closure methods on susceptibility to infection. Arch. Surg., 1980, 115, 674-675.
  17. Stockley I., Elson R. A. Skin closure using staples and nylon sutures : A comparison of results. Ann. R. Coll. Surg. Eng., 1987, 70, 226-228.
  18. Winn H. R., Jane J. A., Rodeheaver G., Edgerton M. T., Edlich R. F. Influence of subcuticular sutures on scar formation. Am. J. Surg., 1977, 133, 257-259.
  19. Zografos G. C., Martis K., Morris D. L. Laser Doppler flowmetry in evaluation of cutaneous wound blood flow using various suturing techniques. Ann. of Surg., 1992, 215, 266-268.

### SAMENVATTING

*S. A. SAKKA, K. GRAHAM, A. ABDULAH. Huid-hechting in heupchirurgie : subcutaan versus intradermisch : prospectieve gerandomiseerde studie.*

Een gerandomiseerde studie werd uitgevoerd van maart 1991 tot december 1993 ter vergelijking van de hechting van de huid door middel van een resorberend materiaal (Dexon), aangevuld met „Steristrips”, en de doorlopende intradermische hechting met niet-resorberend materiaal (zijde), in heupchirurgie.

Tachtig patiënten (48 vrouwen en 32 mannen) van 19 tot 94, (gemiddelde van 71,4 jaar), ondergingen 97 heupoperaties.

De patiënten werden gevolgd tussen de tweede en de twintigste post-operatieve maand. De twee groepen werden geëvalueerd in verband met het aantal infecties, de voldoening van de patiënt over zijn litteken, tijd en kostprijs van verwijdering van de hechting en het esthetisch aspect van het litteken geëvalueerd door een

plastisch chirurg die de foto's beoordeelde volgens zijn specifieke evaluatietechniek. Vijf patiënten overleden tijdens deze studie. Er was geen relevant verschil tussen de twee groepen wat betreft de oppervlakkige infecties (5% met positieve bacteriologie en 16% waarvoor extra antibiotica, op klinische indicatie, in aanmerking kwamen). In geen van beide groepen werden diepe infecties gezien.

De gemiddelde score voor de voldoening van patiënt over zijn litteken was 9,6/10 in de subcutane groep en 8,68/10 in de doorlopende hechting groep, met een relevant verschil tussen de twee groepen ( $P < 0,05$ ). De esthetische evaluatie door de plastische chirurg, die zijn eigen criteria gebruikte, toonde een beter cosmetisch resultaat in de subcutane groep met een relevant verschil ( $P < 0,01$ ). De verwijdering van de hechting in de niet-resorbeerbare groep vergde 17 minuten naast de kostprijs van de „set”.

De auteurs konkluderen dat een resorbeerbare subcutane hechting, aangevuld met „Steristrips”, een betrouwbare en doelmatige techniek is en voordelen biedt tov. de traditionele intradermische hechting in heupchirurgie.

### RÉSUMÉ

*S. A. SAKKA, K. GRAHAM, A. ABDULAH. Suture cutanée en chirurgie de la hanche : Comparaison d'une suture sous-cutanée et d'une suture intradermique. Étude prospective randomisée.*

Une étude randomisée fut menée de mars 1991 à décembre 1993 pour comparer l'efficacité d'une suture sous-cutanée avec matériel résorbable (Dexon) complétée par «Steristrips», et la suture intradermique utilisant un matériel non-résorbable (soie) en chirurgie de la hanche.

Quatre vingts patients (48 femmes et 32 hommes) âgés de 19 à 94 ans, (moyenne de 71,4 ans) subirent 97 opérations. Le recul est de 2 à 20 mois.

Les deux groupes furent évalués considérant le taux d'infection, la satisfaction du patient quant à la cicatrice, le temps et le prix de l'ablation de la suture et l'aspect esthétique évalué par un chirurgien plasticien se basant sur ses critères spécifiques pour l'examen des photographies des cicatrices. Cinq malades décédèrent pendant l'étude. Il n'y eut pas de différence significative en ce qui concerne le taux d'infection entre les deux groupes (5% avec culture positive et 16% pour lesquels un traitement antibiotique complémentaire sur indication clinique fut instauré). On ne nota aucune infection

profonde dans aucun de deux groupes. Le taux moyen de satisfaction des malades était de 9,6/10 pour le groupe sous-cutané et de 8,68/10 pour le groupe intradermique, avec une différence significative entre les deux groupes ( $P < 0,05$ ). L'évaluation cosmétique par un chirurgien plasticien utilisant une échelle de 6 degrés montre un meilleur aspect cosmétique du groupe sous-cutané avec une différence significative ( $P < 0,01$ ). L'abla-

tion du matériel de suture prit 17 minutes de soins en moyenne plus le prix du «set».

Les auteurs concluent qu'en chirurgie de la hanche une suture sous-cutanée resorbable, complétée par «Stéristrips», est une méthode efficace et fiable et présente des avantages par rapport à la suture intradermique classique.