

RESULTS OF EXCISION OF THE INTERDIGITAL NERVE IN THE TREATMENT OF MORTON'S METATARSALGIA

G. DEREYMAEKER, I. SCHROVEN, A. STEENWERCKX, P. STUER

Thirty-one patients (thirty-two feet) had excision of the interdigital nerve as treatment of their Morton's metatarsalgia. A longitudinal dorsal incision was used in all cases. Twenty-five out of 32 cases had a macroscopically visible neuroma, and only two had no evidence of a neuroma on histological examination. All thirty-two patients were available for follow-up at an average of 44.7 months (range 14 to 71 months) post-operatively. Eighty-one per cent of the patients had a good or excellent result, 12.5% had a fair result, with residual pain and some restriction of activities, and 6.5% had no improvement after their operation. It is noteworthy that 19 patients (60%) benefitted from wearing adapted shoes or inner soles for a considerable time after the operation. Even at final follow-up, only 10 patients (30%) had no restrictions in the choice of their shoes.

Keywords : interdigital nerve ; Morton's metatarsalgia.
Mots-clés : nerf interdigital ; métatarsalgie de Morton.

INTRODUCTION

Since the first description by Durlacher (2) of what was later known as Morton's neuroma (9), the rate of effectiveness of operative intervention has been reported to be around the 80% mark. However, some authors report that up to one third of histological specimens show no abnormal findings (10). The figures in our series suggest a similar success rate, but there were only two cases where no histological evidence of a neuroma was found.

Various etiologies have been suggested, but the most generally accepted is an entrapment neuropathy of the interdigital nerve causing a neuroma. Electrodiagnostic tests show a high false-positive and false-negative rate, and M.R.I. resolution

will have to improve to be helpful in cases where the clinical presentation is questionable. So, the diagnosis of the interdigital neuroma remains based on subjective clinical evaluation (6, 9).

Diagnostic criteria include pain in the fore-foot region, radiating into the toes and aggravated while walking in shoes. This pain is usually characterized as burning in nature. Palpation locates the tenderness to the affected webspace. A Mulder's click usually reproduces the patient's symptoms.

MATERIALS AND METHODS

From February 1988 to December 1992, 31 patients underwent operations for Morton's neuroma ; these included 24 women and 7 men. All of the patients complained of pain and tenderness in a single metatarsal interspace, radiating into the relevant toes.

All patients were initially treated conservatively with an innersole, with a metatarsal pad or an insole with metatarsal pad in comfortable shoes. Before performing surgery, from one to three steroid infiltrations were given in combination with use of an insole. The patient was offered an operative intervention only in the case of failure of conservative treatment ; this occurred only in about 30% of all patients with the diagnosis of Morton's neuroma.

All surgically-treated patients were available for follow-up and each patient was carefully questioned regarding the presence of any residual symptoms. In particular residual pain, scar tenderness, return to work, and the need for further treatment were evaluated.

University Hospital Pellenberg, Department of Orthopedics, K.U. Leuven, B-3212 Pellenberg, Belgium.

Correspondence and reprints : G. Dereymaeker.

Patients were judged to have an excellent result if they were pain free, had no restrictions in activities and only minor restrictions in footwear. Patients were judged to have a good result if they had only mild pain, minor restrictions in activities and some restrictions in footwear. Patients were classified as having a fair result if they had significant residual pain, restrictions in activities and significant restrictions in footwear. A poor result was seen as no improvement of, or deterioration in preoperative symptoms.

Operative procedure

A longitudinal dorsal incision is made in the relevant web space, and deepened directly in line with the interspace until the metatarsal heads are identified. The intermetatarsal ligament is carefully divided, bringing the neurovascular structures into view. After identification of the neuroma (fig. 1), the two distal branches of the nerve are sectioned distally and then the nerve is dissected free and sectioned out as far proximally as possible so that at least 3 cm of the nerve is removed proximal to the neuroma, as a number of plantar branches can branch off up to 3 cm proximal to the bifurcation and these can be a cause of pain due to impingement. After a sufficiently proximal resection, the nerve can retract into the intrinsic muscles, away from the weight-bearing area of the forefoot (5, 7).

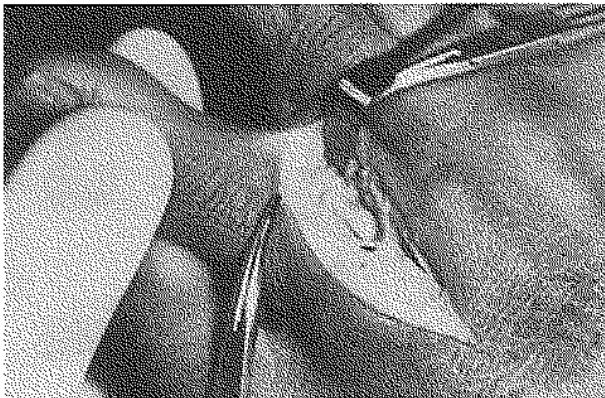

Fig. 1. — Exposure of the digital nerve.

RESULTS

A follow-up of patients was done on average 3 years, 9 months after the surgical intervention. Neuromas were removed from the right foot in 17 cases, from the left foot in 14 cases and from

both feet in one case. The third web space was the source of the neuroma in 23 cases, the second web space in 8 cases, and the fourth webspace in one case. Symptoms had been present for an average of 31 months (range 3 to 168). At final follow-up 19 (60%) were free from pain, 7 (22%) reported substantial improvement of their pain and 6 (18%) had only minor improvement of their pain. None of the patients were made worse by the operation.

Twenty-three patients (72%) had no restrictions of activities, including sports. Eight (25%) had some restriction of activities, but not severe enough to interfere with normal daily activities, and only one patient (3%) reported being unable to return to work because of residual pain in his foot; this patient developed his Morton's metatarsalgia in a work-related accident and is currently still involved in litigation against his former employer.

Restrictions in footwear were common. Initially, all patients experienced difficulties in wearing narrow shoes, but after three months, most patients had noticed an improvement. At final follow-up, only 10 patients (31%) had no trouble at all in wearing any style of shoe they wished, 14 (44%) had some difficulties in wearing narrow shoes and 8 patients (25%) were unable to wear narrow fashionable shoes.

None of the patients developed a postoperative infection or a hypertrophic scar. All patients, without exception, expressed satisfaction with the cosmetic result of the scar and no patients complained of scar tenderness.

There were two patients in whom biopsy did not confirm the presence of an interdigital neuroma. One underwent re-exploration with a subsequent good result, the other one had only a fair result at final follow-up.

Overall, 23 patients (72%) had an excellent result following surgery, 3 (9%) had a good result, 4 (12.5%) had a fair result and only 2 (6.5%) felt they had not been improved and required further surgery.

HISTOLOGICAL FINDINGS

In 25 cases (78%) there was a microscopically visible interdigital neuroma. Microscopic exami-

nation confirmed that it could be characterized as a primary interdigital neuroma.

The histological findings have been well described (4) and are distinct from those of other neuromas. In an interdigital neuroma, there is thickening and hyalinization of the walls of the epineural and endoneural vessels in addition to a variable degeneration of the myelinated fibers, thickening and fibrosis of the epineurium and perineurium (fig. 2).

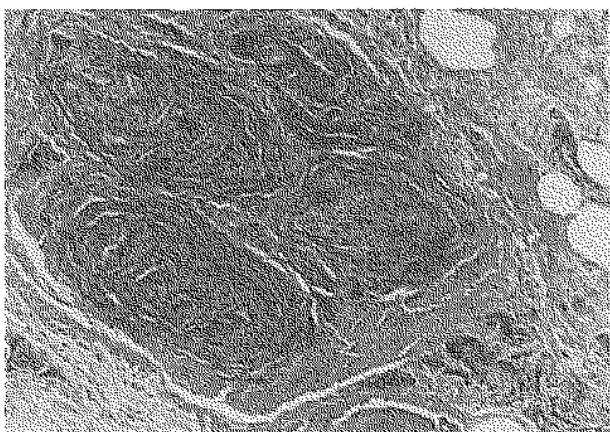


Fig. 2. — Histopathology of Morton's neuroma : degeneration of the myelinated fibers, thickening and fibrosis of the epineurium and perineurium.

Five cases (16%) showed no macroscopic evidence of an interdigital neuroma, but did show the characteristic histological findings of a primary interdigital neuroma. In two cases, there was no histological evidence of an interdigital neuroma : one specimen revealed the presence of a section of normal interdigital nerve and, the other had a biopsy specimen that showed a small artery.

DISCUSSION

Although a number of papers have been published since the original description by Durlacher (2), most have concentrated on methods of surgical treatment, etiology or pathophysiology. Relatively few have reported the results of surgical treatment and no such article has appeared in the last five years. Johnson *et al.* (5) reported the results of surgical treatment of recurrent interdigital neuromas in 1988, but the last significant

report on the results of surgical treatment of Morton's neuroma dates from 1983 (7).

Bradley *et al.* (1) did not mention the surgical approach. Mann and Reynolds preferred excision of the neuroma through a dorsal incision to avoid a painful hypertrophic scar over the weight-bearing area of the forefoot (7) and for this same reason, we chose the dorsal approach. For excision of a primary neuroma, this provides more than adequate visualization of the relevant neurovascular structures and permits adequate dissection. In addition, this dorsal approach causes no problems with wound healing or scar tenderness.

Vachon *et al.* (10) report that up to a third of resected "diseased" digital nerves were histologically normal, but in our series only 2 (6%) showed no histological evidence of a Morton's neuroma. We believe that a meticulous preoperative history, examination and well-performed conservative treatment are important in decision making for surgical treatment in this condition. We have not found a preoperative ultrasound to be an essential part of the preoperative investigation, but recognize that it may be useful in selected cases (8).

In our series, there was a clear predisposition for the third web space. Several explanations have been offered. The most common explanations are that the mobility between the third and the fourth metatarsal is increased compared to the mobility between the other metatarsals, as the medial three metatarsals are fixed to the cuneiforms and the fourth and fifth metatarsals are fixed to the cuboid. Also, because the third interdigital nerve is formed by branches from the medial plantar nerve and the lateral plantar nerve, it is slightly larger in size than its fellows in the other web spaces.

Postoperative problems with footwear have been mentioned in the past (5), but we believe that not enough emphasis has been placed on the fact that, even after an apparently successful procedure with good pain relief, the majority of patients have problems with wearing normal shoes in the first three to six months after their operation ; and even after an average follow-up of nearly four years, it is noteworthy that only a third of our patients experienced no restrictions in wearing shoes of any kind.

Overall, our results show a satisfactory outcome in 81% of cases, a figure which confirms previous reports in the literature.

REFERENCES

1. Bradley N., Müller W. A., Evans J. P. Plantar neuroma. Analysis of results following surgical excision in 145 patients. *S. Med. J.*, 1976, 69, 835.
2. Durlacher L. A treatise on corns, bunions, the diseases of nails, and the general management of the feet. Philadelphia, Lea and Febiger, 1845, p. 52.
3. Gauthier G. Thomas Morton's disease : A nerve entrapment syndrome. A new surgical technique. *Clin. Orthop.*, 1987, 142, 90-93.
4. Graham C. E., Graham D. M. Morton's neuroma : a microscopic evaluation. *Foot and Ankle*, 1984, 5, 150-153.
5. Johnson J. E., Johnson K. A., Krishnan Unni K. Persistent pain after excision of an interdigital neuroma, Results of reoperations. *J. Bone Joint Surg.*, 1988, 70-A, 651-657.
6. Lelièvre J., Lelièvre J. F. Pathologie du pied. 5th Ed. Névrome plantaire. Masson, Paris, 1981, pp. 557-560.
7. Mann R. A., Reynolds J. A. Interdigital neuroma — A critical analysis. *Foot and Ankle*, 1983, 3, 238-243.
8. Redd R. A., Peters V. J., Emery S. F., Branch H. M., Rifkin M. D. Morton neuroma : Sonographic evaluation. *Radiology*, 1989, 171, 415-417.
9. Regnaud B. Le Pied. Névralgie de Thomas G. Morton. Springer-Verlag, Berlin, 1986, pp. 550-553.
10. Vachon P., Lemay M., Bouchard H. L. Etude pathologique du névrôme de Morton. *Can. J. Surg.*, 1991, 34, 356-359.

SAMENVATTING

G. DEREYMAEKER, I. SCHROVEN, A. STEENWERCKX, P. STUER. Resultaten van de excisie van de interdigitale zenuw bij de behandeling van Morton metatarsalgie.

Als behandeling van een Morton metatarsalgie ondergingen 31 patiënten een heelkundige excisie van de

interdigitale zenuw via een longitudinale dorsale toegangsweg.

De gemiddelde follow-up bedroeg 44,7 maand. Eenenachtig % bestempelt het resultaat als goed tot uitstekend ; bij 12,5% werd een middelmatig resultaat bekomen met nog residuele hinder en een zekere functionele weerslag ; 6,5% vermeldde geen verbetering in het klachtenpatroon.

Gedurende de postoperatieve periode maakte 60% van de patiënten gebruik van aangepast schoeisel of een steunzool. Zelfs tijdens de laatste controle vermeldden slechts 10 patiënten (30%) geen enkele beperking bij de keuze van hun schoeisel.

RÉSUMÉ

G. DEREYMAEKER, I. SCHROVEN, A. STEENWERCKX, P. STUER. Résultats de l'excision du nerf interdigital dans le traitement de la métatarsalgie de Morton.

Trente et un patients (trente deux pieds), ont subi l'excision d'un nerf interdigital comme traitement d'une métatarsalgie de Morton. Dans tous les cas, un abord longitudinal dorsal fut employé. Lors de l'intervention, le névrôme était bien visible dans 25 des 32 cas. L'examen histologique a confirmé la nature du névrôme, excepté dans deux cas.

Tous les patients ont été ré-examinés avec un recul moyen de 44,7 mois (variant de 14 à 71 mois). Dans 81% des cas, le résultat était excellent ; 12,5% des patients se plaignaient encore d'une douleur résiduelle avec restriction fonctionnelle ; dans 6,5% des cas, il n'y avait aucune amélioration.

Après l'opération, 19 patients (60%), ont utilisé des chaussures adaptées ou des semelles. Au moment de la dernière visite, 10 patients (30%) seulement étaient capables de porter n'importe quelle chaussure.