

# BILATERAL STRESS-FRACTURE OF THE CALCANEAL TUBERCLE

A. ROSTED, J. BANG, H. SVEND-HANSEN

**A case of bilateral stress fracture of the calcaneal tubercle (beak-fractures) in a 67-year-old woman is presented. The pathogenesis and treatment are discussed, followed by some general considerations on stress fractures.**

**Keywords :** stress fracture ; calcaneal tubercle avulsion ; beak fracture ; bilateral calcaneal fracture.

**Mots-clés :** fracture de fatigue ; avulsion de la tubérosité du calcanéum ; fracture bilatérale du calcanéum.

---

Avulsion fracture of the calcaneus, with upward displacement of large fragments (beak fractures) is rare. Only 1 to 3% of all calcaneus fractures (2, 3, 7, 8) are avulsion fractures. The main causes are direct trauma (e.g. traffic accidents) (2, 7), falls from stairs and chairs (2, 7, 9) or even gunshot wounds (3).

A number of stress fractures of the calcaneal tubercle were documented among marching soldiers during the Second World War, who also had many of the most common stress fracture, the march fracture of the second metatarsal bone (1, 6).

We report a case of bilateral avulsion fracture of the calcaneal tubercle. The pathogenesis is comparable with stress fracture.

## CASE

A 67-year-old woman felt pain in both her heels, corresponding to the attachment of the Achilles tendons, during a 3-week trekking holiday in Turkey. The pain gradually intensified, after 2 weeks

the pain was excruciating, and the last week the patient remained recumbent. The patient had not suffered from any trauma or any other illness. She used new low-heeled shoes, bought especially for the trip ; they were well-fitting and comfortable.

After her return, the pain persisted for 2 weeks, despite reduced physical activity. A radiographic examination of both calcanei was undertaken, but revealed nothing abnormal.

The day following this radiographic examination, the patient felt sudden simultaneous cracks in her heels while walking. Intense pain followed, and she was unable to walk.

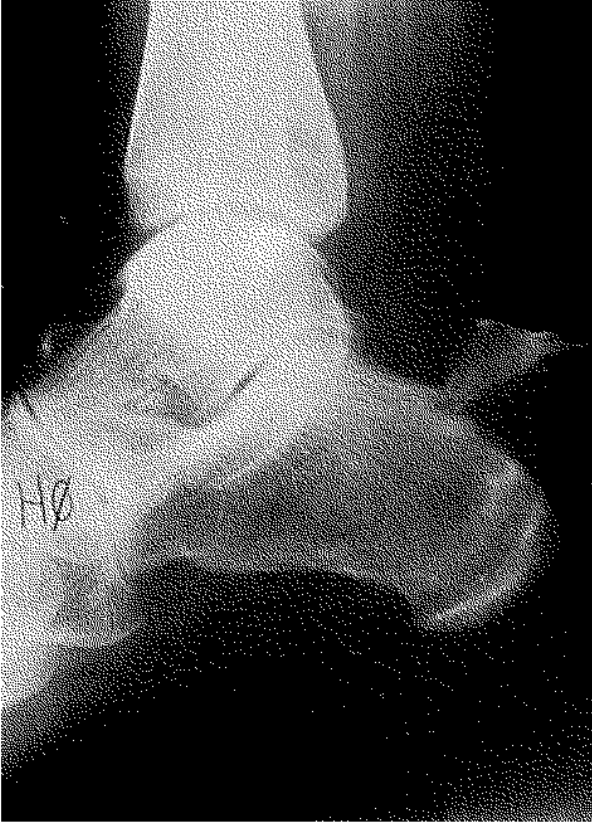On admission to the emergency room new radiographs showed bilateral symmetric avulsions of the calcaneal tubercles, corresponding to the Achilles tendon insertion, as seen in fig. 1a (right foot) and 1b (left foot). Clinical examination revealed swelling, bruising in both heel regions and lack of active plantarflexion.

The bilateral avulsion fractures were reduced and fixed with AO-cancellous screws, as seen in fig. 2a (right foot) and 2b (left foot). The patient was treated with plaster casts for 6 weeks, and was then referred to the physiotherapist for treatment. At the final examination 3 months after the operation the patient had regained full motion of both ankles without any subjective pain or instability.

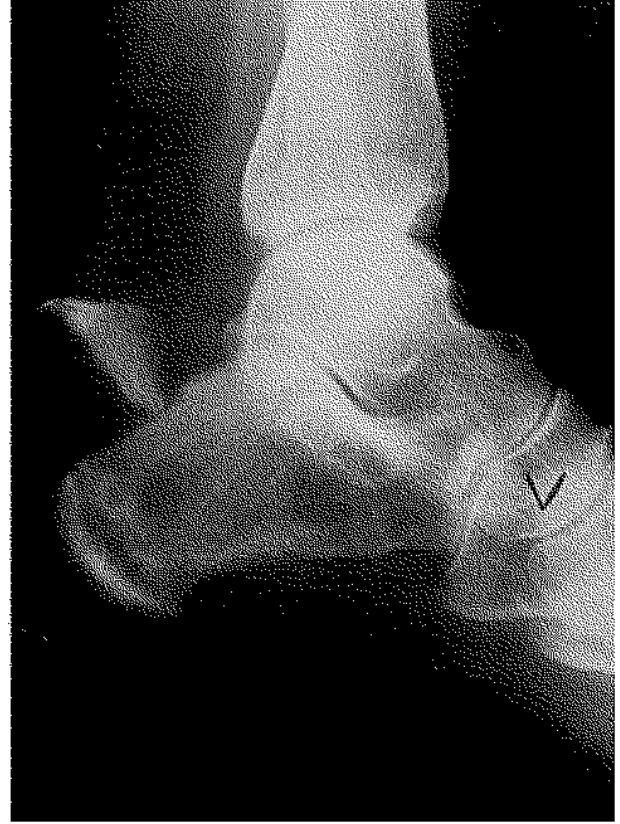
---

Dept. of Orthopedic Surgery, Sundby Hospital, dk-2300 Sundby, Copenhagen, Denmark.

Correspondence and reprints : J. Bang, Rugvej 10, dk-2700 Brønshøj, Denmark.

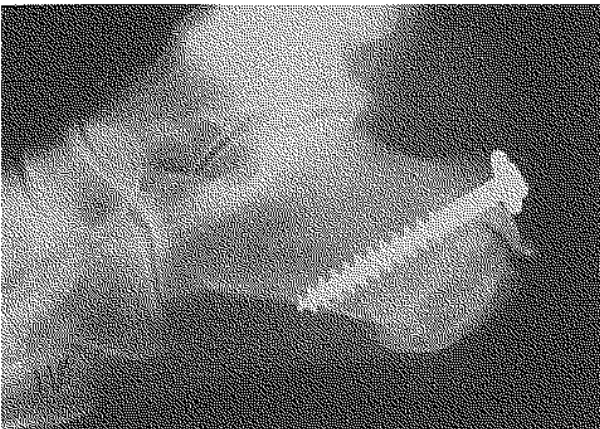


*Fig. 1a.* — Right foot.

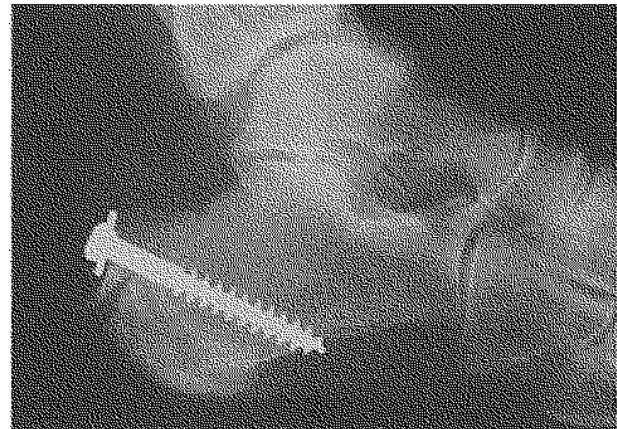


*Fig. 1b.* — Left foot.

*Fig. 1.* — Xrays on admission to the emergency room showing bilateral symmetric avulsions with upward displacement of the calcaneal tubercles. Note the area with osteocondensation in the calcaneus ; this might represent a healing stress fracture. Calcanei are osteoporotic.



*Fig. 2a.* — Right foot.



*Fig. 2b.* — Left foot.

*Fig. 2.* — Postoperative xrays showing reduction and internal fixation.

## DISCUSSION

Stress fractures occur gradually as the result of repeated continuous strain on the bones, without any trauma. In the present case the pathogenesis was assumed to be the constant and repeated stress on the calcaneal tubercles through the insertion of the Achilles tendon, causing microfractures in the cancellous bone (6). Also the existing osteoporosis as seen on the xrays, as well as the low-heeled shoes are supposed to have been predisposing factors.

In cases of avulsions with displacement, reduction and fixation is required, but in cases of incomplete fractures conservative treatment with a plaster cast is proposed.

Stress fractures are difficult to diagnose with routine radiographic examinations. The signs are fissures, callus formation or focal bone sclerosis. Bone scintigraphy reveals enhanced activity, and CT- or MRI-scanning may be a useful aid to the diagnosis (4, 5). The symptoms develop slowly and gradually. Clinical examination reveals localized pain, swelling and tenderness in the heel region.

Pain in the heel region is a normal symptom of overexertion, as seen in bursitis or Achilles tendinitis. Stress fracture is essentially a differential diagnosis that should be considered when treating sportsmen and others with intensive physical exercise. Many injuries of this type can be expected owing to the increasing interest in sports (e.g. marathon).

## REFERENCES

1. Berstein A., Stone J. R. March fracture. *J. Bone Joint Surg.*, 1944, 26, 743-750.

2. Bierweg K. Avulsion Fracture of the Calcaneus. *Int. Surg.*, 1970, 54, 424-427.
3. Cooper D. E. The heel of Achilles : Calcaneal avulsion fracture from a gunshot wound. *Foot Ankle*, 9, 1989, 204-206.
4. Forrester D., Kerr R. Trauma of the foot. *Radiol. Clin. North Am.*, 1990, 28, 423-433.
5. Hulkko A., Orava S. Stress fractures in athletes. *Int. J. Sports Med.*, 1987, 8, 221-226.
6. Hullinger C. W. Insufficiency fracture of the calcaneus. *J. Bone Joint Surg.*, 1944, 26, 751-757.
7. Lowy M. Avulsion fractures of the calcaneus. *J. Bone Joint Surg.*, 1969, 51-B, 494-497.
8. Lyngstadaas S. Treatment of avulsion fractures of the tuber calcanei. *Acta Chir. Scand.*, 1971, 137, 579-581.
9. Protheroe K. Avulsion fractures of the calcaneus. *J. Bone Joint Surg.*, 1969, 51-B, 118-122.

## SAMENVATTING

*A. ROSTED, J. BANG, H. SVEND-HANSEN. Bilaterale stressfractuur van de tuber calcanei.*

Een geval van bilaterale stressfractuur van de tuber calcanei (beak-fracture) bij een 67-jarige vrouw wordt voorgesteld. Bespreking van de pathogenie en behandeling gevolgd met enige algemene overwegingen in verband met stressfracturen.

## RÉSUMÉ

*A. ROSTED, J. BANG, H. SVEND-HANSEN. Fracture de fatigue bilatérale de la tubérosité postérieure du calcaneum.*

Les auteurs présentent un cas de fracture de fatigue bilatérale du calcaneum (fracture en bec) chez une patiente de 67 ans.

Discussion de la pathogénie et du traitement, suivie de considerations générales sur les fractures de fatigue.