

# A COMPARATIVE STUDY OF FIXATION TECHNIQUES IN THE OPEN BANKART OPERATION USING EITHER A CANNULATED SCREW OR SUTURE-ANCHORS

J. NOWAK <sup>1</sup>, G. WINTZELL <sup>1</sup>, A. MOBERG <sup>1</sup>, L. WIKBLAD <sup>2</sup> and S. LARSSON <sup>1</sup>

The purpose of this study was to compare fixation using either Mitek suture-anchors or a cannulated screw technique, both applied extracapsularly, for an open Bankart reconstruction.

Fifty-five consecutive patients with recurrent anterior dislocation of the shoulder were operated in two consecutive series. The same surgical technique was applied regardless of group, except for the reattachment method of the capsulolabral complex to the glenoid rim.

Patients operated with suture-anchor fixation had better anterior stability, external rotation and functional outcome after a 24-month minimum follow-up. There were no differences between the groups regarding re-dislocation or subluxation rate.

**Keywords** : shoulder dislocation ; Bankart lesion ; open Bankart operation ; anchor fixation ; screw fixation.

**Mots-clés** : luxation d'épaule ; lésion de Bankart ; opération de Bankart ; fixation par suture-harpon ; fixation par vis.

---

## INTRODUCTION

During the past century, a large number of open operation techniques for anterior shoulder dislocation have been described and practised with varying outcomes. The different techniques are almost all based on one of three principles : (a) reduction of the range of motion ; (b) blocking the joint by a piece of bone or by a muscle insertion transfer ; or (c) reattachment of the capsulolabral complex to the glenoid rim. The third concept, known as the Bankart operation (2), has become widely accepted in many Western countries as a standard procedure for stabilization of shoulders following recurrent anterior disloca-

tion. What is unique in the Bankart procedure is the goal to regain stability, while simultaneously preserving the range of motion by restoring the joint anatomy.

The original Bankart procedure has gone through several modifications during the past five decades (3, 19, 21). One of the most significant achievements was the introduction of subcortical anchoring fixation of the sutures (12, 14, 16). By using anchors, the suture fixation is simplified and, at the same time, the anchors provide a reliable fixation to the bone, which is shown by good functional outcome with a low recurrence rate and a close to normal range of motion (5, 8, 13, 17).

Despite the reputation of the Bankart procedure as being difficult and time consuming, it has retained a position over the years as one of the leading surgical methods for anterior reconstruction of unstable shoulders. In a comprehensive study by Jerosch *et al.* (11) on the management of patients with shoulder instability at 880 institutions in Germany in 1994, the authors concluded that, in 30% of the institutions, open surgical stabilization for recurrent anterior shoulder dislocations was performed using the Bankart procedure.

To facilitate the Bankart operation, different modifications including various methods of screw fixation, have been used. In 1983 Sergio (20) described a modified Bankart operation using a

---

From the Departments of Orthopedics <sup>1</sup> and Radiology <sup>2</sup>, Uppsala University Hospital, Uppsala, Sweden.

Correspondence and reprints : Jan Nowak, Department of Orthopedics, Uppsala University Hospital, Uppsala, S-752 85 Uppsala, Sweden.

cancellous bone screw with a washer to reattach the capsulolabral complex. Resch *et al.* (15) have developed an extracapsular fixation technique, using small cannulated titanium screws with a washer. Huckstaple *et al.* (10) described a titanium staple for fixation which has been reported as a simplified Bankart operation with a good functional outcome.

The object of this study was to evaluate the radiographic and functional outcome when using either a cannulated screw fixation or a suture-anchor fixation technique (12, 14, 16) in shoulders with persistent instability following recurrent anterior dislocations.

## MATERIAL AND METHODS

Two consecutive series of patients with anterior shoulder instability underwent surgery by one of two surgeons (J. N., A. M.). The inclusion criteria were limited to those with recurrent traumatic unidirectional anterior shoulder dislocation, persistent instability with a positive apprehension test, no joint laxity (22) and no previous shoulder surgery on the affected side.

The first series consisted of 27 patients with 28 unstable shoulders who had undergone surgery between March 1990 and November 1992. A modified open Bankart technique was employed using the Mitek suture-anchor with one hook (GI-Mitek Surgical Products, Norwood, MA, USA) for fixation according to the method described below. The first series included 16 men (60%) and 11 women (40%) with a mean age of 29 years (range 19 to 43 years). Surgery was performed on average 6 years after the primary dislocation. Of the 27 patients, 65% had white collar jobs, whereas the remaining 35% had blue collar jobs. Fifty percent of the patients dislocated their dominant shoulder. The mean follow-up time was 48 months (range 36 to 54 months).

The second consecutive series consisted of 28 patients with 28 unstable shoulders who were operated between February 1993 and October 1994. An identical open Bankart procedure as in the first series was used, but instead of using anchors for suture fixation, a cannulated screw with a washer was used to reattach the capsulolabral complex to the glenoid rim. This group consisted of 23 men (82%) and 5 women (18%) with a mean age at operation of 26 years (range 17 to 42 years). Surgery was performed on average 5 years after the primary dislocation. The dominant side was

involved in 71% of the patients. In this group 62% of the patients had white-collar employment and 38% had blue-collar jobs. The mean follow-up time was 28 months (range 24 to 38 months).

All patients, regardless of group, had moderate to severe limitation of function with inability to perform overhead activity of the affected shoulder before surgery.

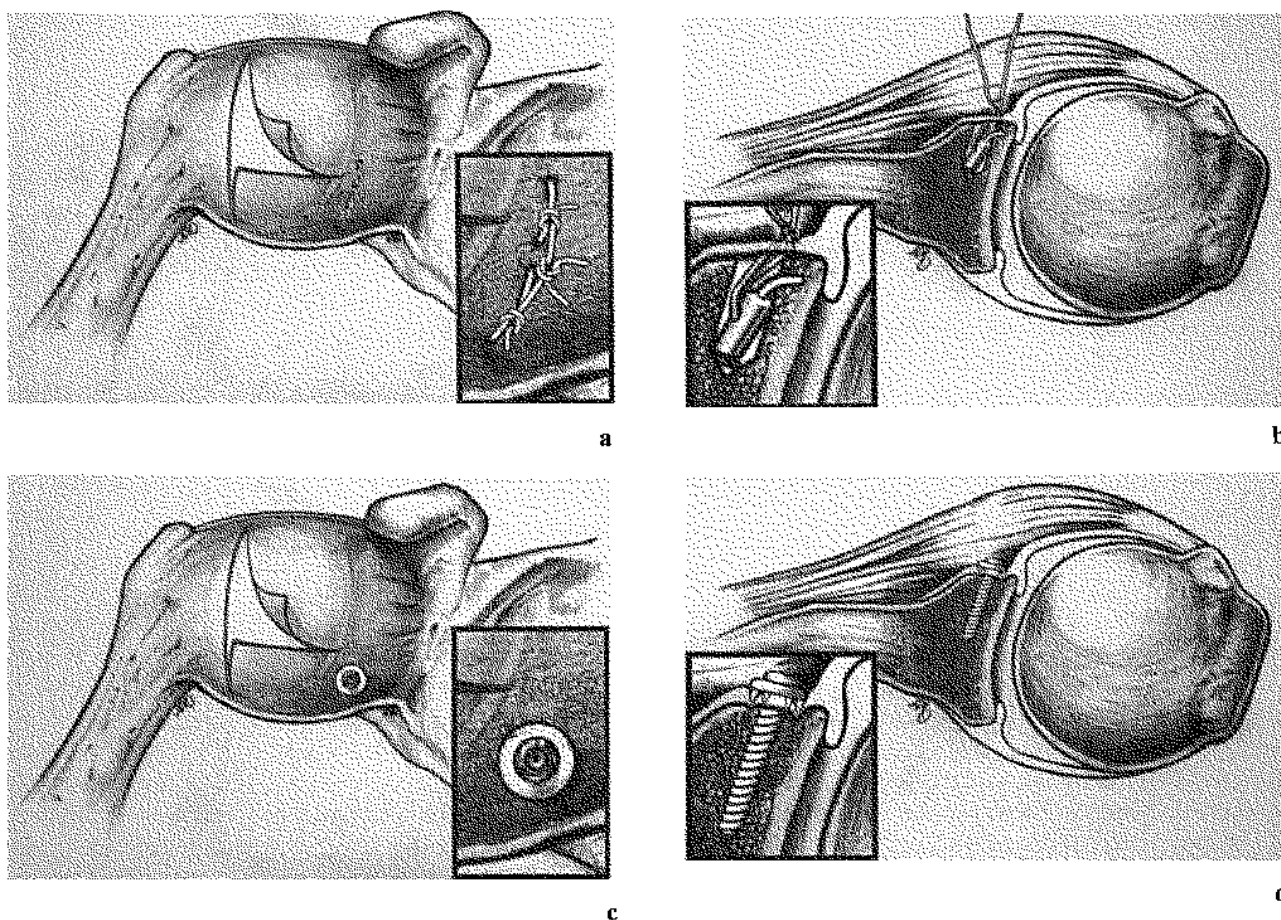
All patients had reported at least three redislocations prior to surgery, with no difference between the groups in preoperative functional assessment based on the Rowe shoulder score of 1978 (17). All patients were classified as poor, with scores ranging from 15 to 25 out of a maximum of 100 units. Preoperative evaluation with Constant score (7) and the Rowe score 1988 was not performed.

## Surgical procedure

The patient was positioned with the upper body elevated 30°. The soft-tissue dissection was identical for both groups. The deltopectoral interval was opened, the cephalic vein preserved and moved laterally while the conjoined tendon was moved medially. Osteotomy of the coracoid process was not performed. Using electric cautery, we made an incision approximately 10 mm lateral to the junction between the subscapularis muscle and the tendon. This incision started in the center of the tendon and continued proximally to the superior glenohumeral ligament, which was preserved. The incision continued down to the anterior humeral circumflex vessels. The subscapularis muscle and the capsule were separated. Stay sutures were placed on both sides of the incision in the subscapularis to facilitate end-to-end reattachment. A horizontal incision was then made in the medial portion of the subscapularis tendon so that the capsule could be clearly exposed. A vertical cut was made in the lateral part of the capsule. The incision continued horizontally just above the inferior glenohumeral ligament. The Bankart lesion was exposed and the glenoid rim decorticated.

## Mitek suture anchor procedure (Fig. 1a, b)

The Mitek suture-anchors with non absorbable sutures were placed in the center of the Bankart lesion. The sutures were then taken extracapsularly and tied to secure the labrum and capsule to the former Bankart lesion. One thread from the upper pair and one from the lower were tied together so that a bridge-like suture was obtained between the two suture knots that were secured earlier. In patients with a minor Bankart lesion, only one Mitek suture-anchor was used.



**Fig. 1.** — Schematic drawings of suture-anchor and screw-fixation in the Bankart operation.

a. *Upper left.* Frontal projection of bridge-like suture-anchor fixation. The incision in the capsule is T-shaped. The sutures are then taken extracapsularly. One thread from the upper and one from the lower knot are tied together so that a bridge-like suture is obtained.

b. *Upper right.* Transaxial projection of suture-anchor fixa-

tion. The anchor sutures are placed in the center of the Bankart lesion. The sutures are tied extracapsularly.

c. *Lower left.* Frontal projection of screw-fixation with a washer. The incision in the capsule is J-shaped. The screw and washer fix the Bankart lesion extracapsularly.

d. *Lower right.* Transaxial projection of screw fixation with a washer. The Bankart lesion is fixed extracapsularly with a screw and washer in the center of the lesion.

#### **Cannulated screw procedure (Fig. 1c, d)**

In the second group, a guide pin was inserted in the center of the Bankart lesion. After drilling and tapping over the guide pin, an 18-mm long 3.5-mm AO/ASIF cannulated cortical screw with a plastic washer (8-mm diameter) was inserted over the guide pin. The screw was placed such that the screw head and the lateral border of the washer were clearly medial to the glenoid (Fig. 2). The screw was tightened until the labrum and capsule were firmly adapted against the underlying bone.

Irrespective of the technique used for attachment of the capsulolabral complex, an anterior capsular shift

was carried out with the arm held to approximately 30° of abduction and 20° of external rotation. The superior corner of the inferior capsular flap was sutured with nonabsorbable sutures, and additional sutures used were absorbable. The wound was closed with absorbable sutures sub- and intracutaneously.

#### **Postoperative regime**

Postoperative rehabilitation was carried out according to a standardized protocol that was identical for both groups. During the first 3 weeks of rehabilitation, all patients were treated with NSAID's. The patients were seen regularly by a physiotherapist during the first

3 months after the operation. The postoperative regime consisted of four phases, each with an approximate duration of 3 weeks.

Phase I. a) Increase range of motion ; b) Body posture exercise ; c) No outward rotation  $> 0^\circ$  with the upper arm in  $0^\circ$  of abduction or according to the surgeons orders.

Phase II. a) Maximize range of motion ; b) Coordination ; c) Muscle strength - isometric, concentric and eccentric.

Phase III. a) Maximize strength ; b) Endurance.

Phase IV. Individualized.

### Clinical evaluation

At the time of follow-up, 5 patients in the suture-anchor group and 3 patients in the screw-fixation group had moved away and were thus not available for evaluation. The follow-up was performed by an independent observer with no previous contact with the patients. Information on functional activity was obtained using the same questionnaire that was used prior to surgery.

Evaluation was performed with respect to frequency of redislocation, subluxation episodes, range of motion with special reference to active external rotation at  $90^\circ$  of abduction (1) in which comparison was made with the contralateral stable shoulder, and anterior shoulder stability when examined with the apprehension and relocation tests (9). Complications were documented based on type and frequency.

The functional outcome at follow-up was evaluated according to the Constant score (7) and the Rowe shoulder score of 1978 (17) and by the Rowe modified scoring system of 1988 (18).

### Radiographic evaluation

Radiographs were taken before and after surgery with anterior-posterior (AP), lateral and epaulette projections (Fig. 2-4). The position of the screws and suture-anchors was described by clockwise orientation, with three o'clock being most anterior for both left and right shoulders. The position of the washer was described by the distance between the lateral edge of the washer and the cortical bone of the glenoid border, as viewed on the AP projection.

### Statistical methods

Fisher's exact test and the Mann-Whitney test for nonparametric data were used to compare the func-

tional outcome between the Mitek suture-anchors and the cannulated screw technique. The level of statistical significance used was  $p < 0.05$ .

## RESULTS

### Recurrences

In the suture-anchor group, one patient had redislocated his shoulder at 12 months and another patient at 30 months following surgery, while in the screw-fixation group one patient had redislocated his shoulder 4 months postoperatively (Fisher  $p = 0.468$ ).

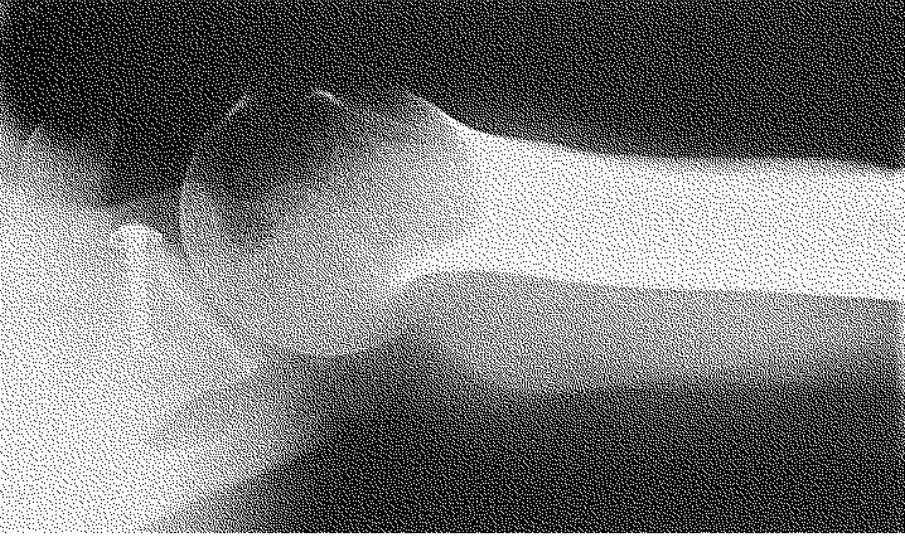Of the two patients in the suture-anchor group who experienced redislocation, one had recurrent dislocations for 6 months after the trauma that caused the first redislocation, and hence reoperation was performed. At follow-up 24 months after reoperation, the apprehension test was negative, and range of motion was normal. The second patient in the suture-anchor group who redislocated his shoulder described adequate causative trauma, and 6 months later the patient had regained a clinically stable shoulder, which was subsequently confirmed at follow-up. The patient who redislocated his shoulder in the screw-fixation group had persistent instability at 28 months' follow-up and was scheduled for reoperation.

### Subluxation

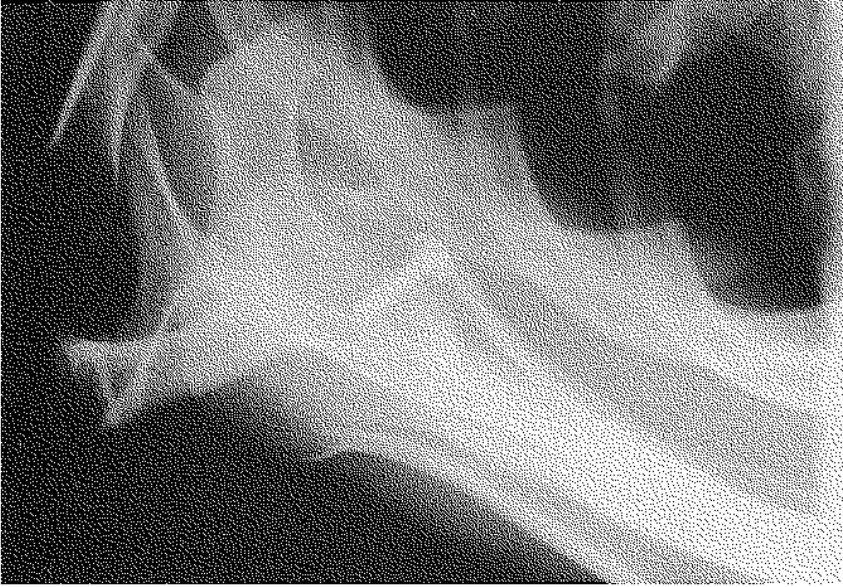
Subluxation episodes were reported in 7 patients in the Mitek-group and in 12 patients in the screw-fixation group. The frequency of episodes varied from once a month to once a year. These patients experienced a feeling of subluxation during overhead activities. The difference in subluxation frequency between the groups, however, was not significant (Fisher,  $p = 0.172$ ).

### Apprehension test

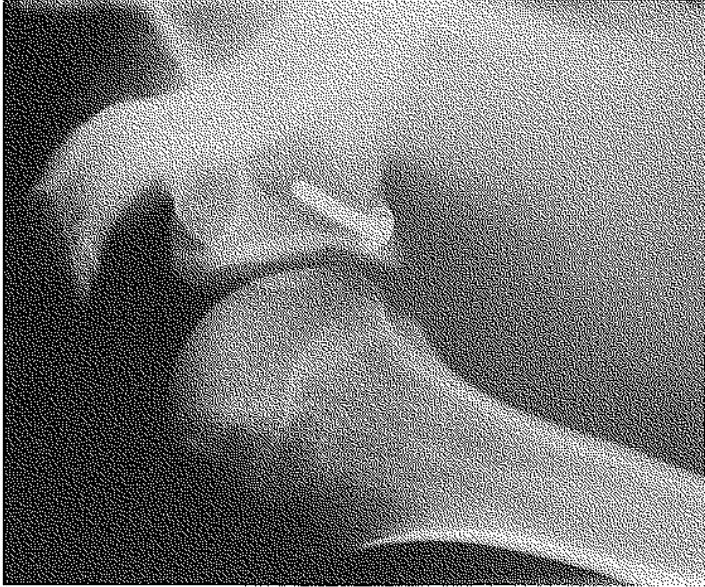Evaluation of anterior shoulder instability was performed using the apprehension test with the patients in a sitting position (Crank test) (9). The test was positive in 4 (17%) patients in the suture-



**Fig. 4.** — Radiographic epaulettic projection of screw-fixation with a washer.



**Fig. 3.** — Radiographic lateral projection of screw-fixation with a washer in a 4 o'clock position.



**Fig. 2.** — Radiographic AP-projection of screw-fixation with a washer.

anchor group and in 12 (48%) patients in the screw-fixation group. The difference between the groups was significant (Fisher,  $p = 0.025$ ).

### Relocation test

Regardless of group, the patients who demonstrated a positive apprehension test also showed a positive relocation test (9).

### External rotation

In the suture-anchor group 2 (9%) patients had decreased external rotation of  $10^\circ$  or more in  $90^\circ$  of abduction. The average reduction in external rotation for the suture-anchor group was  $3.5 \pm 2^\circ$ . In the screw-fixation group, the corresponding figure for reduced external rotation was 9 (36%) shoulders with a reduction of more than  $10^\circ$  with average reduction of  $7.0 \pm 2^\circ$ . The proportion of shoulders with more than  $10^\circ$  of reduced external fixation in the screw-fixation group was significantly higher compared with the number of shoulders with a similar reduction in the suture-anchor group (Fisher,  $p = 0.026$ ).

### Functional outcome

#### Constant score

Assessment of the functional outcome according to Constant score did not reveal any differences between the two groups. The mean scores for the suture-anchor and screw-fixation groups were  $92 \pm 6$  and  $89 \pm 15$  units, respectively of a maximum 100 units (Mann-Whitney,  $p = 0.64$ ).

#### Rowe score (1978)

Assessment of shoulder function was performed with the Rowe score of 1978 (17). These scores showed that a larger proportion of patients (table I) in the suture-anchor group was classified as excellent / good versus fair / poor than were patients in the screw-fixation group (Fisher,  $p = 0.038$ ).

#### Rowe score (1988)

Assessment was also performed with the latter modification of Rowe shoulder score (18), in which pain and strength have been added as variables although with a maximum kept at 100 units.

The assessment showed a significant advantage of the Mitek anchor group compared with the screw group (table II), when evaluating excellent/good versus fair/poor (Fisher,  $p = 0.030$ ).

### Postoperative satisfaction, return to work and sports activities

At follow-up, 85% of the patients in the suture-anchor group reported that their level of shoulder functioning was "much better" compared with their presurgical level. The corresponding figure in the screw-fixation group was 82%. Those subjective results were determined by a five-alternative question ranging from "much worse" to "much better".

Twenty-three patients (92%) in the screw-fixation group and all patients in the suture-anchor group were able to return to their previous occupation after surgery. Twelve of 16 (75%) sports-

Table I. — Rowe score (1978)

Group	Suture-anchor group	Screw-fixation group
Follow-up time	Mean : 48 months	Mean : 28 months
Number of patients	n = 23	n = 25
Excellent	15/23 (65%)	9/25 (36%)
Good	1/23 (4%)	1/25 (4%)
Fair	2/23 (9%)	7/25 (28%)
Poor	5/23 (22%)	8/25 (32%)

Table II. — Rowe score (1988)

Group	Suture-anchor group	Screw-fixation group
Follow-up time	Mean : 48 months	Mean : 28 months
Number of patients	n = 23	n = 25
Excellent	12/23 (52%)	7/25 (28%)
Good	6/23 (26%)	5/25 (20%)
Fair	4/23 (17%)	10/25 (40%)
Poor	1/23 (5%)	3/25 (12%)

active patients in each group could return to their preinjury functional level in their respective disciplines. None of the patients was active in a sport that required overhead activity.

### Operation time

There was no difference in length of operation between methods, with a mean of 117 and 121 minutes for the suture-anchor and screw-fixation groups, respectively.

### Operation fixation device

Two suture-anchors were used in 16 of 23 and one suture-anchor in 6 of 23 operations ; one lesion required three anchors. Of the 25 operations conducted on patients in the screw-fixation group, 23 were performed with one cannulated screw and the remaining two required two screws.

### Complications

Postoperative wound infection was observed in 2 (10%) patients in the suture-anchor group. One of these patients required reoperation for evacuation of a hematoma. Both were treated as outpatients, with antibiotics given orally for 6 weeks. There were no postoperative infections in the screw-fixation group (Fisher,  $p = 0.224$ ).

Mobilization under general anesthesia was performed to treat postoperative adhesive capsulitis in 1 patient in the suture-anchor group and in 3 patients in the screw-fixation group. After mobi-

lization, these patients regained normal range of motion (Fisher,  $p = 0.336$ ).

Persistent postoperative instability, positive apprehension test, and persistent pain motivated a diagnostic arthroscopy in 2 patients in the screw-fixation group ; no findings of intraarticular pathology were noted, however.

### Radiographic evaluation

Radiographic evaluation did not reveal any migration of implants in either the suture-anchor group or the screw-fixation group. In 2 patients, a resorption zone with sclerosis was observed encircling the screw indicating radiographic loosening 42 months postoperatively. One of these patients had a positive apprehension test and reduced external rotation. A change in angle and position of the washer was noted in 2 patients in the screw-fixation group, indicating a possible buttonhole effect ; clinically, these patients were both unstable with positive apprehension and relocation tests.

The radiographic evaluation showed that the anchors were positioned on average between 2:30 and 4 o'clock. The single screw was positioned at 4 o'clock on average (range 4 to 5 o'clock) ; no change in this range was noted when two screws were used. The washer was positioned 1 mm medial to the cortical bone (range  $\pm 3$  mm).

Primary or secondary osteoarthritis was not observed in the shoulder of any of the patients. No radiographic pathology of the humeral head that could be referred to the cannulated screws or Mitek anchors was observed.



## DISCUSSION

This comparative study of two extracapsular Bankart surgical procedures demonstrated significantly better anterior shoulder stability, range of motion and functional outcome for the patients treated with the Mitek suture-anchor fixation technique compared with shoulders stabilized with a cannulated screw-fixation technique. However, there was no difference in rate of recurrence or subluxation between the two methods.

The limitations of the study were the use of consecutive series instead of randomized groups and a relatively limited number of patients. Nonetheless, the two groups were fairly similar with respect to age, occupation, and patient history. The shoulder operations were carried out as two consecutive series by only two surgeons. The difference in follow-up time resulted from the study design with consecutive series. However, we believe that the minimum follow-up of 24 months for the second series allows an adequate comparison between the two fixation techniques. This is underscored by the observation that we were unable to disclose any major improvement or deterioration in the anchor-fixation group during the phase of the follow-up beyond 2 years after surgery. The functional level achieved at 2 years seemed to remain fairly constant over time during the follow-up period used in the present study.

The overrepresentation of positive apprehension and positive relocation tests in the screw-fixation group, despite patients reporting very good shoulder function, implies that several patients might have adapted to a suboptimal functional level. This is supported by the fact that 85% in the suture-anchor group and 80% in the screw-fixation group characterized their shoulder function after operation as "much better", which was the highest degree of satisfaction on a five-step scale.

The normal range of external rotation at 90° of abduction was found in 64% in the screw-fixation group compared with the normalized range of motion of 91% in the suture-anchor group (rotation decreased < 10°); this raises the question of whether screw fixation produces a

more nonelastic capsule attachment to the glenoid. Previous studies using screw fixation have not reported major problems with either decreased range of motion or persistent anterior instability (10, 20).

A plausible explanation to account for the superior results when using multiple anchors is that a larger area of contact and a lower compression force per unit area are obtained when using the suture-anchor technique. This might stimulate healing and enhance normal capsule function compared with the more rigid screw-fixation technique. Thus a suture might be a more flexible and forgiving method when it fixes the soft tissue of the capsule to the glenoid to achieve effective healing. It has also been shown that the suture-anchor fixation provides sufficient strength (16).

The functional outcome evaluated with the Rowe shoulder score was significantly better for the suture-anchor group for both the original Rowe shoulder score of 1978 and the later score of 1988. The functional outcome in the present study, however, was less favorable compared with the extremely high rate (97%) of patients being classified as good or excellent found in a comprehensive study by Rowe *et al.* in 1978 (17). Their recurrence rate was, however, closer to the rates found in our two groups. A comparative study by Levine *et al.* (12) also reported a very high percentage of excellent or good results and a low recurrence rate when using subcortical fixation with a suture-anchor technique similar to ours.

The corresponding results with the Constant score revealed no difference between the groups. The Constant scoring system for shoulder function is widely used and considered to be the standard European system in the evaluation of shoulder function. However, when evaluating patients with shoulder instability, the relevance and accuracy of this system have been questioned (6).

When evaluating different types of anterior capsule reconstruction techniques, it is important to keep in mind that the different Bankart operation procedures create a relative reconstruction of the anatomy of the anterior joint capsule (4). Further analysis in order to explain the higher



percentage of persistent anterior instability of the shoulder when using screw fixation would benefit from CT arthrography. Arthrographic findings may be helpful in answering the question of whether a competent anterior capsule has been restored without a persistent Bankart lesion.

We conclude that the overall result of this study clearly reveals the superiority of the suture-anchor fixation technique over the screw-fixation technique. This implies that the extracapsular screw-fixation technique described should not be used until further development and studies can show a functional outcome in the range of that of the suture-anchor technique.

### REFERENCES

1. A.A.O.S. Joint Motion. Method of Measuring and Recording 1988.
2. Bankart A. The pathology and treatment of recurrent dislocation of the shoulder joint. *Brit. J. Surg.*, 1938, 26, 23-29.
3. Berg E., Ellison A. The inside-out Bankart procedure. *Am. J. Sports Med.*, 1990, 18, 129-133.
4. Blasler R., Bruckner J., Janda D., Alexander A. The Bankart repair illustrated in cross-section. Some anatomical considerations. *Am. J. Sports Med.*, 1989, 17, 630-637.
5. Bänninger J., Matter P. Late results of the combined Putti-Platt and Bankart operations for habitual shoulder dislocations. *Therapeutische Umschau*, 1974, 31, 222-226.
6. Conboy V., Morris R., Kiss J., Carr A. An evaluation of the Constant-Murley shoulder assessment. *J. Bone Joint Surg.*, 1996, 78-B, 229-232.
7. Constant C., Murley A. A clinical method of functional assessment of the shoulder. *Clin. Orthop.*, 1987, 214, 160-164.
8. Dicksson J., Devas M. Bankart operation for recurrent dislocation of the shoulder. *J. Bone Joint Surg.*, 1957, 39-B, 114-126.
9. Hawkins R., Bokor D. Clinical Evaluation of Shoulder Problems. In: Rockwood C., Matsen F., eds. *The Shoulder*, Edinburgh, Churchill Livingstone, 1985, pp. 1169-1170.
10. Huckstaple R., Bowers D. Titanium staple and screw fixation for recurrent dislocation of the shoulder. *Injury*, 1993, 24, 397-402.
11. Jerosch J., Dreschler H., Steinbeck J., Lewejohann B. Current treatment concepts for shoulder instability. Results of a country wide survey. *Unfallchirurg.*, 1994, 97, 64-68.
12. Levine W., Richmond J., Donaldson W. R. Use of the suture anchor in open Bankart reconstruction. A follow-up report. *Am. J. Sports Med.*, 1994, 22, 723-726.
13. Martin B., Vidal J. Long-term results obtained with the Bankart method for the treatment of recurring anterior instability of the shoulder. *Chir. Organi. Mov.*, 1991, 76, 199-207.
14. Obrist J., Genelin F., Neureiter H., Möseneder H. Mitek-anchor-system for Bankart-surgery. *Unfallchirurg.*, 1991, 17, 208-212.
15. Resch H., Kathrein A., Golser K., Sperner G. Arthroscopic and percutaneous screwing techniques with a new screwing device. *Unfallchirurg.*, 1992, 95, 91-98.
16. Richmond J., Donaldson W., Fu F., Harner C. Modification of the Bankart reconstruction with a suture anchor. Report of a new technique. *Am. J. of Sports Med.*, 1991, 19, 343-346.
17. Rowe C., Patel D., Southmayd W.W. The Bankart procedure: A long-term end-result study. *J. Bone Joint Surg.*, 1978, 60-A, 1-16.
18. Rowe C. Evaluation of the shoulder. In: Rowe C. R., ed. *The Shoulder*. New York, Churchill Livingstone, 1988, pp. 631-637.
19. Savornin C., Casanova G., Bisserie P., Chauvet J., Willems Ph. The treatment of recurrent antero-medial dislocation of the shoulder. A report of eighty-five cases treated by a variant of Bankart's operation. *Chir. Orthop.*, 1987, 41, 216-221.
20. Sergio G. Recurrent anterior dislocation of the shoulder joint. A modification of Bankart's capsulopexy. Notes on the surgical technique. *Ital. J. Orthop. Traumatol.*, 1983, 4, 469-474.
21. Thomas S., Matsen F. An approach to the repair of avulsion of the glenohumeral ligament in the management of traumatic anterior glenohumeral instability. *J. Bone Joint Surg.*, 1989, 71-A, 506-512.
22. Wilkinson J., Carter C. Persistent joint laxity and congenital dislocation of the hip. *J. Bone Joint Surg.*, 1964, 46-B, 40-45.

### SAMENVATTING

*J. NOWAK, G. WINTZELL, A. MOBERG, L. WIKBLAD, S. LARSSON. Vergelijkende studie van 2 fixatietechnieken in de open Bankart-herstel operatie.*

Het doel van deze studie is om bij hersteloperaties van het Bankart letsel, twee verschillende kapselfixaties te vergelijken: de gecannuleerde schroef of de Mitek-haakjes. Bij 55 patienten met recidiverende anterieure luxaties werd behalve de kapselfixatie strikt dezelfde techniek van open herstel toegepast. Deze met een Mitek-sutuuranker hadden een beter resultaat, voor wat betreft de stabiliteit, de exorotatie en globale functie na 24 maanden. De redislocatie was niet significant verschillend.

**RÉSUMÉ**

*J. NOWAK, G. WINTZELL, A. MOBERG, L. WIK-BLAD, S. LARSSON. Étude comparative de deux techniques de fixation capsulaire dans l'opération de Bankart au moyen de vis canulées ou de fils de suture sur harpon.*

Les auteurs ont comparé deux techniques de fixation capsulaire utilisée dans des opérations de Bankart à ciel ouvert : ils ont comparé la réinsertion capsulaire au moyen de fils de suture montés sur harpon (Mitek) à une fixation par vis canulées. L'étude a porté sur 55 patients successifs, opérés pour luxation antérieure récidivante de l'épaule. La technique chirurgicale était

en tout point comparable dans les deux groupes, en dehors de la technique de réamarrage de la capsule et du bourrelet au rebord glénoïdien. Avec un recul minimum de 24 mois, les patients qui avaient subi l'opération avec réinsertion par fils de suture sur harpon avaient une meilleure stabilité articulaire, une meilleure rotation externe, et un meilleur résultat fonctionnel. Il n'y avait pas de différence entre les deux groupes en ce qui concerne le taux de reluxation ou de subluxation. Au total, cette étude a montré la supériorité de la fixation par suture sur harpon, comparativement à la fixation capsulaire par une vis canulée dans l'opération de Bankart réalisée à ciel ouvert.