

# UNREAMED INTRAMEDULLARY NAILING OF ACUTE FEMORAL SHAFT FRACTURES USING A TRACTION DEVICE WITHOUT FRACTURE TABLE

P. REYNDERS, P. BROOS

The authors present a simple distraction apparatus that makes it possible to perform nonreamed intramedullary nailing of the femur on a normal operating table. Nonreamed intramedullary (IM) nails were inserted in 24 femoral shaft fractures using this device. The set-up time of this device was 60% shorter compared with a stratified group of 28 femoral nailings performed using the fracture table. The authors feel that this device is a safe and effective alternative to using a fracture table. It is especially useful in the polytrauma patient where the additional lesions can be treated without the need for patient transfer to another table.

**Keywords :** femur fracture ; intramedullary nailing ; femoral distraction ; manual traction.

**Mots-clés :** fracture du fémur ; enclouage médullaire ; distraction fémorale ; traction manuelle.

---

## INTRODUCTION

Closed intramedullary nailing has become a standard treatment for acute femoral shaft fractures (1, 3, 12).

To reduce the risk of pulmonary complications after injury (ARDS) (9, 10) the AO in 1990 developed a stabilization system for femoral fractures known as the "Unreamed Femoral Nail" (UFN) (4).

We have used this nailing technique for subtrochanteric fractures and femoral shaft fractures since April 1995. The UFN is much quicker to insert, is minimally invasive with small wounds and its versatility allows fixation of a wide range of femoral fractures. Until recently we used the fracture table for positioning the patient and maintaining the reduction during the intramedul-

lary nailing. Several authors reported the use of alternative reduction techniques, especially in the multitrauma patient, to avoid unnecessary transfer to a standard table. The technique whereby the fractured femur was nailed on a radiolucent table with the help of a femoral distractor, advocated by McFerran and Johnson (6, 11), turned out to be technically demanding, and potentially hazardous because of the close proximity of the femoral vessels to the proximal distractor pin. Furthermore, varus-valgus or rotational correction to the fractured femur after traction was applied, often proved impossible. Although some authors advocate manual traction and reduction techniques for femoral fractures (2), in our hands this was often time consuming and problematic with risk of contaminating the sterile field.

We therefore developed a simple traction device to hold the reduction while performing a UFN.

## MATERIAL AND METHODS

### Description of the instrument


The traction device (Fig. 1) consists of a stainless-steel tube that glides over a solid stainless-steel rod. At its proximal end the distractor has a perineal countertraction post made of polypropylene, which can be sterilized in an autoclave.

On the distal end of the distractor a vertically-oriented frame is connected to the solid tube with a

---

Department of Traumatology and Reconstructive Surgery, University Hospitals K.U. Leuven.

Correspondence and reprints : P. Reynders, Department of Traumatology and Reconstructive Surgery, University Hospitals K.U. Leuven, Herestraat 49, 3000 Leuven, Belgium.



*Fig. 1.* — The traction device.

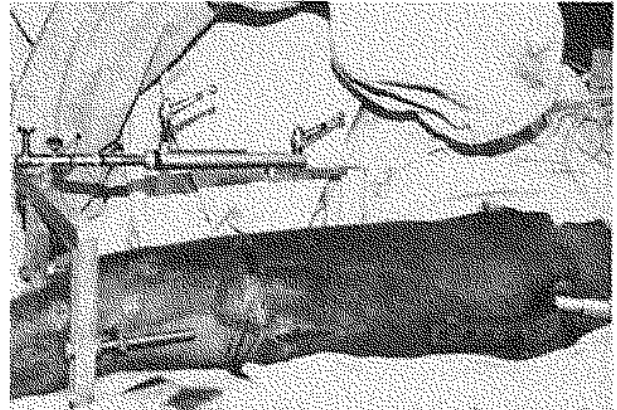
locking nut ; releasing this nut makes rotation around a coronal axis for valgus or varus correction possible. On both sides of the frame a wide slot makes rotation of the traction wire around a frontal axis possible for exo- or endorotation of the distal femoral fragment. The four segments of the distractor are assembled intraoperatively on the instrument table.

### Technique

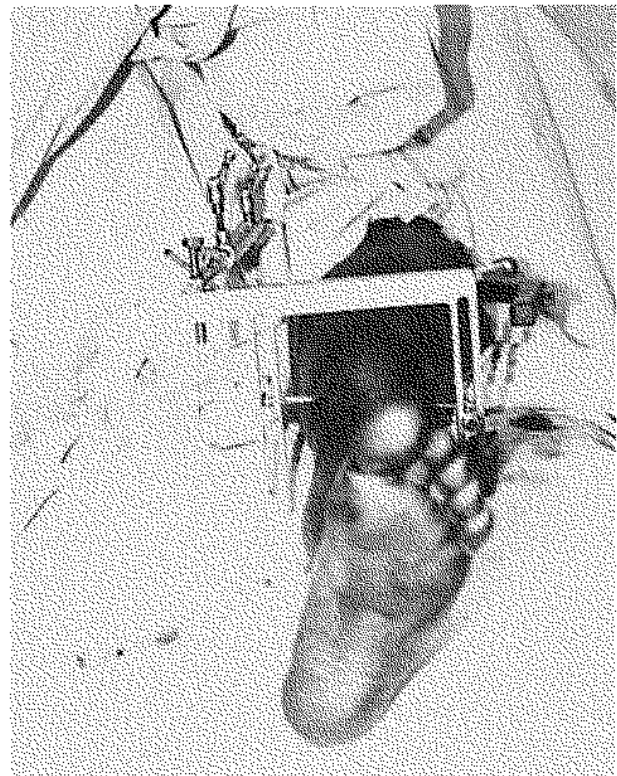
After anesthesia is administered on a stretcher or bed, the patient is transferred to a translucent operating table. With the patient in the supine position the opposite, uninjured extremity is flexed in a 90-90° position and placed in a leg holder to allow for rotation of the fluoroscopy C-arm in anteroposterior and lateral directions. After preparation of the operative field, a condylar traction pin is inserted and connected with the distal frame by a threaded rod and secured with a locking nut. The tube and rod and the perineal post are assembled and connected with the distal frame.

Traction is applied to the femur by pulling on the distal frame. The traction is then maintained by locking the tube and rod with a handscrew (Figs. 2, 3).

To avoid interference by the flank the injured leg is adducted.



*Fig. 2.* Positioning of the lower leg in the traction device.



*Fig. 3.* On both sides of the distal "U"-frame a wide slot (small arrow) makes rotation of the condylar pin possible. Releasing the locking nut makes rotation around a coronal axis (varus-valgus) of the distal femoral fragment possible.

**Patients**

This prospective clinical trial consisted of 2 study groups. All patients who sustained a femoral fracture (including subtrochanteric fractures) treated with antegrade nailing with the UFN, between January 25, 1995 and December 31, 1996, were included in the study. Exclusion criteria included previous fracture, pathologic fracture and intertrochanteric extension of the fracture lines. In the first group, 24 fractures in 24 patients, traction was applied to the femur by the traction device. The other group consisted of 28 fractures in 28 patients where the fracture table was used to aid in obtaining and holding the reduction.

Medical records were reviewed to obtain patient age, mechanism of injury, associated injuries, type of femur fracture, installation time of the patient (time from anesthetic induction to incision), operative time and need for redraping or repositioning on another table.

**RESULTS**

The mean age was 34 years for the fracture-table group, and 37 years for the traction-device group. No statistically significant difference was noted between the two groups with regard to fracture type, multitrauma patients, or condition of the integument as determined by the  $\chi^2$  test (Tables I-III). With regard to the actual operative time, the traction-device group scored better, but this was not statistically significant (Mann-Whitney two-tailed p value = 0.0621).

The set-up time was statistically significantly faster in the traction device group (mean 16 min.) as compared with the fracture-table group (44 min.) (unpaired t-test, two-tailed p = 0.0001).

The need for redraping-repositioning in the subgroup of multitrauma patients was less in the traction device group (1 versus 6). Because of the small numbers in both subgroups (1 in the traction device group versus 6 in the traction-table group) no statistical analysis was done.

In the traction-device group, closed reduction was obtained in 18 fractures. Additional reduction techniques were necessary in the other 6 fractures : axial correction of the nail in the distal femur with the so-called "Poller screws" (5) in 2 cases, cor-

rection of the mediolateral displacement with Lambotte's retractor hooked around the proximal or distal fragment femoral fragment in 2 cases and correction of the anteflexion of a proximal femoral fracture by open reduction of the fracture in 2 fractures.

In the fracture-table group closed reduction was obtained in 20 fractures ; open correction of the mediolateral displacement was necessary 4 times and open correction of the anteflexion of a proximal femoral fragment was needed 4 times.

No intraoperative complications were attributable to the traction-device. No pudendal, sciatic or peroneal nerve palsies occurred in the traction-device group. In the fracture-table group 2 patients had a reversible weakness of the extensor hallucis and one patient had a postoperative pudendal palsy with incomplete recovery after 14 months.

Table I. — Grading of soft tissue lesions in open fractures

| Grade (Open) | Fracture table | Traction device |
|--------------|----------------|-----------------|
| 0            | 17             | 16              |
| 1            | 6              | 5               |
| 2            | 5              | 3               |

Table II. — Data for fracture location

| Location       | Fracture table | Traction device |
|----------------|----------------|-----------------|
| Proximal (1/3) | 4              | 2               |
| Midshaft       | 18             | 16              |
| Distal (1/3)   | 6              | 6               |

Table III. — Fracture types according to the AO classification (8)

| Fracture table  |        |        |
|-----------------|--------|--------|
| A1 : 4          | B1 : 0 | C1 : 6 |
| A2 : 0          | B2 : 8 | C2 : 2 |
| A3 : 8          | B3 : 0 | C3 : 0 |
| Traction device |        |        |
| A1 : 3          | B1 : 0 | C1 : 4 |
| A2 : 1          | B2 : 5 | C2 : 1 |
| A3 : 9          | B3 : 0 | C3 : 1 |

## DISCUSSION

Intramedullary nailing using this traction device is a simple, safe and effective alternative to using a fracture table. Although the fracture-table can hold the reduction of the femoral fragments, it deprives the surgeon of the possibility of mobilizing the limb and the flexibility of the surgical approach is frequently compromised. The time required to position the patient on a fracture-table is eliminated. In this small series there was no need for redraping and/or repositioning in the multiply-injured patients in the traction-device group, whereas in the fracture-table group all multitrauma patients needed redraping or repositioning during surgery.

Manual traction as a "reduction technique" is unreliable in our hands, especially in the muscular patient and we lose a valuable assistant to hold the leg during the operation. If the reduction is lost, it may not be reproduced by a second attempt. The resulting frustration often leads to a surgical struggle and turns the reduction into a traumatic maneuver.

Some authors advocate the use of the AO femoral distractor (6, 7) for obtaining and holding the reduction. The AO femoral distractor needs a proximal screw at the level of the lesser trochanter. With the specially-designed jig the distance of this screw to the nearest neurovascular structure is 2.5 cm. Most of the time however this screw is placed free-handed, increasing the risk of penetrating the neurovascular bundle. Another disadvantage of this apparatus is that the eccentric force produced by the unilaterally mounted distractor produces additional varus deformity which is difficult to correct without releasing the distraction force of the apparatus.

The use of the fracture-table is still the "gold standard" for intramedullary nailing. When dealing with multiply-injured patients, eliminating the fracture-table decreases the need for patient transfer and manipulation intraoperatively. This can lead to a decreased total operative time, and may be safer for the multiply-injured patients.

## REFERENCES

1. Bucholtz R., Jones A. Current concepts review. Fractures of the shaft of femur. *J. Bone Joint Surg.*, 1991, 73-A, 1561-1566.
2. Karpos P. Intramedullary nailing of acute femoral shaft fractures using manual traction without a fracture table. *J. Orthop. Trauma*, 1995, 9, 57-62.
3. Kempf I., Grosse A., Beck G. Closed locked intramedullary nailing : Its application to comminuted fractures of the femur. *J. Bone Joint Surg.*, 1985, 67-A, 709-720.
4. Krettek C. *et al.* Unreamed intramedullary nailing of femoral shaft fractures : Operative technique and early clinical experience with the standard locking option. *Injury*, 1996, 27, 233-254.
5. Krettek C., Schandelmaier P., Tscherner H. Non-reamed interlocking nailing of closed tibial fractures with severe soft tissue injury : Indications, technique and clinical results. *Clin. Orthop.*, 1995, 315, 34-41.
6. McFerran M., Johnson K. Intramedullary nailing of acute femoral shaft fractures without a fracture table : Technique of using a femoral distractor. *J. Orthop. Trauma*, 1992, 6, 271-278.
7. Müller M., Allgöwer M., Scheider R., Willenegger H. *Manual of internal fixation.* Berlin, Heidelberg, New-York, Springer-Verlag, 1991.
8. Müller M., Nasarian S., Koch P., Schatzker J. *The comprehensive classification of fractures of long bones.* Springer-Verlag, Berlin - Heidelberg - New York, 1990, 110-115.
9. Oettinger W., Bach A. Thromboxanfreisetzung während intramedullärer Nagelung von Femurschaftfrakturen bei Patienten. *Langenbecks Arch. Chir. Suppl. Chir. Forum*, 1983, 233.
10. Pape H., Dwenger A., Regel G., Schweitzer G., Jonas M. *et al.* Pulmonary damage due to intramedullary femoral nailing in severe trauma in sheep — Is there an effect from different nailing methods? *J. Trauma*, 1992, 33, 1-9.
11. Sirkin M., Behrens F., Mc Cracken K., Aurori K., Aurori B., Schenk R. Femoral nailing without a fracture table. *Clin. Orthop.*, 1996, 332, 119-125.
12. Winquist R., Hansen Jr. S., Clawson K. Closed intramedullary nailing of femoral fractures : A report of five hundred and twenty cases. *J. Bone Joint Surg.*, 1984, 66-A, 529-539.

## SAMENVATTING

*P. REYNDERS, P. BROOS. Ongერიemde intramedullaire nageling van acute femurschaftfracturen met behulp van een tractietoestel zonder orthopedische tafel.*

De auteurs stellen een tractie-apparaat voor dat ongeriemde intramedullaire femurnageling mogelijk maakt

op een operatietafel. Met behulp van dit toestel werden 24 ongeriemde intramedullaire (IM) nagels geplaatst bij femurschaftbreuken. De operatieduur was 60% korter dan in een groep van 28 femurschaftfracturen behandeld op een orthopedische tafel in tractie. De auteurs vinden dit tractietoestel een veilig en effectief alternatief voor de orthopedische tafel. Het is vooral nuttig bij polytraumatpatiënten, omdat additionele letsels behandeld kunnen worden zonder de patiënt naar een andere tafel te verplaatsen.

### RÉSUMÉ

*P. REYNDERS, P. BROOS. L'enclouage médullaire sans alésage des fractures récentes de la diaphyse fémorale au moyen d'un dispositif de traction sans table orthopédique.*

Les auteurs présentent un dispositif de traction simple qui permet de réaliser sur une table d'opération or-

dinaire l'enclouage médullaire du fémur sans alésage. Ils ont réalisé, en utilisant ce dispositif, 24 enclouages médullaires sans alésage pour des fractures de la diaphyse fémorale. Le temps opératoire dans cette série a été 60% plus court que dans un groupe de 28 enclouages fémoraux réalisés sur table orthopédique en traction. Les auteurs pensent que ce dispositif est une alternative sûre et efficace à la table orthopédique. Il est particulièrement utile chez le polytraumatisé car il permet de traiter ses autres lésions sans devoir transférer le patient sur une autre table d'opération.