

DURAL TEAR ASSOCIATED WITH A FLEXION DISTRACTION  
SUBLUXATION TO THE CERVICAL SPINE  
WITHOUT NEUROLOGIC INJURY

D. DE GELB \*, L. LENKE \*\*, J. POND \*\*

The authors report an unusual cervical spine flexion distraction injury presenting initially without a neurologic deficit who was found during a posterior stabilization procedure to have a large dural tear with a cerebral spinal fluid leak. The occurrence of dural tears in the setting of cervical injury without severe neurologic injury has not been previously reported. Optimal management of this unusual condition is suggested and results of the treatment are provided.

Keywords : cervical spine ; sublaxation ; dural tear.  
Mots-clés : rachis cervical ; sublaxation ; brèche durale.

INTRODUCTION

Dural tear at the site of a cervical fracture or dislocation accompanied by complete spinal cord injury is a well recognized phenomenon. However, the occurrence of dural tears in the setting of cervical injury without severe neurologic injury has not been previously reported. We report a case of a woman with a cervical flexion distraction injury presenting initially without a neurologic deficit who was found during a posterior stabilization procedure to have a large dural tear with a cerebrospinal fluid (CSF) leak at surgery.

CASE REPORT

A 65-year-old female was brought to the Emergency Department after being involved in a motor vehicle accident. Initial evaluation revealed a Grade II open left supracondylar femur fracture and anterior sublaxation of C4 on C5 (Fig. 1). Peripheral neurologic examinations upon admission

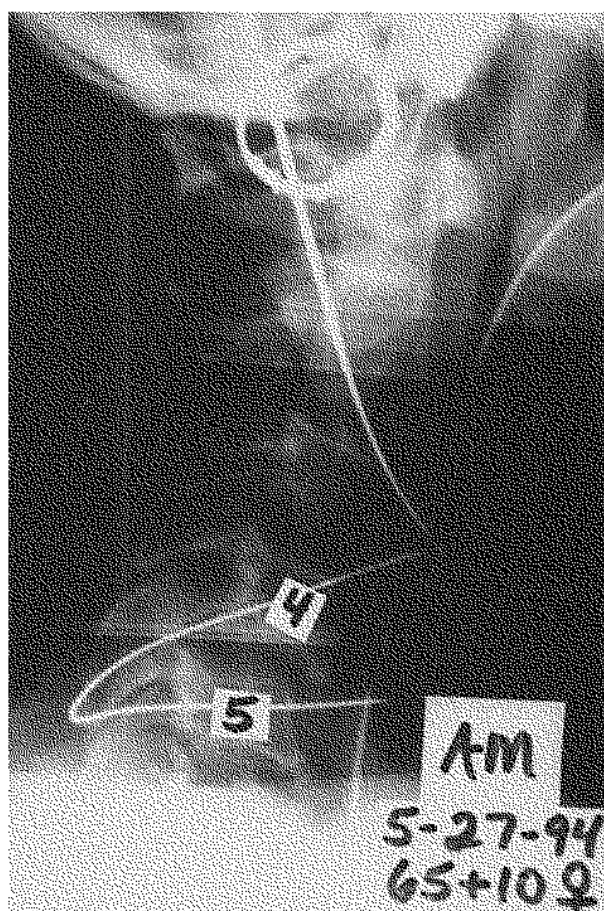


Fig. 1. The lateral cervical spine radiograph on admission shows C4 dislocated on C5.

\* Penn State College of Medicine, Hershey, Pennsylvania.

\*\* Department of Orthopaedic Surgery, Washington University School of Medicine, St. Louis, MO 63110.

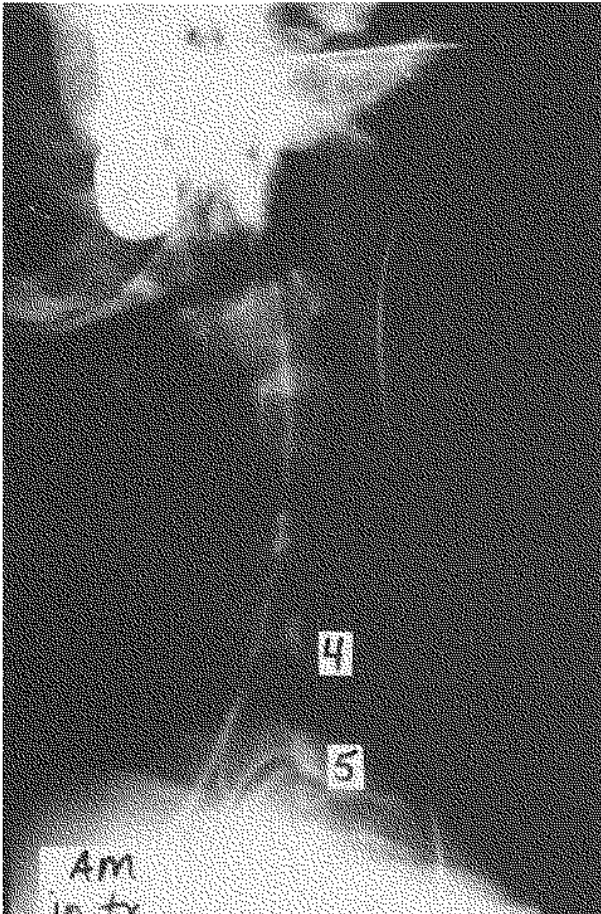
Correspondence and reprints : Lawrence G. Lenke, M.D., One Barnes-Jewish Plaza, Suite 11300, St. Louis, Missouri 63110, USA.

by an orthopedic resident and spine fellow revealed no focal deficits in this awake and cooperative patient. She was placed in 15 pounds of Gardner-Wells tong traction and repeat lateral cervical spine radiographs revealed reduction of the subluxation but some distraction at the C4-5 interspace (Fig. 2). Neurologic examination in traction following reduction showed no change in the neurologic status, and she was maintained in 10 pounds of cervical traction. The patient was then admitted and underwent medical stabilization and clearance for surgery.

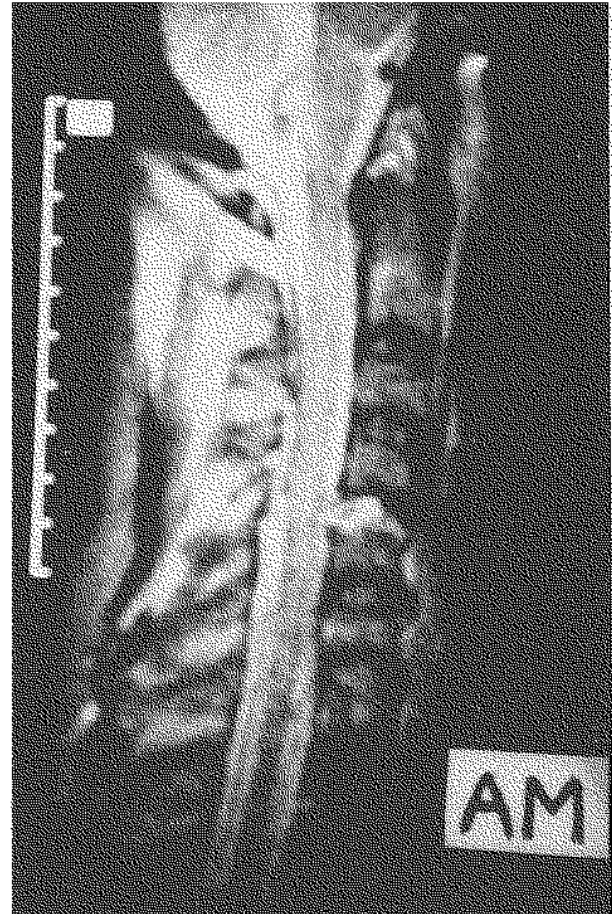
Approximately 12 hours following her reduction, her neurologic exam just prior to going to surgery revealed new weakness of the left upper extremity involving the biceps, triceps, and intrinsic

muscles of the hand. She then underwent emergent MR imaging which documented a herniated disc at the C4-C5 interspace, along with slight residual subluxation at that level (Fig. 3). The patient was then taken to surgery where an anterior cervical discectomy, autogenous tricortical iliac fusion, and anterior cervical plating for stabilization was performed. No evidence of CSF leak was seen during this procedure. Under the same anesthetic, she then underwent operative fixation of her left supracondylar femur fracture. Postoperatively, there was no immediate change in the patient's peripheral neurologic examination.

Due to the highly unstable nature of the posterior ligamentous structures injured, a posterior fixation and fusion procedure was felt to be



*Fig. 2.* — Following 15 pounds of Gardner-Wells tong traction the facet joints are reduced with residual distraction between the vertebral bodies and facet joints at C4-C5.



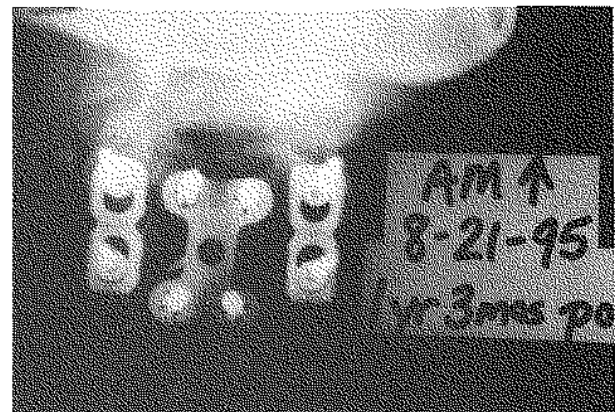*Fig. 3.* — Sagittal MRI scan preceding operative intervention showing a herniated disc fragment within the spinal canal along with slight residual subluxation of the C4-C5 vertebral bodies.

indicated. However, the patient's postoperative course was complicated by delirium, pneumonia, and pulmonary failure delaying the procedure until her medical condition stabilized. During this period she was maintained in a Philadelphia collar.

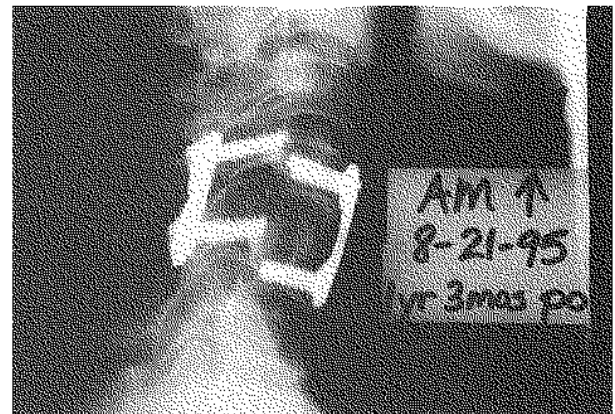
Two weeks after her anterior stabilization procedure, the patient was returned to the operating room for a posterior cervical fusion. Immediately upon incision of the deep cervical fascia, a large quantity of CSF was encountered. Further dissection revealed complete disruption of the ligamentum flavum at C4-C5, with CSF emanating from this site on the right. Laminectomy was performed to expose the dural tear and repair it. Full exposure of the defect revealed a large tear extending from C4 to C7 and laterally to involve the right C5 nerve root. Primary repair of the defect was deemed impossible. Therefore, the defect was patched with allograft dura and fibrin glue. Posterior stabilization was completed with lateral mass plating and autogenous iliac crest bone grafting. A lumbar CSF drain was placed postoperatively and maintained for one week. She was allowed to have her head of bed elevated for pulmonary toilet, as her lumbar CSF shunt was calibrated to accept changes in CSF hydrostatic pressure. The surgical wounds all healed primarily with no evidence of continued cerebral spinal fluid leakage. Immediately postoperative, there were no new neurologic deficits noted. At one year and 3 months follow-up, the patient has a solid spinal fusion (Fig. 4), and her left upper extremity neurologic deficits resolved completely by 2 months postoperative.

## DISCUSSION

Dural tear accompanying severe spinal trauma with spinal cord transection is a well recognized phenomenon (4). However, the occurrence of a dural tear associated with lesser degrees of spinal cord trauma has not been previously described in the cervical spine. Several standard orthopedic and neurosurgical textbooks and a thorough literature review could uncover no reference describing this combination of injuries. In this patient



a



b

**Fig. 4.** -- (A) Posteroanterior radiograph at 1 year 3 months postoperative showing the anterior cervical plate and posterior lateral mass screws and plates. (B) The lateral cervical radiograph at 1 year postoperative shows a complete reduction of the deformity with a solid anterior spine fusion and the instrumentation described previously.

with a highly unstable cervical spine, the plain radiographic findings underestimated the degree of soft tissue injury. However, the initial energy of the injury was insufficient to cause significant damage to the spinal cord. Additionally, there was no evidence of cerebrospinal fluid seen during the anterior procedure. Therefore, the finding of a large collection of CSF during the posterior exposure was unexpected.

Facet subluxations and dislocations generally are accepted to fall into the classification of flexion-distraction injuries as described by Allen *et al.* (1). As force is applied, the posterior liga-

mentous structures fail in tension, allowing the facet joints to subluxate and eventually dislocate. Continued force leads to disc disruption and eventually complete cervical dislocation. The frequency of neurologic injury increases with increasing injury severity (2, 3, 4, 5). Undoubtedly the dura can be stretched and torn by the same mechanism. The unknown factor is to what extent the spinal cord can tolerate stretch prior to sustaining permanent damage. With extreme anterior displacement, the cord can be severed between the posterior elements of the dislocated vertebra and the posterior body of the subjacent one. In this case, the initial injury force did not produce any immediate neurologic damage as evidenced by the patient's initially normal examination. The patient's partial left upper extremity neurologic deficit 12 hours after admission was probably the result of retropulsion of the disk fragment into the canal that occurred with reduction, a known potential complication occurring with reduction of cervical facet dislocations (3).

The question of the most appropriate care for this type of lesion remains. Traditionally, flexion distraction injuries have been treated primarily by posterior wiring and fusion to reinforce the torn posterior ligamentous structures. However, this injury can also necessitate an anterior approach primarily to remove a disc herniation causing spinal cord compression. Thus, it may be advantageous to treat this type of specific cervical spine injury from the anterior approach alone via single level discectomy, graft, and plate fixation as was done as a first stage in this case. Postoperative cervical spine immobilization is required in this circumstance. The third option is a combined anterior and posterior procedure which obviates postoperative external immobilization. The reason for performing the second stage posterior stabilization in this case included: the large amount of ligamentous instability noted; intraspinal and facet widening following the anterior grafting; and the soft, osteoporotic bone encountered when placing the anterior cervical plate which gave only fair fixation to the vertebral bodies. Thus, the surgeon recommended either a postoperative halo or a single level posterior stabilization as an

adjuvant means to stabilize the anterior cervical construct to ensure adequate healing. The patient and her family elected to have the posterior procedure instead of wearing a halo vest for three months following the anterior procedure. There is certainly no way of knowing if this second procedure was absolutely necessary for appropriate healing in this case.

In this case, during the posterior procedure, the laminectomy was performed only for the purpose of exposing and repairing the dural defect. The authors fully expected to find a small tear amenable to direct repair. However, at 2 weeks post-injury, the reactive inflammation and edema rendered the tissue extremely friable and the defect was found to be larger than expected and impossible to repair primarily. The authors suggest that similar situations might respond to meticulous water tight fascial closure and placement of a lumbar drain; with adequate cerebrospinal fluid diversion, it is likely that the leak would seal spontaneously. In the absence of other indications, laminectomy need not to be performed for dural repair alone. Retrospectively, it obviously may have been advantageous to manage this patient in a halo vest without a posterior approach to completely avoid the CSF leak in the first place. However, the patient did heal her unstable cervical injury without any further sequelae from the CSF leak.

In conclusion, this case report is intended to alert spinal surgeons to the possibility of dural tear co-existent with spinal injury without severe neurologic deficit in the cervical spine. In an era of more aggressive surgical management of spinal fractures, often to avoid prolonged halo immobilization, the possibility of encountering a lesion such as this might become more frequent and surgeons should be prepared. The authors suggest meticulous fascial closure and CSF diversion as the recommended treatment for this problem.

## REFERENCES

1. Allen B., Ferguson R. L., Lehmann T. R., O'Brien R. P. A mechanistic classification of closed, indirect fractures and dislocations of the lower cervical spine. *Spine*, 1982, 7, 1-27.

2. Bohlman H. H. Acute fractures and dislocations of the cervical spine. *J. Bone Joint Surg.*, 1979, 61-A, 1119-1142.
3. Eismont F. J., Arena M. J., Green B. A. Extrusion of an intervertebral disc associated with traumatic subluxation or dislocation of cervical facets. *J. Bone Joint Surg.*, 1991, 73-A, 1555-1560.
4. Lintner D. M., Knight R. Q., Cullen J. P. The neurologic sequelae of cervical spine facet injuries. *Spine*, 1993, 18, 725-729.
5. Marar B. C. The pattern of neurological damage as an aid to the diagnosis of the mechanism in cervical-spine injuries. *J. Bone Joint Surg.*, 1974, 56-A, 1648-1654.

### SAMENVATTING

*D. DE GELB, L. LENKE, J. POND. Dura-scheur bij een flexie-distractie subluxatie van de cervicale wervelkolom zonder neurologisch letsel.*

De auteurs melden een geval van distractie-flexie subluxatie van de cervicale wervelkolom waarbij tijdens de posterieure fixatie een grote scheur in de dura met

lekkage van het cerebrospinale vocht werd gevonden. Er was geen neurologisch deficiet initieel. Dergelijke casus werd nog niet gerapporteerd. De optimale behandeling wordt voorgesteld en het resultaat wordt beschreven.

### RÉSUMÉ

*D. DE GELB, L. LENKE, J. POND. Brèche dure-mérienne associée à une subluxation du rachis cervical par flexion-distraktion sans lésion neurologique.*

Les auteurs rapportent un cas inhabituel de lésion traumatique du rachis cervical par flexion distraction, sans déficit neurologique au départ, et chez qui ils ont constaté l'existence d'une large brèche de la dure-mère, avec fuite de liquide céphalo-rachidien, au cours d'une opération de stabilisation par voie postérieure. La survenue de brèches dure-mériennes à l'occasion d'un traumatisme cervical sans lésion neurologique grave n'avait pas été rapportée antérieurement. Les auteurs proposent un traitement optimal de ce problème inhabituel et ils présentent les résultats de leur traitement.