

# GANGLIA OF THE SUPERIOR TIBIOFIBULAR JOINT : REPORT OF THREE CASES AND REVIEW OF THE LITERATURE

F. DE SCHRIJVER, J. P. SIMON, L. DE SMET, G. FABRY

**Ganglion cysts that compress the common peroneal nerve frequently arise from the proximal tibiofibular joint. We report three cases of such ganglia. In one case the ganglion cyst arises from the proximal tibiofibular joint, finds its course along the common peroneal nerve causing pain, but no neurological deficit. In the two other cases the cysts have the same origin but they are the cause of a progressive peroneal nerve palsy. Treatment in these three cases was successful resection of the cyst with non mutilating surgery for the nerve and ligation of the stalk connecting the ganglion to the proximal tibiofibular articulation. A review of the controversial pathogenesis of the intra- and extra-neural ganglia is exposed, and the anatomy, the diagnosis, the surgical treatment and the prognosis is discussed in light of relevant literature.**

**Keywords :** knee ; synovial cyst ; paralysis.

**Mots-clés :** genou ; kyste synovial ; paralysie.

---

## INTRODUCTION

During its course the common peroneal nerve passes around the lateral surface of the fibular neck, where it lies in an extremely vulnerable position. Injury at this site is common.

The common peroneal nerve is in fact the most commonly damaged nerve in the lower limb. Next to traumatic lesions in connection with laceration or traction due to fibular neck fracture or superior dislocation of the fibular head (11, 14), compression is by far the most common cause of peroneal nerve palsy. Compression may cause nerve dysfunction by both a single episode (during surgery or postoperatively, often in patients who are emaciated or bedridden, or having an ill-fitted plaster cast) and by repeated episodes (habitual leg crossing, yoga positions ...). True entrapment of the nerve within the fibular tunnel is probably rare.

It may be caused by a thickened fascia (8), by nonspecific fibrosis at and above the fibular head (17), by the origin of the peroneus longus muscle (19), by an actively contracting soleus muscle, seen in kneeled farmworkers (18) and by gastrocnemius muscle herniation (1).

Various intrinsic and extrinsic masses around the knee (eg. ganglion cysts, intraneural cysts, cysts arising from the lateral meniscus) are relatively common causes for compression neuropathy (5).

The vast majority of these lesions are sufficiently severe to cause foot drop.

We describe three cases of ganglion cysts arising from the superior tibiofibular joint, and discuss the involvement of surrounding structures such as the common peroneal nerve.

## CASE REPORTS

### Case 1

A 36-year old woman complained of aching pain and swelling over the outer aspect of the leg below the fibular head. The pain was aggravated by exercise, which also produced radiation of pain over the peroneal muscles to the ankle. Four local infiltrations with steroids were given with only temporary relief and a diagnostic arthroscopy was performed, without any specific findings, before she presented at our clinic.

On examination there was an ill-defined swelling over the lateral head of the left gastrocnemius muscle and over the fibular head. There was no subjective or objective evidence of compression of

---

Department Of Orthopaedic Surgery, U.Z. Pellenberg, Weligerveld 1, B-3212 Pellenberg, Belgium.

the common peroneal nerve : there was no muscle weakness or sensory impairment.

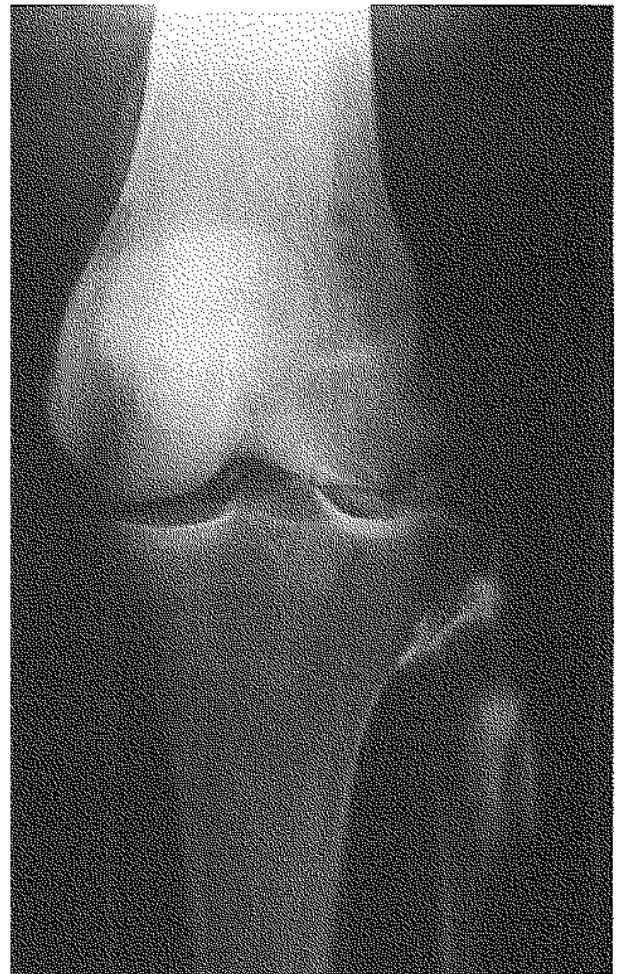
Ultrasound showed a long-stretched cyst under the fascia of the lateral gastrocnemius muscle, with a small defect in this fascia. MRI affirmed a cyst with hypo- to isointensity on T1 and hyperintensity on T2 images, posterior to the proximal tibiofibular joint. A connection to this joint could not be shown, but could be suspected on the raised amount of intra-articular fluid. CATscan, after radioscopic controlled intra-articular infiltration of the proximal tibiofibular joint with contrast-fluid, revealed a connection of the synovial cyst to the joint (fig. 1).

At operation a large cystic structure was found, firmly adherent to the common peroneal nerve and to the capsule of the superior tibiofibular joint from which it appeared to arise. The ganglion was excised and the stalk to the proximal tibiofibular joint was traced. A fenestration of this joint was performed. Histologic studies revealed a fibrous-walled cyst with no specialized lining cells, but some fibroblasts, some mononuclear inflammatory cells and a rich vascular pattern in the cyst wall. A final diagnosis of a synovial cyst was made. Six weeks after operation she was symptomless. The ganglion did not recur within two years.

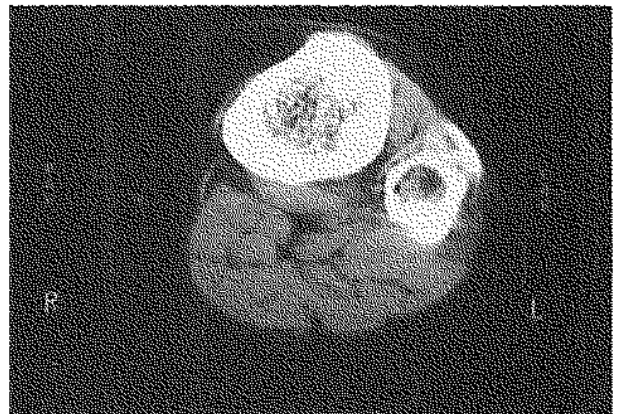
## Case 2

A 56-year old clerk, with a history of chronic low back pain due to lumbar disc disease, complained of an aching pain, presenting in intermittent episodes, over the proximal anterolateral side of the right leg. Pain started at the fibular head and radiated down over the peroneal muscles to the foot and ankle. Sometimes pain was so severe that he was unable to stand. Two weeks before he was admitted in our hospital, pain suddenly aggravated and the patient presented with numbness on the lateral side of the leg and dorsum of the foot together with foot drop. These neurologic findings seemed to be progressive in time.

Physical examination revealed an impaired gait with a manifest limp and a slight lump on the lateral aspect of the right knee. This lump, with severe point tenderness, was overlying the region



a



b

*Fig. 1.* — Case 1 : intra-articular infiltration of the proximal tibiofibular joint with contrast medium. A : Radioscopic control ; B : CAT-scan.

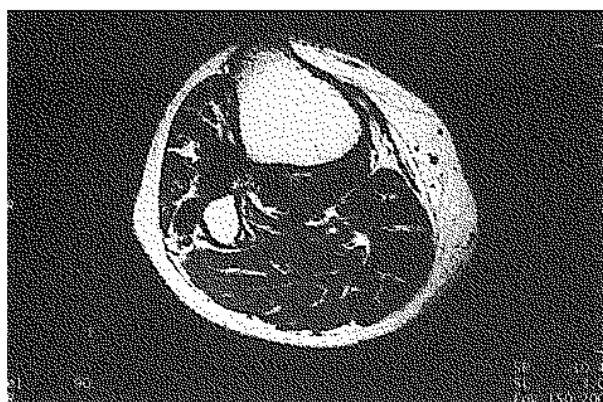of the fibular head. There was total paralysis of the muscles supplied by the deep peroneal nerve together with numbness and paresthesia on the anterolateral side of the leg and the dorsum of the foot. Because of the drop out of the common peroneal nerve, a local lesion on this level was most probable.

MRI of the right knee showed an oval mass laterodorsal to the fibular head, slightly extending distally. The mass exhibited a decreased signal intensity on T1 and increased signal intensity on T2 weighted images (fig. 2). A connection to the proximal tibiofibular joint could be shown. In the tibialis anterior (TA) muscle an increased signal intensity was seen probably due to oedema caused by beginning denervation due to neural compression.

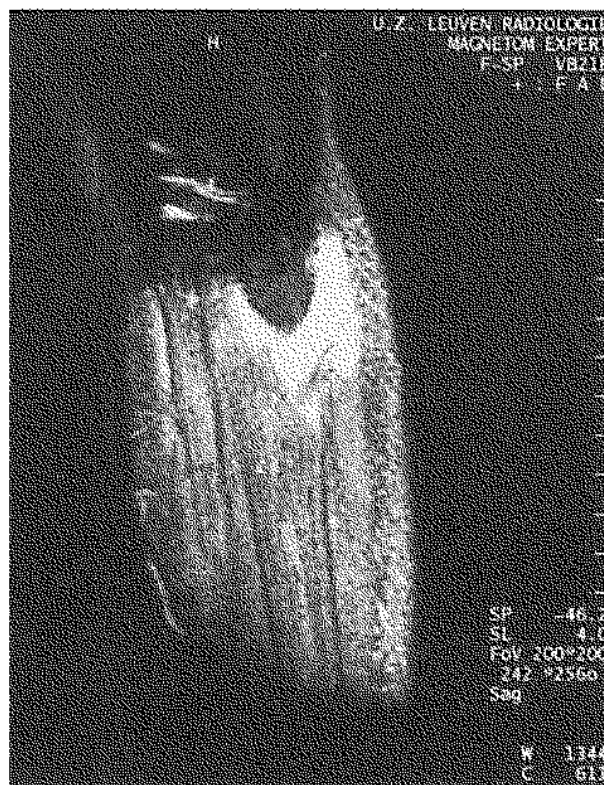
Electromyographic findings suggested on outspoken denervation-activity in the innervation area of the right common peroneal nerve. In the root area S1 there was also some degeneration with pathologic findings in the biceps femoris muscle.

The patient underwent surgery for exploration of the peroneal nerve. A ganglion approximately 3 cm in diameter was found, which originated in the superior tibiofibular joint. The cyst reached the parent peroneal trunk, which it invaginated and compressed, along its sensory branch to the tibiofibular joint.

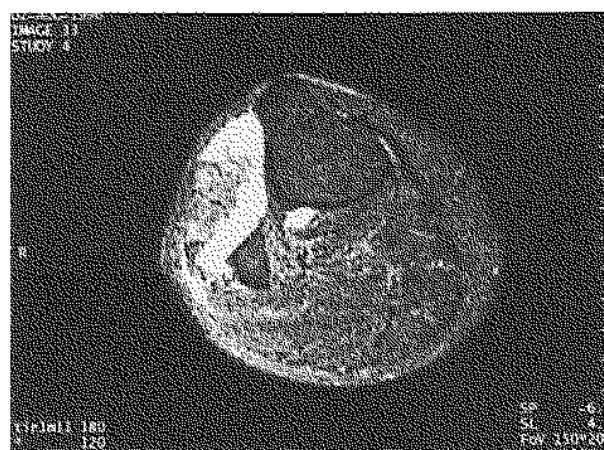
During excision of the cyst, this sensory branch had to be sacrificed. Total excision was not possible because of invagination of the nerve. The stalk was dissected down to the tibiofibular joint.



a



b



c

**Fig. 2.** - Case 2: On MRI the ganglion typically exhibits low signal intensity on T1 weighted images (A) and increased signal intensity on T2 weighted images (B : sagittal window ; C : axial window).

At four weeks follow-up there was a complete relief of pain at the proximal tibiofibular joint and a remarkable improvement of strength of the TA muscle. The extensor hallucis longus (EHL) muscle though was still rather weak. The area of paresthesia diminished progressively downwards.

Three months after operation complete relief of symptoms was obtained. On clinical examination there was a near normal strength in the TA muscle. The strength of the extensor digitorum longus (EDL) and the EHL muscle were improving. EMG showed signs of reinnervation in all.

### Case 3

An 11-year old girl complained of an aching pain and a swelling over the fibular head. The pain suddenly started at night and was so severe that emergency clinic was attended. Initial clinical examination that night showed a slight swelling over the outer aspect of the right proximal tibiofibular joint. X-rays were normal. Next day, there was a more marked swelling and a clear foot drop. Ultrasound showed an irregular, hyporeflexive structure with connection to the proximal tibiofibular joint. CT-scan confirmed these findings. Electromyographic findings were compatible with a compression neuropathy of the deep branch of the common peroneal nerve at the site of the fibular head.

That same day the patient underwent surgery for exploration of the nerve. A ganglion,  $2 \times 1 \times 1.5$  cm in size, with origin in the proximal tibiofibular joint, was found. The ganglion was very adherent to the deep branch of the common peroneal nerve, the superficial branch was only slightly compressed. Total excision was attempted.

Histologic studies revealed myxoid degeneration compatible with a ganglion of the proximal tibiofibular joint.

Postoperatively she was treated with an anti-foot drop polyethylene splint, fixed in neutral ankle position, and physiotherapy. Two months after operation there was a full recovery of the motor function with minimal numbness on the lateral side of the leg and in the first web space.

## DISCUSSION

### Anatomy

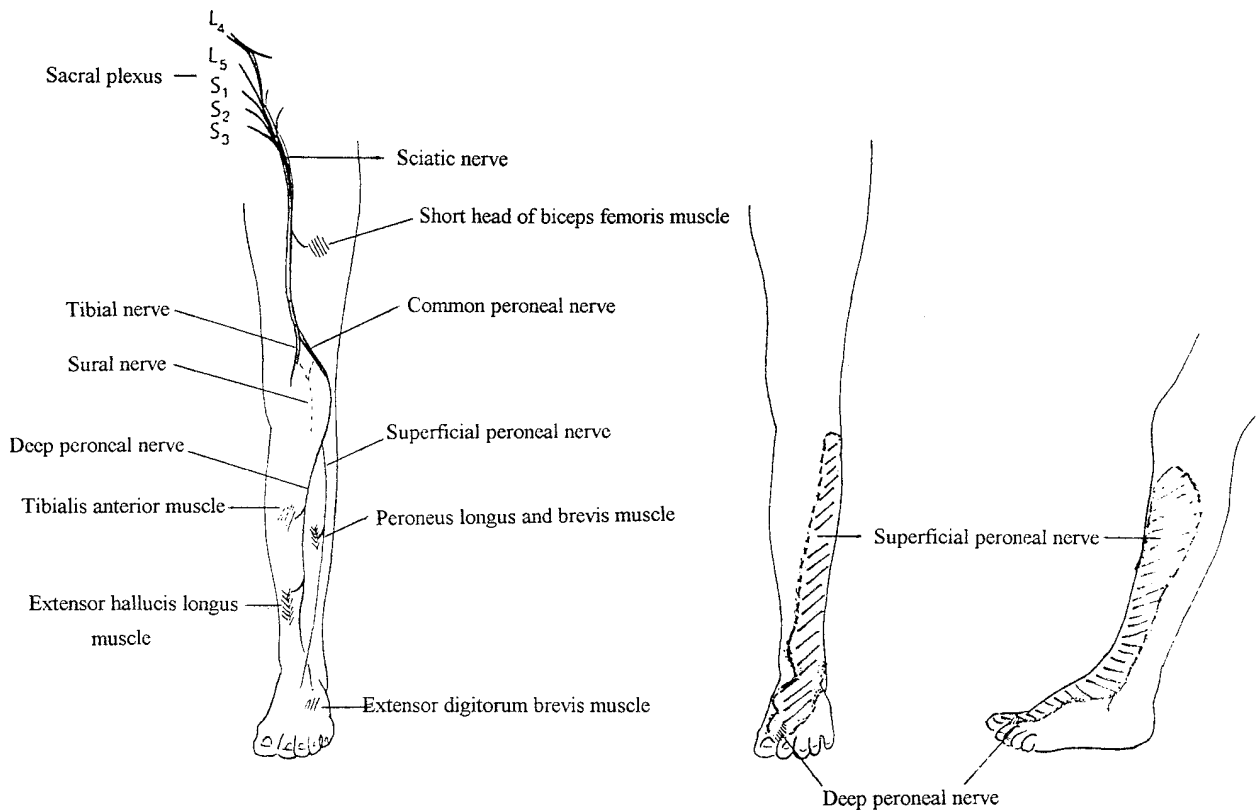
The proximal tibiofibular joint consists of the articulating surfaces of the upper end of the fibular head and the tibial lateral condyle. Both these surfaces are covered with hyaline cartilage. This joint is lined by a synovial membrane and is often in communication with the knee joint. The joint is surrounded by an articular capsule which is reinforced by the anterior and the posterior ligaments. The biceps tendon inserts on the anterior portion of the styloid process of the proximal fibula. This insertion is however divided by the lateral collateral ligament (2, 4, 24).

The morphology of the proximal tibiofibular joint is classified by Ogden (15) in a horizontal and an oblique type. By definition  $20^\circ$  is considered the limit of horizontal type joint inclination.

The common peroneal nerve is the smaller division of the sciatic nerve. Its main root origin is from L5, with less from S1/S2 and least from the L4 root (mainly motor supply to the TA muscle). Its first motor branch, and the only one originating proximal to the fibular head, arises in the mid thigh and innervates the short head of the biceps femoris muscle.

The sciatic nerve grossly separates into its common peroneal and tibial components at, or proximal to, the popliteal fossa. A sensory branch (the lateral cutaneous sural nerve) arises from the common peroneal component and fuses with a sensory branch arising from the tibial component, to form the sural nerve. The common peroneal nerve gives off two other small branches: the ramus articularis and a communicating fibular branch.

More distally the nerve deviates laterally in the popliteal fossa to the anterolateral portion of the proximal leg, by arching around the posterior aspect of the fibular head. At this level the nerve enters the peroneal muscle mass and is covered with a fascia, which is continuous with the deep transverse fascia separating the flexor digitorum longus muscle and the soleus muscle. This fascia is sometimes thickened and can lead to entrapment (8).



**Fig. 3.** — The peroneal nerve : its origins, anatomy and sensory distribution.

At the level of the fibular neck the nerve continues in the muscle mass in a posterior-anterior direction, approximately 25 mm. distal to the tip of the fibular head. It then divides into its deep and superficial peroneal nerve terminations (fig. 3).

The deep branch passes obliquely from the lateral to the anterior compartment, through the intermuscular septum, and runs away from the fibula. First it follows a path beneath the EDL muscle, then between the EDL and the TA muscle. The deep peroneal nerve is primarily motor : it innervates all the anterior leg compartment muscles (EDL, EHL and particularly the TA muscle) and the extensor digitorum brevis muscle on the dorsum of the foot. The nerve ends with a terminal sensory branch to the first web space.

After arising from the common peroneal nerve, the superficial peroneal nerve traverses the lateral compartment. First it runs in the long peroneal

muscle. At the junction of the proximal and middle thirds, it runs between the peroneal muscles and the EDL muscle. At the level of the distal one-fourth of the leg, it passes through the fascia and runs in the superficial subcutaneous tissue to divide into terminal sensory branches. So the superficial peroneal nerve supplies both sensation to the anterolateral aspect of the leg and the whole dorsum of the foot (except the small innervation area supplied by the deep peroneal nerve) and also motor innervation to the peroneus longus and brevis muscles in the lateral compartment.

**Pathology**

The predisposing factors responsible for the formation of ganglion cysts are by no means certain and the origin of ganglion cysts adjacent

to the common peroneal nerve is disputed. We report three cases in which the proximal tibiofibular joint was involved. As Parkes (16) described, the ganglia in two of our three cases arose from the joint and passed along the sheath of a small recurrent (superior tibiofibular articular) sensory branch of the common peroneal nerve to the main nerve trunk. Once the ganglion has reached the main sheath, situating itself within it, the intraneural tissue planes offer little resistance to its (marked) extension. Brooks (3) also found a clear connection of the cyst with the proximal tibiofibular joint. Stack *et al.* (21) found such a connection in only 3 of 9 cases, as did Nucci *et al.* (13) in 40% of their 60 cases. Ghossain (7) makes a classification of the ganglia into intra- and extraneural cysts. Three possible theories have been suggested about the origin of these cysts. First, there is the synovial theory, which is currently believed to be the right one (3, 12, 13), based on the anatomical origin and the course of the ganglion and the histological pattern with its endothelial type lining. Secondly there is the degenerative theory which is based on cystic degeneration of the periarticular tissues. Those who consider that a ganglion of the nerve sheath is a separate entity, maintain that trauma to the nerve is an important etiological factor (23). Finally there is the tumor theory based on cystic degeneration of certain schwannomas type Antoni B. Brooks (3) believes the distinction between cystic degeneration of the nerve sheath and a simple ganglion to be anatomical rather than pathological, one being intraneural, the other extraneural.

It is a well known fact that a simple ganglion arising from a joint can cause compression of an adjacent nerve and interfere with its conductivity causing motor and sensory disturbances in the distribution area of the nerve. The pathology of compression neuropathy is controversial regarding the role of induced ischemia versus pressure on the nerve itself.

### Signs and symptoms

Compression to the common peroneal nerve has a quite typical presentation. Spontaneous pain

is first localised to the upper lateral aspect of the leg and may then be referred downward, following the innervation area of the superficial peroneal nerve, to the dorsum of the foot and toes. There is local tenderness postero-laterally adjacent to the fibular neck. The motor weakness develops progressively. The key to the diagnosis is the local swelling, which is unfortunately not always palpable.

Muscle weakness is more common than sensory impairment. Almost all patients with compression neuropathy of the common peroneal nerve have TA muscle weakness as their main complaint (9, 12, 24). Most patients also have weakness of foot evertors as well as foot dorsiflexors and toe extensors, because of involvement of the superficial peroneal fibers that innervate the lateral compartment muscles. Sensory loss is of little importance clinically and if it is present, it is limited to just large myelinated fiber function, i.e. vibration and position sense. The small myelinated and unmyelinated fibers (conduction of pain and temperature) are spared.

Sometimes it is hard to make a differential diagnosis with sciatic nerve mononeuropathy, lumbosacral plexopathy or L5 radiculopathy. The combination of radiculopathy with a peripheral nerve lesion should be considered. Otherwise, neural activation of dorsal root ganglion by peripheral nerve lesions can theoretically cause referred pain similar to primary lumbar pain syndromes (e.g. proximal pain complaints in carpal tunnel syndrome) (17).

The diagnosis of these lesions rests on the clinical evidence and on the technical investigations, chiefly electromyographic and CT scanning or MRI. Conventional radiographs of the upper tibia and fibula and the knee joint are usually normal. The presence of an intraosseous ganglion in the head or neck of the fibula may sometimes give an indication of a ganglion causing common peroneal nerve compression. Ultrasonography has been successfully used to demonstrate ganglia and to confirm the cystic nature of the mass and therefore distinguish it from solid tumors. CT is a good choice for the detection and precise localisation of soft tissue tumors because of its ability to display the anatomy in an axial plane,

and to distinguish between small differences in the attenuation of various soft tissue components (6). In our first case CT was not able to visualize the stalk connecting the cyst to the proximal tibiofibular joint. Arthrography of this joint with injection of contrast medium contributed to the diagnosis (fig. 1).

MRI is currently superior to CT in the evaluation of soft tissue tumors because of its inherent image contrast and its ability to provide direct sagittal and coronal images (10). The ganglion cyst in two of our three cases typically exhibited low signal intensity on T1 weighted images and increased signal intensity on T2 weighted images (fig. 2).

Electrophysiological tests, including EMG and motor and sensory nerve conduction velocity tests, are of great value with respect to the localisation and degree of involvement. Common peroneal nerve mononeuropathy produces a limited number of EMG patterns (24) :

1. Axon loss (conduction failure) pattern (partial or complete).
2. Conduction block pattern (partial or complete).
3. Mixed axon loss — conduction block pattern.
4. L5 radiculopathy — proximal deep peroneal mononeuropathy axon-loss pattern.

A conduction failure due to axon loss is the most common presentation (9, 13, 24).

An important question is whether or not the first clinical and/or electrophysiological examination can predict the outcome. Smith (20) demonstrated that decreased sensory conduction velocity in the distal segment and/or abnormal motor conduction (distal to the fibular head) and a reduced or absent motor response with stimulation distal to the fibular head was seen in patients who made an incomplete recovery.

### Treatment

Although a few authors (13) argue for total excision of the cyst after accurate dissection using an operating microscope, we prefer, in agreement with previous reports (3, 7, 12, 21, 22, 23) to subtotally excise the intraneural cyst and achieve decompression of the tumor by longitudinally

incising it under microscope and emptying the viscous contents. This subtotal excision does not favor recurrence and destruction of nerve fibers is avoided. It is important to excise the stalk and its base in the superior tibiofibular joint so as to lessen the risk of recurrence. Sometimes the small sensory articular branch of the joint has to be sacrificed.

It is generally believed that the prognosis of peroneal nerve palsies of compressive origin is excellent. When conservatively treated, recovery may take 1 or 2 years and it may be incomplete, requiring the patient to use a peroneal brace. Instead recovery is much faster after operative decompression (22), and will take place after a few days or a few weeks.

The interruption of nerve conductivity is due to simple compression and the severity of nerve lesion is dependent upon the degree and duration of the compression. When compression is relieved, conductivity is usually completely restored. Stack (21) noted a good or excellent recovery of motor function if surgical exploration was done less than one year after onset of foot drop. The course of recovery reflects the type of damage induced to the nerve ; an immediate recovery indicates a metabolic block, whereas recovery over a period of weeks reflects a neurapraxia, i.e. a local conduction block based on myelin damage, but still axonal continuity. Cases requiring several months or 1 year to recover probably indicate axonal degeneration.

### CONCLUSION

External compression must be considered in all patients with symptoms of pain, paresthesia or paresis in the distribution of the common peroneal nerve, particularly if there is no history of trauma, or if there is a palpable mass present at the fibular neck.

Any delay in diagnosis or treatment will lead to poorer long term recovery. Excision of the ganglion with non-mutilating surgery for the nerve and ligation of the stalk connecting the ganglion to the proximal tibiofibular joint must be performed.

## REFERENCES

1. Alhadeff J., Casey K. Gastrocnemius muscle herniation at the knee causing peroneal nerve compression resembling sciatica. *Spine*, 1994, 20, 612-614.
2. Aydogdu S. Peroneal dysfunction after high tibial osteotomy. An anatomical cadaver study. *Acta Orthop. Belg.* 1996, 62, 156-160.
3. Brooks D. Nerve compression by simple ganglia. A review of thirteen collected cases. *J. Bone and Joint Surg.*, 1952, 34-B, 391-400.
4. Brown R., Storm B. Congenital common peroneal nerve compression. *Ann. Plast. Surg.*, 1994, 33, 326-329.
5. Edwards M., Hirigoyen M., Burge P. Compression of the common peroneal nerve by a cyst of the lateral meniscus: a case report. *Clin. Orthop.*, 1995, 316, 131-133.
6. Firooznia H., Golimbu C., Rafii M., Chapnick J. Computerized tomography in diagnosis of compression of the common peroneal nerve by ganglion cysts. *Computerized Radiol.*, 1983, 7, 343-345.
7. Ghossain M., Mohasseb G., Dagher F., Ghossain A. Compression du nerf sciatique poplitée externe par un kyste synovial. *Neurochirurgie*, 1987, 33, 412-414.
8. Jeyaseelan N. Anatomical basis of compression of peroneal nerve. *Anat. Anz.*, 1989, 169, 49-51.
9. Katiirji M., Wilbourn J. Common peroneal mononeuropathy: a clinical and electrophysiologic study of 116 lesions. *Neurology*, 1988, 38, 1723-1728.
10. Leon J., Marano G. MRI of peroneal nerve entrapment due to a ganglion cyst. *Magnetic Resonance Imaging*, 1987, 5, 307-309.
11. Levy M. Peroneal nerve palsy due to superior dislocation of the head of the fibula and shortening of the tibia. *Acta Orthop. Scand.*, 1975, 46, 1020-1025.
12. Muckart R. D. Compression of the common peroneal nerve by intramuscular ganglion from the superior tibiofibular joint. *J. Bone and Joint Surg.*, 1976, 58-B, 241-244.
13. Nucci F., Artico M., Bardella L., Delfini R., Bosco S., Palma L. Intraneural synovial cyst of the peroneal nerve: report of two cases and review of literature. *Neurosurgery*, 1990, 26, 339-344.
14. Ogden J. A. Subluxation of the proximal tibiofibular joint. *Clin. Orthop.*, 1974, 101, 192-197.
15. Ogden J. A. The anatomy and function of the proximal tibiofibular joint. *Clin. Orthop.*, 1974, 101, 186-191.
16. Parkes A. Intraneural ganglion of the lateral popliteal nerve. *J. Bone and Joint Surg.*, 1961, 43-B, 784-790.
17. Saal J., Dillingham M., Gamburd R., Fanton G. The pseudoradicular syndrome; lower extremity peripheral nerve entrapment masquerading as lumbar radiculopathy. *Spine*, 1988, 13, 926-930.
18. Sandhu H., Sandhey B. Occupational compression of the common peroneal nerve at the neck of the fibula. *Austr. and New Zealand J. of Surg.*, 1976, 46, 160-163.
19. Sidey J. Weak ankles. A study of common peroneal nerve entrapment neuropathy. *British Medical Journal*, 1969, 3, 623-626.
20. Smith T., Trojaborg W. Clinical and electrophysiological recovery from palsy. *Acta Neurol. Scand.* 1986, 74, 328-335.
21. Stack R., Bianco A., MacCarty C. Compression of the common peroneal nerve by ganglion cysts. Report of nine cases. *J. Bone and Joint Surg.*, 1965, 47-A, 773-778.
22. Vastamäki M. Decompression for peroneal nerve entrapment. *Acta Orthop. Scand.*, 1986, 57, 551-554.
23. Wadstein T. Two cases of ganglia in the sheath of the peroneal nerve. *Acta Orthop. Scand.* 1931, 2, 221-231.
24. Wilbourn J. AAEE case report °12: common peroneal mononeuropathy at the fibular head. *Muscle & Nerve*, 1986, 9, 825-836.

## SAMENVATTING

*F. DE SCHRIJVER, J. P. SIMON, L. DE SMET, G. FABRY. Cyste van het proximale tibio-fibulaire gewricht.*

Wij presenteren 3 patiënten waarbij een cyste van het proximale tibio-fibulaire gewricht pijnklachten rondom het kniegewricht veroorzaakt geassocieerd met neurologische uitval in de regio van de nervus peroneus communis bij 2.

Als besluit stellen wij dat bij elke patiënt met pijnklachten, paresthesiën of parese in de innervatieregio van de nervus peroneus communis, externe compressie van de zenuw tot de lijst der differentiële diagnoses moet behoren, zeker in het geval dat er geen trauma aan voorafging, of dat er een massa palpabel is overheen de proximale fibula.

Enig uitstel in diagnose of behandeling leidt tot een moeilijkere heling op lange termijn. Niet-mutilerende chirurgie met excisie van de cyste en onderbinding van de connectie met het proximale tibio-fibulaire gewricht is te verkiezen.

## RÉSUMÉ

*F. DE SCHRIJVER, J. P. SIMON, L. DE SMET, G. FABRY. Les kystes à point de départ au niveau de l'articulation tibio-péronière proximale.*

Les auteurs rapportent l'observation de trois patients qui présentaient des douleurs dans la région du genou, en rapport avec un kyste dont le point de départ était



l'articulation tibio-péronnière proximale. Deux patientes présentaient une paralysie du nerf sciatique poplité externe et une atteinte sensitive dans le même territoire. Une compression externe doit être envisagée chez tous les patients qui se plaignent de douleurs, de paresthésie ou de parésie dans le territoire du nerf sciatique poplité externe, surtout dans le cas où il n'y a pas d'antécédent

traumatique ou lorsqu'il y a une masse palpable au col du péroné. Un retard diagnostique ou l'absence de traitement efficace se solde par une récupération moins bonne. L'excision non mutilante de ce kyste avec ligature de sa connexion avec l'articulation tibio-péronnière proximale est le traitement de choix.