

THE UNREAMED AO FEMORAL INTRAMEDULLARY NAIL, ADVANTAGES AND DISADVANTAGES OF A NEW MODULAR INTERLOCKING SYSTEM

A PROSPECTIVE STUDY OF 67 CASES

P. BROOS, P. REYNDERS

Compared with the Reamed Femoral Nail (RFN), the Unreamed Femoral Nail (UFN) has some theoretical advantages. It can also be used for subtrochanteric fractures and ipsilateral fractures of the femoral neck, there is less iatrogenic damage to the vascularisation of the bone, the risk of fat embolism syndrome and ARDS is reduced and the operation is a less time consuming procedure, associated with less blood loss. From April 1995 to July 1996, 66 patients with 67 fractures have been treated with the UFN : 16 patients with metastatic disease, 18 patients with a subtrochanteric fracture, 32 patients with 33 diaphyseal fractures. In 6 cases however, previous reaming was necessary. The spiral blade (SB) was used 35 times. Four patients died within six months after the operation.

Fat embolism syndrome or ARDS were never observed. Five mechanical complications were observed in four patients. In one patient with a metastatic fracture, we noted a breakage of the SB twice. Migration of the SB was observed three times needing reintervention twice. Delayed union needing reaming with a reamed nail was observed twice. The reoperation rate for all patients treated with an UFN-SB was 9%. For diaphyseal fractures, the rate of delayed-union was 6%. This complication was only observed in open fractures. We concluded that the UFN is a safe and less severe procedure than the reamed nail in multiply injured patients. For subtrochanteric fractures, the UFN-SB is a useful implant, but not superior to other methods of treatment. As a definitive treatment for a femoral fracture primarily stabilized with an external fixator, we strongly suggest to carry on using a reamed nail.

Keywords : femoral nail ; femoral shaft fractures ; subtrochanteric fractures ; pathological fractures.

Mots-clés : clou fémoral ; fractures de la diaphyse fémorale ; fractures sous-trochantériennes ; fractures pathologiques.

INTRODUCTION

In 1994, the AO introduced a modular interlocking system of unreamed femoral intramedullary nail (UFN) (11). When using the interlocking technique with the spiral blade (SB), this implant can also be used for subtrochanteric fractures.

Since April 1995, this UFN was used in the University Hospitals of Leuven. Special attention will be given to the following items : is unreamed femoral nailing a safe procedure as to the risk of fat embolism syndrome and ARDS ? Is the UFN with the SB a superior implant for the treatment of subtrochanteric fractures ? Is the UFN indicated for delayed nailing of open fractures initially treated with an external fixator ?

Department of Traumatology and Reconstructive Surgery,
U.Z. Gasthuisberg, Katholieke Universiteit Leuven.

Correspondence and reprints : P. Reynders, U.Z. Gasthuisberg, Herestraat 49, B-3000 Leuven.

MATERIALS AND METHODS

From 1st. April 1995 to 31st. July 1996, 66 patients with 67 fractures were treated with a UFN in the University Hospital Gasthuisberg Leuven. Thirty-eight patients were women (58%), twenty-eight (42%) were men. The average age of the whole group was 55 years, ranging from 14 to 99 years. Distinction has to be made between three groups of patients: 16 patients with metastatic disease, 18 patients with subtrochanteric fractures, 32 patients with 33 diaphyseal fractures.

In the group of pathological fractures, we had 11 women and 5 men with an average age of 57 years, ranging from 49 to 74 years. In seven cases, breast carcinoma was the primary tumor.

In the subtrochanteric group, there were 12 women and 6 men with a mean age of 70 years, ranging from 22 to 99 years. In 14 cases, the fracture was due to a simple fall, in one case to a traffic accident.

In two of the 33 diaphyseal fractures, there also was an associated fracture of the femoral neck; two fractures were segmental fractures. There were 24 men (one with a bilateral fracture) and 8 women. The average age was 37 years, ranging from 14 to 77 years. In 20 cases, the fracture was due to a traffic accident, in 10 cases to a fall from a height, in one case to a crush injury and in another one to a simple fall. Nineteen of these patients had associated injuries (thoracic trauma in six). The mean ISS was 24.3, ranging from 8 to 38. Three of these fractures were open fractures (9) and six closed fractures had soft tissue damage grade 2 as to Tscherne (26).

For the whole group, a 9-mm nail was chosen 28 times and a 12-mm nail 15 times. It is important to mention that in five cases the endomedullary canal was too narrow even for the smallest nail and in these cases reaming was necessary. The standard interlocking technique was used twenty-nine times, the SB thirty-five times and the "miss-a-nail" technique twice. In one case of metastatic disease of the femoral shaft as well as of the ipsilateral acetabulum, a retrograde technique was the only way to stabilise the femoral lesion. In six cases of subtrochanteric fractures a suitable closed reduction was not possible. In these cases additional Partridge bands were also used (fig. 1).

All patients were followed-up prospectively for at least six months or until their death. Special attention was given to the mechanical complications and bone healing. We considered bone healing to be delayed if no progressive healing was observed on serial x rays after 4 months.

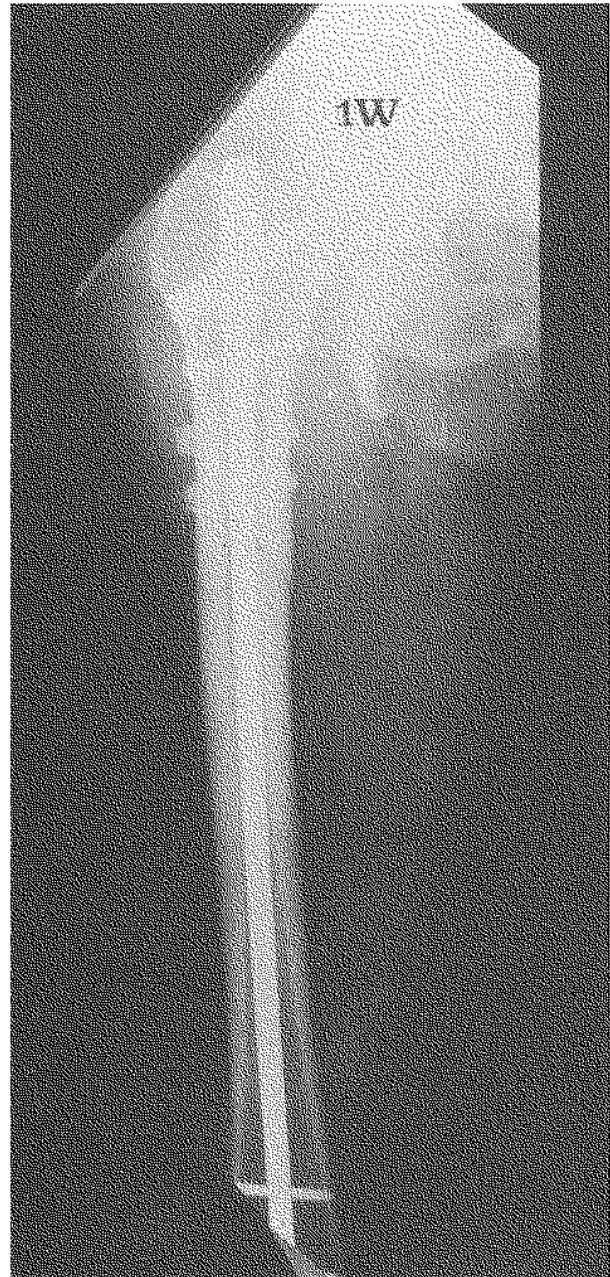

Fig. 1. — Subtrochanteric fracture treated with UFN-SB and Partridge bands.

RESULTS

We never had to deal with a fat embolism syndrome, nor with ARDS. All patients were allowed to walk bearing full weight on the operated leg as soon as possible, taking their associated

lesions or underlying disease into account. Three old patients with a subtrochanteric fracture and one polytrauma patient with a shaft fracture and untreatable brain damage died within six months after injury. In one patient, we noted a breakage of the spiral blade twice. It was a 49 year-old lady with metastatic disease due to a colon carcinoma. Eight months after the operation, the whole femur was destroyed by the malignant process and failure of the blade occurred. Removal of the nail and reinsertion of another UFN-SB with different angle and reinforced by bone cement was the salvage procedure. The patient was able to walk again, but five months later the new blade was broken again due to tumor progression. As the patient was in a pre-terminal state no reintervention was performed. In this case, the mechanical complication was due to the underlying disease and not to the weakness of the implant (fig. 2).

For the non-pathological fractures, the radiological evolution was followed. In patients with a subtrochanteric fracture, migration of the spiral blade took place three times. In a 84 year-old lady, this fortunately caused no pain nor varus deformity and a reintervention was not necessary. In the other two patients however, refixation using a dynamic hip screw with trochanter plate was a definitive solution (reintervention rate for subtrochanteric fractures : 13%). In the other cases no healing problems were observed.

In thirty diaphyseal fractures, the evolution was uneventful. Delayed union was observed twice (6.25%). Both of them were open fractures initially treated with an external fixator. In one case, the UFN was dynamised three months post-injury. Because of delayed union, the unreamed nail was replaced by a reamed nail four and five months after the initial injury. In one case the fracture healed ; in the other there was no complete bone healing after thirteen months despite adjacent bone grafting.

So, for the whole group the reoperation rate and the rate of mechanical complications were 7% (5 each out of 67). As all mechanical complications occurred in patients treated with an UFN-SB, the complication rate (5 patients) and the reintervention rate (3 patients) for this group of 35 patients were 14% and 9%.




Fig. 2. — Fracture of the SB. Femur completely destroyed by metastatic disease.

For the traumatic fractures, the delayed-union/non-union rate was 4% (2 out of 47). For the diaphyseal fractures however this rate reached 6% (2 out of 32).

DISCUSSION

Thanks to the introduction of the principle of reaming by Küntscher in 1951 and the development of the interlocking nail by Klemm in the seventies, it also became possible to treat more complex spiral and comminuted fractures of the

femoral shaft by intramedullary nailing (12, 13). On the other hand, it still was not possible to stabilize epi-metaphyseal fractures and ipsilateral fractures of the neck.

In the late eighties, the AO introduced its own unreamed interlocking nails for the tibia, for the humeral shaft and now also the Modular Interlocking System of an Unreamed Femoral Nail (UFN) (11). In comparison with the reamed femoral nail, the UFN showed several theoretical and practical advantages. The implant can also be used for subtrochanteric fractures and ipsilateral fractures of the femoral neck. The operation is a less time consuming procedure, associated with less blood loss. The risk of fat embolism, ARDS and adjacent pulmonary damage is reduced. There is less iatrogenic damage to the vascularisation of the bone, so a prompt bone healing may be expected. On the other hand however, this last advantage could be neutralized by the fact that the fixation is less stable in comparison with reamed implants. As to the severity of the intervention, in previous studies we compared the operating time and blood loss in patients with a femoral shaft fracture treated with an UFN with patients with the same age and ISS treated with a conventional reamed nail. The average blood loss was 140 cc and the average operating time 70 minutes in patients treated with a UFN. In patients treated with a reamed nail, blood loss was 280 cc and operating time 125 minutes (4, 5).

The importance of early stabilization of femoral shaft fractures in polytrauma patients has already been proved many times before. Nevertheless endomedullary nailing procedures may increase the risk of "fat embolism syndrome" and ARDS, especially in patients with associated thoracic trauma (10, 16, 18, 19, 31). A prospective clinical study of Pape *et al.* showed a significant increase in pulmonary pressure during reaming. They suggested to avoid primary reamed nailing in patients with associated injuries with severe bleeding and thoracic trauma as they are predisposed to capillary damage of the lungs (19). Wenda *et al.* proved that reaming always leads to high pressure increase in the femoral cavity resulting in embolization (31). This was also observed by Neudeck *et al.* in a sheep model (16). Bone

marrow is forced into small vessels by the higher pressure and through the venous system it arrives into the lung circulation, occluding the pulmonary vessels. Neudeck *et al.* also observed a rise in intramedullary pressure leading to fat intravasation during insertion of unreamed nails in sheep (16). This mechanical effect however is not sufficient to create an ARDS. Pape *et al.* showed that fatty embolization and vessel occlusion only start a cascade of release of mediators resulting in ARDS (18). On the other hand, Heim's *in vivo* study in rabbits proved that unreamed nailing of the femur with a solid rod may also cause bone marrow embolization with alteration of pulmonary function, but associated with a significant difference of platelet activation and fibrinogen and anti-thrombin III activity (10). In clinical studies however Pape *et al.* observed no adverse effects to the lung using a UFN (18). Wenda *et al.* never observed a pressure increase greater than 70 mm Hg and no configured embolus was noted using an unreamed technique (30). They concluded that the use of the UFN during the first 24 hours posttrauma is a safe procedure even in multitrauma patients. These findings are confirmed by our own series as we never observed pulmonary embolism or ARDS after the use of the UFN.

As to the more rapid bone healing, there still exist some controversies between different authors. In 1989, Reikeras *et al.* found no significant differences in production of callus between reamed and unreamed femurs in rats (20). In a sheep model, Schemitsh *et al.* observed no difference between perfusion of callus and early strength of union following intramedullary nailing with or without reaming (25). On the other hand, also in a sheep model, Runkel *et al.* proved that bone healing was faster in a clinically relevant way after unreamed nailing (23). In rabbits, Melcher *et al.* observed an impairment of the endosteal blood supply after reaming associated with a significantly higher infection rate (14). However, in a clinical comparison concerning simple fractures of the tibial shaft, Rucholz *et al.* observed an earlier painless full weight bearing after an average of 9.7 weeks in patients treated with an unreamed nail as against 12 weeks in patients treated with a reamed nail (21).

Clinical studies concerning subtrochanteric fractures have sufficiently proved that treatment is difficult and associated with a lot of complications. The Dynamic Condylar Screw treatment is associated with a non-union rate of 20% and a reintervention rate of 12.5 to 20% (17, 24, 29).

When using a Dynamic Hip Screw or a Sliding Nail device some authors report a non-union rate of 5 to 9% and a reintervention rate of 9% (15, 22). By using an intramedullary implant type gamma nail, the prognosis cannot be improved (8, 32).

Our own previous experience with 161 subtrochanteric fractures has shown a reintervention rate of 10% : 7% in patients treated with a condylar blade plate, 8% in patients treated with a Dynamic Condylar Screw and 27% in patients treated with a gamma nail (28).

When using the UFN-SB, Hoffmann *et al.* mentioned no implant complications or loss of reduction in their first 9 patients. Fracture healing was always uneventful. In our first paper about 10 non-pathological subtrochanteric fractures, we observed two mechanical complications of which one needed a reintervention. All fractures healed within six months (5). Now as our series grew up to 15 patients with a longer follow-up, we had to deal with three complications and two reinterventions.

As to fractures of the femoral shaft, the overall results as to bone healing are very good when using the reamed interlocking nail. Bednar reported a primary healing rate of 87% in 130 patients (2). Brumback *et al.* (100 fractures) observed a union rate of 98% (6). In the series of Alho *et al.*, 123 fractures all healed within a year (1). When using the UFN in closed fractures, until now we did not observe mechanical complications nor delayed union as all healing problems occurred in open fractures. Before using the UFN in our department, grade 1 and 2 open fractures were primarily treated with a reamed nail. A temporary external fixator was used in grade 3 fractures and in multiply injured patients where primary intramedullary nailing was contraindicated. The external fixator was converted into an intramedullary nail as soon as local soft-tissue condition and the general condition of the patient allowed

(3, 27). In 1995, we reported on 57 fractures with only one case of malunion and no cases of deep infection (27). As our cases of delayed union after UFN occurred after the conversion of an external fixator, from now on we will again use a reamed nail as a definitive treatment in such cases.

CONCLUSIONS

The limited number of patients and the short follow-up period make definitive conclusions impossible. Nevertheless, the UFN has enlarged the indications for intramedullary nailing to subtrochanteric fractures and especially to femoral fractures in polytrauma patients. The procedure is safe : fat embolism syndrome and ARDS have not been observed. Compared with the reamed nail, it is an easier procedure associated with shorter operating time and less blood loss. So, the UFN is also indicated in isolated closed femoral shaft fractures and in grade 1 and grade 2 open fractures.

The results of the UFN-SB in complex subtrochanteric fractures are in our experience superior to those of other intramedullary implants such as the gamma nail, but are nevertheless still always associated with some mechanical complications. So, the problem of subtrochanteric fractures, especially in elderly patients where early weight bearing has to be made possible, is not solved. Moreover, nailing cannot always be performed as a closed procedure. Open reduction and additional Partridge band fixation was necessary in six cases.

There is probably a need to develop an implant with a smaller diameter, as a 9-mm nail cannot always be inserted without previous reaming.

A more rapid healing time cannot be proved in such a limited series, as the healing results after reamed nailing can hardly be improved.

As to fractures initially treated with an external fixator, we will carry on using a reamed nail whenever conversion is possible.

REFERENCES

1. Alho A., Stromsoe K., Ekeland A. Locked intramedullary nailing of femoral shaft fractures. *J. Trauma*, 1991, 31, 49-59.

2. Bednar D., Ali P. Intramedullary nailing of femoral shaft fractures : reoperation and return to work. *Can. J. Surg.*, 1993, 36, 464-466.
3. Broos P., Miserez M., Rommens P. The monofixateur in the primary stabilization of femoral shaft fractures in multiply-injured patients. *Injury*, 1992, 23, 525-528.
4. Broos P., Vanderspeeten K. De ongeboorde femurmergpen (UFN) : voordelen en onvolkomenheden van een nieuwe behandelingsmethode. *Nederlands Tijdschrift voor Traumatologie*, 1996, 155-161.
5. Broos P., Vanderspeeten K. Our first experiences with the Unreamed Femoral Nail (UFN). *Acta Chir. Belgica*, 1997, 97, 27-32.
6. Brumback R., Uwagie-Ero S., Lakatos R., Poka A., Bathon G., Burgess A. Intramedullary nailing of femoral shaft fractures. Part II : Fracture-healing with static interlocking fixation. *J. Bone Joint Surg.*, 1988, 70-A, 1453-1462.
7. Folsch C., Kunze K. Die Osteosynthese subtrochanterer Femurfrakturen mit der Dynamischen Kondylenschraube. *Zentralbl. Chir.*, 1993, 118, 357-360.
8. Friedl W., Colombo-Benkman M., Dockter S., Machens H. G., Meck U. Gammanagel-Osteosynthese per- und subtrochanterer Femurfrakturen. 4-Jahres-Erfahrungen und ihre Konsequenzen für die weitere Implantatentwicklung. *Chirurg.*, 1994, 65, 953-963.
9. Gustilo R., Anderson J. Prevention of infection in the treatment of 1025 open fractures of long bones. *J. Bone Joint Surg.*, 1976, 58-A, 453-458.
10. Heim D., Regazzoni P., Tsakiris D. A. *et al.* Intramedullary nailing and pulmonary embolism : does unreamed nailing prevent embolization ? An in vivo study in rabbits. *J. Trauma*, 1995, 38, 899-906.
11. Hoffmann R., Sudkamp N., Muller C., Schutz M., Haas N. Osteosynthese proximaler Femurfrakturen mit dem modularen Verriegelungssystem des unaufgebohrten AO-Femurmarknagels (UFN). Erste klinische Erfahrungen. *Unfallchirurg*, 1994, 97, 568-574.
12. Klemm K. Begründete Indikationen für den Verriegelungsnagel. *Hefte-Unfallheilk.*, 1977, 129, 84-88.
13. Küntscher G. Die Stabile Osteosynthese. *Dtsch. Z. Chir.*, 1951, 270, 444-445.
14. Melcher G., Metzendorf A., Schlegel U., Ziegler W., Perren S., Printzen G. Influence of reaming versus nonreaming in intramedullary nailing on local infection rate : experimental investigation in rabbits. *J. Trauma*, 1985, 39, 1123-1128.
15. Mullaji A., Thomas T. Low-energy subtrochanteric fractures in elderly patients : results of fixation with the sliding screw plate. *J. Trauma*, 1993, 34, 56-61.
16. Neudeck F., Obertacke U., Wozasek G., Thurnher M., Schlag G., Schmit-Neuerburg K. P. Pathophysiologische Konsequenzen verschiedener Osteosyntheseverfahren beim Polytraumatisierten. Teil I : Experimentelle Untersuchungen zur intramedullären Plattenosteosynthese am Femur. *Aktuelle Traumatol.*, 1994, 24, 114-120.
17. Nungu K. S., Olerud C., Rehnberg L. Treatment of subtrochanteric fractures with the AO dynamic condylar screw. *Injury*, 1993, 24, 90-92.
18. Pape H., Regel G., Dwenger A. *et al.* Influences of different methods of intramedullary femoral nailing on lung function in patients with multiple trauma. *J. Trauma*, 1993, 35, 709-716.
19. Pape H., Remmers D., Regel G., Tscherne H. Pulmonale Komplikationen nach intramedullärer Stabilisierung langer Rohrenknochen. Einfluss von Operationsverfahren, — Zeitpunkt und Verletzungsmuster. *Orthopäde*, 1995, 24, 164-172.
20. Reikeras O., Skjeldal S., Groggaard B. Mechanical effects of intramedullary reaming in pinned osteotomies in rats. *J. Orthop. Trauma*, 1989, 3, 53-56.
21. Ruchholtz S., Nast-Kolb D., Betz A., Schweiberer L. Frakturheilung nach Marknagelung einfacher Tibiaschaftfrakturen. Ein klinischer Vergleich gebohrter und ungebohrter Verfahren. *Unfallchirurg*, 1995, 98, 369-375.
22. Ruff M., Lubbers L. Treatment of subtrochanteric fractures with a sliding screw-plate device. *J. Trauma*, 1986, 26, 75-80.
23. Runkel M., Wenda K., Ritter G., Rahn B., Perren S. M. Knochenheilung nach unaufgebohrter Marknagelung. *Unfallchirurg*, 1994, 97, 1-7.
24. Sanders R., Regazzoni P. Treatment of subtrochanteric femur fractures using the dynamic condylar screw. *J. Orthop. Trauma*, 1989, 3, 206-213.
25. Schemitsch E., Kowalski M., Swiontkowski M., Harrington R. Comparison of the effect of reamed and unreamed locked intramedullary nailing on blood flow in the callus and strength of union following fracture of the sheep tibia. *J. Orthop. Res.*, 1995, 13, 382-389.
26. Tscherne H., Oestern H. Die Klassifizierung des Weichteilschadens bei offenen und geschlossenen Frakturen. *Unfallheilkunde*, 1982, 85, 111-115.
27. Van den Bossche M., Broos P., Rommens P. Open fractures of the femoral shaft, treated with osteosynthesis or temporary external fixation. *Injury*, 1995, 26, 323-325.
28. Vanderschot P., Vanderspeeten K., Verheyen L., Broos P. A review on 161 subtrochanteric fractures — risk factors influencing outcome : age, fracture pattern and fracture level. *Unfallchirurg*, 1995, 98, 265-271.
29. Warwick D., Crichlow T., Langkamer V., Jackson M. The dynamic condylar screw in the management of subtrochanteric fractures of the femur. *Injury*, 1995, 26, 241-244.
30. Wenda K., Runkel M., Degreif J., Ritter G. Pathogenesis and clinical relevance of bone marrow embolism in medullary nailing — demonstrated by intraoperative echocardiography. *Injury*, 1993, 25 Suppl 3, 73-81.
31. Wenda K., Runkel M. *et al.* Einfluss der Knochenmarkembolisation auf die Verfahrenswahl bei der Stabilisierung von Femurfrakturen. *Orthopäde*, 1995, 24, 151-163.
32. Wu C. C., Shih C. H., Lee Z. L. Subtrochanteric fractures treated with interlocking nailing. *J. Trauma*, 1991, 31, 326-333.

SAMENVATTING

P. BROOS, P. REYNDERS. De ongeriemde femurnagel : voordelen en nadelen van een nieuw modulair vergrendelingssysteem. Een prospectieve studie van 67 gevallen.

In vergelijking met de geriemde femurnagel (Reamed Femoral Nail) (RFN) heeft de nieuwe ongeriemde nagel (Unreamed Femoral Nail) (UFN) enkele belangrijke voordelen. De pen kan ook gebruikt worden voor subtrochantaire fracturen en voor femurschaftfracturen met ipsilaterale femurhalsfractuur. De bloedvoorziening van het bot wordt bij het inbrengen minder beschadigd. Er is minder risico op vetembolie en ARDS. De operatie kan snel worden uitgevoerd met weinig bloedverlies.

Van april 1995 tot juli 1996 werden 66 patiënten met 67 fracturen behandeld met een UFN : 16 metastatische fracturen, 18 subtrochantaire fracturen en 33 diafysaire fracturen. In 6 gevallen kon de nagel pas na voorafgaand opboren worden ingebracht. Vijfendertig maal werd het spiraalblad (SB) gebruikt als vergrendelings-systeem (UFN-SB).

Vier patiënten overleden binnen de zes maand na de operatie. Een vetemboolsyndroom of een ARDS kwam nooit voor. Bij één patiënte met een metastatische fractuur brak er tweemaal een spiraalblad. Bij drie anderen kwam het spiraalblad los. Hiervoor was tweemaal een heringreep nodig. Bij de patiënten met een diafysaire fractuur werd tweemaal een vertraagde heling waargenomen. Telkens ging het om een open fractuur die initieel met een fixateur externe was behandeld. De ongeriemde nagel werd dan door een dikke geriemde pen vervangen. Dit betekent dat in de groep behandeld met een UFN-SB in 9% van de gevallen een heringreep nodig was en dat bij de schaftfracturen in 2% vertraagde heling werd vastgesteld.

We menen dat de UFN veilig gebruikt kan worden bij polytraumapatiënten ; vetembool syndroom en ARDS werden immers niet waargenomen. Het staat nog niet vast dat de UFN-SB beter is dan andere implantaten bij subtrochantaire fracturen. Bij omvorming van een fixateur externe naar een mergnagel raden we toch aan een opgeboorde pen te gebruiken.

RÉSUMÉ

P. BROOS, P. REYNDERS. Le clou fémoral non alésé : avantages et désavantages d'un nouveau système modulaire de verrouillage. Étude prospective de 67 cas.

Comparé aux clous verrouillés classiques, le nouveau clou non-alésé (UFN) a plusieurs avantages. Il peut également être employé pour des fractures sous-trochantériennes et pour des fractures diaphysaires associées à une fracture du col ; il provoque nettement moins de dégâts de la vascularisation endoméduleuse ; le risque d'embolie graisseuse est moins élevé ainsi que celui du syndrome de détresse respiratoire de l'adulte. L'opération se fait en peu de temps et est associée à une perte de sang fort limitée.

Pendant une période de quinze mois, 66 patients avec 67 fractures ont été traités à moyen d'un UFN : 16 fractures métastatiques, 18 fractures sous-trochantériennes, 33 fractures diaphysaires. Néanmoins il fut impossible à 6 reprises d'introduire le clou sans aléser le canal médullaire. La lame spiroïde (Spiral Blade SB) fut employée 35 fois (UFN-SB).

Quatre malades moururent dans un délai de 6 mois après l'opération. On n'a observé ni embolie graisseuse, ni syndrome de détresse respiratoire de l'adulte. Chez une malade qui présentait une fracture métastatique, on a observé une rupture de la lame spiroïde à deux reprises. On a noté également la migration de la lame spiroïde chez trois malades, une réintervention étant nécessaire deux fois. Dans 2 fractures diaphysaires (2 fois une fracture ouverte originalement stabilisée au moyen d'un fixateur externe), la consolidation osseuse fut retardée. Le remplacement du clou non alésé par un gros clou alésé a été nécessaire.

Le taux de réintervention chez les malades traités par un UFN-SB a été de 9%. Pour les fractures diaphysaires, un retard de consolidation a été observé dans 2% des cas.

On peut conclure que l'UFN est indiqué chez les malades polytraumatisés ; le risque d'embolie graisseuse et d'un syndrome de détresse respiratoire de l'adulte est limité.

En ce qui concerne les fractures sous-trochantériennes, l'UFN-SB n'est pas supérieur aux autres implants.

Pour les fractures diaphysaires, originalement stabilisées au moyen d'un fixateur externe les auteurs suggèrent d'employer un clou alésé comme traitement définitif.