

ULTRASOUND ASSESSMENT OF THE ACETABULUM IN THE INFANT HIP

C. MORIN (1), S. ZOUAOUI (1), A. DELVALLE-FAYADA (2), P. M. DELFORGE (2), H. LECLLET (2)

One hundred and fifty infant hips were studied using simultaneous ultrasonography and radiography.

The reliability of measurement was found to be similar for alpha angle and d/D ratio. However, the acetabular index correlated much better with the d/D ratio than with the alpha angle. In fact, in hips where the d/D ratio exceeded 56 %, radiographs could be dispensed with. Besides, the use of a sector scanner or a linear-array transducer was found to make no significant difference to the correlation between the acetabular index and the d/D ratio.

Sonographic assessment of acetabular development in the infant should permit a reduction in the number of radiographs required during screening and follow-up.

Key words : Developmental dysplasia of the hip, ultrasonography.

Mots-clés : Dysplasie de croissance de la hanche, échographie.

INTRODUCTION

To date, various techniques have been proposed for the imaging of the infant hip to detect developmental dysplasia of the hip (ddh). Real time ultrasonography is now a well-accepted method to study the position of the femoral head in relation to the acetabulum in the neonatal period. Later on, when assessment of the bony acetabulum is concerned, radiography of the pelvis is still considered the "gold standard" by many authors. Until the osseous nucleus appears, the acetabular shape can be studied by ultrasound. The ultrasonographic assessment of acetabular development may be done using either the alpha angle method of Graf (2) or the d/D ratio method of Harcke (3).

In the pilot study describing the latter, the investigators were able to demonstrate a good correlation between the d/D ratio measured by ultrasonography and the acetabular index measured on plain radiographs. They were also able to demonstrate, thanks to a longitudinal study of 28 hips under treatment, a good correlation between the evolution of the d/D ratio and the evolution of the acetabular index (3). This study had however been conducted using a real-time sector scanner transducer instead of the presently much more commonly-used linear-array transducer. Furthermore in this initial study, the reliability of the measurements had not been checked and no comparison had been made with the alpha angle method.

In order to complete the pilot study, the present work retrospectively reviews the hips studied between 1986 and 1989 at the Institut Calot of Berck-Plage using conventional radiography and linear-array real-time ultrasonography performed at the same time.

MATERIAL AND METHODS

Population

One hundred and fifty infant hips were studied in seventy-five patients. The male-to-female ratio was 1:5. Mean age at examination was 5 months (range : 1-12

¹ Service d'orthopédie et de chirurgie réparatrice de l'enfant.

² Service d'imagerie médicale.

Correspondence and reprints : C. Morin, Service d'Orthopédie et de Chirurgie réparatrice de l'enfant, Institut Calot, 62608 Berck-Plage, France.

months). Five infants were referred for clinically unstable (dislocated or dislocatable) hips which were proved as such by sonography. Fifteen others were under treatment with Pavlik's harness. The remaining fifty-five had stable hips but were considered "at-risk" due to decreased abduction, clicks around the hip or positive family history.

Ultrasound study

All sonographies were performed with a 5 or 7.5 Mhz real-time linear-array transducer. The coronal flexion view, which is produced by keeping the transducer on the lateral aspect of the 90° flexed and slightly abducted hip, parallel to the long axis of the body, was used in all studies.

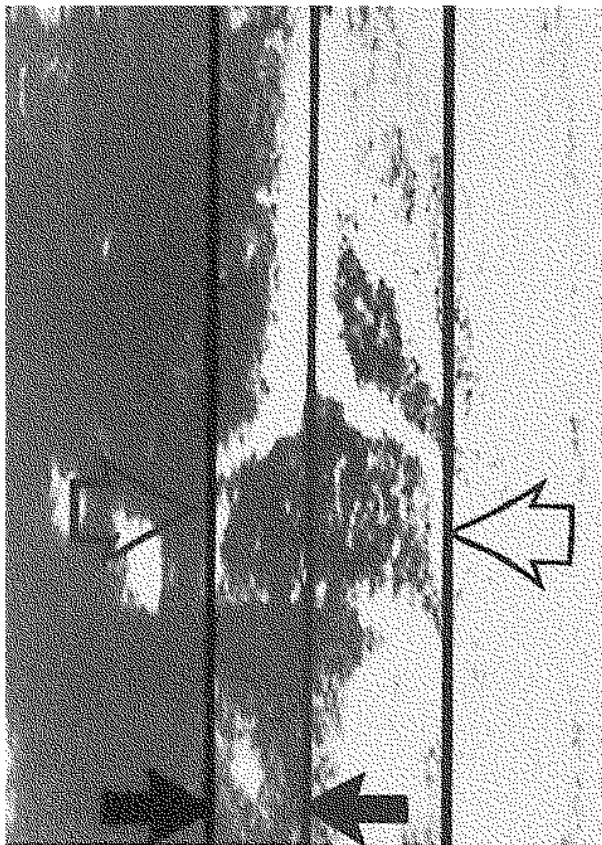


Fig. 1a. — The d/D ratio, where d is the depth of the acetabulum (measured as shown between the black arrows) and D is the diameter of the femoral head (measured as shown between the white arrows). This is expressed as a percentage, i.e. $d/D \times 100$.

In this view, the image showing a vertical iliac line and the maximum diameter of a well-rounded femoral head was selected for measuring the alpha angle and d/D ratio.

In order to determine the d/D ratio, two straight lines were drawn parallel to the iliac line, one tangent to the lateral aspect of the femoral head and the other tangent to the deepest point of the acetabulum. The ratio of d (depth of the acetabulum) to D (diameter of the femoral head) multiplied by one hundred gave the index of acetabular depth (fig. 1a).

The equivalent of Graf's alpha angle on the coronal flexion view was measured at the intersection of the iliac line and the line of the acetabular roof which was drawn connecting the lower edge of the os ilium medially to the osseous convexity laterally (fig. 1b).



Fig. 1b. — The alpha angle of Graf is the angle formed at the intersection of the iliac line and the line of the acetabular roof (drawn from the lower edge of the iliac bone to the osseous convexity).

Radiographic study

Sonographic measurements were compared with the radiographically determined acetabular index.

According to Tönnis (6), an acetabular index more than two standard deviations above the mean value

is definitely abnormal whereas one below the mean is normal ; an index between these two values may be considered borderline.

Intra- and interobserver variation study

The participants were two paediatric orthopedic surgeons and one radiologist. The method described by Spatz *et al.* (5) to determine the intra- and interobserver errors was used.

RESULTS

They are presented in table 1.

The d/D ratio was found to vary by 6% for a mean value of 53% (range 14%-72%). This was not very different from the alpha angle variation where the intraobserver error was 6° and the interobserver error 7° for an alpha angle mean value of 53° (range 30°-83°).

Table 1

	Mean value	Range	Intra-observer error	Inter-observer error
d	10mm	1-17mm	0.95mm	1.31mm
D	18mm	11-28mm	1.45mm	1.63mm
d/D ratio	53%	14-72%	6%	6%
Alpha angle	53°	30-83°	5.58°	7.03°
Acetabular index	28°	10-50°	2.10°	2.73°

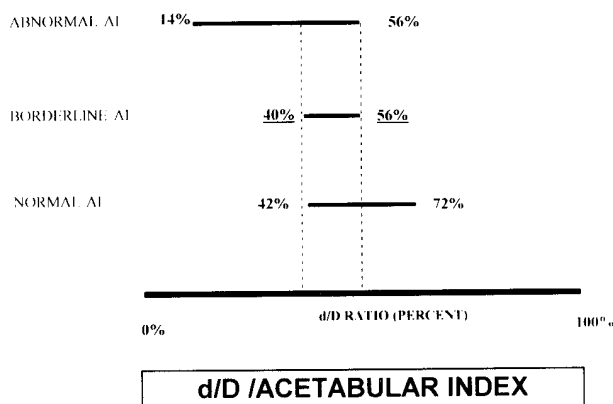


Fig. 2. — d/D ratio (mean values and range) as a function of the acetabular index (AI).

In our series conducted with a linear transducer, it was clear that on an average the d/D ratio decreased as the acetabular index increased. The correlation was not perfect and there was a grey zone between 40% and 56% where abnormal, borderline and normal acetabular indices corresponded to the same d/D ratio. However beyond the limits of 40% and 56% in our series, the inverse relation always held true (fig. 2) i.e. all the hips with a d/D ratio below 40% had abnormal acetabular indices whereas all those with a d/D ratio greater than 56% were found to have normal acetabular indices (fig. 4).

On the other hand, correlation between alpha angle and acetabular index was much less reliable

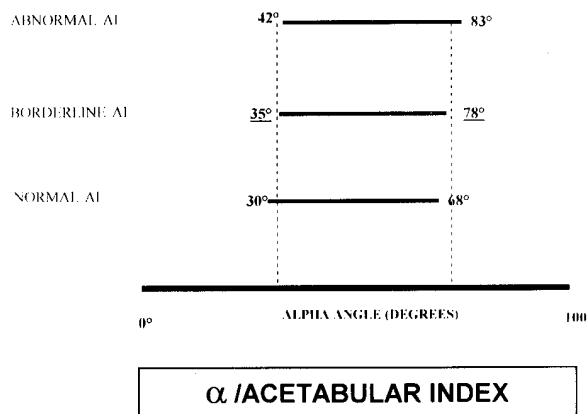


Fig. 3. — Alpha angle (mean values and range) as a function of the acetabular index (AI).

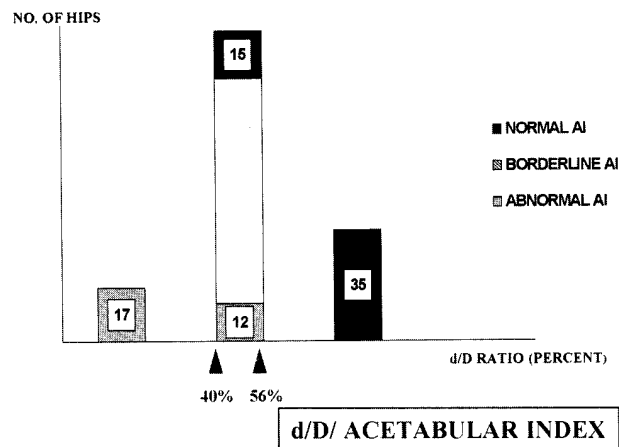


Fig. 4. — Distribution of hips according to d/D ratio and acetabular index (AI).

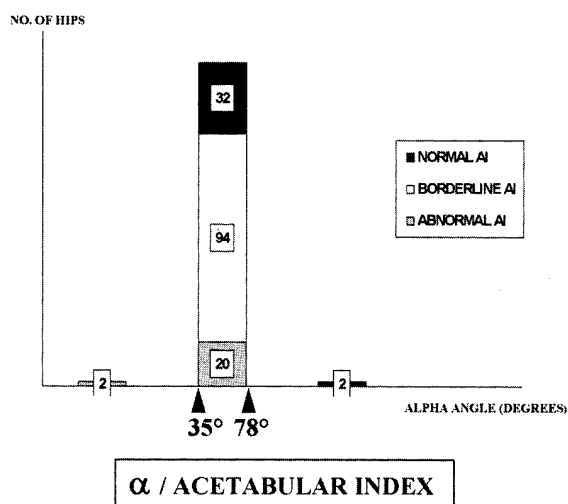


Fig. 5. — Distribution of hips according to alpha angle and acetabular index (AI).

with a very large grey zone between 35° and 78° (fig. 3).

It thus proved impossible, for the vast majority of hips (146 out of 150), to forecast from the alpha angle the value of the acetabular index (fig. 5).

We were not able to find any statistically significant difference between male and female, left and right hips nor variation in the d/D ratio in relation to age in the hips considered normal with reference to the acetabular index.

DISCUSSION

Real-time ultrasound has gained wide acceptance for the screening of infant hips for DDH on account of its innocuousness, its ability to render visible the cartilaginous structures of the infant hip and the possibility of conducting dynamic studies. The first three to four months of life are recognized as the best time to study the hip by ultrasonography. Thereafter ultrasound can still give useful information about the hip, provided the ossific nucleus of the femoral head has not appeared. This was the case in our series until as late as 12 months.

Graf was the first to describe the ultrasonographic morphology of the infant hip and to develop a method to quantify the shape of the acetabulum

using lines and angles. He described the alpha angle to characterize the bony contour of the infant socket. The d/D ratio was described some years later and was found to be easy to determine (6).

After three to four months of age, the acetabular index determined on the anterior-posterior radiograph of the pelvis, is still considered the “gold standard” to study the shape of the bony acetabulum in the majority of publications. Earlier on, radiographs are very difficult to interpret. Thus, neither ultrasonography nor radiography may be considered as a “universal tool” to study the development of the bony acetabulum from the neonatal period to the end of the first year of life. In an earlier comparative study between the d/D ratio and the acetabular index, the authors were able to show a correlation not only between the individual values of these two variables but also between their evolutions during treatment (3). They therefore proposed the possibility of reducing the number of radiographs in cases where ultrasonography is able to demonstrate an excellent d/D ratio.

Intra- and interobserver variations in the measurement of alpha angle have been reported. In one such study the variations were so marked (5) that the predictive value of this measurement was questioned. The d/D ratio has been described as easier to determine (4). In our study we found the two values to have the same reproducibility during intra- and interobserver comparisons.

Sector scanner ultrasound which was the technique used for the pilot study, is no longer popular. Hence, it was necessary to confirm the results with the new generation of linear-array transducer. Even though there was not a perfect correlation between d/D ratio and acetabular index, we were able to find limit values beyond which there were no doubts about the extent of development of the acetabulum. The most important point was that for any d/D ratio superior to 56%, the acetabular index was always normal. We thus confirmed the information obtained in our previous study using a sector scanning transducer (3). No similar conclusion could be drawn for the alpha angle, as the sensitivity appeared to be very low.

Ultrasonography is not yet a perfect tool to study acetabular development mainly because its interpretation is nearly impossible once the ossific nucleus of the femoral head has appeared, but it can be used to check the evolution of the hip under treatment in order to decrease the number of radiographs in the treatment programme and perhaps eliminates the need for any radiograph when the d/D ratio is above 56%.

REFERENCES

1. Clarke N. M. P., Harcke H. T., Mc Hugh P., Lee M. S., Borns P. F., Mac Ewen G. D. Real-time ultrasound in the diagnosis of congenital dislocation and dysplasia of the hip. *J. Bone Joint Surg.*, 1985, 67-B, 406-412.
2. Graf R. New possibilities for diagnosis of congenital hip joint dislocation by ultrasonography. *J. Pediatr. Orthop.*, 1983, 3, 354-359.
3. Morin C., Harcke T., MacEwen G. D. The infant hip : Real-time US assessment of acetabular development. *Radiology*, 1986, 157, 673-677.
6. Nimityongskul N., Hudgens R., Anderson L., Melhem R., Green A., Saleeb F. Ultrasonography in the management of developmental dysplasia of the hip. *J. Pediatr. Orthop.*, 1995, 17, 741-746.
5. Spatz D. K., Reiger M., Klaumann M., Miller F., Stanton R. P., Lipton G. E. Measurement of acetabular index intraobserver and interobserver variation. *J. Pediatr. Orthop.*, 1997, 17, 174-175.
6. Tönnis D. Normal values of the hip joint for the evaluation of x-rays in children and adults. *Clin. Orthop.*, 1976, 119, 39-47.

SAMENVATTING

MORIN C., ZOUAOUI S., DELVALLE-FAYADA A., DELFORGE P. M., LECLET H. Echografische evaluatie van het acetabulum van de infantiele heup.

Er werden 150 kinderheupjes simultaan radiologisch en echografisch onderzocht. De betrouwbaarheid van de metingen was groot voor de alfahoek en de d/D ratio. De acetabulaire index correleerde beter met de d/D ratio dan met de alfahoek. Inderdaad kan bij heupen met een d/D ratio van meer dan 56%, radiografieën worden vermeden. Het gebruik van een sector scanner of een lineaire array transducer gaf geen significant verschil bij het bepalen van de d/D ratio en de acetabulaire index. Echografische evaluatie van de ontwikkelende heup zou het aantal radiografieën in de toekomst bij follow-up en screening moeten beperken.

RÉSUMÉ

MORIN C., ZOUAOUI S., DELVALLE-FAYADA A., DELFORGE P. M., LECLET H. Étude échographique du cotyle dans les hanches des petits enfants.

Cent cinquante hanches de petits enfants ont été étudiées simultanément par échographie et radiographie. La reproductibilité des mesures échographiques étudiant le cotyle osseux (angle alpha de Graf et rapport d/D) est identique. Par contre il existe une bien meilleure corrélation entre la mesure radiographique de l'état du cotyle osseux (angle acétabulaire) et le rapport d/D, qu'entre cet angle acétabulaire et l'angle alpha. Ainsi lorsque le rapport d/D est supérieur à 56%, on est assuré d'un angle acétabulaire normal, et une radiographie ne paraît pas nécessaire. Ces conclusions apparaissent valables, que l'on utilise une sonde sectorielle ou linéaire. L'évaluation échographique du développement du cotyle pourrait permettre une réduction du nombre de clichés radiographiques durant la surveillance des petits enfants traités pour luxation congénitale de la hanche.