

SIMPLIFIED 3D-EVALUATION OF PERIACETABULAR OSTEOTOMY

M. DUTOIT, P. Y. ZAMBELLI

Reorientation osteotomies are widely used for the treatment of residual dysplasia of the hip. Preoperative planning is mandatory, and 3D-evaluation is of utmost importance for precise definition of direction and magnitude of displacement of the acetabulum.

Instead of a 3D-CT scan reconstruction which needs multiple slices, we developed a 3D-reconstruction from a single AP pelvic view. This method is applicable if we accept that the femoral head and acetabulum are quite spherical. Appropriate software and a PC are used for this reconstruction that we compared with 3D CT-scan reconstruction and pelvic anatomical preparations.

Twenty-two patients, 17 female, 5 male, with hip dysplasia, were treated by periacetabular osteotomy according to Ganz. The mean age was 27 years (14-40 years); the mean follow-up, 4.8 years (2-7 years). Four patients were treated conservatively in infancy for DDH, one patient had snapping hips associated with hip dysplasia, and two patients had slight sequelae of cerebral palsy.

All patients were symptomatic mainly during daily activities or sports. The clinical evaluation was done using the Charnley scoring system. The Charnley score for pain improved from 3.6 (2-3.5) to 5.8 (5-6) at follow-up. No restriction of mobility or of walking capacity was observed after operation.

The computer-assisted method also permits appreciation of the evolution of classical coxometry; i.e. Wiberg and Lequesne angles. The improvement after Ganz osteotomy was respectively 141% and 161% for Wiberg and Lequesne angles without any posterior uncoverage. The 3D-evaluation showed an improvement of 28% of the vertical projection area of the acetabulum on the femoral head. The anterolateral coverage improved from 20.3 to 50.1%.

The Ganz osteotomy is really a 3D-reorientation osteotomy. With our simplified method it is possible to predict and control the amount of displacement to be

done. However, we have to keep in mind that the articular cartilage is a limited crescent in the acetabulum; this method cannot replicate exactly the form and shape of articular cartilage. At this time it allows us to better control the amount of displacement during operation to avoid too large a displacement or lateralization.

Keywords : hip dysplasia ; pelvic osteotomy ; 3D-evaluation.

Mots-clés : dysplasie de hanche ; ostéotomie pelvienne ; évaluation tridimensionnelle.

The current incidence of hip dysplasia is still unknown; its natural history is not very well understood, but a certain relationship between dysplasia and early degenerative alterations of the hip has been established, particularly in young women (11). The prognosis depends on the degree of subluxation (broken Shenton's line); the greater the subluxation, the earlier the clinical manifestations will appear, often during the second and third decade.

In the adult only painful hips are an indication for surgical treatment. Pain often precedes radiological manifestations of secondary hip osteoarthritis. Nevertheless a small number of patients remain asymptomatic until severe radiological alterations of the hip joint become evident. The mobility of the joint remains unaffected until degenerative changes are prominent.

Hôpital orthopédique de la Suisse romande, Lausanne, Suisse.

Correspondence and reprints : M. Dutoit, Hôpital orthopédique, Av. P.-Decker 4, 1005 Lausanne (Suisse).

The degree of femoral head uncovering, subluxation and articular incongruence are the main prognostic factors affecting the rapidity of the installation and the severity of clinical symptoms of hip dysplasia.

The good quality of treatment results also depends on two other factors : early diagnosis and appropriate medical or surgical treatment during infancy are of utmost importance if not for healing, at least for a good clinical and radiological result for as long a time a possible. Nevertheless some cases remain undiagnosed and some well-treated developmental dysplasias of the hip (DDH) can have an atypical evolution explaining the persistence of late diagnosed hip dysplasia.

More often the dysplasia is on the pelvic side : lack of growth, lack of anterosuperior coverage and lack of depth of the acetabular cavity. Femoral dysplasia, usually coxa valga antetorta, is much more unusual ; it is exceptionally isolated and rather participates in global dysplasia of the hip. Therefore, surgical treatment of dysplasia is mainly done on the pelvis : acetabular reorientation osteotomies, augmentation arthroplasties (2, 3, 9, 10). Preoperative planning with dynamic xrays is very important step in this reconstructive surgery of the hip. 3D-evaluation is mandatory to define the type, direction and amount of displacement of the acetabulum (5, 6, 8). Moreover, a pelvic osteotomy should not produce incongruency between the articular surfaces because of inadequate or excessive displacement. The osteotomy should center two cartilaginous areas invisible on xrays.

The 3D-evaluation can be done by CT-scan with reconstruction, which uses multiple joined slices (1-2 mm). The irradiation is not negligible for patients who have often had numerous xrays in infancy. CT is not available everywhere ; furthermore CT has a relatively high cost. To overcome these drawbacks we worked out a simplified 3D-reconstruction method using a single AP-view of the pelvis. This xray can be done standing or supine.

SIMPLIFIED 3D-ANALYSIS

On a pelvic xray, in a patient of 12 to 13-year-old, it is possible to delineate two lines of pro-

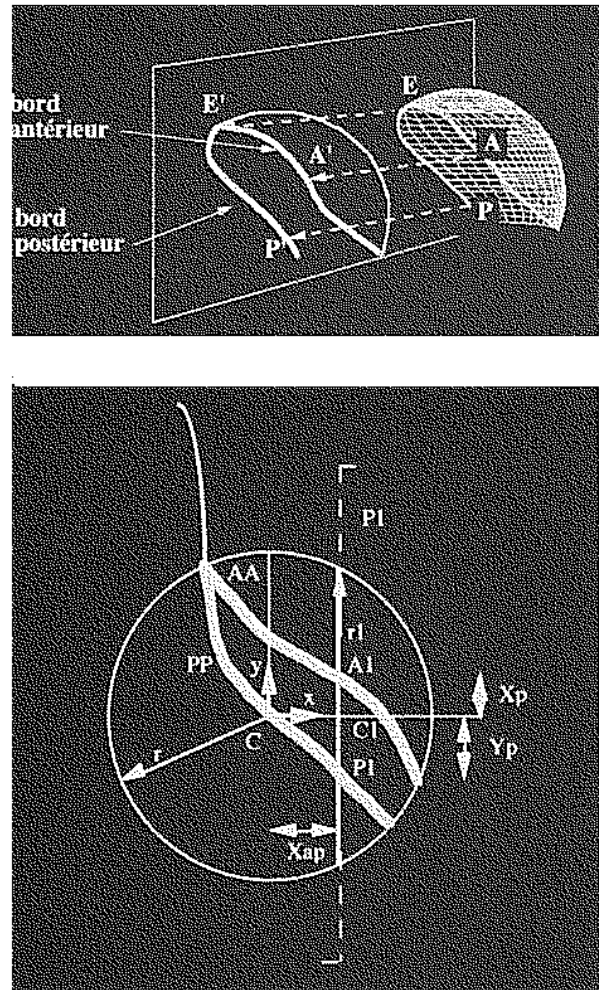


Fig. 1a. — Schematic representation of the xray projection of the acetabulum with 3D-evaluation. *b.* Frontal analysis of the anterior (AA) and posterior (PP) rim of the acetabulum. Center of the hip with 3D-axis X, Y, R.

jection corresponding to the anterior and posterior rim of the acetabulum (fig. 1). If we consider the femoral head to be spherical, the acetabulum is part of a space-oriented sphere whose frontal projection of anterior and posterior rim is well known (7). The points of the anterior and posterior rim of the acetabulum can be calculated on a AP xray according to the radius of the acetabular circle and to the X-Y axis from the center of the circle.

Data processing is very helpful in this analysis and in this 3D-reconstruction. It is done in four steps :

- Digitization (scan or video camera) of the AP pelvic view with definition of the horizontal line and scale reference.
- Numerical analysis of the digitized xray. We measure a scale reference factor, the radius of the acetabular circle, the radius of the femoral head and Wiberg and Hilgenreiner angles. Afterwards the determination of an X-Y orthogonal reference system is done, centered in the middle of the femoral head if it is concentric within the acetabulum, or in the center of the inscribed circle of the acetabulum if excentration of the femoral head exists. Software ORTHOPLAN®, developed for planning a custom hip prosthesis, is used in this second step.
- The third step achieved with the software CONVERT® allows us to obtain not only the coordinates of the anterior and posterior rim of the acetabulum but also 20 intermediate points in the horizontal plane between the

acetabular rims. This software automatically computes the vertical projection area of the acetabulum on the femoral head. An index is created.

- This index, during the fourth step is read by 3D-reconstruction software, MOVIEBUYER®.

It is therefore possible to obtain a realistic 3D-reconstruction of the hip with a simple AP view of the pelvis (fig. 2). Our results are in agreement with 3D CT-scan reconstructions. Wiberg and Hilgenreiner angles measured by this method are comparable to the classical xray evaluations. This method was also compared to the 3D-evaluation of cadaveric pelvis without hip dysplasia (4).

MATERIAL AND METHOD

We applied this simplified 3D-evaluation to 30 periacetabular osteotomies according to Ganz, in the surgical treatment of hip dysplasia (fig. 3). Our data

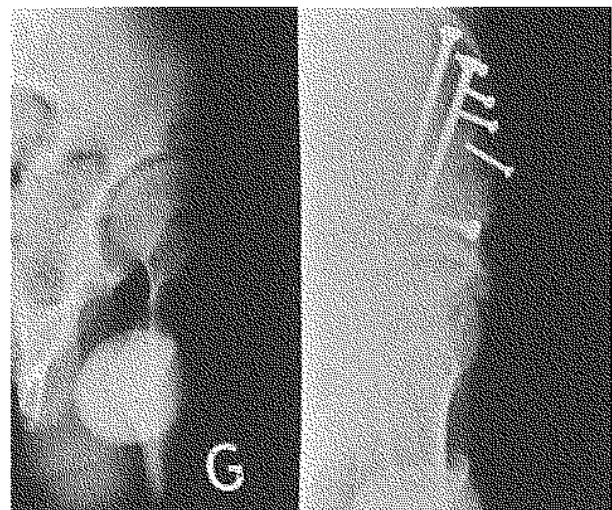
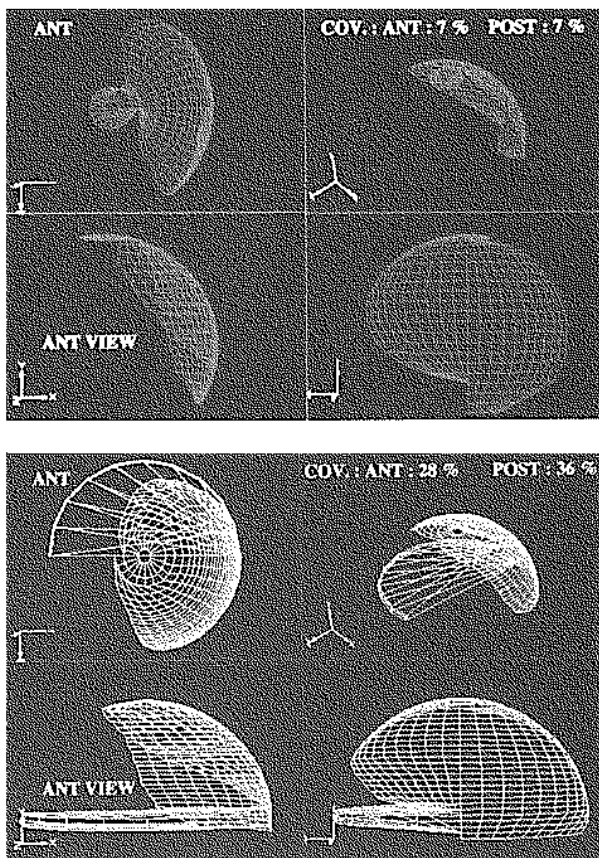


Fig. 2a. — Simplified preoperative 3D-reconstruction of the right hip with severe dysplasia : lack of anterior and posterior covering < 10%.

- a) superior view
- b) anterior view
- c) posterior view
- d) lateral view

b. — Same patient, same hip at follow-up. Much better coverage both anteriorly (28%) and posteriorly (36%).
c. — Same patient. Lequesne false profile preoperatively and at follow-up ; good improvement in anterolateral covering of the femoral head.

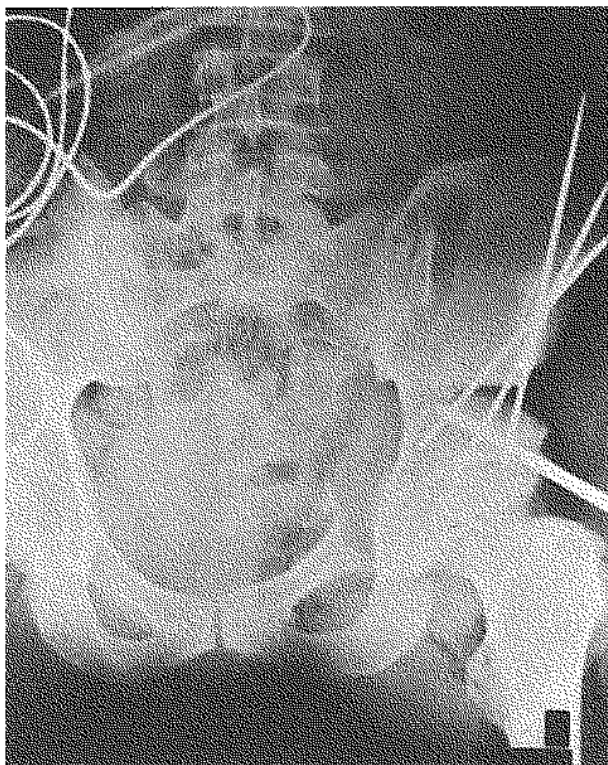


Fig. 3. — Xray during Ganz osteotomy showing the anterior and posterior rims of the acetabulum.

concern 22 patients ; 17 female, 5 male with a mean age of 27.4 years (14-40 years) ; the mean follow-up was 4.8 years (2-7 years). Four patients were treated in infancy for DDH. One patient had bilateral snapping hips associated with dysplasia, and two patients had slight cerebral palsy (CP) sequels with predominantly posterior uncovering of the hips.

All these young patients were symptomatic : pain during walking, exercises or sports.

Clinical evaluation was done pre- and postoperatively in order to assess the evolution of the functional Charnley score. The xray evaluation always included, besides an AP pelvic view, a false profile according to Lequesne, and an MRI to assess the labrum, articular cartilage and quality of the subchondral bone. The simplified 3D-evaluation was compared to standard coxometry by measuring pre and postoperatively Wiberg and Lequesne angles. We also measured the improvement (in %) of femoral head coverage. Our method allows to assess and compare the anterior, posterior, superior and lateral views. The vertical projected area of the acetabulum is automatically calculated (fig. 4).

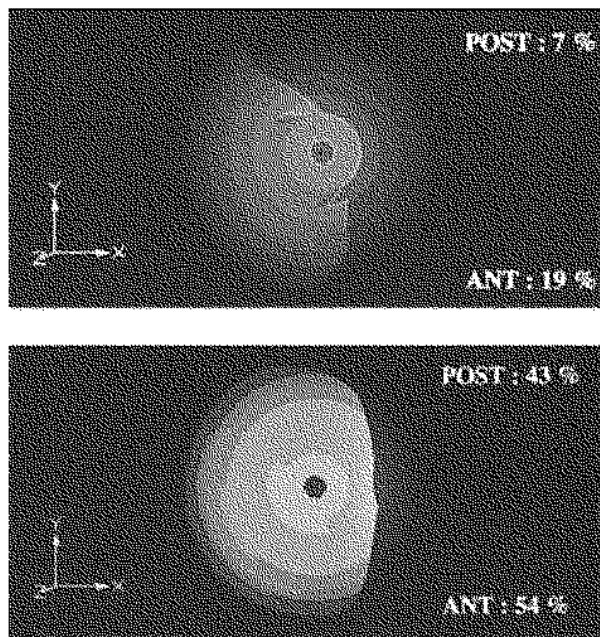


Fig. 4a. — Vertical shadow (clear) of acetabulum. Preoperative 3D-reconstruction in a CP patient, insufficiency of anterior and mainly posterior covering. **b.** — Same patient. At follow-up, both anterior and posterior covering are quite normal.

RESULTS

Charnley's score for pain was 3.6 (2-5) preoperatively. At follow-up the score was 5.7 (5-6) : gain 2. The functional impairment mainly during sport and activities, disappeared almost completely.

The walking capacity was normal before operation and remained so at follow-up. At follow-up the mobility was quite normal : flexion 97° (90-110°), abduction 35° (20°-40°), and adduction 25° (0°-40°), internal rotation 25° (10°-40°) and external rotation 30° (15°-60°). No patient mentioned any problem concerning mobility, whatever his activities.

The improvement in the classical coxometric values was very significant, more than 100% for Wiberg and Lequesne angles (table I).

The improvement in anterolateral coverage was 30%, without any decrease posteriorly, which even improved by 33%. An articular reorientation was really achieved. The coverage of the femoral head

Table I. — Evolution of Wiberg and Lequesne angles before and after Ganz periacetabular osteotomy. Wiberg angle was determined both on xray and on computer 3D-reconstruction

Angle		Preoperative	Follow-up	Improvement	
Wiberg	xray	13.4° (-14° to 20°)	32.4° (19-40°)	16.9° (4-34°)	141%
	Computer	12.9° (1.8° to 25.4°)	25.6° (19-44.1°)	13.2° (-0.3-30.8°)	97%
Lequesne		19.6° (0-40°)	37.9° (30-60°)	24.4° (10-50°)	161%

Table II. — 3D-assessment of anterior and posterior coverage of the femoral head before and after Ganz periacetabular osteotomy. Preoperative and follow-up evolution of the vertical shadow of the acetabulum (fig. 4)

3D-covering	Preoperative	Follow-up	Improvement
Anterolateral	20.8% (± 17.7%)	50.1% (± 24%)	30.5% (- 11 to 72%)
Posterolateral	18.6% (± 2.9%)	51.1% (± 25%)	93.3% (0-95%)
Vertical shadow of acetabulum	68.4% (49-93%)	88.2% (6-112%)	20.2% (0-42%)

was better : improvement of the vertical shadow of acetabulum by 20.2% (table II).

There were no severe complications in this short series except 2 cases of transitory meralgia paresthetica and 3 cases of anemia from blood loss despite blood predonation and use of a cell saver. Two patients had pain for several months (more than 6) ; at follow-up they were totally pain free.

DISCUSSION

This short series confirms the effectiveness of articular reorientation after periacetabular osteotomy according to Ganz. After this operation there was no pathological posterior uncoverage. All the patients were pain free, the preoperative pain during sports, long walking or exercise disappeared totally ; nevertheless, the follow-up was short. Can this kind of surgery avoid degenerative changes of the hip joint ? Only time can give the answer. The osseous coverage is much better, but we have no idea about the condition of the cartilage with this method of evaluation.

Our simplified 3D-reconstruction method allows us to ascertain the geometrical effectiveness of periacetabular osteotomy as a surgical treatment of primary or secondary dysplasia of the hip. Coxometry evaluating the evolution of Lequesne angles allows us to assess the constant improvement of the anterosuperior coverage. This im-

provement seems somewhat less impressive with computer assisted measurements. These divergences with classical coxometry may arise because of a better evaluation by a simplified 3D-reconstruction of slightly decentered hips or for hips not totally spherical but congruent (1, 6, 9).

The divergences for Wiberg and Lequesne angles between extreme values are as important preoperatively as at follow-up. They probably reflect the small number of cases in this series. It is also possible that very small acetabula do not permit a large correction. These small acetabula perhaps need an enlargement osteotomy. It is possible to obtain a 3D-reconstruction of the hip with minimal irradiation and a 10-fold lower cost with our method compared to a CT-scan reconstruction.

In analyzing the results one should also keep in mind the technical difficulties of periacetabular osteotomies in explaining some incomplete reorientation, that can also be secondary to a small acetabulum. In the amount of correction we must remember to maintain the articular congruence and to preserve at follow-up the normal preoperative hip mobility of these young patients. Ganz osteotomy is effective not only for coxometric improvement but also in the treatment of symptomatic patients, as most of them are pain free.

Our simplified 3D-reconstruction method allows us to appreciate the total improvement of the femoral head coverage, anteriorly and posteriorly.

The Ganz osteotomy can also be used for the treatment of posterior uncoverage often seen in neurological patients (CP). In two CP patients, it was possible to improve the posterior coverage by more than 30%. (fig. 4).

This method can also be used in the operating room to evaluate the displacement planned or already accomplished, thus avoiding inappropriate displacements quantitatively or qualitatively (inadequate or too large displacement, poor orientation, loss of articular congruence). If the quality of the peroperative xray is sufficient, it is possible to analyze the displacement in real time. This is obviously impossible with a CT-scan.

To our knowledge there is no study in adults (1) that analyzes the 3D-correction after periacetabular osteotomy. One must repeat a CT-scan. Our technique with a single control xray permit us to appreciate the 3D-correction at a lower cost, with minimal irradiation. Our method also enables us to plan the correction on a standing xray before the operation, to assess the displacement during the operation, and to optimize the peroperative correction. The results are comparable with a 3D CT-scan. Neither method can give any information about the quality and localization of the articular cartilage. This will be done in the future with 3D-MRI.

REFERENCES

1. Azuma H., Taneda H., Igarashi H., Fujioka M. Preoperative and postoperative assessment of rotational acetabular osteotomy for dysplastic hips in children by three dimensional surface reconstruction computed tomography imaging. *J. Ped. Orthop.*, 1990, 10, 33-38.
2. Carliz H., Khouri N., Hulin P. Ostéotomie triple juxtacotyloïdienne. *Rev. Chir. Orthop.*, 1982, 68, 497.
3. Ganz R., Klaue K., Vinh T. S., Mast J. W. A new periacetabular osteotomy for the treatment of hip dysplasia. *Clin. Orthop.*, 1988, 232, 26-36.
4. Guesmia S. Evaluation tridimensionnelle de la hanche à partir d'une radiographie. Thèse Ecole Ingénieurs, Yverdon-les-Bains, 1994.
5. Klaue K., Wallin A., Ganz R. CT evaluation of coverage and congruency of the hip prior to osteotomy. *Clin. Orthop.*, 1988, 232, 15-25.
6. Klaue K. Applications de l'imagerie tridimensionnelle en pathologie orthopédique. Cahiers d'enseignement de la SOFCOT, 1994, pp. 219-232.
7. Le Cœur P. Corrections des défauts d'orientation de l'articulation coxo-fémorale par ostéotomie de l'isthme iliaque. *Rev. Chir. Orthop.*, 1965, 51, 211.
8. Millis M. B., Murphy S. B. Use of computed tomography reconstruction in planning osteotomies of the hip. *Clin. Orthop.*, 1992, 274, 154-159.
9. Ninomiya S. Rotational acetabular osteotomy for the severely dysplastic hip in the adolescent and adult. *Clin. Orthop.*, 1989, 247, 127-137.
10. O'Sullivan G., Goodmann S. B., Jones H. H. Computerized tomographic evaluation of acetabular anatomy. *Clin. Orthop.*, 1992, 277, 175-181.
11. Tönnis D., Behrens K., Tscharani F. A modified technique of the triple pelvic osteotomy. *J. Ped. Orthop.*, 1981, 1, 241.
12. Weinstein S. Natural history of congenital hip dislocation (CDH) and hip dysplasia. *Clin. Orthop.*, 1987, 225, 62-76.

SAMENVATTING

M. DUTOIT, P. Y. ZAMBELLI. Vereenvoudigde 3D evaluatie van peri-acetabulaire osteotomie.

Reorientatie osteotomies worden vaak toegepast in de behandeling van residuele dysplasie van de heup. Preoperatieve planning is noodzakelijk en 3D evaluatie is onmisbaar voor een precieze definitie van de richting en de omvang van de acetabulaire verplaatsing.

In tegenstelling tot een 3D-CT scan reconstructie welke veelvuldige coupes noodzakelijk maakt, hebben wij een methode ontwikkeld om een 3D reconstructie uit te voeren vanaf een enkelvoudige AP view. Deze methode is toepasbaar wanneer men aanneemt dat heupkop en acetabulum vrij sferisch zijn. Aangepaste software en een PC zijn nodig. Deze methode werd vergeleken met de klassieke CT reconstructie.

Een periacetabulaire osteotomie volgens Ganz werd uitgevoerd bij 22 patiënten, 5 mannen en 17 vrouwen. De gemiddelde leeftijd was 27 jaar (14 tot 40 jaar) en de gemiddelde follow-up was 4,8 jaar (2 tot 7), 4 werden voorheen conservatief behandeld wegens CHD, één had een snapping hip en 2 hadden discrete sequellen van CP. Bij alle patiënten was er pijn bij de dagelijkse activiteiten en bij sport. De evaluatie gebeurde volgens de Charley score. Deze verbeterde van 3.6 (2-3.5) naar 5.8 (5-6). Er werden geen restricties van mobiliteit noch van gangpatroon vastgesteld.

De computer-geassisteerde methode liet een appreciatie toe van de klassieke coxometrie mn. de hoeken van Wiberg en Lequesne. De verbetering na Ganz osteotomie was respectievelijk 141% en 161% zonder posterieure niet-bedekking.

De 3D evaluatie toonde een verbetering van 28% van de verticale projectie area van het acetabulum op de femurkop. De anterolaterale bedekking verbeterde van 20,3 naar 50,1%.

De Ganz-osteotomie is waarlijk een 3D reoriëntatie. Met onze methode is het mogelijk om de verplaatsing te voorspellen en te controleren. Men moet echter weten dat de kraakbeenlaag in het acetabulum beperkt is tot een halve maanvormige zone. Deze methode kan niet de exacte vorm van het gewrichtskraakbeen reproduceren. Tot heden laat het wel toe om de verplaatsing te controleren om overmatige verplaatsing of lateralisatie te vermijden.

RÉSUMÉ

M. DUTOIT, P. Y. ZAMBELLI. Évaluation tridimensionnelle simplifiée des ostéotomies péri-acétabulaires.

Les ostéotomies de réorientation de l'acétabulum sont largement utilisées dans le traitement des dysplasies résiduelles de la hanche. La planification préopératoire est obligatoire et l'évaluation tridimensionnelle est particulièrement importante pour définir précisément la direction et l'importance du déplacement de l'acétabulum. Pour remplacer le CT-scan tridimensionnel qui nécessite de multiples coupes, nous avons développé une reconstruction tridimensionnelle à partir d'une simple vue antéro-postérieure du bassin. Cette méthode simple assimile la tête fémorale et l'acétabulum à des portions de sphère. Un simple PC et quelques logiciels suffisent pour obtenir des reconstructions tridimensionnelles qui ont été validées par comparaison avec le CT 3D et des préparations anatomiques.

Vingt-deux patients (17 femmes, 5 hommes) présentant une dysplasie de hanche, ont été traités par une

ostéotomie péri-acétabulaire selon Ganz. L'âge moyen est de 27 ans (14-40 ans); le suivi moyen est de 4,8 ans (2 à 7 ans). Quatre patients avaient été traités pour une maladie luxante de hanche de façon conservatrice dans l'enfance. Une patiente présente une hanche à ressaut bilatérale, associée à une dysplasie de hanche et deux patients sont des IMC légers.

Tous les patients étaient symptomatiques, surtout durant les activités de la vie quotidienne ou lors de la pratique de sports. L'évaluation clinique fut réalisée à l'aide du score de Charnley. Le score de Charnley, pour la douleur, passe de 3,6 (2 à 2,5) à 5,8 (5 à 6) au recul. Il n'y a pas de restriction de la mobilité ou de la capacité de marche après l'intervention.

Cette méthode 3D simplifiée a montré une amélioration postopératoire de 28% de la surface de projection verticale de l'acétabulum sur la tête fémorale, alors que la couverture antéro-latérale passe de 20,3 à 50,1%. La méthode permet également les mesures coxométriques classiques, c'est-à-dire l'angle de Wiberg et l'angle de Lequesne. L'amélioration, après ostéotomie selon Ganz, fut respectivement de 141 et 161% pour les angles de Wiberg et de Lequesne, sans découverte postérieure associée.

Ainsi, l'ostéotomie péri-acétabulaire est réellement une ostéotomie de réorientation tridimensionnelle. Notre méthode simplifiée d'évaluation permet de prédire et de contrôler l'importance du déplacement. Il faut cependant se souvenir que le cartilage articulaire, dans une articulation coxo-fémorale, est limité à un croissant. Cette méthode ne donne bien entendu qu'une idée indirecte de la forme et des dimensions du cartilage articulaire. Elle nous permet cependant de mieux contrôler le déplacement durant l'intervention, empêchant ainsi des déplacements trop généreux ou des latéralisations articulaires non souhaitées.