

# GROWTH DISTURBANCE OF THE ILIUM AFTER SPLITTING THE ILIAC APOPHYSIS AND ILIAC CREST BONE HARVESTING IN CHILDREN : A RETROSPECTIVE STUDY AT THE END OF GROWTH FOLLOWING UNILATERAL SALTER INNOMINATE OSTEOTOMY IN 21 CHILDREN

R. ROSSILLON (1), D. DESMETTE (2), J.J. ROMBOUITS (1)

The morphology of the iliac bone was assessed at the end of growth on AP xrays of the pelvis in 21 children who had previously undergone unilateral pelvic osteotomy. The nonoperated side was used as a reference. There were 13 girls and 8 boys. Age at operation varied from 12 months to 12 years with a mean of 3 years and 10 months.

The patients were distributed in 2 groups depending on their age at operation : before age 5 (group A, 16 cases) or after age 5 (group B, 5 cases). The mean age at follow-up was 15 years and 2 months (range 11-19 years). The end of pelvic growth was established by Risser stage IV.

Distinct hypoplasia of the ilium due to premature growth arrest was observed in 16 cases : 12 in group A and 4 in group B. Other changes in the morphology of the ilium were noted, e.a. increased height of the ilium which was noted in 12 cases. The cosmetic prejudice was however minor, as compared with the radiological changes.

In the authors' opinion, the alar hypoplasia was related to growth disturbances due to repeated splitting of the iliac apophysis.

To prevent this complication the authors recommend avoiding the use of an electrocautery to incise the iliac apophysis and cutting the Kirschner wires so that their proximal ends lie within the subcutaneous fat , in order to avoid repeated splitting of the apophysis at the time of hardware removal.

**Key words :** Salter innominate osteotomy, growth disturbance, ilium.

**Mots-clés :** ostéotomie pelvienne, Salter, trouble de croissance, aile iliaque.

## INTRODUCTION

Salter (6) introduced innominate osteotomy in the treatment of congenital hip dislocation in 1961. In his original technique, the approach required splitting of the iliac apophysis followed by oriented epiphysiolytic. Since his description, almost all pelvic osteotomies have used the same approach, some with subtle modifications but always with partial or complete epiphysiolytic of the iliac apophysis. A triangular piece of bone is harvested from the anterosuperior iliac spine down to the anteriorinferior iliac spine, extending posteriorly to the mid-point of the iliac crest. This tricortical bone graft is strong enough to keep the osteotomy open ; its high osteogenic potential promotes rapid healing of the osteotomy.

Fixation of the osteotomy with K-wires or screws is usually required, and repeated splitting of the crest may be necessary later on for removal of the hardware.

Beaty (1) in "Campbell's Operative Orthopaedics" recommends cutting the Kirschner wires so

---

<sup>1</sup> Department of Orthopedic Surgery , Université Catholique de Louvain, Brussels, Belgium.

<sup>2</sup> Service d'Orthopédie, Clinique Saint Joseph, Mons, Belgium.

Correspondence and reprints : J. J. Rombouts, Service de Chirurgie Orthopédique et de Traumatologie de l'Appareil Locomoteur, Cliniques Universitaires Saint Luc, Avenue Hippocrate 10, 1200 Bruxelles, Belgique.

that their anterior ends lie within the subcutaneous fat rather than below the apophysis which is repaired with absorbable sutures. However some surgeons prefer to cut the Kirschner wires shorter, to avoid injury to the subcutaneous tissues and the overlying skin. In this case, repeated splitting of the apophysis is performed at the time of hardware removal.

To our knowledge, the literature contains only a few studies (3,4,5) on the long-term development of the pelvis and iliac crest following Salter innominate osteotomy. The growth disturbances of the ilium are minimized by most authors given the biomechanical improvement of the coxo-femoral joint.

We investigated the development of the iliac wing at the end of growth taking into account the radiological changes noted on AP xrays of the pelvis and the possible cosmetic compromise. The outcome of the osteotomy on the hip joint itself was not considered in the present study.

**MATERIAL AND METHODS**

We retrospectively studied 21 adolescents who had undergone unilateral pelvic osteotomy before 1980. There were 13 girls and 8 boys with a mean age of 15 years and 2 months (range 11 to 19 years) at follow-up. At the time of revision, the growth of the iliac bone was completed, having reached at least Risser stage IV, even in an 11-year-old girl who was very mature for her age.

Sixteen children underwent a Salter innominate osteotomy before age 5, at a mean age of 2 years and 2 months (range 1 to 4 years) for hip dislocation or residual dysplasia.

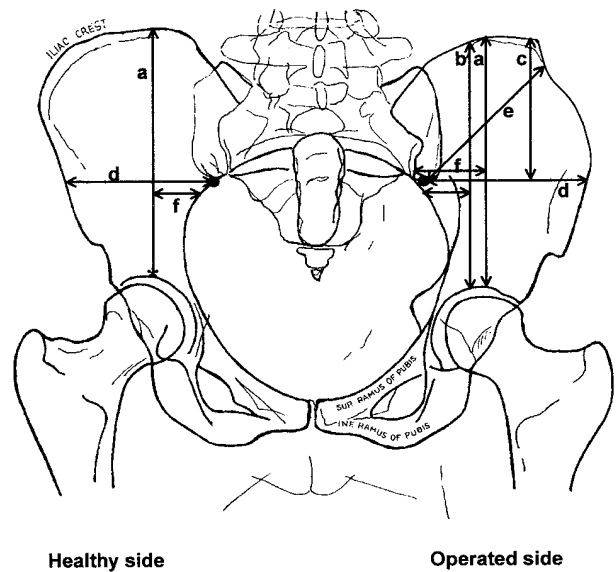
Five cases required this osteotomy after age 5 (mean 9 years and 6 months, range 8-12 years) for residual dysplasia or Legg Perthes disease.

All osteotomies were performed by the same surgeon (J.J.R.), using the same technique : the classic Smith-Petersen approach splitting the iliac apophysis with a sharp knife in the midline or slightly lateral, with an oriented epiphysiolyis using a periosteal elevator. The osteotomy was usually fixed by two threaded K-wires. At the end of the procedure, the apophysis and the iliac crest were closed with absorbable sutures. In most cases the apophysis covered the anterior ends of the wires. In this series, removal of the hardware was

performed through a limited approach with repeated splitting of the iliac apophysis.

All children were reviewed clinically at the end of growth. A standing AP film of the pelvis was obtained with a heel lift under the short limb when appropriate.

The posterior inferior iliac spine (p.i.i.s.) was taken as the reference point not involved by the osteotomy or the growth of the pelvis. We defined 6 variables (fig. 1, fig. 2).



- P.i.i.s. : posteriorinferior iliac spine
- \* Top of the healthy acetabulum
- a. Total height
- b. Equidistant height
- c. Alar height
- d. Width
- e. Oblique diameter
- f. Excentricity

**Fig. 1.** — The six measurements made on an A-P view of the pelvis.

- (a) *The total height* extends vertically from the highest point of the acetabulum to the iliac crest. It measures the global height of the proximal hemipelvis.
- (b) *The equidistant height* is the total height taken at the same distance from the p.i.i.s. on both sides. This measurement eliminates the influence of a possible displacement of the acetabulum {see excentration (f)}. The top of the healthy acetabulum is taken as a reference.

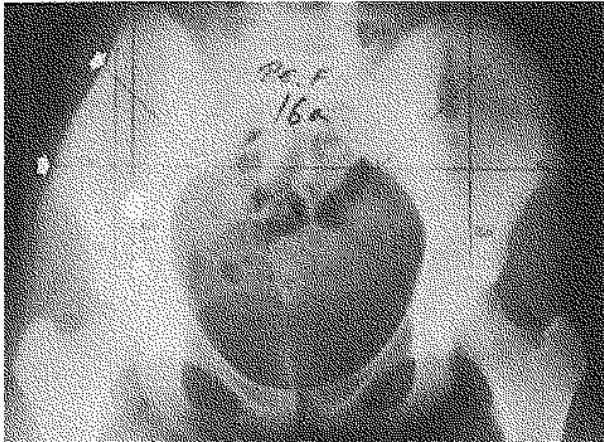

Fig. 2. — Construction for the measurements on the xrays. Salter at age 2, to treat an acetabular dysplasia.

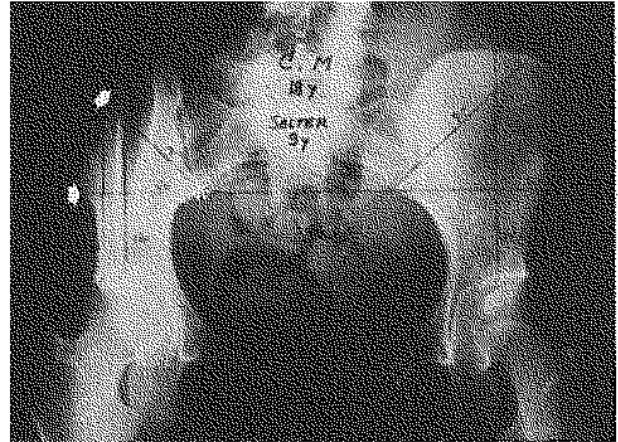


Fig. 3. — Salter at age 9 to treat a neurological subluxation.

- (c) *The alar height* is the greatest vertical distance between the iliac crest and the horizontal line joining the two p.i.i.s.
- (d) *The width at 90°* is the horizontal distance between the p.i.i.s and the most lateral projection of the pelvis.
- (e) *The oblique diameter* is the distance between the p.i.i.s and the iliac crest on a line ascending with an 45° angle from the p.i.i.s. This value, as compared with the normal side, is expected to reflect most accurately the growth defect induced by a diminution of the growth potential of the anterior part of the iliac apophysis.
- (f) As the innominate osteotomy may displace the acetabulum, we tried to measure this displacement, called «excentricity», and its consequences on the shape of the ilium. *Excentricity of the acetabulum* is the distance measured horizontally between the p.i.i.s. and a line raised vertically from the top of the acetabulum (a).

These measurements were expressed as a percentage of the values recorded on the contralateral side. We considered values for the operated side to be normal between 98-102 % of the values noted on the reference side. This 5% range represented the margin of error of measurements on the radiographs. Any value below 98% was considered as below normal and any value above 102% as above normal.

An overall estimate of the group was obtained first ; subsequently, the younger age group and the older age group were studied separately, for comparison.

## RESULTS

When the group was considered as a whole, the most striking finding (table I) was the reduction of the mean (e) oblique diameter (83.6% of the normal side), the mean (d) width (90.9%) and the mean (c) alar height (92.4%), reflecting the expected growth disturbances. The mean (f) excentricity was moderately diminished (94.5%). The mean (a) total height and (b) equidistant height were practically normal. This could be readily explained by the fact that the interposition of the graft, between the acetabulum and the alar wing, compensated for the minor development of the ala.

This discrepancy was also apparent when individual children were considered (table II) : 18 or 86% had a decreased oblique diameter, 16 or 76

Table I. — Average values for each diameter expressed as a percentage of the normal side (21 cases)

Total height	100.3%
Equidistant height	98.1 %
Alar height	92.4 %
Width	90.9 %
Oblique diameter	83.6 %
Excentricity	94.5 %

The most significant measurement reflecting the observed growth defect of the iliac wing is given, as expected, by the reduction of the "oblique diameter" on the affected side.

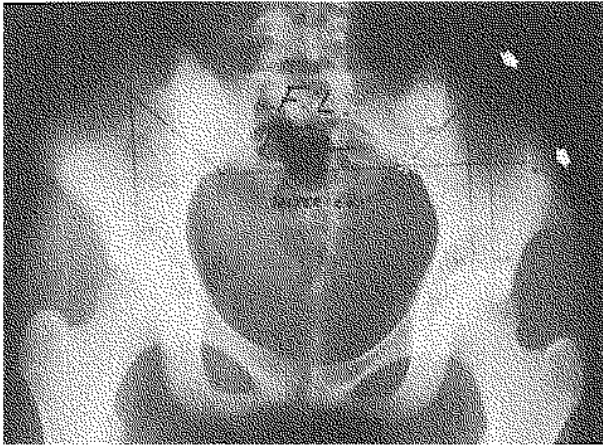
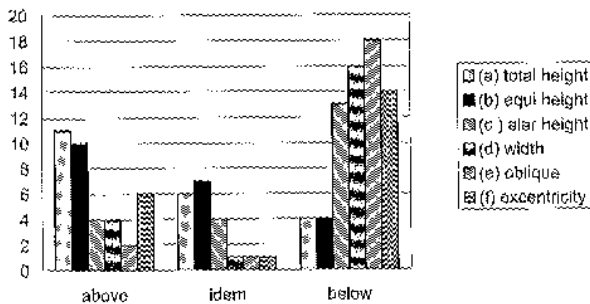


Fig. 4. — 14-year-old girl, Salter osteotomy with bone harvesting at 4 years of age.

Table II. — Total population

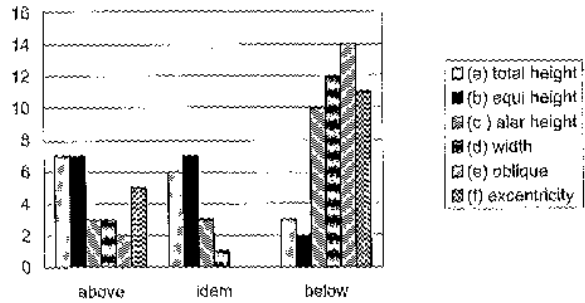


Half (52 %) of the patients present an increase in the total height of the ilium (a) despite the fact that 62% of the iliac wings are decreased in height (c). 76 % of the pelvis examined show a width shortening (d) ; 86 % show a reduction of the oblique diameter (e).

% a decreased width and 13 or 62% a decreased alar height, while 11 or 52% had an increased total height.

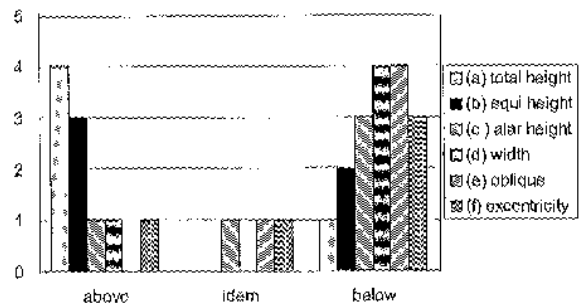
The younger age group and the older age group were also studied separately, in order to determine if age at operation influenced the final outcome regarding growth. In the younger age group (table III) the alar height was decreased in 60% ; while total height was increased in 44%. In the older age group (table IV), however, alar height was decreased in 60% and total height increased in 80%. In both groups, width and oblique diameter were reduced in the majority of cases.

Table III. — Younger age group



In the younger age group, the total height (a) is increased in 7 of the 16 pelvis (44 %). The proximal part of the iliac wing (c) has a reduced height in 10 out of 16 (60 %).

Table IV. — Older age group



The height of the iliac wing (c) is decreased in 3 cases out of 5. The total height (a) is increased in 4 cases out of 5.

From a clinical point of view, the hypotrophic iliac wing did not seem to produce any functional difficulties.

Cosmetically, the dysmorphic lesion was less obvious (fig. 5). The loss of the bony ridge, underlined by the scar, reduced the normal swaying gait on this side and gave an unsightly and palpable defect. In the majority of cases, these adolescents did not complain much about their cosmetic physical injury.

### DISCUSSION

It has been stated that Salter osteotomy significantly decreases the pelvic outlet but that much of this decrease is corrected when the osteotomy is performed prior to the pubertal growth spurt (3), which implies that some remodeling is possible at a younger age.

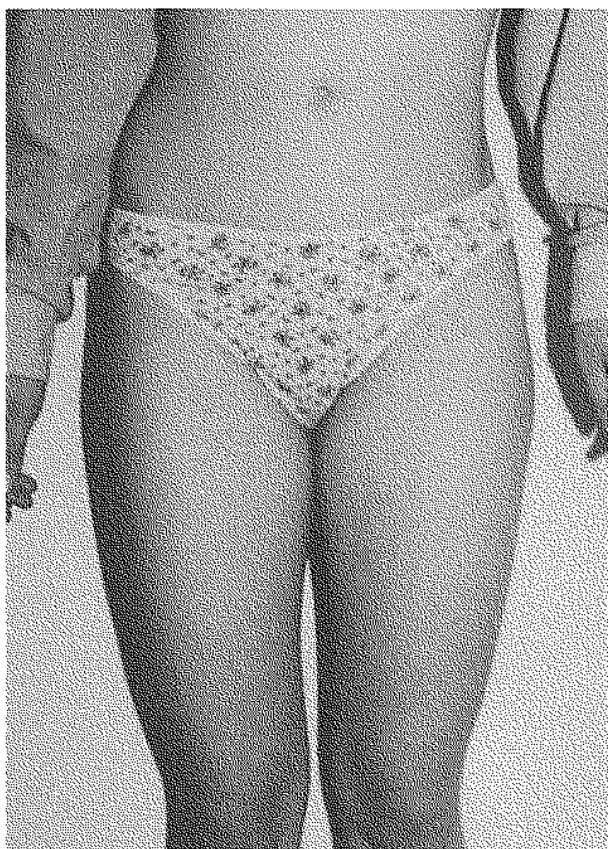


Fig. 5. — Salter osteotomy at age 5.

In a prospective study of 20 Salter innominate osteotomies performed in two different age groups, one mature and one immature, Saleh *et al.* (5) have shown that in the immature pelvis the asymmetric appearance of the obturator foramen gradually remodeled during the six months following the procedure; however no such remodeling potential was demonstrable in the mature patient during the study period.

Using a rabbit model, Olney *et al.* (4) demonstrated that splitting the iliac apophysis in a growing animal could lead to hypoplasia of the iliac wing. When the apophysis was split sharply with a scalpel, the type of repair apparently had no effect on subsequent growth; the iliac growth was more affected when electrocautery rather than a scalpel was used. In consequence, the electrocautery must be avoided for this procedure. This study has demonstrated that the growth distur-

bance of the ilium results from splitting of the iliac apophysis.

Kamegaya *et al.* (2) have advocated not to split the iliac crest apophysis: access to the sciatic notch is best gained by detaching a 1-cm flap of muscle on both inner and outer aspects of the ilium, alongside the apophysis and the anterosuperior iliac spine. To avoid any secondary dysmorphism of the iliac bone due to bone harvesting, Kamegaya *et al.* (2) advocate the use of biocompatible materials such as hydroxyapatite, which are inserted into the osteotomy site instead of the tricortical iliac graft. Although excision of the anterosuperior iliac spine alone may theoretically result into morphological changes of the ilium, our data are more consistent with a growth disturbance of the iliac apophysis than with simple bone loss due to the harvesting of a graft.

Our results clearly demonstrate that, in the series studied, repeated splitting of the iliac apophysis and bone harvesting — whatever the age of the child and the volume of the bone graft — may induce a significant stunting of growth of the anterior part of the iliac crest (fig. 2,3,4). The repeated epiphysiolysis induces a growth defect of the anterosuperior part of the ilium. The bone harvesting alone may lead to a diminution of the height of the pelvis. The opening osteotomy will however compensate for and in some cases overcorrect this effect. The need to remove the hardware imposes a further limited approach to the iliac crest. It seems preferable to cut the K-wires just above the repaired apophysis, in order to facilitate their removal without a secondary injury to the growth plate.

The use of a hydroxyapatite block or freeze-dried allograft rather than an autogenous graft, may theoretically be considered but is not widely accepted. Other anatomic sites could also be considered for harvesting autogenous bone, but the authors consider the iliac bone donor site to remain the best choice in pelvic osteotomies in children, due to the easy access and the good quality of the tricortical bone graft which can be harvested there.

However impressive the xray changes may appear, the cosmetic damage is less obvious. The prominent part of the crest has disappeared and

the pelvis seems to tilt (fig. 5). This defect in contour may theoretically become uncomfortable in thin people who may experience difficulties wearing pants. This unsightly aspect is however less important in bigger individuals who conceal the bone defect by the thickness of their subcutaneous fat.

The morbidity linked to the Salter innominate pelvic osteotomy is considered very low in light of its advantages.

## REFERENCES

1. Beaty J. H. — Congenital anomalies of lower extremity. In : Crenshaw A. H. (Ed.) Campbell's Operative Orthopaedics. Eighth edition, vol. 3, Mosby, Saint Louis, 1992, pp. 2180-2183.
2. Kamegaya M., Shinohara Y., Shinada Y., Moriya H., Koizumi W., Tsuchiya K. The use of a hydroxyapatite block for innominate osteotomy. *J. Bone Joint Surg.* 1994, 76-B, 123-126.
3. Loder R. T., Karol L. A., Johnson S. Influence of pelvic osteotomy on birth canal size. *Arch. Orthop. Trauma Surg.* 1993, 112, 210-214.
4. Olney B. W., Schler F. J., Asher M. A. Effects of splitting the iliac apophysis on subsequent growth of the ilium : a rabbit study. *J. Pediatr. Orthop.* 1993, 13-A, 365-367.
5. Saleh J. M., O'Sullivan M. E., O'Brien T. M. Pelvic remodeling after Salter osteotomy. *J. Pediatr. Orthop.* 1995, 15-A, 342-345.
6. Salter R. B. Innominate osteotomy in the treatment of congenital dislocation and subluxation of the hip. *J. Bone Joint Surg.* 1961, 43-B, 518-539.

## SAMENVATTING

*R. ROSSILLON, D. DESMETTE, J. J. ROMBOUITS. De groeistoring van de ala ossis illii na bekkenosteotomie volgens Salter. Retrospectieve radiologische studie van 21 bekkens na unilaterale osteotomie.*

Voor deze studie werden radiologische dossiers van 21 kinderen, met unilaterale bekkenosteotomie volgens Salter, op volwassen leeftijd onderzocht. Het doel was eventuele laattijdige gevolgen van de transapofysaire doorgang terug te vinden.

De patiënten werden geopereerd tussen 1 en 12 jaar met een middelbare leeftijd van 3 jaar en 10 maanden.

Ze werden gevolgd met een tijdsperiode van 11 tot 19 jaar (gemiddeld 15 jaar 2 maand).

In deze groep werden 16 afwijkingen van de ontwikkeling van de bekkenvleugel vastgesteld. De risicofactor blijkt niet bepaald gebonden met de leeftijd op het ogenblik van de ingreep : 12 anomalieën bij 16 patiënten voor de leeftijd van 5 jaar, 4 bij 5 geopereerd op een latere leeftijd.

De hypoplasie van de ala blijkt wel het gevolg van de gestoorde activiteit van het groeikraakbeen dat tijdens de operatie ingesneden werd.

De elektrische bistouri was nooit gebruikt geweest om het groeikraakbeen in te snijden en is afgeraden op basis van experimenten van Olney *et al.* (4).

De vastgestelde stoornissen kunnen eveneens een gevolg zijn van de herhaling van de insnijding van het groeikraakbeen om het synthesemateriaal (Kirschner draden) dat diep onder de epifysis werd ingebracht weg te nemen. Het is misschien beter het gebruikte materiaal onderhuids te laten.

Ondanks de indrukwekkende radiologisch beelden, zijn de cosmetische gevolgen van gering belang. De patiënten uitten spontaan geen klachten in dit verband.

## RÉSUMÉ

*R. ROSSILLON, D. DESMETTE, J. J. ROMBOUITS. Perturbation de la croissance de l'aile iliaque après ostéotomie innominée de Salter : Etude radiologique rétrospective de 21 bassins après ostéotomie unilatérale.*

Les dossiers radiologiques de 21 enfants ayant subi une ostéotomie pelvienne de Salter d'un seul côté ont été revus à maturité dans le but d'apprécier les éventuelles répercussions sur la croissance de l'aile iliaque, de l'abord transapophysaire et de la prise de greffe iliaque. Le suivi va de 11 ans à 19 ans avec une moyenne de 15 ans et 2 mois. Les enfants ont été opérés entre 1 an et 12 ans d'âge (moyenne 3 ans et 10 mois).

Un défaut de développement de l'aile iliaque a été observé 16 fois (16/21). Il semble que l'âge de l'intervention ne modifie pas le risque d'apparition de cette complication, qui a été constatée 12 fois parmi les 16 enfants opérés avant l'âge de 5 ans et 4 fois chez les 5 enfants opérés après cet âge.

Cette hypoplasie post-chirurgicale de l'aile iliaque semble être la conséquence d'un défaut d'activité du cartilage de croissance de l'apophyse iliaque qui est incisée lors de l'abord.

Sur base de travaux expérimentaux publiés récemment par Olney *et coll.* (4) les auteurs recommandent d'éviter l'utilisation du bistouri électrique pour l'incision de l'apophyse iliaque. La fréquence des troubles de croissance observés dans cette série pourrait bien être liée au fait que les broches de fixation de l'ostéotomie ont été laissées enfouies profondément sous l'apophyse et que leur ablation a nécessité une seconde incision du

cartilage de croissance. Il est donc recommandé de laisser les broches dépasser le cartilage jusque dans le tissu sous-cutané.

Bien que les images radiologiques soient assez spectaculaires, les conséquences de l'hypoplasie de l'ilion sont peu perceptibles chez l'adulte et les patients ne s'en plaignent pas spontanément.