

8-YEAR SURVIVORSHIP ANALYSIS AND SUBJECTIVE RESULTS OF 687 PRIMARY BALGRIST HIP SOCKETS

B. ECHTLER, H. A. C. JACOB, M. HOUWELING, O. HERSCHE

The Balgrist hip socket consists of an outer split ring in the form of a truncated cone, made of titanium, which is expanded by a tapered HDPE insert during implantation, thus ensuring firm primary press-fit and the possibility of retightening in the postoperative remodelling phase. Between November 1987 and October 1996, 687 primary Balgrist hip sockets were implanted in 555 patients. Five hundred and thirty-seven patients were investigated. Of these patients, 71.1% never had pain in the operated hip, 88.1% had no problems putting on their shoes, 76.2% were able to walk one or more hours. Furthermore, 91.7% are very or mostly content with the postoperative result. Nineteen hip sockets had to be revised until April 1997. With a 92.1% Kaplan-Meier survivorship rate after 8 years the Balgrist hip socket ranks among the most successful noncemented acetabular components.

Keywords : Balgrist hip socket ; expansion-type tapered hip socket ; press-fit hip socket ; noncemented acetabular component ; survivorship analysis.

Mots-clés : cotyle de Balgrist ; cotyle conique expansible ; cotyle press-fit ; cotyle non cimenté ; courbes actuarielles de survie.

INTRODUCTION

The Balgrist hip socket examined here (fig. 1) may be generally characterized as being of the press-fit, metal-backed type for cement-free fixation. An inlay of HDPE presents the bearing surface on which the ball head of the femoral component articulates. A unique feature of this socket is that the metal backing is a split ring of titanium alloy in the shape of a truncated cone, which is expanded during implantation on merely

driving home the tapered HDPE insert, thereby avoiding the use of screw threads for primary fixation.

This socket was first introduced for clinical use in 1982, and its design features have been reported in detail elsewhere (13, 17). Initially, from 1982 to 1987, this prosthesis had the outer, expandable split ring made of HDPE. In spite of good short-term results there was some concern about the long-term results because it had become known that HDPE debris could cause osteolysis by granulomas and loosening of the implant (2, 28). Therefore, the outer split ring with a taper of 30° that faces the bone has, since November 1987, been made of titanium, the insert remaining HDPE. The latter has no direct contact with the bone apart from a few apertures that are, however, necessary to give the outer split ring its desired flexibility. The purpose of this study was to evaluate the clinical outcome and survivorship rate to date of this unconventional hip socket.

MATERIAL AND METHODS

Implants

In an effort to generally retain as much subchondral bone of the acetabulum as possible (18) and to nevertheless obtain optimal fixation of the socket within the surrounding bone, the outer split ring has

Orthopädische Universitätsklinik Balgrist, Forchstr. 340, 8008-Zürich, Switzerland.

Correspondence and reprints : H. A. C. Jacob.





Fig. 1. — *a)* The Balgrist hip socket consists of an outer split ring of titanium and a tapered HDPE insert.
b) The insert is driven into the split ring during implantation. The expansion of the split ring ensures firm primary fixation



with the possibility of retightening during the postoperative phase of bone remodelling.

been given the form of a truncated cone instead of a hemisphere, since it is believed that the surrounding bone finds better purchase on the former shape, especially for primary fixation. A taper angle of 30° ($\pm 15^\circ$) retains the greater part of the subchondral cortical bone in the region of the important semilunate surface of the acetabulum. Although some bone stock from the far medial aspect of the acetabulum is sacrificed (fig. 2), this compromise permits excellent primary fixation of the socket to be accomplished, which would not be easily possible with a hemispherical socket unless such accessories as screws, pegs etc. are also incorporated, together with the necessity to ream the acetabulum very precisely.

During implantation of the socket the outer split ring alone is first introduced in a contracted state into the acetabulum, the latter having been prepared by a simple tapered reamer. The tapered insert is then introduced and driven in, until it stands above the outer ring by about 3 mm. The ability for the insert to move further in by 3 mm permits the outer ring to retighten its seating in the surrounding bone when the patient has begun to load the limb during the critical phase of bone remodelling in the first few weeks after implantation.

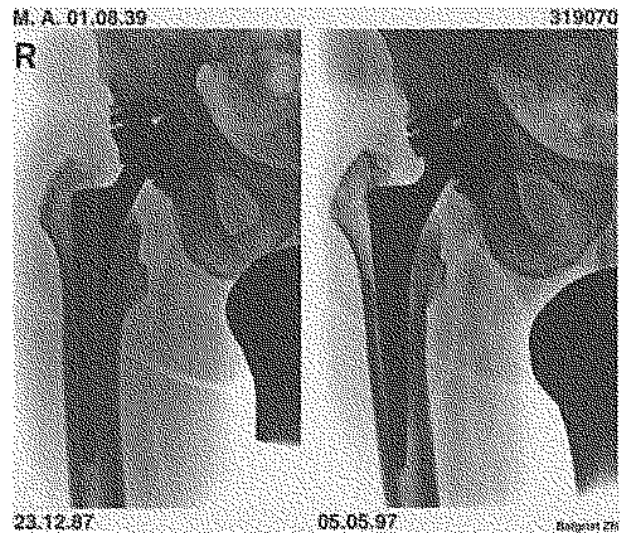


Fig. 2. — A typical xray showing a correctly implanted Balgrist socket. Note that the socket has been intentionally placed as far medially as possible.
a) immediately postoperatively
b) 9 1/2 years later

Apart from ensuring a firm primary press-fit, this expansion mechanism gives the possibility of retightening to compensate for the slack that might come about during the bone remodelling phase postoperatively.

When the tapered insert has moved fully into the outer ring in the course of time (usually between 3 and 6 months postoperatively) it is stopped by a ledge with small spikes that arrest further travel.

Although the bone might eventually come in contact with the HDPE, no scouring of the HDPE surface occurs because no relative movement takes place after the insert has settled into its final position.

The socket is presently available in six sizes, with outer diameters of 47, 50, 53, 56, 60 and 64 mm, the diameter of the ball head now being only 28 mm. Until 1992 all ball heads, except that of the 47-mm socket, were 32 mm in diameter.

Patients

Between November 1987 and October 1996, 687 primary Balgrist hip sockets were implanted in 555 patients, in 132 cases on both sides. Three hundred and six men received 388 hip sockets, 249 women 299. The most-used size in men was 56-mm outer diameter (232 times) and in women 50-mm diameter (112 times). The grit-blasted Zweymüller femoral component (titanium alloy) was mainly used (559 times) in combination with the Balgrist hip socket. With a mean age of 58.5 years, the men were slightly younger than the women, with 60.1 years. In 76.9% of our cases the reason for hip arthroplasty was primary or secondary arthritis of the hip, in 16.3% necrosis of the femoral head, in 6.1% congenital dysplasia of the hip, while the remaining 0.7% consisted of fractures of the femoral neck, rheumatoid arthritis and ankylosis. Because all patients with primary implanted Balgrist sockets have been included in this study, the mean survival time is relatively short, with 3.6 years in men and 3.3 years in women, ranging from 3 to 111 months.

Evaluation system

General

Comparing results in orthopedic surgery is a well-known problem, especially in hip and knee arthroplasty. Radiographic analysis of stem or acetabular cup loosening (7, 11, 16, 27) is not entirely convincing since there is no generally accepted radiologic definition of

loosening up to now. Even if this were the case, some patients with radiographic loosening however it is defined would not have any problems whatsoever, making revision arthroplasty optional, especially in the case of older patients. Currently, survivorship analysis with confidence intervals and a defined endpoint is the most accepted method. One point to be considered, however, is that the survival probability of patients lost to follow-up is not the same as that of the examined patients (25). We therefore decided to define the endpoint of the survival analysis as the revision of the hip-socket. We contacted the largest number of patients by questioning them on the telephone using a standardized questionnaire. All 555 patients with a total of 687 hip-sockets were traced successfully. We were thus able to evaluate all important subjective parameters and obtain the relevant information on the survival of the hip prostheses. Patients with problems and those regularly examined were clinically and radiographically assessed as usual at our hospital, but for the purpose of this study the subjective information from the patients has been mainly used.

One means of expressing the functional condition of the hip in a quantitative manner is by using a hip-score. Of the various types of scores that have evolved, the modified Merle d'Aubigne, as mentioned by Krämer and Maichl (21), appears most suitable for the present purpose, and therefore this rating has been chosen. In this rating system, only pain and walking ability is assessed, and leads to a maximum number of 12 points (2 × 6) in a very good case. The rating may be described as follows :

Pain : none, 6 ; very mild and inconstant, permitting normal activity, 5 ; mild when walking, disappearing with rest, 4 ; tolerable, with limited activity 3 ; severe when walking, preventing any activity, 2 ; severe at night, 1 ; intense and permanent, 0.

Walking ability : normal, 6 ; without stick, but with slight limp, 5 ; with stick for long distances, short distances without stick but with slight limp, 4 ; with one stick, less than one hour, 3 ; only with two sticks, 2 ; only with crutches, 1 ; unable to walk, 0. All patients who could not be evaluated (patients died, or hips revised) were given a rating of 0. Scores of 11 and 12 were classified as "very good" ; 10 points as "good" ; 9 as "satisfactory" ; 8 as "fair" ; from 7 to 0, as "poor".

We used the Kaplan-Meier survival curve (19) and a full life-table analysis (12, 31) with confidence intervals (22) for estimating the survival rate. The "endpoint" for this analysis was revision of the socket for any reason.

Radiological

In spite of the difficulty in correlating radiological observations with clinical findings, as mentioned above, it is of general interest to know how the socket has behaved within the host bone, even in subjects with no complaints. Also, it is necessary to note any possibly destructive process which might be in progress, such as osteolytic changes due to the the action of polyethylene wear particles, for instance. Therefore, after obtaining the approval of the Ethics Committee of the University of Zurich, we recently xrayed a limited number of patients (25 patients with 26 implants) who have had this implant for the longest possible period of time. We chose the first 25 patients whom we were able to contact in the city of Zurich, in strictly chronological order of implantation, without applying any other criterion for the selection. The time-period between the first postoperative and the latest radiograph averaged 10 years (8 to 12 years). Standardized anteroposterior radiographs that were made immediately postoperatively and at sequential follow-up visits were analyzed for behavior of the prostheses in these 25 patients. The radiographic evaluation of the acetabular component comprised: identification of radiolucent lines at the bone-implant interface, osteolytic changes within the pelvis, polyethylene wear, breakage and migration of the socket. For the assessment of radiolucent lines and osteolytic changes, we divided the acetabulum into the three zones (the superolateral, pubic and ischial edges of the socket) on the anteroposterior radiograph, as described by DeLee and Charnley (7).

Osteolysis was defined as expansive if the radiolucent space had a sharply demarcated, rounded or scalloped appearance and extended away from the surface of the implant; it had linear radiolucent lines if at the interface between the implant and bone a relatively uniform space of more than 1 mm was present. Evidence of migration of the acetabular component was measured by a method similar to the one described by Callaghan *et al.* (4). As suggested by Heekin *et al.* (14), we also considered a change of 5 mm in either the horizontal or vertical direction as an indication of acetabular migration. Tilting of 5° or more was also considered an indication of migration of the acetabular component as stipulated by McAuley *et al.* (24). The acetabular component was deemed possibly loose when there was radiolucency in all three zones and it exceeded 2 mm in width in one of the zones. Polyethylene wear was evaluated by measuring the distance of migration of the center of the femoral head on two

radiographs (8- to 12-year interval) using the center of the identification wire ring, fitted around the periphery of the polyethylene insert, as a reference to line up the two pictures. This measurement was carried out to the closest 0.5 mm.

We also evaluated the femoral component to see if there was bone resorption which might be related to granuloma formation due to titanium or polyethylene wear particles (5, 6). The location of any osteolysis was described according to the seven zones proposed by Gruen *et al.* (11). However, the commonly observed bone atrophy due to stress-shielding of the proximal part of the femur through the prosthesis stem has been considered irrelevant for the present purpose and has therefore not been specially presented and discussed.

RESULTS

General

Nineteen hip sockets had to be revised up to March 1997, in 6 men and 13 women (table I). The mean time until revision surgery was 3.6 years (men 3.0 years, women 3.9 years). In 13 cases the reason for revision was aseptic loosening of the hip-socket, 7 times with a broken outer split ring with a damaged polyethylene inlay (figs. 3a, b). In one case the reason for aseptic loosening was a trauma from skiing. In three other patients the hip socket had to be changed because of severe groin pain caused by the iliopsoas muscle rubbing against the malpositioned acetabular component, that was retroverted and extended anteriorly. One revision was carried out because of a malpositioned hip-socket that had caused dislocation of the hip several times. A hip-socket, implanted with too

Table I. — Reasons for revision

Reason	Number of patients	Mean time of survival (months)
aseptic loosening (no breakage)	6	45
septic loosening	1	25
implant breakage	7	55
iliopsoas impingement	3	33
other reasons	2	16
Total	19	43


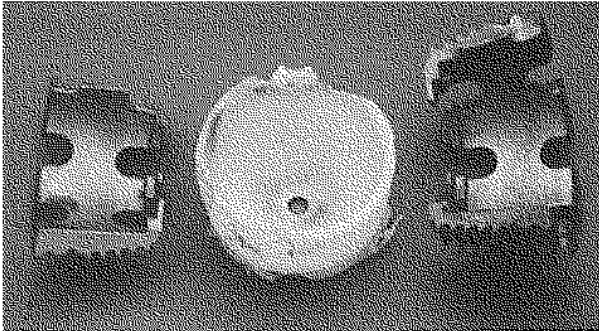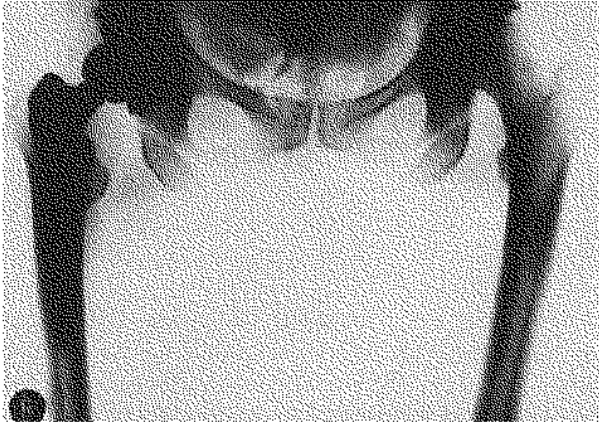


Fig. 3. — *a)* A too vertically implanted Balgrist hip socket of 50-mm outer diameter combined with a 32-mm ball head. *b)* Overstressing of the metal backing and breakage of the split ring due to the situation in a), which involves a relatively thin HDPE inlay. *c)* Another insert that was removed 2 years after implantation showing the appearance of the outer surface.

much anteversion, was revised because of restricted range of motion with extension deficit. One socket was revised following septic loosening. Eighteen patients died, 14 men and 4 women. None of them needed revision surgery before death.

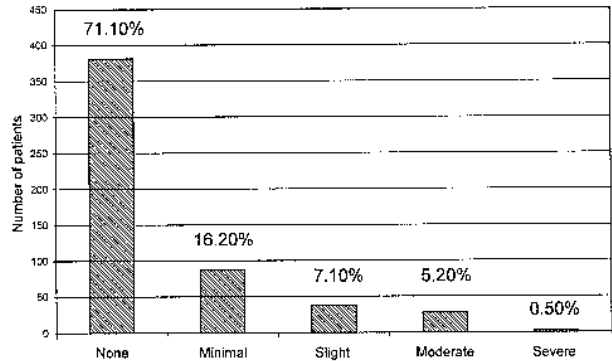


Fig. 4. — Pain in the operated hip joint.

Of the 537 patients interviewed, 71.1% never had any pain in the operated hip, 16.2% minimal and 7.1% slight pain, whereas 5.7% reported moderate or severe pain (fig. 4). The majority of the patients (88.1%) had no problems putting on their shoes (fig. 5); 76.2% were able to walk one or more hours; 18.9% distances up to 2 km, 2.0% could only walk 500 m and 3.0% were only able to walk at home or were unable to walk at all (fig. 6). Of all patients, 91.7% were very or mostly content with the result of hip arthroplasty, 6.6% were partially, and 1.7% were not satisfied with the procedure.

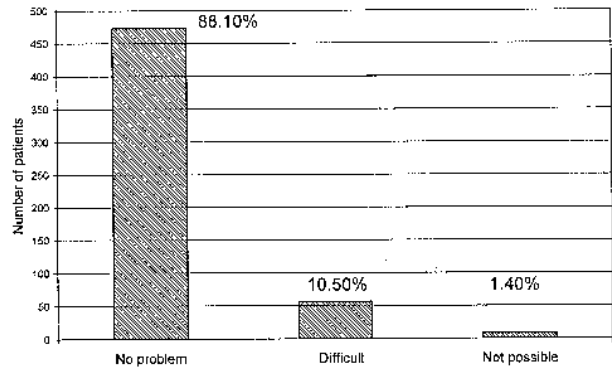


Fig. 5. — Problems putting the shoes on.

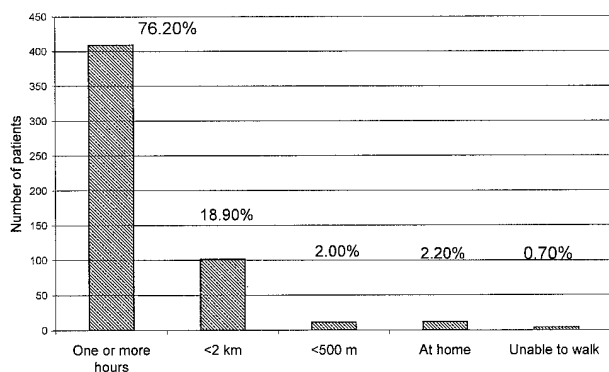


Fig. 6. — Walking distance.

According to the modified Merle d'Aubigne scoring system used (max. 12 points for “very good”), 457 hips were classified as “very good” (382 with 12 points, and 75 with 11 points), 98 hips as “good” (10 points), 34 hips as “satisfactory” (9 points), 39 hips as “fair” (8 points), and 59 hips as “poor” (< 8 points). The last group of 59 patients included the 19 sockets that were revised and the 18 patients who died during the period of investigation.

The Kaplan-Meier survival curve shows a 9-year-survival probability of 92.1% (95% confidence interval ranging from 0.875 to 0.966) (fig. 7).

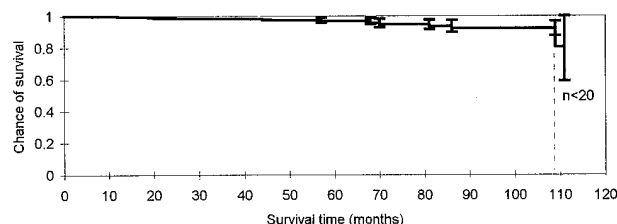


Fig. 7. — Kaplan-Meier Survivorship Analysis of 687 primary implanted Balgrist hip sockets. The 9-year survival probability is 92.1%. Because of the small number of patients ($n = 20$) followed up more than nine years, conclusions can be drawn only for the 9-year survivorship.

Radiological

The radiological investigation carried out on the 25 patients (26 implants) who have had this socket implanted for the greatest length of time (8-12 years), showed no cases where linear radiolucent

lines at the bone-implant surface were present. For instance, what might be expected to be a trace of a radiolucent line in fig. 2 (superolateral border) is actually a narrow zone of trabecular bone, connecting the former layer of subchondral cortical bone with the ribs on the outer surface of the titanium shell. However, far laterally, a small space that existed immediately after implantation of the socket appears to have remained void, without bone having bridged this gap.

Except in one case, no signs of migration or tilting were seen. In this single case (L.D.1919) a total upward migration of about 8 mm, with tilting of about 4° (socket axis now more vertical), was determined. None of the 26 acetabular components had broken. In two cases expansive osteolytic changes that ballooned into the trabecular bone, and which were not demarcated by a sclerotic seam, were present. In one of these two cases (R.K.1934), one lesion measured about 0.4 cm² in zone 1 and a second lesion measured about 2.6 cm² in zone 2. The second case showed one lesion in zone 1 measuring 1.1 cm² and one in zone 2 with an area of about 1.7 cm². Nevertheless, in both cases the socket appeared stable.

The quality of the radiographs permitted the measurement of wear in 23 instances (in 3 cases it was not possible). Average wear amounted to 1.0 mm, ranging from 0 to 3.0 mm. Wear of more than 2 mm was found only in two cases, 3 mm in each.

On the femoral side, all cases showed the commonly encountered bone atrophy at the proximal end of the femur due to stress-shielding. One case was seen with linear radiolucent lines of at least 3 mm at the bone-implant interface practically all around the implant with evidence of subsidence of about 5 mm. A further femoral shaft (case R.K. 1934, mentioned above) showed two expansive ballooning lesions of about 1.5 cm² and 1.1 cm², localized in zones 1 and 7, respectively.

DISCUSSION

The aim of our study was to carry out a survival analysis of the Balgrist hip socket while keeping the number of patients lost to follow-up as low

as possible. We were aware from other studies that a number of patients are not willing to come for a checkup, especially those with either excellent or poor results (25). Furthermore, an increasing number of patients do not agree to have an xray taken unless this is absolutely necessary. We therefore decided to use a method which allowed us to obtain as much relevant information as possible while keeping expenses low. Interviewing the patients by telephone by an independent interviewer (in no case was it the surgeon who implanted the socket) with a standardized questionnaire, gave us all the subjective and some of the clinical parameters we required. Most important was whether a revision had taken place or not. Patients with problems were clinically and radiographically examined, unless they expressly declined. A critical problem is the discrepancy between clinical symptoms (or subjective results) and radiographic evidence of loosening, the latter not being adequately defined. Kavanagh *et al.* (20) report that of all radiographically evident loosening of acetabular components, only 33% were symptomatic. Also, pain in the operated hip does not always indicate loosening, insofar as excellent or good hip scores occasionally appear together with loose implants (10).

There are many types of hip scores (21), and big differences have been reported even in evaluation of the same patients (1, 3). Many components of the hip scores are purely subjective, e.g. 91% of the Harris Hip Score is based on a patient-subjective evaluation (21). Bryant *et al.* (3) report that the essential measurable variables appear to be the walking distance, hip flexion and pain. Measurement of more than these variables would add only little further information and would barely affect the outcome of the investigation. They recommend that these three variables be recorded separately, because numerical scores are arbitrary and without scientific foundation. Instead of measurement of motion, evaluation of certain functional activities, like putting on shoes, would have the advantage of providing fairly accurate answers without direct examination (10). In our questionnaire we followed the suggestions of Bryant *et al.* (3) by assessing functional activity by walking distance, movement by the ability to

put on shoes or to sit comfortably, and by pain. Also, using the information obtained, we evaluated the patients according to a modified Merle d'Aubigné rating system. In this rating system, only pain and walking ability are assessed, and this leads to a maximum number of 12 points (2×6) in a very good case. With 555 hips being classified as "good" (10 points) or "very good" (> 10 points), 81% of all hip sockets were within these categories. "Poor" was defined for a very wide range, from 7 to 0 points, and 59 patients fell into this group. These cases included the 19 sockets that were revised and the 18 patients who died during the period of investigation.

Altogether 19 of the 687 hip sockets had to be revised, but in only 13 cases was this caused by aseptic loosening, 7 of which resulted from a broken outer split ring or inlay. In one case the loosening was due to a skiing accident. Five of the 13 aseptic loosening sockets were sockets of 50-mm outer diameter paired with a ball of 32-mm diameter. This head size was used until 1994. It has been completely abandoned in favor of the 28-mm head, which was first introduced in 1992. The 50-mm socket combined with a 32-mm head therefore resulted in a relatively thin HDPE inlay, which under adverse load-bearing conditions led to overstressing of the metal backing. Walker and Zhou (34) showed that a thicker HDPE tibial component of knee arthroplasties provides load distribution over a larger area, thus reducing the stress in the HDPE material and also at the interfaces. In 3 cases the outer split ring fractured in the area of maximum load (cranial). Of these, in one case the outer split ring broke after trauma from skiing and in two cases of relatively vertically implanted sockets (rotational axis of cone, or taper, rather horizontal, as in fig. 2), a fracture of the ring developed. One vertically implanted hip socket of 47-mm outer diameter (with 28-mm ball head) in congenital dysplasia of the hip also had to be revised because of a broken outer split ring and inlay. The only septic loosening was an infection that developed after 25 months in an immunologically suppressed patient. In 3 cases the hip socket was revised because of severe groin pain which increased in active hip flexion and passive hip extension, caused by the anterior iliopsoas

tendon rubbing against a malpositioned acetabular component. The hip sockets were in retroversion and extended anteriorly. The impingement of the iliopsoas tendon was visualized with arthrography or sonography and could be verified intraoperatively. This cause of hip pain has been reported before by Trousdale *et al.* (33). The reason for such occurrences is possibly that the Balgrist socket can be firmly implanted without the precision normally required by other press-fit sockets. This ease of implantation unfortunately promotes the possibility of leaving the implant extending out of the bony acetabulum anteriorly and laterally, that is, without bone coverage. The situation is worsened if the implant is placed in retroversion.

In one case we had the opportunity to examine a socket that had been removed because of persisting pain 2 years after implantation, with no other signs of loosening. The tapered insert (fig. 3c) showed only signs of slight protrusion (< 0.2 mm) into the apertures present at the lateral aspect of the titanium ring. The surface area that entered the apertures still exhibited the machining grooves from the manufacturing process, thus indicating that no rubbing or scoring against bone had taken place. Also further medially, and toward the apex of the acetabulum, the machining grooves again become visible in an area that is completely in contact with the titanium surface (which itself is smoothly machined), thus showing that here too, no abrasion had become evident. This example, which came from a university hospital in Spain, and does not belong to the collective of 687 sockets reported here, is a confirmation that virtually no movement occurs between insert and outer ring, once the former has settled into its final position.

As mentioned previously, the good subjective results alone do not allow us to conclude that none of these implants have loosened. On the other hand, not all of the nearly 13% with slight, moderate or severe pain will have a loosened hip socket, because it is difficult to differentiate from pain arising from the femoral shaft or from the acetabular component. Other extra-articular causes of hip pain after arthroplasty may also be the cause.

Even though, as mentioned above, a correlation between radiological evidence of implant behavior within the host bone and clinical findings is not always possible and therefore not reliable, it is nevertheless necessary to show whether a destructive process is in progress or not. This is especially so when fear of massive bone lesions, through the action of polyethylene wear particles, for example, exists. Therefore, we carried out a radiological examination on a limited number of patients (25 patients with 26 implants) so that a follow-up of 8 to 12 years was possible. These patients were taken in strictly chronological order of implantation, and apart from the matter of availability (those living outside the city were not approached, others had died, etc.), no other criterion was applied in selecting them. The average age of these 25 patients at the time the last radiographs were made was 67 years, ranging from 43 to 81. The standard anterior-posterior radiographs allowed direct comparison with the first postoperative pictures taken.

None of the sockets were seen to exhibit linear radiolucent lines at the bone-implant interface. Also, none of the acetabular components had broken. Considering the difficulty in ascertaining the exact amount of wear from conventional radiographs, and observing that a wear rate of up to 0.2 mm/year for the HDPE of hip prostheses is common (23), we decided to set a value of 2 mm as an upper limit for the acceptable total wear in 10 years. Measurement of wear on 23 implants (3 radiographs could not be evaluated) actually indicated an average value of 1 mm, ranging from 0 to 3 mm. Wear of more than 2 mm was found only in two instances, 3 mm in each. In one of these two cases with 3 mm wear (L.D. 1919), migration of the socket was also seen, this in a vertical direction and measuring about 8 mm. In this particular case the socket had been implanted in a 72-year-old man who had undergone radiation therapy for a bladder tumor and who also had a Girdlestone hip after a deep infection of the joint and resection of the femoral head and neck. The Balgrist socket had been implanted particularly deep in the first place, allowing the medial corner to project into the lesser pelvis by

as much as 9 mm. It is worthy of mention that the same patient has a similar hip replacement on the contralateral side, that had been implanted a year earlier, and which shows no signs of any disorder. The patient, who is now 80 years of age, continues to be satisfied with both his hips.

In two other cases we observed expansive osteolytic changes in zones 1 and 2 of the acetabular region that ballooned into the trabecular bone, and which were not demarcated by sclerotic bone. In one of these two cases (R.K. 1934), one lesion measured about 0.4 cm² in zone 1 and a second lesion measured about 2.6 cm² in zone 2. The second case showed one lesion in zone 1 measuring 1.1 cm² and one in zone 2 with an area of about 1.7 cm². Nevertheless, in both cases the socket appeared stable.

The case R.K. 1934 also showed ballooning lesions around the femoral implant. Wear particles would be expected to be responsible for this, but in this particular case the amount of wear measured was negligible.

On the femoral side, all cases showed the commonly encountered bone atrophy at the proximal end of the femur due to stress-shielding. One case was seen with linear radiolucent lines of at least 3 mm at the bone-implant interface practically all around the implant with evidence of subsidence of about 5 mm. A further femoral shaft (case R.K. 1934, mentioned above) showed two expansive ballooning lesions of about 1.5 cm² and 1.1 cm², localized in zones 1 and 7, respectively.

We used the Kaplan-Meier survival curve (19) and a full life-table analysis (12, 31) with confidence intervals (22) for estimating the survival rate after 9 years. As the endpoint for our survival analysis we used the only well-defined endpoint, namely, the time to revision, for any reason. This provides a good means of comparing the life span of different types of prosthesis with each other (22). We also present the 95% confidence interval, as recommended by Dorey *et al.* (8) and Dorey and Korn (9). Most important for the comparison of two or more survivorship curves is that they should be composed of comparable patient populations, in particular with respect to such variables as age, diagnosis and activity level, which are known to be related to prosthesis failure. To prevent being misled by the right-hand tails of the survival curves, it is recommended by Dorey and Amstutz (8) to discuss only curves that include a reasonable number of patients (> 20) who are still being followed. The last time period discussed by us for survivorship included 34 patients. Only 8 patients had a follow-up longer than nine years, and therefore no conclusions have been drawn for this length of time.

In several publications evaluating the survivorship of hip arthroplasty no distinction was made between survival of the shaft and that of the acetabular component. Others again either do not describe their statistical analysis, or they only present the percentage of failures (number of failures as a percentage of the total number of

Table II. — Results of survivorship analysis of different noncemented acetabular sockets

Author	Year of publication	Type of acetabular component	Follow-up time (years)	Number of acetabular components	Type of analysis	Defined endpoint	Survivorship
Sedel <i>et al.</i>	1990	alumina-on-alumina	10	71	Armitage	revision	98.0%
Chauvet <i>et al.</i>	1992	Lord/Motta cups	5	72	Kaplan-Meier	revision	59.3%
Owen <i>et al.</i>	1994	PCA	8	241	Kaplan-Meier	revision	57.0%
Savilahti <i>et al.</i>	1995	Link RS	7	100	Armitage	intention for revision	89.0%
Huo <i>et al.</i>	1996	Mittelmeier	10	112	Kaplan-Meier	revision	87.9%
Tompkins <i>et al.</i>	1997	Harris-Galante Type I	10	204	Kaplan-Meier	revision, aseptic loosening, reoperation	97.0%
Echtler <i>et al.</i>	1999	Balgrist	9	687	Kaplan-Meier	revision	92.1%

prostheses implanted). This can produce misleading results, since the duration of the implant is a dominant determinant of failure, and the larger the proportion of recent implants in the total, the lower will the rate of failure appear to be (31).

Table II compares the results of our survivorship analysis with those published for other noncemented hip-socket systems (6, 15, 26, 29, 30, 32). The above-mentioned reports review smaller numbers of cases than we did, but mostly with a longer mean follow-up time. In some cases the implantation was carried out by only one experienced surgeon, whereas our 687 hip sockets were implanted by 15 different surgeons, including residents. About 25% of the revised hip sockets had to be revised because of technical errors in implantation. With a 92.1% survivorship after eight years, in which the defined endpoint was revision of the implant for any reason, the Balgrist hip socket can be ranked among the most successful uncemented acetabular components that have been investigated. Therefore it can be concluded that the unusual principle of fixation of the Balgrist hip socket has proved to function. With an improved implantation technique that would avoid positioning the socket too "vertically", and with measures to ensure that the sockets do not extend either anteriorly or laterally, the results in the future could even be better.

Acknowledgement

We wish to express our thanks to Prof. C. Gerber for his unrelenting support given to this project, to Dr. V. Zdravkovic for his advice on the use of statistical methods in evaluating the results, to Dr. J. Hodler and his staff of the radiology department, and to Dr. M. Noger for carrying out the radiological evaluation.

REFERENCES

- Andersson G. Hip assessment : A comparison of nine different methods. *J. Bone Joint Surg.*, 1972, 54-B, 621-625.
- Bertin B. C., Freeman M. A. R., Morscher E., Oeri A., Ring P. A. Cementless acetabular replacement using a pegged polyethylene prosthesis. *Arch. Orthop. Trauma Surg.*, 1985, 104, 251-261.
- Bryant M. J., Kernohan W. G., Nixon J.R., Mollan R.A.B. A statistical analysis of hip scores. *J. Bone Joint Surg.*, 1993, 75-B, 705-709.
- Callaghan J. J., Dysart S. H., Savoy, C. G. The uncemented porous-coated anatomic total hip prosthesis. Two year results of a prospective consecutive series. *J. Bone Joint Surg.*, 1988, 70-A, 337-346.
- Callaghan J. J., Dysart S. H., Savory C. F., Hopkinson W. J. Assessing the results of hip replacement. A comparison of five different rating systems. *J. Bone Joint Surg.*, 1990, 72-B, 1008-1009.
- Chauvet J. F., Pascarel X., Bosredon J., Honton J. L. Screwed acetabulum : Results of 72 cases with a mean follow-up of 5 years (French). *Rev. Chir. Orthop.*, 1992, 78, 340-346.
- DeLee J. G., Charnley J. Radiological demarcation of cemented sockets in total hip replacement. *Clin. Orthop.*, 1976, 121, 20-32.
- Dorey F., Amstutz H. C. Survivorship analysis in the evaluation of joint replacement. *J. Arthroplasty*, 1986, 1, 63-69.
- Dorey F., Korn E. L. Effective sample sizes for confidence intervals for survival probabilities. *Stat. Med.*, 1987, 6, 679-687.
- Galante J. The need for a standardized system for evaluating results of total hip surgery. *J. Bone Joint Surg.*, 1985, 67-A, 511-512.
- Gruen T. A., McNeice G. M., Amstutz H. C. "Modes of Failure" of cemented stem-type femoral components. *Clin. Orthop.*, 1979, 141, 17-27.
- Hassenpflug J., Hahne H. J., Hedderich J. Gedanken zur Anwendung der "Life-Table-Methode" in der Orthopädie. *Z. Orthop.*, 1992, 130, 223-229.
- Hauser R., Jacob H. A. C., Schreiber A. The Balgrist hip socket for fixation without cement : Analysis of 387 primary total hip replacements. *Bull. Hosp. Joint Dis.*, 1996, 54, 180-185.
- Heekin R. D., Callaghan J. J., Hopkinson W. D., Savoy C. G., Xenos J. S. The porous coated anatomic total hip prosthesis, inserted without cement. *J. Bone and Joint Surg.*, 1993, 75-A, 77-91.
- Huo M. H., Martin R. P., Zatorski L. E., Keggi K. J. Total hip replacements using the ceramic Mittelmeier prosthesis. *Clin. Orthop.*, 1996, 332, 143-150.
- Ilchmann T., Franzén H., Mjöberg B., Wingstrand H. Measurement accuracy in acetabular cup migration. A comparison of four radiologic methods versus roentgen stereophotogrammetric analysis. *J. Arthroplasty*, 1992, 7, 121-127.
- Jacob H. A. C., Hilfiker B. Die nachspannende Balgrist-Hüftpfanne für zementlose Fixation : Entwicklungsgeschichte und bisherige klinische Erfahrungen. *Z. Orthop.*, 1990, 128, 254-261.
- Jacob H. A. C., Huggler A. H., Dietschi C., Schreiber A. Mechanical function of subchondral bone as experimentally determined on the acetabulum of the human pelvis. *J. Biomech.*, 1976, 9, 625-627.
- Kaplan E. L., Meier P. Nonparametric estimation from incomplete observations. *J. Am. Stat. Assoc.* 1958, 53, 457-81

20. Kavanagh B. F., Ilstrup D. M., Fitzgerald R. H. Revision total hip arthroplasty. *J. Bone Joint Surg.*, 1985, 67-A, 517-526.
21. Krämer K. L., Maichl F. P. Scores, Bewertungsschemata und Klassifikationen in Orthopädie und Traumatologie. Thieme Verlag, 1993, pp. 183-222.
22. Lettin A. W. F., Ware H. S., Morris R. W. Survivorship analysis and confidence intervals. An assessment with reference to the Stanmore total knee replacement. *J. Bone Joint Surg.*, 1991, 73-B, 729-731.
23. Livermore J., Ilstrup D., Morrey B. Effect of femoral head size on wear of the polyethylene acetabular component. *J. Bone Joint Surg.*, 1990, 72-A, 518-527.
24. Mc Auley J. P., Moore K. D., Culpepper W. J., Engh C. A. Total hip arthroplasty with porous-coated prostheses fixed without cement in patients who are sixty-five years of age or older. *J. Bone Joint Surg.*, 1998, 80-A, 1648-1655.
25. Murray D. W., Britton A. R., Bulstrode C. J. K. Loss to follow-up matters. *J. Bone Joint Surg.*, 1997, 79-B, 254-257.
26. Owen T. D., Moran C. G., Smith S. R., Pinder I. M. Results of uncemented porous-coated anatomic total hip replacement. *J. Bone Joint Surg.*, 1994, 76-B, 258-262.
27. Pettersson H., Gentz C.-F., Lindberg H. O., Carlsson A. S. Radiologic evaluation of the position of the acetabular component of the total hip prosthesis. *Acta Radiol. Diag.*, 1982, 23, 259-263.
28. Remagen W., Morscher E. Histological results with cement-free implanted hip joint sockets of polyethylene. *Arch. Orthop. Trauma Surg.*, 1984, 103, 145-151.
29. Savilahti S., Myllyneva I., Lindholm T. S., Pajamaki K. J., Nevalainen J., Laippala P. Clinical outcome and survival of Link RS total hip prosthesis. *J. Bone Joint Surg.*, 1995, 77-B, 369-373.
30. Sedel L., Kerboull L., Christel P., Meunier A., Witvoet J. Alumina-on-alumina hip replacement. Results and survivorship in young patients. *J. Bone Joint Surg.*, 1990, 72-B, 658-663.
31. Tew M., Waugh W. Estimating the survival time of knee replacements. *J. Bone Joint Surg.*, 1992, 64-B, 579-582.
32. Tompkins G. S., Jacobs J. J., Kull L. R., Rosenberg A. G., Galante J. O. Primary total hip arthroplasty with a porous-coated acetabular component. *J. Bone Joint Surg.*, 1997, 79-A, 169-176.
33. Trousdale R. T., Cabanela M. E., Berry D. J. Anterior iliopsoas impingement after total hip arthroplasty. *J. Arthropl.*, 1995, 10, 546-549.
34. Walker P., Zhou X. The dilemma of surface design in total knee replacement. *Trans. Orthop. Res. Soc.*, 1987, 12, 291.

SAMENVATTING

B. ECHTLER, H. A. C. JACOB, M. HOUWELING, O. HERSCHE. 8 jaarsoverlevingsanalyse en subjectieve resultaten van 687 primaire Balgrist heupacetabulum.

De Balgrist heup cup bestaat uit een uitwendige gesplitte titanium ring in de vorm van een conus, welke uitzet door een spitstoelopende HDPE insert tijdens de implantatie om aldus een stevige press-fit en een postoperatief verder aanspannen te verzekeren. Tussen november 1987 en oktober 1996 werden dergelijke cup bij 687 heupen in 555 patiënten ingebracht. Men zag er 537 terug. Daarbij had 71% nooit pijn, 88,1% had geen problemen met schoenen aandoen, 76,2% kon één of meerdere uren wandelen. Algemeen was 91,7% tevreden over de ingreep. Tot april 1997 werden 19 cups gereviseerd. Met een 92,1% Kaplan-Meier overleving op 8 jaar is de Balgrist cup bij de meest succesvolle niet-gecementeerde cups.

RÉSUMÉ

B. ECHTLER, H. A. C. JACOB, M. HOUWELING, O. HERSCHE. Survie à 8 ans et résultats subjectifs de 687 cotyles de Balgrist en implantation primaire.

Le cotyle de Balgrist comporte un anneau de titane fendu, de forme tronc-cônique, dans lequel s'encastre un insert en polyéthylène, également tronc-cônique, qui provoque l'expansion de l'anneau ; ceci assure un bon press fit initial, avec possibilité d'expansion supplémentaire pendant la phase de remodelage post-opératoire. De novembre 1987 à octobre 1996, ce cotyle a été utilisé dans 687 arthroplasties primaires chez 555 patients. L'étude a porté sur 537 patients : 71,1% n'ont jamais eu de douleurs à la hanche opérée, 88,1% enfilent leurs chaussures sans difficulté, 76,2% sont capables de marcher une heure ou davantage. De plus, 91,7% se disent satisfaits de leur résultat. En avril 1997, 19 cotyles avaient dû être repris. Le taux de survie à 8 ans, calculé selon Kaplan-Meier, est de 92,1% ; ce taux soutient la comparaison avec celui des meilleurs cotyles non cimentés.