

# DIAGNOSIS AND TREATMENT OF ACUTE RUPTURES OF THE ACHILLES TENDON CURRENT CONCEPTS REVIEW

N. POPOVIC, R. LEMAIRE

Subcutaneous rupture of the Achilles tendon seems to have become more common in recent years. This results from a combination of more awareness in the medical field and greater participation in physical activities by the general population.

The causes of Achilles tendon rupture are multifactorial and still unclear. The diagnosis can be made based on physical examination ; special diagnostic studies are rarely necessary.

The literature on ruptures of the Achilles tendon and associated treatment has expanded over the past decade. The lack of a universal, consistent protocol for subjective and objective evaluation following treatment of Achilles tendon rupture has prevented any comparison of results. There is still controversy concerning the best treatment. From a literature review, it appears that a satisfactory outcome may be achieved with either nonoperative or operative treatment but surgical repair appears to provide better functional capacity. Lower rerupture rates and slightly improved strength and functional ability may be expected with surgical treatment ; however, the rate of minor complications is higher than with nonoperative treatment. Reports in the literature indicate that in active, young, very demanding individuals, surgical repair should be considered, with nonsurgical treatment reserved for elderly or sedentary patients.

There is no single, uniformly accepted surgical technique for Achilles tendon repair. Most acute ruptures have been treated successfully with simple end-to-end suture, although various augmentation procedures have been combined with simple suture with satisfactory outcomes. To minimize the complications typically associated with open surgery, percutaneous techniques to repair the ruptured Achilles tendon have been advocated, and the results are reported to be promising, although not without failures and complications. Several recent studies have reported functional benefits of early post-

operative tendon mobilization in well-motivated patients, since treatment results are determined not only by the method of repair but also, and perhaps more importantly, by the early postoperative functional rehabilitation.

**Keywords :** Achilles tendon ; rupture ; treatment.

**Mots-clés :** tendon d'Achille ; rupture ; traitement.

---

## INTRODUCTION

Rupture of the Achilles tendon (AT) was reportedly first described by Ambroise Paré in 1575 and was reported in the literature in 1633 (71). Until the beginning of the 20th Century, the treatment was predominantly nonoperative : various means of immobilization were used, with limited success. After the 1920's, the use of operative treatment increased, primarily because of reports by Abrahamsen (1) in 1923 and Quénu and Stoïanovitch (73) in 1929 who advocated surgical repair, based on accumulated cases from the literature. Surgery became the accepted treatment of Achilles tendon rupture. This period was characterized by statements such as "Patients with a rupture of the Achilles tendon should be operated on and should be operated on without delay" (66).

When Lee and Smith (49) published their results in 1972, it became obvious that nonsurgical treatment also gave good results, as good as those

---

Department of Orthopedic Surgery and Traumatology,  
University Hospital Sart-Tilman, B-4000 Liège, Belgium.

Correspondence and reprints : N. Popovic.

reported in surgical series. For that reason, in 1973, an editorial in *The Lancet* stated that "In view of the excellent results obtainable by conservative treatment it is doubtful whether surgical repair in closed rupture of the Achilles tendon can still be justified" (2).

More recently, some surgeons stated that, with current advances in surgical repair techniques and owing to the excellent results obtainable by functional postoperative treatment, it is doubtful whether cast immobilization after Achilles tendon suture repair can be justified (12).

Animal and human investigations have shown that a biphasic separation between the tendon ends occurs, despite adequate tendon sutures and immobilization (67). The controversy concerning the best treatment is still present, since clinical results are determined not only by the methods of repair but also, and perhaps more importantly, by the functional rehabilitation after repair. The risks and benefits of open versus closed treatment continue to be debated. Which option should the orthopedic surgeon select? What is the safest, most cost-effective method of treatment and what should be the "standard treatment" for acute Achilles tendon rupture remains a matter of controversy.

This paper reviews the literature concerning the incidence, etiology, diagnosis and treatment of acute Achilles tendon ruptures.

## INCIDENCE

There are only a few epidemiological studies on the incidence of Achilles tendon ruptures. Only 66 ruptures of the Achilles tendon had been reported in the literature before 1929 (73). In 1969, Goldman *et al.* (25) found only 38 cases of proven complete rupture treated in a 20-year period at the Mayo Clinic.

Ruptures of the Achilles tendon have been reported to occur infrequently (27). This suggestion may be misleading, because Arner and Lindholm (4) stated in 1959 that the incidence of Achilles tendon rupture in their practice had approximately doubled once they became attuned to the diagnosis.

Holz and Asherl (28) noted that ruptures of the Achilles tendon are relatively common in developed countries. In 1981, Nistor (66) reported 107 patients treated over a period of four years at the only hospital serving a population of approximately 500,000. On the other hand, in 1977, Sun-Yu-Sheng *et al.* (85) reported only 40 cases during a 5-year period from a hospital serving a Chinese city of 2.5 million inhabitants.

Ruptures of the Achilles tendon have become more common in the recent years. They are closely associated with sports activities. It has been reported that 75% of nearly 4,000 ruptures were related to sports (29).

The reported incidence of Achilles tendon rupture is 2 to 12 times higher in men than in women (16, 26). Achilles tendon ruptures are most frequently unilateral, and a slight left leg predominance has been reported (50). Simultaneous bilateral AT ruptures are very rare in healthy individuals; they can occur in older patients with underlying systemic disease or a history of long-term steroid medication.

An average of 10% (range 1 to 36%) of patients with complete rupture have had preceding symptoms for a variable period of time (50).

Leppilahti and Orava (50) reported an average 2% (range 0 to 8%) of patients with AT rupture had received earlier local corticosteroid injections around the AT for peritendinitis and tendinitis.

## ETIOLOGY

Spontaneous rupture of the Achilles tendon remains an incompletely understood phenomenon. The exact causes of Achilles tendon ruptures are still unclear, but the literature is replete with theories, including repetitive microtrauma (21), inhibitor mechanism malfunction (30), a correlation of rupture with blood type O (35), hypoxic and mucoid tendon degeneration (37), decreased perfusion that results in degenerative changes (48) and systemic or locally injected steroids (57).

Initially experiments on rupture supported the degeneration theory rather than the mechanical theory (21, 27). Lagergren and Lindholm (48) noted that ruptures of the Achilles tendon are

usually limited to a definite segment of the tendon 2 to 6 cm proximal to its insertion on the calcaneus. In a microangiographic study in nine specimens they found that the proximal muscle and the distal insertion were well supplied with vessels, which decreased toward the tendon segment that was more prone to rupture. They concluded that the poor blood supply in this segment (2-6 cm) may contribute to ruptures.

In a supporting study, Arner *et al.* (6) found edematous disintegration of the tendon tissue with fragmentation of the collagen bundles and absence or decreased frequency of cell nuclei in cases with Achilles tendon rupture. They thought that these changes were consistent with poor blood supply as the causative factor. Such information has been used in the literature to support a degeneration theory to explain the cause of Achilles tendon ruptures. In contrast, Schmidt *et al.* (78) stated that the area of poor vascularization and the rupture site of the Achilles tendon do not necessarily correlate with each other.

The fact that the peak incidence of Achilles tendon ruptures occurs in the middle age group rather than in the older population suggests a mechanical etiology for tendon rupture (7, 38).

Barfred (7) supported the possibility that mechanical factors are involved in Achilles tendon ruptures. In his rupture experiments on anesthetized rats, the calcaneus was rotated to correspond with inversion or eversion of the foot, and the muscles were electrically stimulated via the sciatic nerve. Preceding damage was not needed for tendon rupture to occur and the risk of tendon rupture was increased after oblique traction.

The low number of reported ruptures in well-conditioned, professional athletes lends support to both of these theories, which in fact may be interrelated. There are clinical case reports of AT ruptures related to use of corticosteroids, but there are no published rigorous studies in the literature that evaluate the risk of rupture with local corticosteroid injection. However fluoroquinolone antibacterials have recently been implicated in the etiology of AT tendinitis and subsequent tendon rupture (50). The quinolones may have a toxic effect on tendon tissue. We can conclude that the

etiological basis for these ruptures may be simple or multifactorial.

## DIAGNOSIS

The diagnosis of Achilles tendon rupture is not difficult and is based almost solely on the history and physical findings. These ruptures usually occur in men between 30 and 50 years of age (8). There is an apparent predilection for the weekend athletes engaging in acceleration - deceleration sports.

Soldatis *et al.* (81) reported similar numbers of patients describing their symptoms after an acceleration or a deceleration maneuver. This is in contrast with the study by Beskin *et al.* (8), whose patients all reported acceleration events.

Arner and Lindholm (5) distinguished three main types of indirect injury capable of causing a rupture. These were pushing off with the weight-bearing forefoot while extending the knee, sudden, unexpected dorsiflexion of the ankle and violent dorsiflexion of the plantar-flexed foot. Rupture can also be caused by direct blows to the tendon (27).

The classic history is sudden pain in the calf associated with an audible snap, and this is followed by difficulty in stepping off on the foot. The initially minimal or absent pain often leads both patients and physicians to regard the injury as trivial. It has been reported that Achilles tendon rupture tends to be missed by the primary physician as often as 25% of the time. The importance of recognizing rupture of the Achilles tendon without delay was stressed by several authors (17, 79). An overlooked Achilles tendon rupture, and consequently a delayed treatment, tends to end up in reduced function in daily life and certainly gives an athlete a diminished chance to return to sports activities at the same level as before the injury (81).

Physical examination of the fresh rupture can reveal swelling of the calf as well as a palpable defect in the tendon. To avoid misdiagnosis, several diagnostic tests and signs are available: Simmond's test (50), Thompson's test (87), the

resisted plantar flexion test (50), the needle test (68), the Brunet-Guedj sign and the sphygmomanometer cuff test described by Copeland (in 50). The Thompson squeeze test is most often used in orthopedic practice, and it should be performed in any evaluation of ankle pain. If the calf muscles are squeezed just distal to their maximal girth, the foot goes into plantar flexion unless the soleus is detached from the Achilles tendon. A positive test is characterized by absence of plantar movement of the foot, and this indicates complete rupture of the heel cord. In many cases, active plantar flexion of the ankle may be maintained in the patients with Achilles tendon rupture by the action of the intact tibialis posterior, peroneals and long toe flexors (83). Lift-off on both forefeet together may be possible, but lift-off on the affected extremity alone will typically be impossible. The diagnosis of complete rupture of Achilles tendon is certain if the results of at least two of these clinical tests were positive.

Few articles reported verification of the rupture by lateral radiographs. Kager (37) described a triangle seen on the radiograph that is filled with fatty tissue and is bound by the margins of the Achilles tendon, the calcaneus and the deep flexors. When the Achilles tendon is ruptured, the triangle loses its regular configuration. Toygar (88) suggested measuring the angle of the posterior skin surface as visualized on the radiograph because the ends of the tendon are displaced anteriorly after rupture; the angle becomes  $130^{\circ}$  to  $150^{\circ}$ . Most authors have not found these investigations useful and consider radiographic studies of secondary importance to physical examination (24, 27, 29, 66, 74).

Sophisticated imaging modalities generally are not necessary. The two modalities that can best image the Achilles tendon are sonography and magnetic resonance imaging; each has inherent advantages and disadvantages. Sonography is relatively inexpensive, is fast and repeatable and has the potential for dynamic examination. It does, however, require substantial experience to learn how to operate the probe and interpret the images correctly.

In contrast to sonography, MR imaging is relatively expensive and is typically not used for

dynamic assessment. It is superior in the detection of incomplete tendon ruptures and the evaluation of various stages of chronic degenerative changes.

The postsurgical appearance of Achilles tendon rupture on ultrasonography and MR imaging has been studied (40, 69). The common finding in these studies has been thickening of the Achilles tendon. How important is ultrasound with regard to the functional evaluation of late results? Rupp *et al.* (77) stated that US examination is able to reveal long-lasting alterations in echogenicity of the tendon, but is only of limited value with regard to evaluation of the functional results after surgical repair. We can conclude that ultrasonography is the imaging method of choice, and MR imaging is an additional optional procedure.

## TREATMENT

The goals of treatment of a ruptured Achilles tendon are to restore length and tension and thereby to optimize ultimate strength and function. There continues to be controversy as to whether operative or nonoperative treatment best achieves these goals. Options for treatment include nonoperative closed methods, open surgical procedures, and percutaneous methods of repair.

### NONSURGICAL TREATMENT

Conservative treatment is alleged to avoid surgical complications and to reduce the costs. Authors advocating conservative management (49, 66, 84) claim that the results of cast immobilization are comparable to those of operative intervention, but the period of morbidity is shorter, the complaints are fewer and no hospital stay is needed. The background to support a change in the attitude towards nonoperative treatment is to be found in the experimental work in rats by Lipscomb and Wakim (54). After excising the Achilles tendon from the musculo-tendinous junction to its insertion in rats, they found complete regeneration of the tendon after a few weeks. Stein and Luekens (84) have shown that the paratenon generally remains intact when the Achilles tendon ruptures, and they suggested that operative repair of a ruptured Achilles tendon should be avoided,

as the paratenon provides a valuable blood supply to the damaged tendon.

Nonsurgical treatment of Achilles tendon rupture consists of cast immobilization. Various types of cast immobilization have been used. Some authors have recommended long-leg immobilization; others have recommended short-leg immobilization with the degree of plantar flexion of the ankle established by gravity, while still others have recommended short-leg immobilization in maximal ankle plantar flexion. Some have recommended functional bracing alone. There is no agreement in the literature on the optimal method of nonoperative management. Usually, a below-knee cast with the foot in gravity plantar flexion is worn for four weeks without weight-bearing. This is followed by a below-knee cast with reduced equinus angulation of the foot to permit full weight-bearing for another four weeks. When the second cast is removed, a 2.5-cm heel-lift is added to the shoe and used for four weeks or until the patient can dorsiflex the ankle about 10°. The mean time in cast for patients treated nonoperatively is 8.3 weeks (range: 5 to 12 weeks).

One of the major objections to nonsurgical treatment has been the high incidence of re-rupture. Most authors reported an incidence between 10 and 30% (table I). Furthermore, con-

servative treatment requires a longer immobilization time, which leads to muscle atrophy. Following cast immobilization, even with aggressive rehabilitation, patients never return to their maximal level of function (83). For example, most authors have recommended an 8-week period of cast immobilization; this will result in a 10% to 15% strength and power deficit (31, 66).

It is impossible to anatomically restore the correct length of Achilles tendon with nonoperative treatment. When selecting nonoperative care, ultrasonic examination of the tendon is helpful to determine the gap between the tendon ends and to assess the mobility of the tendon ends in plantar flexion. The gap invariably bridges with scar fibrosis, with a risk of tendon lengthening as the gap increases in length. This will result in elongation of the muscle-tendon unit during the healing process, resulting in weakness of push-off strength and reduced power of the musculotendinous unit of the calf. If nonoperative treatment is used, it should be done judiciously and rarely in competitive athletes. Ultrasonography can be used to confirm tendon apposition with 20° or less of plantar flexion of the ankle, and if a gap persists with 20° of plantar flexion, operative treatment is indicated. Recently, Sekiya *et al.* (80) suggested that the nonoperative treatment of Achilles tendon ruptures requires immobilization in maximal ankle plantar flexion and that immobilization of the knee may not be necessary to achieve tendon-edge apposition.

Table I. — Complications after nonsurgical treatment of ruptures of the Achilles tendon

Complications	Number of patients (Total : 569)	%
Major		
Rerupture	76	13.3
Deep vein thrombosis	7	1.2
Pulmonary embolism	1	0.2
Extreme lengthening	15	2.7
Second rerupture	3	0.5
Persisting equinus	1	0.2
Total	103	18.1
Minor		
	0	0
Total	0	0
Overall total	103	18.1

Data collected from the literature (17, 26, 34, 49, 50, 53, 66, 90).

## SURGICAL TREATMENT

The advantage of surgical treatment of Achilles tendon rupture lies in the possibility of exerting early tension on the tendon, which will ensure appropriate orientation of collagen fibers and improve the strength of the calf muscle. Mc Graw (in 23) found that the peak levels of collagen phagocytosis by fibroblasts during scar maturation coincide with enhanced fiber bundle reorientation and thus stronger, stiffer tendon healing.

The literature is replete with various techniques with which to repair the ruptured Achilles tendon.

These include :

- repair without augmentation (simple suture, cross-stitch suture, percutaneous suture, pullout wire, three-bundle suture, external fixation) ;
- repair with augmentation (gastrocnemius flap, plantaris tendon, fascial reinforcement, carbon fiber or Marlex mesh, Dacron or polylactate graft).

The surgical procedure can be done under local, spinal, epidural or general anesthesia.

Most surgeons recommend 6 weeks of immobilization in a short-leg cast followed by various rehabilitation means. It appears that very few surgeons use a long above-knee cast to immobilize the knee in flexion and thus decrease tension on the rupture by the gastrocnemius, as was classically advocated. The period with no or partial weight-bearing varies widely when comparing studies in the literature.

Optimal operative outcome demands good operative technique, respect for contraindications and appropriate patient selection. In the series of Kuwada (44, 45), one important factor for outcome prediction was the surgeon. This was not confirmed in the studies of Leppilahti and Orava (50).

Surgical treatment has a low rerupture rate and provides good recovery of calf muscle strength.

The major problem of surgical treatment has been a high rate of complications. In the review of the literature, the complication rate for surgical treatment was 561 out of 4477 or 12.5% (table II). Most are minor wound complications, which delay recovery but do not influence the final outcome. Major complications are rare, but usually serious, debilitating and often difficult to treat with minor procedures. Complications of open surgical treatment have become less frequent as advances have been made in surgical repair technique and knowledge of neurovascular anatomy. It has been shown that the incidence of sinus and adhesion formation can be decreased by using absorbable suture material and by using either the plantaris tendon or fascial reinforcement to enhance the repair.

Levy *et al.* (51) in 1983 adopted new approaches in the surgical treatment of Achilles tendon rup-

tures. They stated that the ideal tendon repair should be sufficiently strong to obviate immobilization and permit immediate functional rehabilitation. The tendon suture was augmented with different artificial materials (carbon fiber, Dacron vascular graft and Marlex mesh) to enhance healing and to avoid elongation of rerupture of the tendon repaired. Amis *et al.* (in 50) studied the biological behavior of carbon fiber and reported a significant foreign body response in the early stage of collagen scaffolding and a steady decrease in the collagen network, producing large, edematous areas within the neotendon at 6 months (50). They believe that this reaction was a response to the brittle carbon fiber debris.

The disadvantages of these repairs are that they are bulky and cordlike (when applied to the tendon). Consequently, problems with wound healing can occur, or the cord may be perceptible beneath the skin. However, there is no evidence that primary augmentation of a repair of an acute

Table II. — Complications after surgical treatment of ruptures of the Achilles tendon

Complications	Number of patients (Total : 4477)	%
<b>Major</b>		
Rerupture	69	1.5
Deep infection	51	1.1
Skin necrosis	26	0.6
Chronic fistula	7	0.15
Deep vein thrombosis	7	0.15
Pulmonary embolism	2	0.04
Death	2	0.04
<b>Total</b>	<b>164</b>	<b>3.6</b>
<b>Minor</b>		
Adhesion of the scar	118	2.6
Delayed wound healing	100	2.2
Disturbance of sensibility	84	1.8
Superficial infection	54	1.2
Suture granuloma	22	0.5
Temporary fistula	19	0.4
<b>Total</b>	<b>397</b>	<b>8.86</b>
<b>Overall total</b>	<b>561</b>	<b>12.5</b>

Data collected from the literature (8, 11, 17, 18, 26, 31, 34, 41, 50, 60, 66, 90, 91)

rupture of the Achilles tendon is any better than nonaugmented end-to-end repair.

An investigational tendon repair device made of a polymer of lactic acid (PLA) is currently undergoing clinical trials for use in repairing AT rupture (33). Acute ruptures have been treated successfully with simple end-to-end suture when the repair was not delayed.

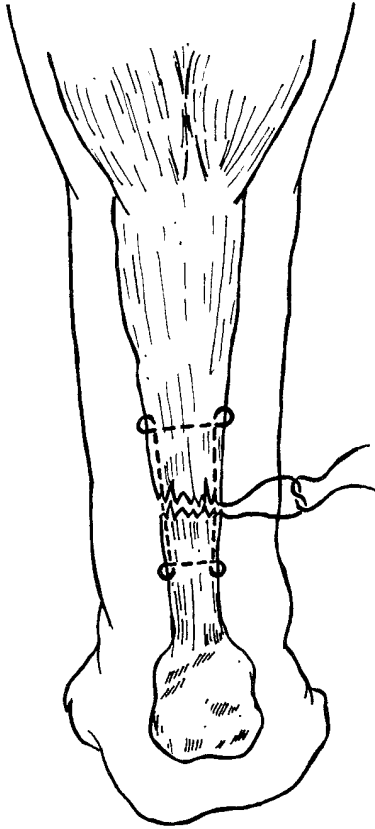
Percutaneous techniques (11, 20, 56) have been used recently to minimize the typical complications associated with open operative methods and non-operative treatment. Ma and Griffith (56) developed a method for percutaneous repair of Achilles tendon rupture. The technique involves producing six small stab incisions along the medial and lateral borders of the tendon and then passing a suture through the tendon by way of these incisions. The results are reported to be satisfactory, but many of the authors using percutaneous suture techniques consider sural nerve irritation to be one of the major risks. Rerupture is another much dreaded complication. The overall rate of rerupture reported in the literature was 6.4% (90). Recently, Webb and Bannister described a new technique that minimizes the risk of injury to the sural nerve. The repair is carried out using three midline stab incisions over the posterior aspect of the tendon. A n° 1 nylon suture on a 90-mm cutting needle approximates the tendon with two box stitches. In their series of 27 patients who had a percutaneous repair at 35 months median interval after operation, there were no injuries to the sural nerve or late reruptures. Delponte *et al.* (19) using a percutaneous technique with Dacron yarn with a 5-mm wide hook set on a n° 12 long flexible needle reported globally good results in 28 patients. There was no injury to the sural nerve or rerupture; only three cases developed irritation from the subcutaneous knot. In a comparison of percutaneous and open surgical repairs, recovery of strength and motion was essentially the same, but the cosmetic results were better after percutaneous procedures whereas the rate of rerupture was higher. When comparing open with combined open and percutaneous techniques, the latter gave better relief from symptoms, a higher rate of return to sports, better cosmetic results and no reruptures (38).

To conclude, there is no single, uniformly accepted surgical technique. If open surgical treatment is chosen, the repair should avoid classic wound complications and should be sufficiently strong to allow for early rehabilitation. Among the various techniques of surgical repair, we believe that simple end-to-end suture or fascial reinforcement can provide good clinical and functional results. We consider it of prime importance to suture the paratenon (4-0 absorbable suture) to retain the vascular supply to the Achilles tendon and to avoid adherence to the skin due to scarring. Among different methods of suture repair, the technique described by Kessler or by Kirschmayer (figs. 1, 2) can provide strong and durable tendon repair while allowing for an early rehabilitation protocol. We think that the use of absorbable suture for repair can provide mechanically strong repair and may also reduce the risk of complications due to implantation of foreign material in the tendon. The flap augmentation Achilles tendon repair technique, a modified version of Lindholm's technique (23), may be a useful adjunct to conventional suture repair (fig. 3). Minimizing casting time after surgical repair seems to be a valuable solution allowing for an early weight-bearing rehabilitation protocol.

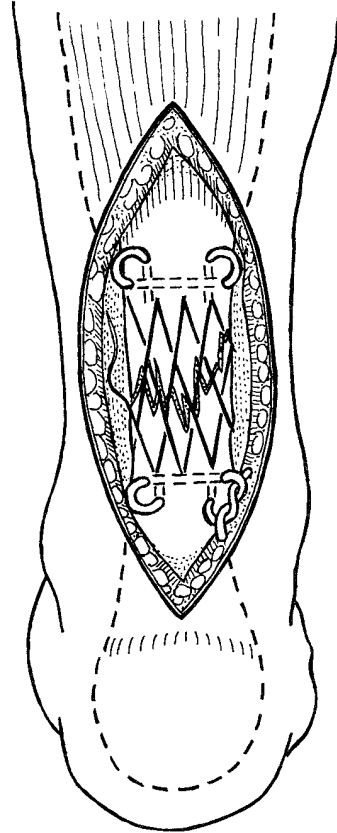
#### FUNCTIONAL POSTOPERATIVE TREATMENT

Until recently, the usual postoperative regimen of surgically treated Achilles tendon rupture included cast immobilization (6 to 8 weeks) in equinus position. The complications after prolonged immobilization are well documented: arthrofibrosis, calf atrophy, adhesions and deep venous thrombosis.

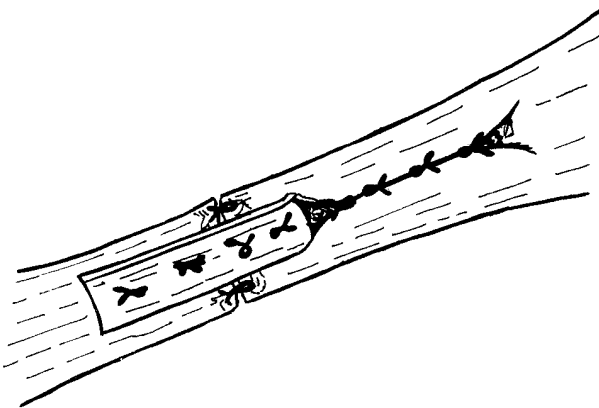
Some authors now use an aggressive postoperative regimen comprising early mobilization coupled with immediate full weight-bearing. There seems to be since the early 1990's a new wave of enthusiasm for operative repair and functional postoperative treatment. Based on recent studies, early mobilization seems to enhance the healing process in the Achilles tendon. The work by Gelberman *et al.* (22) with flexor tendons showed that with early mobilization there is an increased



**Fig. 1.** — The Kessler suture-repair technique is demonstrated. Approximation of both ends of the ruptured tendon was performed using a stitch through each stump 2.5 cm from the rupture.



**Fig. 2.** — The Kirschmayer core suture with n° 2 Tevdek and cross-stitch epitenon suture with 2-0 Maxon placed inside the tendon grasps of the Kirschmayer core suture.



**Fig. 3.** — A flap-augmentation technique. After a conventional primary repair was performed, a central tongue of tendon was isolated proximally, such that on bending it back at its base it would cross the rupture site and overlap the distal stump approximately 2 to 3 cm distal to the rupture site.

organization of the collagen at the repair site that leads to increased strength. If the tendon undergoes tension during healing, orientation of collagen fibers and strength of the calf muscles are improved, as are tendon vascularity and breaking strength. The concept of a functional postoperative treatment is by no means new. In 1974, Marti *et al.* (60) advocated a protocol allowing full weight-bearing after surgical repair of the Achilles tendon. In 1987, Zwipp *et al.* (92) developed a special shoe for functional treatment, and Carter *et al.* (15) prescribed a removable anterior plastazote brace in neutral position of the ankle. They allowed limited weight-bearing as tolerated, with early ankle mobilization, and did not observe any increase in the rerupture rate. Several recent studies report encouraging results of immediate free ankle motion after surgical repair of acute



Achilles tendon ruptures (12, 15). In small series of compliant, well-motivated patients, functional postoperative treatment has been reported to be well tolerated, safe and effective. Recently, some authors managed patients with Achilles tendon rupture with a functional bracing protocol; they achieved good functional results, proving that, for selected patients, nonoperative functional bracing may be a viable alternative to operative intervention (15).

## DISCUSSION

The literature contains over 450 studies dealing with Achilles tendon ruptures, and there is no consensus on how to manage these common injuries. There have been many persuasive arguments raised on both sides of the long-standing controversy regarding nonsurgical versus surgical treatment. Several authors (8, 13, 17, 24, 26, 66, 86) have compared the various operative and nonoperative treatments of acute Achilles tendon rupture (table III). Jacobs (34) in 1978 showed significant benefits from operative repair. Nistor (66) in 1981 noted no significant difference between the results of operative and nonoperative treatment options, and in fact he stated that patients may benefit from earlier return to work after choosing the nonoperative option. Beskin *et al.* (8) in 1987 showed that the surgically treated

patients had increased strength and a decreased rerupture rate. In a randomized prospective study, Cetti *et al.* (17) concluded that operative treatment of a ruptured Achilles tendon is preferable, but nonoperative treatment is an acceptable alternative.

To use statistical procedures on many different reports with different treatments is very difficult and perhaps impossible. There are many biases, known and unknown, that are impossible to take into account in the statistics used. Statistical analysis only shows that the differences in the results are significant (in favor of the operative treatment), but the grounds for the results are not taken into consideration. The lack of a universal consistent scoring protocol for the subjective evaluation of Achilles tendon rupture makes direct comparison of results in the different articles extremely difficult. The results have often been assessed according to the criteria of Arner and Lindholm (4) or Percy and Conchie (72). Therefore, we should be aware that the differences between results in the literature review are unreliable.

From the literature review of operative treatment (4,477 patients), the rerupture rate was 1.5% as compared with the nonoperative casting group (569 patients), where the rerupture rate was 13.3%. It is clearly demonstrated that the chances of rerupture are considerably decreased after operative intervention.

Table III. — Comparison between the results of conservative and surgical treatment of Achilles tendon ruptures (values are reported as conservative/surgical)

Study	Year	No. of patients	Mean follow-up (months)	No. of reruptures	No. of other major complications	No. of minor complications	Plantar flexion strength (% of uninjured side)	Group with better results
Gillies & Chalmers	1970	7/6		1/0	0/1	0/0	80/85	Conservative
Inglis <i>et al.</i>	1976	23/44	> 12	9/0	0/2	0/0	73/101	Surgical
Jacobs <i>et al.</i>	1978	32/26		7/0	1/2	0/3	65/75	Surgical
Nistor	1981	60/45	30/30	5/2	0/2	0/29	86/88	Equal
Häggmark <i>et al.</i>	1986	8/15				98/97	71/90 <sup>a</sup>	Surgical
Carden <i>et al.</i>	1987							
early		37/36	64/48	0/0	3.9/16.6 (%)	3.9/22.2 (%)	92/91	Equal
late		14/17		1/0	18.8/26.9 (%)	6.2/26.9 (%)	80/91	Surgical
Cetti <i>et al.</i>	1993	56/55	12/12	7/3	2/2	3/15		Surgical
Thermann <i>et al.</i>	1995	22/28	12/12	0/0	1/1	0/3	95/94	Equal

One important aspect of the successful management of Achilles tendon rupture is the patient's ability to return to his preinjury status. From the literature review, 83% of patients treated surgically and 69% of patients treated by cast immobilization achieved this objective.

Despite difficulties comparing the frequency of resumption of sports activities after rupture of the Achilles tendon in different reports, there was a tendency toward a higher rate of return to sports activities at the same level after operative treatment. In the literature, 62% to 82% of the patients treated operatively and 52% of the patients treated nonoperatively resumed sports activities at the same level.

In the article that used an objective measuring system (Cybex II), strength and power testing have shown increased strength in the operative group, compared with the nonoperative group of patients. The mean plantar flexion strength after operative treatment was 87.3% as compared with the contralateral side, versus 78% after nonsurgical treatment. This is probably related to the ability through reconstruction of the tendon to maintain the appropriate musculotendinous tension and to prevent significant atrophy, as well as to obtain the appropriate length of the tendon at the time of repair.

From the literature review (17), it appears that surgical treatment results in higher cost for the patient because the mean hospitalization time was 6.4 days, whereas that for the nonoperatively treated patient was 0.2 days. Likewise, the mean sick leave time was 10.5 weeks for surgically treated patients, versus 8.2 weeks for nonsurgically treated patient (17).

When comparing costs, the higher frequency of rerupture in patients nonoperatively treated must also be considered, since patients treated nonsurgically who experienced rerupture took more than 6 months to return to active work. In recent years, most surgical treatments for Achilles tendon rupture were performed on an outpatient basis, resulting in a reduction in cost of surgical treatment.

It is important to recognize that the major drawback of surgical treatment in the literature

was the high rate of complications. An overall incidence of 20% was reported.

In our review of 5,046 cases of surgical and nonsurgical treatment of Achilles tendon ruptures reported in the literature, the incidence of complications was 12.5% and 18.1% respectively.

Most surgical complications are minor wound complications (8.8%) that delay recovery but do not influence the final outcome. The complications of conservative treatment include mostly rerupture (13.3%) and residual lengthening (2.7%) of the tendon, resulting in significant calf muscle weakness.

A review of published reports on postoperative treatment shows that recommendations for casting time and time to full weight-bearing are still unclear: they range from partial weight-bearing during the entire casting period to immediate free ankle motion with full weight-bearing as tolerated. No randomized studies comparing simple suture technique and repair with augmentation are available in the literature.

Clearly, satisfactory outcomes may be obtained with either nonoperative or operative treatment of acute tendon ruptures. Surgically treated patients show a slight advantage in isokinetic strength and return to preinjury activity levels compared with nonoperative treatment.

## CONCLUSION

The incidence of Achilles tendon rupture reported in the literature seems to have increased in recent years. This was caused by a combination of more awareness in the medical field as well as greater participation by the general population in recreational sports activities in developed countries. The exact causes of Achilles tendon ruptures are still unclear. The diagnosis of Achilles tendon rupture is based on the history and physical findings. Ultrasonography is the imaging method of choice, when necessary. Surgical repair of the ruptured Achilles tendon is preferable; it is the method of choice in younger very demanding individuals. Nonoperative treatment is an acceptable alternative and is the treatment of choice in older and less demanding individuals. Functional

postoperative treatment has been reported recently to be well tolerated, safe and effective in well-motivated patients.

## REFERENCES

1. Abrahamsen K. Ruptura tendinis Achillis. *Ugeskr. Laeger.*, 1923, 85, 279-285.
2. Achilles tendon rupture (editorial) *Lancet*, 1973, I, 189-190.
3. Aldam C. Repair of calcaneal tendon ruptures: A safe technique. *J. Bone Joint Surg.*, 1989, 71-B, 486-488.
4. Arner O., Lindholm Å. Subcutaneous rupture of the Achilles tendon. *Acta Chir. Scand.*, 1959, Suppl. 239, 1-51.
5. Arner O., Lindholm Å., Lindvall N. Roentgen changes in subcutaneous rupture of the Achilles tendon. *Acta Chir. Scand.*, 1958/59, 116, 496-500.
6. Arner O., Lindholm Å., Orell S. R. Histologic changes in subcutaneous rupture of the Achilles tendon. *Acta Chir. Scand.*, 1958/59, 116, 484-490.
7. Barfred T. Achilles tendon rupture: Aetiology and pathogenesis of subcutaneous rupture assessed on the basis of literature and rupture experiments on rats. *Acta Orthop. Scand.*, 1973, Suppl. 152, 1-124.
8. Beskin J. L., Sanders R. A., Hunter S. C., *et al.* Surgical repair of Achilles tendon ruptures. *Am. J. Sports Med.*, 1987, 15, 1-8.
9. Bosworth D. M. Repair of defects in the tendo Achillis. *J. Bone Joint Surg.*, 1956, 38-A, 111-114.
10. Boyden E. M., Kitaoka H. B., Cahalan T. D., *et al.* Late versus early repair of Achilles tendon rupture: clinical and biomechanical evaluation. *Clin. Orthop.*, 1995, 317, 150-158.
11. Bradlay J. P., Tibone J. E. Percutaneous and open surgical repairs of Achilles tendon ruptures. *Am. J. Sports Med.*, 1990, 18, 188-195.
12. Buchgraber A., Passler H. H. Percutaneous repair of Achilles tendon rupture. *Clin. Orthop.*, 1997, 341, 113-122.
13. Carden D. G., Jonathan N., Chalmers J., *et al.* Rupture of the calcaneal tendon: The early and late management. *J. Bone Joint Surg.*, 1987, 69-B, 416-420.
14. Carr A. J., Norris S. H. The blood supply of the calcaneal tendon. *J. Bone Joint Surg.*, 1989, 71-B, 100-101.
15. Carter T. R., Fowler P. J., Blokker C. Functional postoperative treatment of Achilles tendon repair. *Am. J. Sports Med.*, 1992, 20, 4, 459-462.
16. Cetti A., Andersen I. Roentgenographic diagnosis of ruptured Achilles tendons. *Clin. Orthop.*, 1993, 286, 215-221.
17. Cetti R., Christensen S. E., Ejsted R., *et al.* Operative versus non-operative treatment of Achilles tendon rupture. *Am. J. Sports Med.*, 1993, 21, 791-799.
18. Cetti R., Christensen S. E., Reuther K. Ruptured Achilles tendons treated surgically under local anaesthesia. *Acta Orthop. Scand.*, 1981, 52, 675-677.
19. Delpont P., Potier L., Poulpique P. Ruptures sous-cutanées du tendon d'Achille par ténoraphie percutanée. *Rev. Chir. Orthop.*, 1993, 78, 404-407.
20. Fitzgibbons R. E., Hefferon J., Hill J. Percutaneous Achilles tendon repair. *Am. J. Sports Med.*, 1993, 21, 724-727.
21. Fox J. M., Blazina M. E., Jobe F. W., *et al.* Degeneration and rupture of the Achilles tendon. *Clin. Orthop.*, 1975, 107, 221-224.
22. Gelberman R. H., Manske P. R., Van de Berg J. S., *et al.* Flexor tendon repair in vitro: A comparative histologic study of the rabbit, chicken, dog and monkey. *J. Orthop. Res.*, 1984, 2, 39-48.
23. Gerdes M. H., Brown T. D., Bell A. L., *et al.* A flap augmentation technique for Achilles tendon repair. *Clin. Orthop.*, 1992, 280, 241-246.
24. Gillies H., Chalmers J. The management of fresh rupture of tendo Achillis. *J. Bone Joint Surg.*, 1970, 52-A, 337-343.
25. Goldman S., Linscheid R. L., Bickel W. H. Disruptions of tendo Achillis: Analysis of 33 cases. *Mayo Clin. Proc.*, 1969, 44, 25-35.
26. Häggmark T., Liedberg H., Eriksson E., *et al.* Calf muscle atrophy and muscle function after non-operative versus operative treatment of Achilles tendon ruptures. *Orthopaedics*, 1986, 9, Suppl. 2, 160-164.
27. Hattrup S. J., Johnson K. A. A review of ruptures of the Achilles tendon. *Foot Ankle*, 1985, 6, 34-38.
28. Holz U., Asherl J. Die Achillessehnenruptur: Eine klinische Analyse von 560 Verletzungen. *Chir. Praxis*, 1981, 28, 511-526.
29. Howard C. B., Winston I., Bell W., *et al.* Late repair of the calcaneal tendon with carbon fibre. *J. Bone Joint Surg.*, 1984, 66-B, 206-208.
30. Inglis A. E., Scott W. N., Sculco T. P., *et al.* Ruptures of the tendo Achillis. *J. Bone Joint Surg.*, 1976, 58-A, 990-993.
31. Inglis A. E., Sculco T. P. Surgical repair of ruptures of the tendo Achillis. *Clin. Orthop.*, 1981, 156, 160-169.
32. Ippolito E., Natali P. G., Postacchini F., *et al.* Morphological, immunochemical and biomechanical study of rabbit Achilles tendon at various ages. *J. Bone Joint Surg.*, 1980, 62-A, 583-598.
33. Liem M. D., Zegel H. G., Balduini F. C., *et al.* Repair of Achilles tendon ruptures with a polylactid acid implant: Assessment with MR imaging. *Am. J. Roentgenol.*, 1991, 156, 769-773.
34. Jacobs D., Martens M., Van Audekercke R., *et al.* Comparison of conservative and operative treatment of Achilles tendon rupture. *Am. J. Sports Med.*, 1978, 6, 107-111.
35. Jozsa L., Balint J. B., Kannus P., *et al.* Distribution of blood groups in patients with tendon rupture. *J. Bone Joint Surg.*, 1989, 71-B, 272-274.

36. Jozsa L., Kvist M., Balint B. J., *et al.* The role of recreational sport activity in Achilles tendon rupture : A clinical, pathoanatomical, and sociological study of 292 cases. *Am. J. Sports Med.*, 1989, 17, 338-343.
37. Kager H. Zur Klinik und Diagnostik des Achillessehnenrisses. *Chirurgie*, 1939, 11, 691-695.
38. Kakiuchi M. A combined open and percutaneous technique for repair of tendo Achillis : Comparison with open repair. *J. Bone Joint Surg.*, 1995, 77-B, 60-63.
39. Kannus P., Jozsa L. Histopathological changes preceding spontaneous rupture of a tendon. *J. Bone Joint Surg.*, 1991, 73-A, 1507-1525.
40. Karjalainen P. T., Ahovuo J., Pihlajamäki H. K., *et al.* Postoperative MR imaging and ultrasonography of surgically repaired Achilles tendon ruptures. *Acta Radiol.*, 1996, 37, 639-646.
41. Kellam J. F., Hunter G. A., McElwain J. P. Review of the operative treatment of Achilles tendon rupture. *Clin. Orthop.*, 1985, 201, 80-83.
42. Keller J., Bak B. The use of anesthesia for surgical treatment of Achilles tendon rupture. *Orthopedics*, 1989, 12, 431-433.
43. Kleinman M., Gross A. E. Achilles tendon rupture following steroid injection. *J. Bone Joint Surg.*, 1983, 65-A, 1345-1347.
44. Kuwada G. T. Critical analysis of tendo Achillis repair using Achilles tendon rupture classification system and repair. *J. Foot Surg.*, 1993, 32, 611-616.
45. Kuwada G. T. Diagnosis and treatment of Achilles tendon rupture. *Trauma*, 1995, 12, 633-652.
46. Kvist M. Achilles tendon injuries in athletes : A review. *Sports Med.*, 1994, 18, 173-201.
47. Kvist M., Jozsa L., Järvinen M. Vascular changes in the ruptured Achilles tendon and paratenon. *Int. Orthop.*, 1992, 16, 377-382.
48. Langergren C., Lindholm Å. Vascular distribution in the Achilles tendon. *Acta Chir. Scand.*, 1958, 116, 491-495.
49. Lea R. B., Smith L. Non-surgical treatment of tendo Achillis rupture. *J. Bone Joint Surg.*, 1972, 54-A, 1398-1407.
50. Leppilahti J., Orava S. Total Achilles tendon rupture : A review. *Sports Med.*, 1998, 25, 79-100.
51. Levy M., Velkens S., Goldstein J., *et al.* A method of repair for Achilles tendon ruptures without cast immobilization. *Clin. Orthop.*, 1983, 187, 199-204.
52. Lieberman J. R., Lozman J., Czajka J., *et al.* Repair of Achilles tendon ruptures with Dacron vascular graft. *Clin. Orthop.*, 1987, 234, 204-208.
53. Lildholt T., Munch-Jørgensen T. Conservative treatment of Achilles tendon rupture. *Acta Orthop. Scand.*, 1976, 47, 454-458.
54. Lipscomb P. R., Wakim K. G. Regeneration of severed tendons : An experimental study. *Proc. Staff Meet. Mayo Clin.*, 1961, 36, 271-276.
55. Lynn T. A. Repair of the torn Achilles tendon, using the Plantaris tendon as a reinforcing membrane. *J. Bone Joint Surg.*, 1966, 48-A, 268-272.
56. Ma G. W., Griffith T. G. Percutaneous repair of acute closed ruptured Achilles tendon : A new technique. *Clin. Orthop.*, 1977, 128, 247-255.
57. Maffulli N., Dymond N. P., Regine R. Surgical repair of ruptured Achilles tendon in sportsmen and sedentary patients : A longitudinal ultrasound assessment. *Int. J. Sports Med.*, 1990, 11, 78-84.
58. Mahler F., Fritschy D. Partial and complete ruptures of the Achilles tendon and local corticosteroid injections. *Br. J. Sports Med.*, 1992, 26, 7-14.
59. Mandelbaum B. R., Myerson M. S., Forster R. Achilles tendon ruptures. A new method of repair, early range of motion, and functional rehabilitation. *Am. J. Sports Med.*, 1995, 23, 392-395.
60. Marti R. K., Van der Werken C., Shütte P. R., *et al.* Operative repair of ruptured Achilles tendon and functional after treatment. *Nether. J. Surg.*, 1983, 35, 61-65.
61. Michna H., Hartmann G. Adaptation of tendon collagen to exercise. *Int. Orthop.*, 1989, 13, 161-165.
62. Möller A., Åström M., Westlin N. E. Increasing incidence of Achilles tendon rupture. *Acta Orthop. Scand.*, 1996, 67, 479-481.
63. Mortensen N. H. M., Sæther J., Steinke M. S., *et al.* Separation of tendon ends after Achilles tendon repair : A prospective, randomized, multicenter study. *Orthopedics*, 1992, 15, 899-903.
64. Nellas Z. J., Loder B. G., Wertheimer S. J. Reconstruction of an Achilles tendon defect utilizing an Achilles tendon allograft. *J. Foot Ankle Surg.*, 1996, 35, 144-148.
65. Nillius S. A., Nilsson B. E., Westlin N. E. The incidence of Achilles tendon rupture. *Acta Orthop. Scand.*, 1976, 47, 118-121.
66. Nistor L. Surgical and non-surgical treatment of Achilles tendon rupture. *J. Bone Joint Surg.*, 1981, 63-A, 394-399.
67. Nyström B., Holmlund D. Separation of tendon ends after suture of Achilles tendon. *Acta Orthop. Scand.*, 1983, 54, 620-621.
68. O'Brien T. The needle test for complete rupture of the Achilles tendon. *J. Bone Joint Surg.*, 1984, 66-A, 1099-1101.
69. O'Reilly M. A. R., Massouh H. Pictorial review : The sonographic diagnosis of pathology in the Achilles tendon. *Clin. Radiol.*, 1993, 48, 202-206.
70. Panageas E., Greenberg S., Franklin P. D., *et al.* Magnetic resonance imaging of pathologic conditions of the Achilles tendon. *Orthop. Rev.*, 1990, 19, 975-980.
71. Paré A. *Les œuvres*. 9th ed. Lyon. Claude Rigaud et Claude Obert, 1633.
72. Percy E. C., Conochie L. B. The surgical treatment of ruptured tendo Achillis. *Am. J. Sports Med.*, 1978, 6, 132-136.
73. Quénu J., Stoianovitch S. M. Les ruptures du tendon d'Achille. *Rev. Chir. Paris*, 1929, 67, 647-678.
74. Quigley T. B., Scheller A. D. Surgical repair of the ruptured Achilles tendon. *Am. J. Sports Med.*, 1980, 8, 244-250.

75. Rantanen J., Hurme T., Paananen M. Immobilization in neutral versus equinus position after Achilles tendon repair. *Acta Orthop. Scand.*, 1993, 64, 333-335.
76. Rothenbühler J. M., Korkodelovic B., Regazzoni P. Die operative Behandlung der Achillessehnenruptur. *Z. Unfallchir. Versicherungsmed.*, 1991, 84, 25-33.
77. Rupp S., Tempelhof S., Fritsch E. Ultrasound of the Achilles tendon after surgical repair : Morphology and function. *Br. J. Radiol.*, 1995, 68, 454-458.
78. Schmidt R. B., Graf J., Schneider V., *et al.* The blood supply of the Achilles tendon. *Int. Orthop.*, 1992, 16, 29-31.
79. Scott W. N., Inglis A. E., Sculco T. P. Surgical treatment of reruptures of the tendo Achillis following nonsurgical treatment. *Clin. Orthop.*, 1979, 140, 175-177.
80. Sekiya J. K., Evensen K. E., Jebson P. J. L., *et al.* The effect of knee and ankle position on displacement of Achilles tendon ruptures in a cadaveric model. *Am. J. Sports Med.*, 1999, 27, 632-636.
81. Soldatis J. J., Goodfellow D. B., Wilber J. H. End-to-end operative repair of Achilles tendon rupture. *Am. J. Sports Med.*, 1997, 25, 90-95.
82. Sölveborn S. A., Moberg A. Immediate free ankle motion after surgical repair of acute Achilles tendon ruptures. *Am. J. Sports Med.*, 1994, 22, 607-610.
83. Soma C. A., Mandelbaum B. R. Repair of acute Achilles tendon ruptures. *Orthop. Clin. North Am.*, 1995, 26, 239-247.
84. Stein S. R., Luekens C. A. Closed treatment of Achilles tendon ruptures. *Orthop. Clin. North Am.*, 1976, 7, 241-246.
85. Sun Y. S., Yen T. F., Chie L. H. Ruptured Achilles tendon, Report of 40 cases. *Zhonghua Yixue Zazhi*, 1977, 57, 94-98.
86. Thermann H., Zwipp H., Tscherne H. Funktionelles Behandlungskonzept der frischen Achillessehnenruptur : zwei Jahresergebnisse einer prospektiv-randomisierten Studie. *Unfallchirurg.*, 1995, 98, 21-32.
87. Thompson T. C., Doherty J. H. Spontaneous rupture of tendon of Achilles : A new clinical diagnostic test. *J. Trauma*, 1962, 2, 126-129.
88. Toygar O. Subkutane Ruptur der Achillessehne. *Helv. Chir. Acta*, 1947, 14, 209-231.
89. Troop R. L., Losse G. M., Lane J. G., *et al.* Early motion after repair of Achilles tendon ruptures. *Foot Ankle Int.*, 1995, 16, 705-709.
90. Webb J. M., Bannister G. C. Percutaneous repair of the ruptured tendon Achillis. *J. Bone Joint Surg.*, 1999, 81-B, 877-880.
91. Wills C. A., Wasburn S., Caiozzo V., *et al.* Achilles tendon rupture : A review of the literature comparing surgical versus non-surgical treatment. *Clin. Orthop.*, 1986, 207, 156-163.
92. Zwipp H., Sudkamp N., Thermann H., Somek N. Rupture of the Achilles tendon. Results of 10 years' follow-up after surgical treatment. A retrospective study. *Unfallchir.*, 1989, 92, 554-559.

## SAMENVATTING

*N. POPOVIC, R. LEMAIRE. Diagnose en behandeling van akute Achillespeesrupturen.*

Het lijkt dat subcutane Achillespeesrupturen de laatste jaren frequenter voorkomen. Dit is uit te leggen door een verhoogde aandacht voor deze pathologie door de artsen en door een toename van de sportactiviteiten. De oorzaken zijn multiple en nog in discussie. De diagnose is klinisch ; andere technische onderzoeken zijn zelden noodzakelijk. Er bestaat een omvangrijke literatuur, maar de vergelijking van de resultaten is moeilijk door het ontbreken van subjectieve en objectieve beoordelingscriteria.

Bij nazicht van de literatuur lijkt de conservatieve behandeling aanvaardbare resultaten op te leveren, maar de operatieve geeft betere functionele resultaten. De chirurgie geeft ook minder recidief rupturen en herstelt beter de kracht en functie. Echter zijn er ook meer complicaties. Bij jonge, actieve en veeleisende patiënten verdient een heilkundige behandeling de voorkeur en wordt de conservatieve behandeling voorbehouden voor sedentaire en oudere patiënten.

Er bestaat geen unanimitieit voor de techniek. Voor de akute ruptuur is een eind-aan-eind suture meestal voldoende. Percutane technieken werden ontwikkeld om de complicaties te beperken ; de resultaten zijn veelbelovend doch niet altijd zonder falen. Recent werd ook de aandacht getrokken op een vroegtijdige mobilisatie postoperatorioir. Dit beïnvloedt zeer gunstig de resultaten.

## RÉSUMÉ

*N. POPOVIC, R. LEMAIRE. Diagnostic et traitement des ruptures fraîches du tendon d'Achille.*

La rupture sous-cutanée du tendon d'Achille semble être devenue plus fréquente depuis quelques années. Ceci peut s'expliquer par le fait que les médecins sont plus attentifs à ce diagnostic et aussi par l'augmentation des activités sportives de la population.

Les causes de la rupture du tendon d'Achille sont multiples et encore discutées. Le diagnostic peut être posé sur base de l'examen clinique ; des examens complémentaires sont rarement nécessaires.

Une littérature abondante a été consacré aux ruptures du tendon d'Achille et à leur traitement au cours de la dernière décennie, mais la comparaison des résultats rapportés est rendue difficile par l'absence d'un protocole d'évaluation subjective et objective des résultats.

Le choix thérapeutique reste controversé. Il ressort d'une revue de la littérature que l'on peut obtenir un résultat satisfaisant aussi bien avec un traitement conservateur qu'avec un traitement chirurgical, mais ce dernier semble restaurer une meilleure capacité fonctionnelle. Le traitement chirurgical donne moins de re-ruptures et restaure mieux la force et la capacité fonctionnelle ; en revanche, il donne davantage de complications mineures que le traitement conservateur. Sur base des résultats publiés, il apparaît que la réparation chirurgicale doit être envisagée chez des sujets jeunes, actifs, très exigeants, tandis que le traitement conservateur doit être réservé aux patients âgés ou sédentaires. Il n'existe pas de technique chirurgicale qui fasse l'unanimité pour la réparation du tendon d'Achille. Le

plus souvent, les ruptures fraîches ont été traitées avec succès par une simple suture bout à bout, mais des résultats satisfaisants ont aussi été obtenus en recourant à différentes techniques de renforcement combinées à la suture. Des techniques de réparation percutanée ont été proposées dans l'espoir de réduire les complications classiquement associées à la chirurgie ; les résultats semblent prometteurs, mais non sans échecs et complications. Plusieurs travaux récents ont montré l'intérêt sur le plan fonctionnel de la mobilisation post-opératoire précoce chez des patients motivés ; en effet, les résultats du traitement sont déterminés non seulement par la technique de réparation mais aussi et même avant tout par la revalidation fonctionnelle post-opératoire.