

CONGENITAL INSENSITIVITY TO PAIN WITH ANHIDROSIS REPORT OF A CASE AND REVIEW OF THE LITERATURE

S. D. THEODOROU¹, A. E. KLIMENTOPOULOU², E. PAPALOUKA³

In a previous paper published in this journal, we reported two cases of "Congenital Sensory Neuropathy with Anhidrosis" with reference to the orthopedic complications (Theodorou *et al.*, 1985). We now present a new typical case, under the currently used term: "Congenital Insensitivity to Pain with Anhidrosis" (CIPA) and a brief review of the literature on the incidence, etiology and problems arising in various systems. CIPA is an autosomal recessive form of sensory neuropathy manifesting with typical clinical features. Universal insensitivity to pain, anhidrosis or hypohidrosis, bouts of hyperpyrexia from very young age, self inflicted injuries, defective or absent lacrimation and mental retardation are specific diagnostic findings. Orthopedic, maxillofacial, dermatological and ophthalmologic complications are common. Counseling of the family and school personnel for the prevention of injuries is necessary. Early diagnosis is very important for the prevention and treatment of various complications. The etiology and pathogenesis of the condition is still unclear. The recent detection of a new gene, which encodes a receptor tyrosine kinase for nerve growth factor and lately of a specific point mutation associated with the gene inactivation¹¹, may open new ways for the study and management of this disabling condition.

Key words : insensitivity, neuropathy, anhidrosis, pain absence.

Mots-clés : insensibilité, neuropathie, anhidrose, absence de douleur.

INTRODUCTION

The term "Congenital Insensitivity to Pain with Anhidrosis" (CIPA) which is in current use was

introduced by Swanson (1963) in his classification of sensory neuropathies.

Previously, Gillespie and Perruca in 1960 described the case of a 3-year-old child with analgesia, hypohidrosis and mental retardation under the title "Congenital Insensitivity to Pain". Other terms that have also been used include "Familial Sensory Neuropathy with Anhidrosis" (33), "Congenital Sensory Neuropathy with Anhidrosis" (42) and "Type IV Congenital Sensory and Autonomic Neuropathy"(6). A new typical case with six years follow-up and a review of the literature on the genetics, pathophysiology and the problems arising, are presented.

CASE REPORT

The patient is the second of dizygotic male twins born by caesarian section with a birth weight of 2800 gr. The pregnancy was uneventful except for slight bleeding at the eighth week. His 42-year-old healthy mother and his 50-year-old diabetic father were unrelated. Soon after his birth his mother noticed that he was "different" from his twin brother. He seemed weaker and there were difficulties in feeding him. He presented bouts of high fever particularly in hot weather, without sweating. Because of the hyperpyrexias and food refusal, he had to be

¹ University of Athens, Greece.

² Department of Hygiene and Epidemiology, University of Athens, Greece.

³ Piraeus General Hospital, Greece.

Correspondence and reprints : S. D. Theodorou, 39, Jean Moreas St., Halandri 15231, Athens, Greece.

admitted to the children's hospital at the age of 8 weeks and was treated for bronchopneumonia with antibiotics. After eruption of teeth at the age of 7 months, he was noticed to bite his tongue, lips and fingertips causing bleeding. Later he kept losing his teeth either by biting or self-extraction. He walked at the age of 15 months and spoke words at 17 months. He continued presenting intermittent fevers and bouts of bronchitis (postinfectious asthma), which became less frequent with age. He was

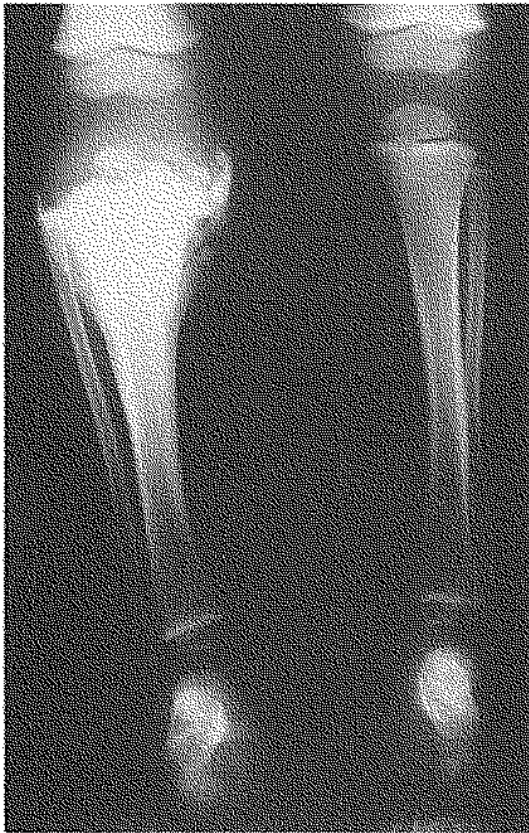

Fig. 1. — A. Bone density of the proximal part of the right tibia following fracture and neuropathic knee joint.

seen for the first time at the age of 4 years for swelling of the proximal end of the right tibia. Pressure over the swelling was painless as he was walking and running. His mother said he never protested when given injection or after falls. Pressure over tendons or muscles did not produce any pain nor to the pinprick in various areas of the body. His skin was unusually dry, hard and hirsute

and his mother said he never sweated, even in very hot weather or when running high temperatures. He was noted also to touch hot objects and receive burns without complaining. Nevertheless, superficial sensation to light touch was intact. There was some scarring on his lips and tongue, the tip of which was missing as a result of biting. For the same reason his fingertips showed scarring and absorption. Many of his teeth were missing. Bruises in several parts of his body were also noted. Corneal reflexes were absent and tear production was reduced. Tendon reflexes were hypoactive. He was hyperactive trying to compete with his healthy twin brother, but was cooperative. Routine laboratory tests were unremarkable. Radiographs of both tibias showed increased bone density of the metaphyseal-epiphyseal region of the proximal end of the right tibia, hyperplastic bone formation and disorganization. (fig. 1-A). An above knee plaster of Paris was applied which was soon destroyed and had to be replaced repeatedly. Radiographs 4 months later showed reorganization of the proximal end of the right tibia, but periosteal reaction and increased density was noted in the metaphyseal region of the upper end of the left tibia (fig. 1-B).

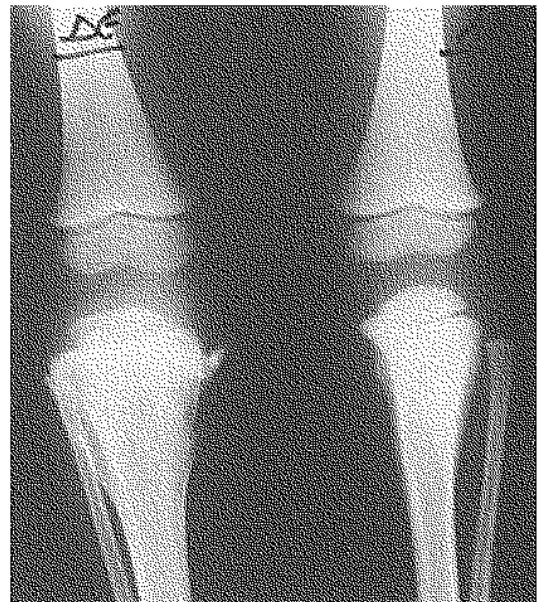

Fig. 1. — B. Good reconstruction after 4 months of immobilization in plaster. The proximal part of the contralateral tibia shows densification and periosteal reaction.

An above knee plaster of Paris was applied to the left leg, which was again repeatedly destroyed and replaced (fig. 1-C) and immobilization had to be continued for another three months until satisfactory reconstruction in both tibiae was demonstrated (fig 1-C). Ulcerations of the anterior surface of the knees and a perforating ulcer in the foot were treated with debridements, aseptic dressings and efforts to prevent external pressure on these areas by various means with great improvement.

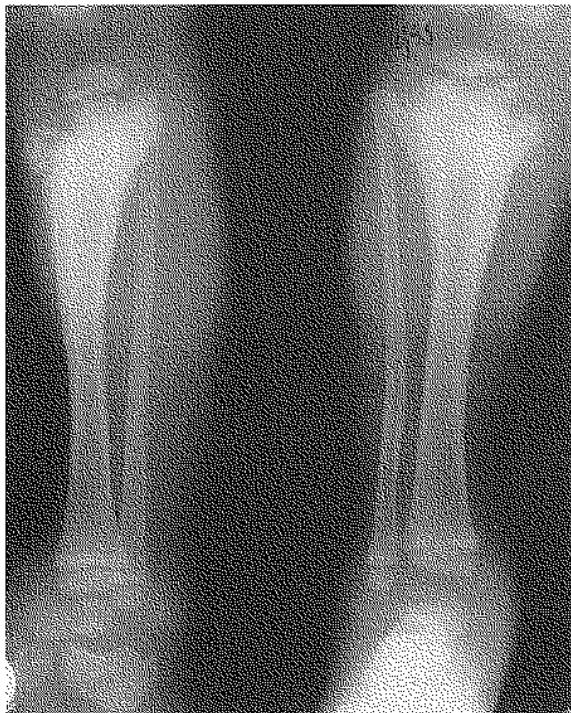

Fig. 1. — C. In spite of immobilization in plaster for three months, bone remodeling of the proximal end of the left tibia was not satisfactory.

A few months later he sustained a fracture of the lateral condyle of the left elbow with gross displacement. It was treated with open reduction and fixation with Kirschner wires. The plaster was destroyed and the wound became infected. At operation abundant purulent material was found and a large fragment of the lateral condyle was removed. *Staphylococcus Aureus* was isolated and the infection resolved after administration of antibiotics. An open wound in the posterolateral aspect of the elbow and ulcerations of the knees healed slowly in

the course of the next three months, after debridements, aseptic dressings of the wound and protection from external pressure.

A few months later he sustained a non-displaced fracture of the right elbow, which healed with immobilization in plaster for two months. On a recent examination at the age of 9 years, the patient was still very active but more cooperative. His height was 122 cm and weight 23 kg (both at the 10th percentile). His general condition was good. Hyperpigmentation was noted in the posterior aspect of the elbows and over the knees. Tendon reflexes were diminished, abdominal and cremaster reflexes were hypoactive. Radiographs showed no abnormalities in the spine and hips. Radiographs of the knees showed complete healing but the proximal growth cartilage of both tibiae was narrow (fig. 1-D). The right elbow was normal and the left one showed neuropathic changes (fig. 2-A). The right ankle appeared normal, but the left was swollen and radiographs showed neuropathic changes (fig. 2-B). Most of his teeth were missing and scarring of the lips and the tongue in association with wasting of the maxillofacial area, gave an appearance resembling a "toothless old man" (fig. 3).

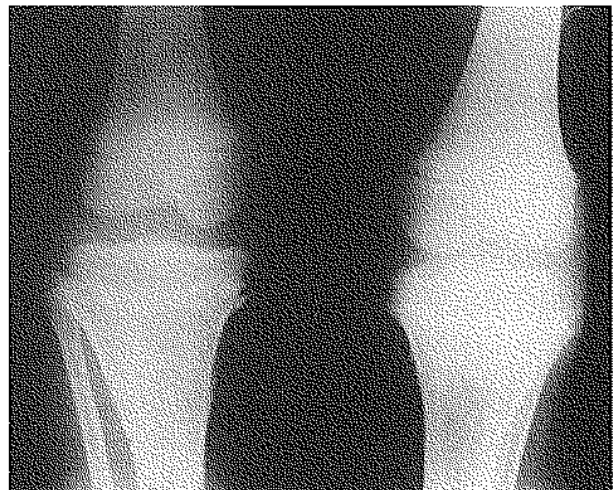

Fig. 1. — D. Radiograph of knees at the age of 9 years shows good remodeling but growth plates of proximal tibial epiphysis are narrowed.

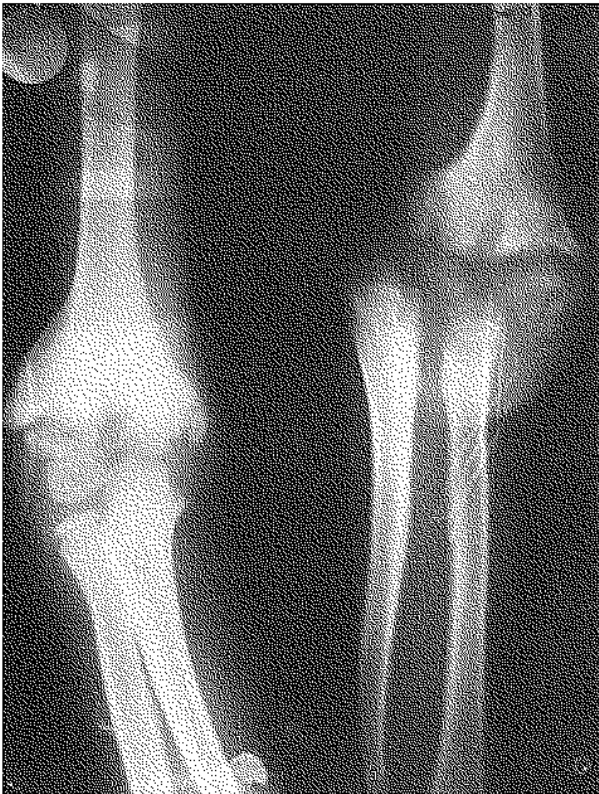


Fig. 2. — A. Neuropathic left elbow joint.

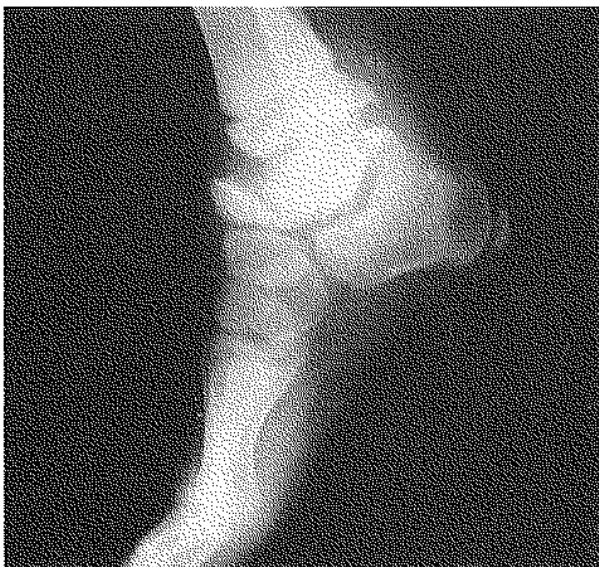

Fig. 2. — B. Neuropathic left ankle joint.

The fingertips of most fingers were missing and the nails were dystrophic. Ulcerations on the anterior surface of the knees and posterior surface of the elbows had recurred, but there had been no new fracture for the last 13 months. The knees and the ankles were slightly swollen and the skin of the legs below the knee was edematous with some hard nodules (fig. 3). Despite the family's support and the help from psychologists the patient manages to escape supervision and to take part in sports like basketball and football.

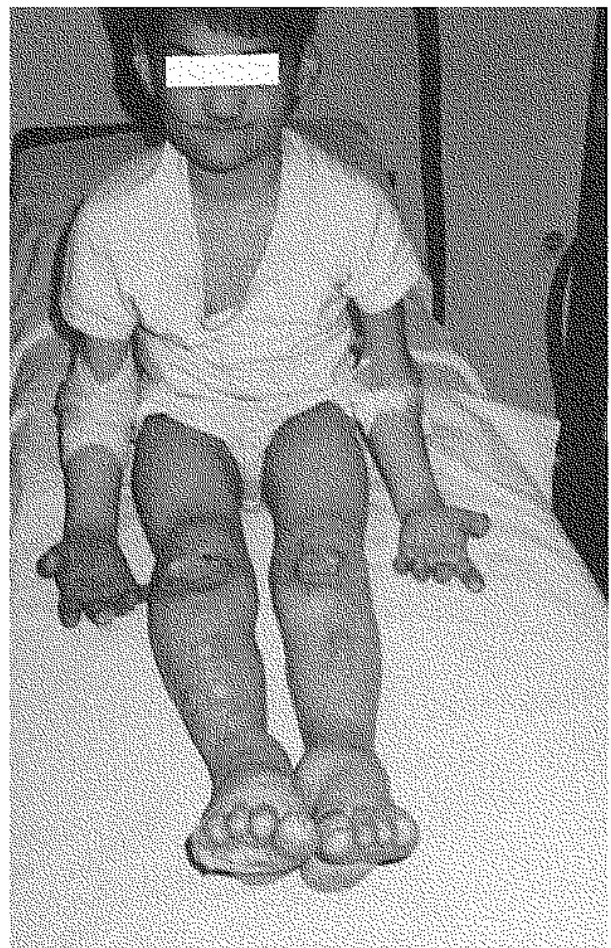

Fig. 3. — Photograph of the patient at the age of 9 years shows scarring of lips and wasting of maxillofacial area. The fingertips of almost all fingers are missing and their ends are rounded. Ulcerations of knees and the foot, swelling and deformity of the left ankle are also noted.

DISCUSSION

Congenital Insensitivity to Pain with Anhidrosis (CIPA) is an autosomal recessive condition, presenting with a wide spectrum of typical clinical symptoms and signs. The classical clinical presentation in neonates and infants includes apathy, hypotonia, often refusal or inability to feed, dry and hot, non-sweating skin even in high summer temperatures. Frequent episodes of unexplained hyperpyrexia occur, particularly in hot weather during the first years of life. This may result in the death of 20% of the affected children (34). Iwanaga *et al.* (1996) reported magnetic resonance imaging and cerebrospinal fluid abnormalities in a 9-month old girl with CIPA and hyperpyrexia, complicated by generalized tonic convulsions and coma. Juri *et al.* (1997) observed encephalitis with generalized tonic convulsions in a 14-month old girl, as a result of heat stroke. Mental retardation of mild degree is usually present and motor abilities may be delayed. Deep sensation is absent and the superficial may be diminished or normal. Many children fail to thrive, the height and the weight percentiles being below average. After eruption of the teeth, biting and scarring of the lips is common and loss of the tip of the tongue results in a round or bifid appearance. Autoextraction of teeth is also common and decubital ulcers of the ventral surface of the tongue from the incisors may lead to severe problems including bleeding, infection, halitosis and malnutrition (2, 5, 23, 32). Maxillofacial problems may also require special care (32).

As a result of biting, fingertips appear scarred, smaller and rounded with dystrophic nails. Burns and self-inflicted lesions of the skin, mainly of the extremities, are common (13, 16). Lacrimation may be defective or normal. Severe ophthalmologic problems may arise from corneal ulcers and introduction of foreign bodies (43).

Fractures may occur early in the first months of life (29, 36, 24) and become frequent with time as the child becomes mobile. Complicated fractures, dislocations, neuropathic joints and infection necessitated amputation in many cases (27, 18, 12). All parts of the skeleton may be affected including

the spine (8). Nagayama *et al.* (31) reported spinal cord injury at birth in a neonate with CIPA.

Diagnosis or differential diagnosis of CIPA from other conditions presenting with absence or depression of pain can be easily established on the basis of the distinct clinical picture. The cardinal features of insensitivity to pain, anhidrosis, frequent hyperpyrexias and mental retardation are not found in any other type of neuropathy.

CIPA has been considered as a rare condition. In 1976 Lee *et al.* estimated the number of reported cases as 7, Theodorou *et al.* (1985) as 28, Rosemberg *et al.* (1994) as 31 and Edwards-Lee *et al.* (1997) as 32 (7). In reviewing the literature we found 51 cases reported in which the general, pediatric, orthopedic and neurological aspects of the condition were presented, 50 cases dealing with ophthalmologic, dermatological, maxillofacial and oral problems and 9 cases in which aspects of histology, genetics and research were discussed, a total of 110 cases.

It is probable that there is overlapping in certain cases, with the same case reported by different authors devoted to different aspects of the condition of the same patient and therefore an accurate estimation is difficult to make. Nevertheless, we believe that the increasing number of reported cases during the last few years has contributed to the earlier diagnosis, study and management of the condition.

Except for the mode of inheritance and the specific gene mutation, the pathophysiology of CIPA remains unclear. In table I, the type of investigations performed to date in patients and the corresponding findings/ results are demonstrated. There are some contradictory results, a fact that can be partly attributed to the limited number of times these investigations are performed. The almost universal finding of extreme paucity of small myelinated fibers as well as the lower density of unmyelinated fibers (which convey the senses of pain and temperature) in electron microscopy in sural nerve biopsy, appears as a pathognomonic feature along with the almost stereotyped clinical presentation (10, 29, 14, 18, 20, 39, 4, 34).

Table I also reflects the different theories on the pathophysiology of the disease. Briefly, these have

Table I. — Investigations performed in patients with CIPA with corresponding findings/results*

Type of investigation	Findings/results
Full blood count, Serum electrolytes, Renal function Tests, Lipid profile, Uric Acid, Blood pH, Lactic acid (serum), Urine organic acids, Serum aminoacids, Electromyography, Cerebrospinal fluid protein, cells, glucose, chloride, Karyotype, Sural nerve biopsy (light microscopy), Vitamins B6, B12, C and folic acid	Normal
Ammonia	Normal/slightly elevated (7)
Liver function tests	Normal/SGOT, LDH elevated (19)
Creatine kinase	Elevated (19)
Immunologic studies	Normal/IgA levels transiently decreased (41)
Electroencephalogram	Normal/diffuse slowing/other non specific findings (7)
Nerve conduction tests (motor and sensory)	Normal/decreased/absence of action potentials in ulnar and sural nerve (3)
Cerebrospinal fluid electrophoresis	Normal/elevation of myelin basic protein (19)
Cerebrospinal fluid Substance-P	Decreased (30)
Urine HVA/VMA** ratio	Slightly elevated (35)
Histamine intradermal injection	Wheal with no axonal flare
Pilocarpine iontophoresis	No sweat production
Ocular Pilocarpine 0,05%	No miosis (7)
Computed tomography brain scan	Normal/non specific dilatation of the third or the lateral ventricles
Magnetic resonance imaging	Normal/changes consistent with hyperpyrexia
Skin biopsy	Normal/lack of innervation of sweat glands
Muscle biopsy	Lipid droplet accumulation and reduced cytochrome C oxidase histochemically/neurogenic and myogenic changes
	Lack/reduction of small myelinated fibers and decreased unmyelinated fibers
Sural nerve biopsy (electron microscopy)	Absence of Lissauer tract, loss of small myelinated fibers in dorsal roots and spinal tract of trigeminal nerve, loss of small ganglion cells of dorsal ganglia
Autopsy	TrKA-NGF gene defect
Gene sequencing	

* Literature references shown either when test performed only once or when findings/results differ from the ones usually reported.

** Homovallinic acid/Vanillylmandelic acid.

been focused on five main hypotheses : I) Disturbance of catecholamine metabolism (35), II) Faulty development of neural crest derivatives (18), III) An inborn error of metabolism involving a minor pathway of tyrosine metabolism (7), IV) Substance-P neurotransmission defect (30), V) Low biological activity of nerve growth factor (15).

Although this pathological entity has been recognized since 19609, it is only in 1996 that Indo *et al.* made an important contribution by demonstrating mutations in tyrosine kinase A/ nerve growth

factor gene (TrKA/NGF gene), in an Ecuadorian family using gene sequencing (15). Moreover, Greco *et al.* in January 2000 found a specific point mutation that is associated with the inactivation of this gene. Nerve Growth Factor (NGF) induces neurite overgrowth and promotes survival of embryonic sensory and sympathetic neurons. This newly detected gene encodes a receptor tyrosine kinase for NGF. This in turn suggests that defects in TrKA cause CIPA and that the NGF-TrKA system has a crucial role in the development and func-

tion of the nociceptive reception as well as establishment of thermoregulation via sweating in humans. Mardy *et al.* and Yotsumoto *et al.* (1999) have confirmed the findings mentioned above.

Early diagnosis of the condition may save the life of neonates and infants suffering from complications such as hyperpyrexia and protect children from exposure to various dangerous activities. The management of bone and joint lesions is extremely difficult. With the protecting benefit of sensation absent, patients overuse the bones and joints, resulting in fractures and dislocations. For psychological reasons affected children are hyperactive and tend to demonstrate their particular qualities and abilities resulting from the absence of pain.

Fractures are more common in the lower limbs particularly proximal to the knee and also ankle and hip joints with consequent neuropathy of the adjacent joints, but practically all bones and joints may be affected. Fractures must be suspected in every bruising or swelling especially near the metaphyses of the long bones. They should be properly immobilized as soon as possible. Usually, well-padded plaster of Paris was applied which should be constantly checked by the parents and replaced immediately if it is worn out. In our case fractures of the proximal tibias and neuropathic knee joints showed satisfactory healing with immobilization in plaster. Fixation of fracture of the lateral condyle of the elbow with Kirschner wires failed. Therefore if internal fixation is indicated, this must be rigid. In one case of an 11-week-old male infant with non-union of a fracture of the ulna, internal rigid fixation with dynamic compression plate was successful (24).

Dislocations are difficult to deal with particularly in neuropathic joints. Attempt for surgical treatment of congenital hip dislocation has failed (22).

Ulcerations in the posterior aspect of the elbows, knees, heels, hands and other parts of the body are managed by local care of the wounds, aseptic dressings and avoidance of external pressure by covering the area with thick dressings, bandaging and other means.

Of utmost importance, are the continuous information, guidance and help of the whole family by psychologists and social workers. The school

personnel should also be informed of the dangers of injuries. The idea is to "steal time". If children are not severely mentally handicapped or uncooperative, they learn with time to avoid exposing themselves to dangerous activities and excessive exertion.

REFERENCES

1. Abbruzzese M., Gatti R., Ratto S., Bugiani O. Congenital sensory neuropathy with anhidrosis. A new family with a study of the sensory conduction velocity. *Acta Neurol.*, 1978, 33, 413-418.
2. Amano A., Akiyama S., Ikeda M., Morisaki I. Oral manifestations of hereditary and sensory autonomic neuropathy type IV. *Oral Surg. Oral Med. Oral Pathol. Oral Radiol. Endod.*, 1998, 86, 425-431.
3. Aslan D., Sarikayalar F. Congenital insensitivity to pain with anhidrosis. *Cutis*, 1997, 60, 188-190.
4. Berkovitch M., Copeliovitch L., Tauber T. *et al.* Hereditary insensitivity to pain with anhidrosis. *Pediatr. Neurol.*, 1998, 19, 227-229.
5. Domingues C., Moreno A., Mariano A. *et al.* Congenital sensory neuropathy with anhidrosis. *Paediatr. Dermatol.*, 1994, 11, 231-236.
6. Dyck P. J., Mellinger F. G., Reagan G. T. *et al.* "Not indifference" but varieties of hereditary sensory and autonomic neuropathy. *Brain*, 1983, 106, 373-390.
7. Edwards-Lee T. A., Cornford M. A., Yu K.-T. T. Congenital insensitivity to pain and anhidrosis with mitochondrial and axonal abnormalities. *Pediatr. Neurol.*, 1997, 17, 356-361.
8. Fath M., Hassannein R., James J. I. P. Congenital absence of pain. *J. Bone Joint Surg.*, 1983, 65-B, 186-188.
9. Gillespie J. B., Perruca L. G. Congenital generalised indifference to pain (congenital analgia). *Am. J. Dis. Child.*, 1960, 100, 124-126.
10. Goebel H. H., Veit S., Dyck P. J. Confirmation of virtual unmyelinated fiber absence in hereditary sensory neuropathy type IV. *J. Neuropathol. Exp. Neurol.*, 1980, 39, 670-675.
11. Greco A., Villa R., Fusetti L. *et al.* The Gly571Arg mutation, associated with the autonomic and sensory disorder congenital insensitivity to pain with anhidrosis causes inactivation of the NTRK1/ nerve growth factor receptor. *J. Cell Physiol.*, 2000, 182, 127-130.
12. Hasegaya Y., Ninomiya M., Yamata Y., Hattori T. Osteoarthropathy in congenital insensitivity to pain with anhidrosis. *Clin. Orthop.*, 1990, 258, 232-236.
13. Hatzis J., Gourgiotou K., Koumelas D. *et al.* Congenital sensory neuropathy with anhidrosis. (Congenital sensory neuropathy type IV). *Australas. J. Dermatol.*, 1992, 33, 103-107.

14. Herdem N., Polat *et al.* Congenital insensitivity to pain with anhidrosis. A case report. *Int. Orthop.*, 1998, 22, 139-140.
15. Indo Y, Tsuruta M., Hayashida Y. *et al.* Mutations in TrKA /NGF receptor gene in patients with congenital insensitivity to pain with anhidrosis. *Nat. Genet.*, 1996, 13, 485-488.
16. Ishii N., Kawaguchi H. *et al.* Congenital sensory neuropathy with anhidrosis. *Arch. Dermatol.*, 1998, 124, 564-56.
17. Ismail E. A., Al Shammari N., Anim J. T. *et al.* Congenital insensitivity to pain with anhidrosis. Lack of eccrine sweat gland innervation confirmed. *J. Child. Neurol.*, 1998, 13, 243-246.
18. Itoh Y., Yagishita S., Nakayima S., Nakano T. Congenital insensitivity to pain with anhidrosis : Morphological and morphometrical studies on the skin and peripheral nerves. Ippokrates Verlag GmbH, 1986, 17, 103-110.
19. Iwanaga R., Matsuishi T., Ohnishi K. *et al.* Serial magnetic resonance images on a patient with congenital sensory neuropathy and complications resembling heat stroke. *J. Neurol. Sci.*, 1996, 142, 79-84.
20. Juri T., Higuchi R., Shirai T. *et al.* A case of hereditary sensory and autonomic neuropathy type IV, diagnosed following the development of acute encephalopathy due to stroke. *No To Hattatsu*, 1997, 29, 254-260.
21. Kim J. S., Woo Y. J., Kim C. J. *et al.* Congenital insensitivity to pain with anhidrosis : a case report. *J. Korean Med. Sci.*, 1999, 14, 460-464.
22. Koster G., Knoch M., Von Villert H. G. Unsuccessful surgical treatment of hip dislocation in congenital sensory neuropathy with anhidrosis. *J. Bone Joint Surg.*, 1999, 81-B, 102-105.
23. Kouvelas N., Terzoglu C. Congenital insensitivity to pain with anhidrosis. A case report. *Pediatr. Dent.*, 1989, 11, 47-51.
24. Krettek C., Gluer S. *et al.* Non-union of the ulna in a ten-month-old child who had type IV hereditary sensory neuropathy. A case report. *J. Bone Joint Surg.*, 1997, 79-A, 1232-1234.
25. Langer J., Goebel H. H., Veit S. Eccrine sweat glands are not innervated in hereditary sensory neuropathy with anhidrosis. *Acta Neuropathol. (Berl)*, 1981, 54, 199-202.
26. Lee E. L., Ohg C., Lam K. L., Paramesvaran N. Congenital sensory neuropathy with anhidrosis. A case report. *Paediatr.*, 1976, 57, 259-262.
27. Majare A., Herold H. G., Vardy P. A. Congenital sensory neuropathy with anhidrosis. *Clin. Orthop.*, 1976, 118, 184-187.
28. Mardy S., Miura Y., Endo F. *et al.* Congenital insensitivity to pain with anhidrosis. Novel mutation of TRKA (NTRK1) gene encoding a high affinity receptor for NGF factor. *Am. J. Hum. Genet.*, 1999, 64, 1590-1579.
29. Matsuo M., Kurikawa T., Giya N., Ohta M. Congenital insensitivity to pain with anhidrosis in a two-month-old boy. *Neurol.*, 1981, 31, 1190-1192.
30. Nagamitsu S., Toyojiro M., Ohnishi A., Kato H. Decreased CSF levels of substance-P in patients with congenital sensory neuropathy with anhidrosis. *Neurology*, 1997, 48, 1133.
31. Nagayama E., Segawa M., Kitayama T. A case of spinal cord injury at birth with analgesia and anhidrosis. *Pediatr. Univ. Tokyo*, 1970, 18(-HD-), 174-179.
32. Narayanan V. Oral and maxillofacial manifestations of hereditary sensory neuropathy with anhidrosis. *Br. J. Oral Maxillofac. Surg.*, 1996, 34, 446-449.
33. Pinsky L., Digeorge A. M. Congenital familial neuropathy with anhidrosis. *J. Paediatr.*, 1966, 68, 1-13.
34. Rosemberg S., Marie S. K., Kliemann S. Congenital insensitivity to pain with anhidrosis. *Paediatr. Neurol.*, 1994, 11, 50-56.
35. Shekim W. O., Daniel A. E., Koresko R. *et al.* Catecholamine metabolites in congenital sensory neuropathy with anhidrosis. *Paediatr.*, 1980, 65, 154-156.
36. Swanson A. G. Congenital insensitivity to pain with anhidrosis. A unique syndrome in two males. *Arch. Neurol.*, 1963, 8, 299-306.
37. Swanson A. G., Buchan G. C., Alvor E. C. Jr. Anatomic changes in congenital insensitivity to pain. *Arch. Neurol.*, 1965, 12, 12-18.
38. Tachi N., Ohya K., Chiba S. *et al.* Muscle involvement in congenital insensitivity to pain with anhidrosis. *Pediatr. Neurol.*, 1995, 125, 264-266.
39. Tawa R., Matsuda H., Morimoto T. *et al.* Neurophysiologic and histopathologic studies in a case of congenital sensory neuropathy with anhidrosis. *No To Hattatsu*, 1992, 24, 542-547.
40. Theodorou S. D., Rasheed Asma, Maklouf S. A., Stefanouris J. C. Orthopaedic complications in congenital sensory neuropathy with anhidrosis. *Acta Orthop. Belgica*, 1985, 51, 91-102.
41. Vardy P. A., Greenberg L. W., Kochel C. *et al.* Congenital insensitivity to pain with anhidrosis ; report of a family and review of the literature with reference to immune deficiency. *Am. J. Dis. Child.*, 1979, 133, 1153-1155.
42. Vassella F., Emrich M. H., Kraus-Ruppert R. Congenital sensory neuropathy with anhidrosis. *Arch. Dis Child.*, 1968, 43, 124-130.
43. Yagev R., Levy J. *et al.* Congenital insensitivity to pain with anhidrosis. Ocular and systemic manifestations. *Ophthalm.*, 1999, 127, 322-326.
44. Yoshitake S., Maysumoto K. *et al.* Anaesthetic consideration of a patient with congenital insensitivity to pain with anhidrosis. *Masui*, 1993, 42, 1233-1236.
45. Yotsumoto S., Setoyama M., Hozumi H. *et al.* A novel point mutation affecting the tyrosine kinase domain of TRKA gene in a family with congenital insensitivity to pain with anhidrosis. *J. Invest. Dermatol.*, 1999, 112, 810-814.

SAMENVATTING

S. D. THEODOROU, A. E. KLIMENTOPOULOU, E. PAPALOUKA. *Congenitale ongevoeligheid voor pijn met anhidrose : case report en overzicht van de literatuur.*

De auteurs stellen een typisch geval voor van aangeboren ongevoeligheid voor pijn met anhidrose, alsmede een overzicht van de literatuur naar frequentie, etiologie en problemen veroorzaakt door deze aandoening. Het gaat om een autosomaal recessieve aandoening met een sensorielle neuropathie met volgende kenmerken: ongevoeligheid voor pijn, anhidrose of hypohidrose, koortsperiodes bij jongere patiënten, auto-traumata, geen of weinig tranen en lichte mentale achterstand. Orthopedische, maxillofaciale, dermatologische en oftalmologische complicaties zijn frequent. Een vroegtijdige diagnose is belangrijk. Alhoewel de etiopathogenese nog onbekend is, zal de ontdekking van een gen verantwoordelijk voor een factor voor de ontwikkeling en de groei van zenuwen een doorbraak betekenen in de studie en behandeling van deze aandoening.

RÉSUMÉ

S. D. THEODOROU, A. E. KLIMENTOPOULOU, E. PAPALOUKA. *Indifférence congénitale à la douleur avec anhidrose. Présentation d'un cas.*

Les auteurs présentent un cas typique d'«insensibilité congénitale à la douleur avec anhidrose» et aussi une revue de la littérature sur la fréquence, l'étiologie et les problèmes provoqués par la maladie. Il s'agit d'une forme autosomique récessive de la neuropathie sensorielle qui se manifeste par des signes cliniques typiques: insensibilité à la douleur, anhidrose ou hypohidrose, crises d'hyperpyrexie chez des sujets jeunes, auto-traumatismes, pas ou peu de larmes et retard mental léger. Des complications orthopédiques, maxillo-faciales, dermatologiques et ophtalmiques sont fréquentes. Le diagnostic précoce est très important. Bien que la physiopathologie soit pas encore connue, la découverte d'un nouveau gène responsable du facteur déterminant le développement et la croissance des nerfs pourrait faire progresser l'étude et le traitement de la maladie.