

BIFOCAL PUBIC STRESS FRACTURE AFTER IPSILATERAL TOTAL KNEE ARTHROPLASTY IN RHEUMATOID ARTHRITIS

A CASE REPORT

E. THIENPONT, J. P. SIMON, D. SPAEPEN, G. FABRY

We present the case of a 78-year-old rheumatoid patient with a bifocal stress fracture of the pubic rami after ipsilateral total knee arthroplasty. Many risk factors that may cause insufficiency fractures are combined in rheumatoid arthritis. These patients are used to chronic pain, and therefore the diagnosis is often made late. When a patient suffering from rheumatoid arthritis presents with recent pain in the pelvic or hip region after hip or knee arthroplasty, a stress fracture should always be suspected. A standard pelvic radiograph and skeletal scintigraphy establish the diagnosis. CT-scan may be useful in the differential diagnosis with less benign pathology. Rest and analgesic drugs are sufficient to let the fracture heal. Nonunion has never been reported for these fractures.

Key words : pubis, stress fracture, rheumatoid arthritis, arthroplasty.

Mots-clés : pubis, fracture de fatigue, arthrite rhumatoïde, prothèse totale.

Rheumatoid arthritis is a well-known risk factor for insufficiency fractures (4, 5, 6). However pubic stress fractures and especially bifocal fractures of the pelvis are rare (4). The incidence of these fractures is probably underestimated since these patients are used to daily pain and experience these fractures as mild to moderate discomfort (4). We report the case of a patient who sustained a bifocal fracture of the pubic rami a few months after she had ipsilateral total knee arthroplasty.

CASE REPORT

A 78-year-old woman presented to our outpatient clinic with pain in the left hip. She had a history of seropositive rheumatoid arthritis for which she was at that time on D-penicillamine. She had not been on corticosteroids for the last 2 years. She had a total knee arthroplasty on the right side 3 years earlier and a total hysterectomy 7 years previously. She started to complain of activity-related pain in the hip and pelvis 3 months after she had a total knee arthroplasty on the same side. Her general practitioner prescribed rest and anti-inflammatory medication. The pain in her left groin recurred when she stopped the medication. She experienced difficulty walking longer distances and lifting objects from the floor.

Physical examination revealed a "positive standing sign" and tenderness on deep palpation of the left groin. The range of motion of the hip was limited but not painful. Standard xrays of the pelvis showed a bifocal stress fracture of the left pubic rami with callus formation as well as arthritic changes in both hips. The full leg radiograph demonstrated slight varus alignment of the left knee. Complete rest for an additional 6 weeks was advised, following which all symptoms resolved.

Department of Orthopedic Surgery, University Hospital Pellenberg, K.U. Leuven.

Correspondence and reprints : J. P. Simon, Department of Orthopedic Surgery, University Hospital Pellenberg, Weliger-veld 1, B-3212 Pellenberg, Belgium.

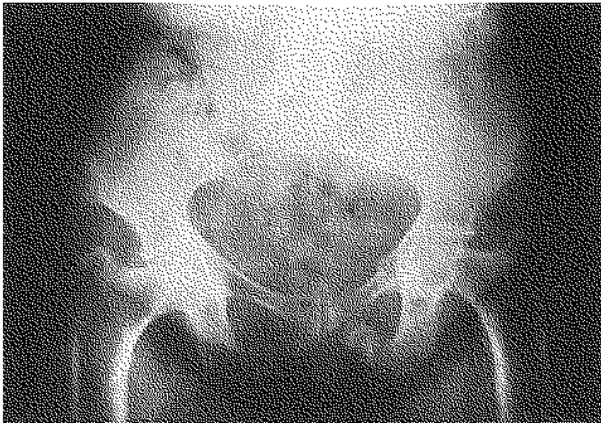


Fig. 1. — Standard xrays show a stress fracture of the left superior and inferior pubic ramus with surrounding callus formation.

DISCUSSION

Many predisposing factors may lead to weakening of bone and insufficiency fractures. These include osteoporosis, inflammatory diseases, chronic renal failure, prolonged corticosteroid treatment, pelvic irradiation and biomechanical changes after arthroplasty (5, 6). Bone loss in osteopenic women is induced by their hormonal status, age, lack of physical activity, low body mass, and sometimes by taking steroids for a prolonged time in addition to chronic disease (1, 3, 4). In rheumatoid patients several factors predisposing to osteopenia are likewise combined. These patients often have been treated with corticosteroids for a long time, while their restricted activity, in addition to the autoimmune process, negatively affects their skeleton (1). Multiple joint arthroplasties are often necessary to maintain these patients mobile. Arthroplasties lead to a higher activity level and simultaneously affect the biomechanical strain on their bones by altering the force vectors on the skeleton. Thus both the arthroplasty and the improved mobility increase the strain to a level their bones are no longer adapted for, owing to their long-standing disease. Insufficiency fractures following arthroplasty are thus induced by a combination of increased activity and altered biomechanics. Malalignment may be an additional factor predisposing to this problem. Many pubic




Fig. 2. — Full leg xrays show varus alignment of the left knee.

fractures after total hip replacement and even femoral neck fractures after total knee arthroplasty have been described (2). In these cases early diagnosis is very important, since arthroplasty of the hip may be necessary after displacement, whereas screw fixation or rest may be sufficient in undisplaced cases. However only two pubic fractures after total knee replacement have been reported, but never a bifocal case (7, 8). The female gender is more at risk for such insufficiency fractures for anatomical reasons: the bones are more slender, the margins of the ischiopubic rami are less everted and the obturator foramen is more triangular than oval (3).

These patients will often present with only mild complaints of pain in the groin and/or the ischial tuberosity (4). Since rheumatoid patients are used to daily pain and anti-inflammatory or analgesic drugs ease the pain, they usually delay their search for medical help. Physical examination is important since discomfort is experienced in monopodal stance, putting weight on the affected side with the normal leg unsupported ("positive standing sign"). Deep palpation reveals local tenderness over the pubic ramus and the ischial tuberosity (4).

Most pubic stress fractures are seen in athletes. These stress fractures must be differentiated from adductor tendinitis, a pulled muscle in the groin or hamstrings, osteitis pubis and avulsion fractures of the adductor or hamstring muscles. For this reason an xray and radionuclide bone scan (Tc^{99} MDP) must be requested. Stress fractures may however have an aggressive appearance on xray and bone scan mimicking malignancy (6). CT-scan may be helpful in the differential diagnosis: it shows the fracture line with the surrounding callus formation (5). MRI may give an erroneous diagnosis since the images may suggest low-grade chondrosarcoma (6). This may lead to a biopsy which may support the diagnosis of malignancy since hemorrhage, fibrous tissue, woven bone, dead bone and cartilage may be found not only in a stress fracture, but also in a chondrosarcoma, an osteosarcoma or even in osteomyelitis (6).

Until now, nonunion of a stress fracture of the pubis has never been described (3). As in our case a longer period of rest and pain killers are sufficient to treat the problem. If the patient has a total hip arthroplasty, problems of loosening and/or infection of the components must be excluded.

In conclusion, insufficiency fractures of the pubic rami should be suspected when a patient presents with pain in the groin following total knee arthroplasty.

REFERENCES

1. Dequeker J., Maenhaut K., Verwilghen J., Westhovens R. Osteoporosis in rheumatoid arthritis. Clin. Exp. Rheumatol., 1995, 13, 21-26.

2. Hardy D., Delince P., Yasik E., Lafontaine M. Stress fracture of the hip. An unusual complication of total knee arthroplasty. Clin. Orthop., 1992, 281, 140-144.
3. Hill P., Chatterji S., Chambers D., Keeling J. Stress fracture of the pubic ramus in female recruits. J. Bone Joint Surg., 1996, 78-B, 383-386.
4. Isdale A. Stress fractures of the pubic rami in rheumatoid arthritis. Ann. Rheum. Dis., 1993, 52, 681-684.
5. Schapiro D., Militeanu D., Israel O., Scharf Y. Insufficiency fractures of the pubic ramus. Semin. Arthritis Rheum., 1996, 25, 373-382.
6. Seo G., Aoki J., Karakiola O., Sone S., Ishii K. Ischiopubic insufficiency fractures: MRI appearances. Skeletal Radiol., 1997, 26, 561-567.
7. Smith M., Henke J. Pubic ramus fatigue fractures after total knee arthroplasty. A case report. Orthopedics, 1988, 11, 315-317.
8. Torisu T. Fatigue fracture of the pelvis after total knee replacements: Report of a case. Clin. Orthop., 1980, 149, 216-219.

SAMENVATTING

E. THIENPONT, J. P. SIMON, D. SPAEPEN, G. FABRY. Bifocale stress fractuur van de pubis na een ipsilaterale totale knieprothese in een reumatoïde arthritis patiënt.

Wij stellen een geval voor van een bifocale stress fractuur van de ramus superior en inferior van de pubis na het plaatsen van een totale knieprothese aan de ipsilaterale zijde, bij een patiënte die lijdt aan reumatoïde arthritis. Een aantal voorbeschikkende factoren voor stress fracturen zijn aanwezig bij reumatoïde arthritis. Deze patiënten, die gewoon zijn aan chronische pijn, ervaren de last van dergelijke fracturen slechts als een milde tot matige pijn. Om deze reden worden dergelijke fracturen wellicht vaak niet gediagnosticeerd. Pijn rond de heup of in het bekken, na het plaatsen van een heup- of knieprothese moet bijgevolg steeds doen denken aan een mogelijke stress fractuur van de pubistakken. Een radiografische bekkenopname en een technesium botscintigrafie eventueel aangevuld met een CT-scan laten toe de diagnose te stellen. Rust en analgetische medicatie volstaat als behandeling. Pseudarthrosen van dergelijke fracturen werden nooit beschreven.

RÉSUMÉ

E. THIENPONT, J. P. SIMON, D. SPAEPEN, G. FABRY. Fracture de fatigue du pubis après prothèse totale de genou ipsilatérale chez une patiente atteinte d'arthrite rhumatoïde.

Nous présentons un cas de fracture de fatigue bifocale des branches supérieure et inférieure du pubis après implantation d'une prothèse totale de genou du même côté, chez une patiente atteinte d'arthrite rhumatoïde. Les patients atteints d'arthrite rhumatoïde sont habitués aux douleurs chroniques et ressentent donc ces fractures comme légèrement ou moyennement douloureuses. Pour cette raison, ces fractures échappent souvent au diagnostic. Une douleur de hanche ou du bassin, après

implantation d'une prothèse de hanche ou de genou doit par conséquent toujours faire penser à la possibilité d'une fracture de fatigue des branches pubiennes. Une radiographie du bassin et une scintigraphie osseuse éventuellement complétées par un CT scan permettent de poser le diagnostic. Le repos et les antalgiques suffisent comme traitement. Une évolution vers la pseudarthrose n'a jamais été décrite.