

## Anterolateral approach for posterolateral tibial plateau fractures

Jianwen LI, Khan Akhtar ALI, Chengyan XIA, Meipeng ZHU, Weikai ZHANG, Hui HUANG

Department of Orthopedics, Tongji Hospital, Tongji Medical College, Huazhong University of Science and Technology, Wuhan, Hubei, China.

Correspondence at: Weikai Zhang, Jiefang Avenue, Qiaokou District, Wuhan, Hubei, 430030, China, Email: weikai-zhang@qq.com

**The posterolateral tibial plateau fracture is an uncommon intra-articular injury and mostly needed surgery. However, its surgical approach remains controversial. This manuscript describes an anterolateral approach to treat posterolateral tibial plateau fractures and evaluates the patient's functional outcomes. From June 2018 to July 2021 seventeen patients with posterolateral tibial plateau fractures were surgically treated through an anterolateral approach. The intraoperative and postoperative follow-up indicators were recorded. The reduction quality of fractures was assessed using Rasmussen radiological score, and postsurgical functional recovery was estimated using Rasmussen clinical score and Lysholm score. The mean follow-up interval was  $28.71 \pm 9.61$  months (range 18-44). The surgery time and blood loss were  $111.06 \pm 15.62$  min (range 85-140) and  $118.12 \pm 38.45$  mL (range 80-250) separately. Postoperatively, the Rasmussen radiological score was  $16.24 \pm 2.33$  (range 12-18). The average time of bone union was  $14.29 \pm 1.53$  weeks (range 12-18). At the final follow-up, the average PTS and MPTA were  $9.71 \pm 2.76^\circ$  (range 5-14 $^\circ$ ) and  $86.82 \pm 2.04^\circ$  (range 84-90 $^\circ$ ) separately. A satisfactory articular reduction was achieved in 16 patients (94.1%). The final ROM was  $123.29 \pm 19.70^\circ$  (range 60-142 $^\circ$ ). The Rasmussen clinical score and Lysholm score were  $25.71 \pm 5.74$  (range 10-30) and  $91.47 \pm 6.50$  (range 75-98) separately. Anterolateral approach has minimal risk of intraoperative neurovascular injuries in the popliteal fossa with satisfactory results. The hardware removal was also facilitated. This approach is feasible, safe and efficient.**

**Keywords:** Knee, tibial plateau fractures, posterolateral fracture, anterolateral approach.

### INTRODUCTION

Posterolateral tibial plateau fracture is an uncommon articular surface injury, and its prevalence is approximately 7% in tibial plateau fractures<sup>1,2</sup>. The injury mechanism is mainly electric bicycle accidents and its incidence is high in China<sup>3</sup>. When the knee is in a flexion position, an axial compressive loading with valgus force imposes on the posterior part of the tibial plateau, which is subjected to posterolateral tibial plateau fractures. This specific fracture pattern is difficult to describe by an established classification method and is usually presented with isolated or combined with other tibial plateau quadrant fractures<sup>4</sup>. Thus, it is usually underestimated.

For posterolateral tibial plateau fractures, open reduction and internal fixation are the main treatment to restore the congruity of the joint surface, axial alignment, and knee stability<sup>5</sup>. Orthopedic surgeons have proposed different surgical methods to fix this fracture. Chang et al.<sup>1</sup> used a direct posterolateral incision to expose and buttress plate fixation for posterior coronal fractures of the tibial plateau. During follow-up, four of eight (50%) patients occurred with a flexion lag of

10°-20° after surgery. Moreover, four of five (80%) patients with bone union performed plate removal surgery, but the iatrogenic venous damage occurred during the second surgery<sup>6</sup>. Luo et al.<sup>7</sup> introduced an inverted L-shaped incision to fixate posterior tibial plateau fragments, but it may injure neurovascular bundle branches in the popliteal fossa. Lobenhoffer et al.<sup>8</sup> first reported a transfibular approach with fibula neck osteotomy for fixation of posterolateral fractures, whereas the possibility of common peroneal nerve damage and fibula nonunion exists. Hence, the best surgical approach to treat posterolateral tibial plateau fractures remains controversial. It is urgent to find a feasible and safe surgical method. The anterolateral approach has been a classic surgery method for the treatment of lateral tibial plateau fractures (Schatzker type I-III)<sup>9,10</sup>. It possesses advantages including convenient manipulation, low iatrogenic injury risk, and obtaining a promising prognosis.

Our study used an anterolateral approach for posterolateral plateau fractures and their functional outcomes were evaluated.

## MATERIALS AND METHODS

Between June 2018 and July 2021, seventeen consecutive patients with posterolateral split depression fractures of the tibial plateau were included in this study, and they were operatively treated with the anterolateral approach. The inclusion criteria were as follows: Displaced or comminuted split-depression fractures extending into the lateral part of the posterior column, intra-articular displacement of  $\geq 2$  mm, unilateral closed fractures, and patients aged  $\geq 18$  years. Meanwhile, the exclusion criteria were as follows: undisplaced fractures of the posterolateral tibial plateau, fracture extension into the medial tibial plateau requiring surgery, and open or bilateral fractures.

This study included six males (35.3%) and eleven females (64.7%), with an average age of  $48.59 \pm 15.91$  years (range 18-70). The injury mechanism included motor collision (six patients, 35.3%), fall from an electric bicycle (four patients, 23.5%), motorcycle/electric bicycle collision (three patients, 17.6%), fall

(two patients, 11.8%), fall from height (one patient, 5.9%), and struck by a heavy object (one patient, 5.9%). One patient had a lateral meniscus (LM) slight torn. One patient had anterior cruciate ligament avulsion. One patient had LM and medial meniscus (MM) torn, lateral collateral ligament (LCL) avulsion, and medial collateral ligament (MCL) avulsion. One patient occurred a common peroneal nerve (CPN) injury. The patient demographics are shown in Table 1.

According to the AO/OTA system<sup>11</sup>, seventeen patients with posterolateral aspect fractures of the tibial plateau were classified. Two patients with pure split fractures were classified as 41-B1.1(4), three patients with pure depression fractures were classified as 41-B2.2(4), and twelve split-depression fractures were classified as 41-B3.1(4).

Preoperative routine examinations included knee X-ray, CT, three-dimensional reconstruction, and low limb color ultrasound. MRI was performed for suspecting ligaments and meniscus injury. The injured limb was provisionally fixed with calcaneal pin traction

**Table 1.** — Patient demographics.

Patient No.	Gender/ Age (y)	Injured limb	Injury mechanism	Proximal fibular fracture	Fracture classification	Surgery approach	Time from injury to surgery (d)	Associated lesion
1	F/56	Right	Motor collision	No	S-D	AL	7	None
2	F/46	Right	Fall from an electric bicycle	No	S-D	AL	9	None
3	F/38	Left	Motor collision	Yes	S	AL	8	None
4	F/31	Right	Motor collision	Yes	S-D	AL	9	LM tear
5	F/54	Left	Motor collision	No	S-D	AL	6	None
6	F/77	Left	Motorcycle collision	No	S-D	AL	7	None
7	M/49	Left	Fall from height	No	D	AL	5	None
8	F/48	Left	Fall from an electric bicycle	No	S-D	AL	3	ACL avulsion
9	M/56	Left	Struck by a heavy object	No	S-D	AL	3	LM and MM tear, LCL and MCL avulsion
10	F/18	Left	Fall from an electric bicycle	No	D	AL	5	None
11	M/28	Right	Fall	No	S-D	AL	6	CPN damage
12	F/74	Left	Electric bicycle collision	Yes	S	AL	9	None
13	M/53	Left	Fall from an electric bicycle	No	S-D	AL	4	None
14	M/56	Left	Fall	No	D	AL	9	None
15	F/67	Right	Electric bicycle collision	No	S-D	AL	5	None
16	F/40	Left	Motor collision	No	S-D	AL	13	None
17	M/35	Left	Motor collision	No	D	AL	6	None

y, year; d, day; F, Female; M, Male; S-D, Split-depression; S, Split; D, Depression; AL, Anterolateral.

or plaster, and the surgery time depended on the patient’s condition.

All patients were placed in the supine position, a tourniquet was used and general or nerve blocked anesthesia was given. An anterolateral incision started from the proximal crease of the knee joint and extended distally to below the inferior margin of the fracture site. Next, an arc incision was performed from the anterior margin of the lateral condyle to the Gerdy tubercle. The incision of the fascia was parallel to the leading edge of the iliotibial tract, and sharply cutting the coronary or infra-meniscotibial ligament and superiorly retracting the lateral meniscus were performed to open the knee joint. The starting point of the extensor muscles was stripped from the anterolateral edge of the lateral condyle through an inverted L-shaped incision. The horizontal limb of the incision was extended laterally from the tibial tuberosity and passed the vertical limb of the incision distally just lateral to the crest of the tibia. The muscle was retracted laterally to expose the collapsed articular surface and fracture fragments. Subsequently, the cortical window underneath the depression area was made. A periosteal elevator was inserted below the articular fragments of depression to elevate the depressed fracture blocks with moderate upward pressure. The bone defect was filled with allograft bone after reducing the articular surface.

Several Kirschner wires were used to temporarily fix the restored fracture fragment, while using a fluoroscope to check the insertion site of Kirschner wires. Care should be taken to avoid interfering with the plate placement. Then, an L-shaped buttress plate with raft screws was placed and used for definite fixation. The meniscus was carefully sutured to the previous attachment. The fascia and skin were closed while placing drainage.

The muscle strengthening exercises were encouraged, a passive motion machine was used after the second day and the knee joint’s range of motion (ROM) increased gradually. All patients were allowed to walk with a stick after four weeks postsurgically.

All patients were followed up at postoperative one, three, six, and twelve months respectively. X-rays of the injured knee and physical examinations were routinely checked each time to assess fracture healing and functional recovery of the knee. Rasmussen radiological score was used to estimate the reduction quality of fractures by immediate postsurgical radiographs. At the last follow-up, Rasmussen clinical score and Lysholm score were used to evaluate the functional recovery of patients. Moreover, the posterior tibial slope (PTS), medial proximal tibial angle (MPTA), lateral condylar width, and intra-articular step-off were measured by anteroposterior and lateral radiographs of the joint.

**Table II.** — Intraoperative and postoperative follow-up variables.

Patient No.	Surgery time (min)	Blood loss (ml)	Postoperative hospital stays (d)	Ambulation time (w)	Bone union (w)	Full loading (w)	PTS (°)	MPTA (°)	articular step-off (mm)	Lateral condylar width (mm)
1	112	110	4	4	12	14	5	88	0	0
2	127	140	8	5	16	12	12	85	0	0
3	115	104	13	9	14	17	10	86	0	1.31
4	120	108	8	8	15	14	6	85	0	0
5	95	90	11	4	14	16	12	89	0	0
6	106	110	10	8	14	16	12	84	0	0
7	135	115	7	4	15	14	11	87	0	0
8	125	102	8	8	13	16	9	89	0	0
9	85	80	7	8	14	18	14	85	1.80	0
10	90	109	6	4	12	14	7	89	2.18	5.67
11	121	105	8	4	15	14	6	85	0	0
12	98	85	6	6	14	16	10	90	0	1.75
13	108	150	9	7	14	16	11	88	0	0
14	110	120	6	4	12	14	8	88	0	0
15	140	250	7	6	17	15	13	84	0	0
16	105	100	6	6	18	18	7	85	0	3.01
17	96	130	7	4	14	16	12	89	0	0

w, week

Definition of malreduction included  $PTS \geq 15^\circ$  or  $\leq -5^\circ$ ,  $MPTA \geq 95^\circ$  or  $\leq 80^\circ$ , lateral condylar width  $> 5\text{mm}$ , or intra-articular step-off  $> 2\text{mm}$ .

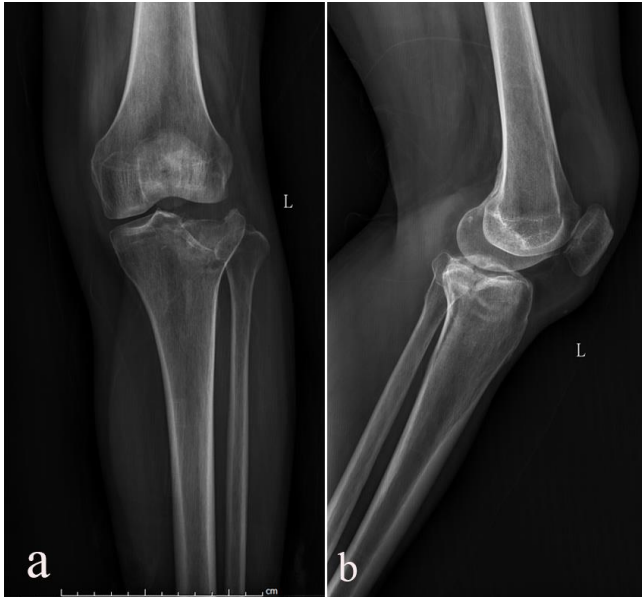

Fig. 1. — A 54-year-old female sustained from an electric bicycle accident was surgically treated through the anterolateral approach. a, b Preoperative anteroposterior and lateral X-ray views showed the collapse of the lateral part of tibial plateau.

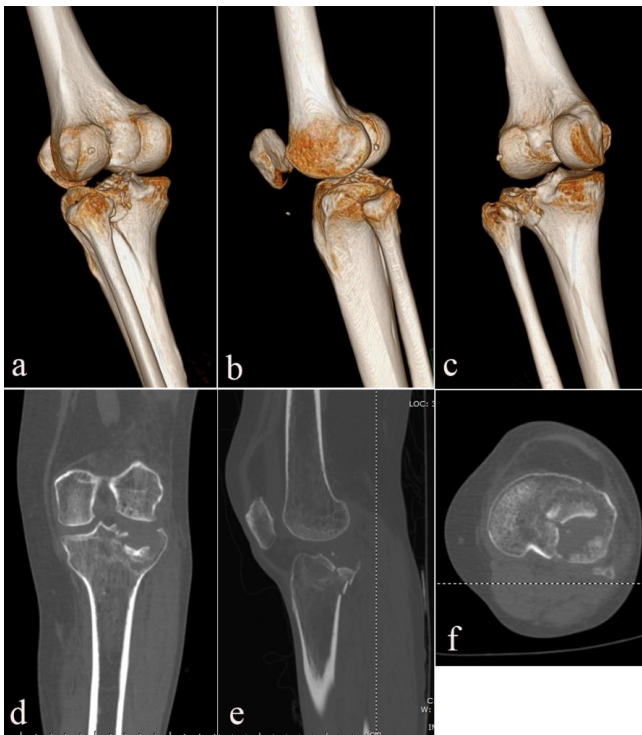


Fig. 2. — Preoperative CT and three-dimensional reconstruction views clearly showed the split and expression of the lateral tibial plateau involving the posterolateral aspect. a-c Three-dimensional reconstruction view. d Coronal view. e Sagittal view. f Axial view.

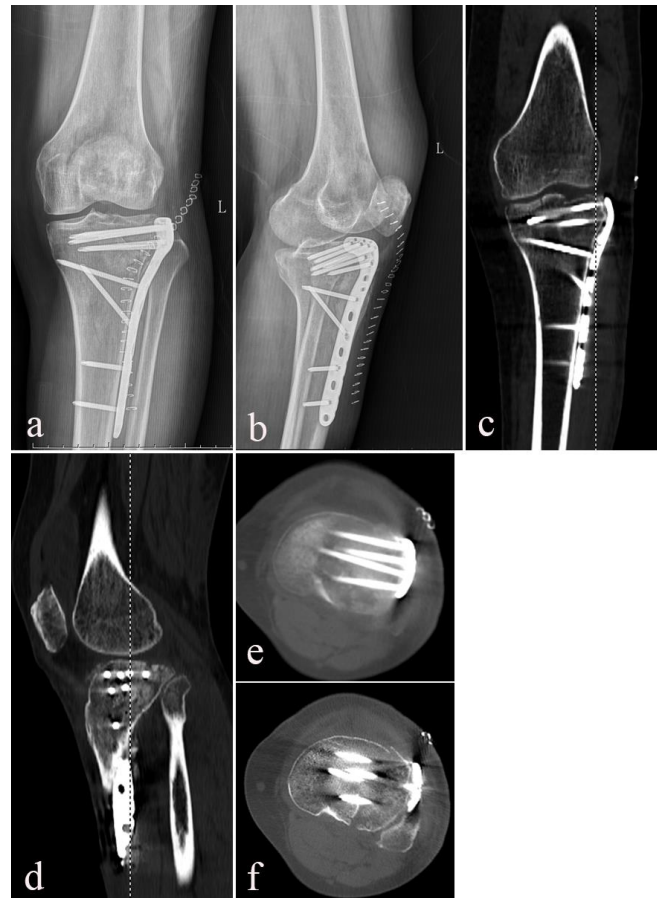

Fig. 3. — Postoperative X-rays and CT views showed collapsed articular surface was satisfactorily restored. a, b Anteroposterior and lateral views. c Coronal view. d Sagittal view. e, f Axial view.

## RESULTS

The average follow-up period of all patients was  $28.71 \pm 9.61$  months (range 18-44), and the mean time from injury to surgery was  $6.71 \pm 2.59$  days (range 3-13). The average operation time was  $111.06 \pm 15.62$  min (range 85-140). Moreover, the average blood loss was  $118.12 \pm 38.45$  mL (range 80-250). No neurovascular injury occurred during surgery. No knee joint instability has occurred in three patients with preoperative ligament and meniscus damages after surgery. (Table 2)

The average postoperative hospital stay was  $7.71 \pm 2.14$  days (range 4-13). After surgery, the mean ambulation time was  $5.82 \pm 1.85$  weeks (range 4-9), and the average full-loading interval was  $15.29 \pm 1.61$  weeks (range 12-18). All patients have achieved bone union, with an average time of  $14.29 \pm 1.53$  weeks (range 12-18). (Table 2)

Rasmussen radiological score was  $16.24 \pm 2.33$  points (range 12-18) and all patients obtained satisfactory fracture reduction (Fig.1-3) (Table 3). At the final follow-up, the average PTS and MPTA were 9.71

**Table III.** — Follow-up function evaluation and complications.

Patient No.	Follow-up (m)	Final ROM (°)	Rasmussen radiological score/grade	Rasmussen clinical score/grade	Lysholm score/grade	Complications	Hardware removal after bone union
1	44	128	12/Good	29/Excellent	97/Excellent	None	Yes
2	43	130	18/Excellent	30/Excellent	98/Excellent	None	Yes
3	42	134	14/Good	28/Excellent	85/Good	None	No
4	40	132	18/Excellent	27/Excellent	95/Excellent	None	Yes
5	39	142	18/Excellent	29/Excellent	95/Excellent	None	Yes
6	32	128	18/Excellent	24/Good	93/Good	None	No
7	30	140	18/Excellent	28/Excellent	96/Excellent	None	No
8	28	125	14/Good	27/Excellent	96/Excellent	None	No
9	26	132	16/Good	29/Excellent	93/Good	None	Yes
10	26	60	12/Good	12/Fair	75/Fair	Flexion limitation of the knee	No
11	25	135	18/Excellent	27/Excellent	95/Excellent	None	No
12	20	120	14/Good	28/Excellent	95/Excellent	None	No
13	19	110	18/Excellent	25/Good	94/Good	Walking with slight claudication	No
14	19	130	18/Excellent	28/Excellent	90/Good	None	No
15	19	95	18/Excellent	10/Fair	78/Fair	Knee pain after long-distance walking	No
16	18	125	14/Good	29/Excellent	90/Good	Knee pain after strenuous activity	No
17	18	130	18/Excellent	27/Excellent	90/Good	None	No

$\pm 2.76^\circ$  (range 5-14°) and  $86.82 \pm 2.04^\circ$  (range 84-90°) separately. The articular reduction was graded as imperfect (intra-articular step-off > 2mm and lateral condylar width > 5mm) in one patient (5.9%). However, in sixteen patients (94.1%) the articular reduction was graded as satisfactory. (Table 2)

At the final follow-up, the functional rehabilitation of all patients was assessed. The final ROM was  $123.29 \pm 19.70^\circ$  (range 60-142°). The average Rasmussen clinical score was  $25.71 \pm 5.74$  points (range 10-30), and its excellent-good rate was 88.2% (15/17). Additionally, the mean Lysholm score was  $91.47 \pm 6.50$  points (range 75-98), and its excellent-good rate also was 88.2% (15/17). Five patients requested to take out the plates after the fractures healed. When performing the second surgery, there is no neurovascular damage during dissection, and the average surgery interval was  $55.40 \pm 10.95$  min (range 45-70). Generally, fifteen of seventeen patients got satisfactory function outcomes. (Table 3)

Two patients complained of moderate knee pain due to long-distance walking and strenuous activity, which can be relieved after rest. One patient walked with slight claudication and one patient experienced a knee flexion limitation of 60°. No postoperative wound infection or fixation failure occurred. (Table 3)

## DISCUSSION

Posterolateral tibial plateau fracture has gradually been given attention in recent years, and it becomes a hot study point. It is identified as any fracture fragments on the posterolateral quadrant or the fracture line extending to the posterolateral bone cortex, which primarily shows three fracture patterns including split, depression, and split-depression<sup>4,12,13</sup>. Posterolateral tibial plateau fractures have been underestimated and are not well described through the Schatzker classification<sup>9</sup>. At present, the AO/OTA classification system<sup>11</sup> has been widely used in clinical practice and is clear for the description of this special fracture. It classified the posterolateral fracture as partial or B-type(41-B), meanwhile adding a six number in parenthesis to comprehensively describe the posterior articular surface. For instance, 41B1.1(4) represents proximal tibia partial articular split fracture of the lateral plateau on the posterior part in the frontal part, 41B2.2(4) represents proximal tibia partial depression articular fracture of the lateral plateau on the posterior part, 41B3.1(2) represents proximal tibia partial split-depression articular fracture of the lateral plateau on the posterolateral part, and 41B3.1(4) represents proximal

tibia partial split-depression articular fracture of the lateral plateau on the posteromedial part.

For posterolateral tibial plateau fractures, the effect of conservative treatment is limited because the knee joint hardly keeps stable during flexion after injury. Clinically, open reduction and buttressing plate fixation are the primary treatment for this special intra-articular fracture. The anterolateral approach has been widely used for lateral tibial plateau fractures, and gotten satisfactory outcomes<sup>9,10</sup>. Hence, the anterolateral approach was used to fixate fractures of the posterolateral tibial plateau in our study, and its clinical efficacy was demonstrated.

Considering the particularity of the fracture site and the difficulty of its exposure, the surgical approach for the treatment of posterolateral fracture of the tibial plateau maintains controversial<sup>14</sup>. Several authors have proposed posterolateral or posteromedial approaches to treat the posterolateral tibial plateau fracture<sup>1,3,12,15</sup>. The posterior approach can directly expose the fracture fragments, and manipulate fracture reduction as well as plate fixation under direct visualization. Whereas, this surgical approach is correlated with iatrogenic damage risk and complications. The anterior tibial vascular bundle traverses the interosseus membrane to the anterior compartment, about 5 cm (even 2.7 cm) below the joint surface, which limits the distal dissection during the operation<sup>16</sup>. In the popliteal fossa, other structures consist of the popliteal vessel bundle, the tibial nerve, the saphenous nerve, and the common peroneal nerve. These structures may be injured during dissection and exposure of the fracture fragments through the posterior approach. Chang et al.<sup>1</sup> adopted a posterolateral approach to directly expose and buttress plate fixation for eight patients with posterior tibial plateau fractures. However, one patient appeared with peroneal nerve distribution paresthesia postoperatively, and four patients had a flexion lag of 10°-20°. Five patients with bone union required plate removal after two years, whereas the surgical dissection was tedious and time-consuming due to heavy surgery scar formation<sup>6</sup>. The minimum time cost was 1.5 hours for the second operation. Moreover, four patients occurred iatrogenic venous rupture during the dissection, leading to wound hematoma and subsequent healing delay. Yu et al.<sup>3</sup> used the posterolateral approach to fixate the posterolateral fracture of the tibial plateau in fifteen patients. One patient occurred a wound infection, and two occurred knee flexion contractures. The hardware removal was performed on five patients after the fractures healed. However, two of five patients occurred an anterior tibial veins injury during distal dissection. Carlson<sup>17</sup>

used dual incisions through the posterior approach to treat posterior bicondylar fractures of the tibial plateau in five patients. Three patients appeared with transient saphenous nerve sensory deficits, one had a residual anterior subluxation, and one had deep vein thrombosis and superficial wound dehiscence, resulting in knee flexion contracture. Thus, the posterior approach may occur neurovascular damage and complications such as knee flexion contracture for fixating the posterolateral tibial plateau fracture. Furthermore, the prone position of the posterior approach may be difficult to place for patients with multiple injuries, and this position hardly allows fixating other quadrant fractures of the tibial plateau.

Several studies have used the fibular neck osteotomy approach to fixate posterolateral tibial plateau fractures<sup>8,18</sup>. Lobenhoffer et al.<sup>8</sup> and Chen et al.<sup>18</sup> described the posterolateral approach with fibular neck osteotomy and Hu et al.<sup>19</sup> introduced the anterolateral supra-fibular-head approach for sufficient exposure of the posterolateral fracture site. However, these approaches require the common peroneal nerve (CPN) free during operation, which increases the risk of iatrogenic damage to the CPN. Moreover, nonunion or fixation failure of the osteotomy part may occur.

Our study used the anterolateral approach to treat the posterolateral tibial plateau fracture. There are no neurovascular damages during surgery, and the patients got satisfactory function recovery. In the immediate postoperative X-rays, the reduction quality of fractures was satisfactory in all patients. The fracture healed at postoperative  $14.29 \pm 1.53$  weeks (range 12-18). Moreover, they walked at full weight condition, with a mean time of  $15.24 \pm 1.52$  weeks (range 12-18) after surgery. Among seventeen patients, the articular restoration was satisfactory in 16 patients (94.1%) and imperfect in only one patient (5.9%) at the final follow-up. Complications included the following: two patients felt moderate pain in the knee after long-distance walking and strenuous activity separately, which got relief after some rest; one patient walked with slight claudication; one patient experienced a flexion limitation of 60°. For these patients, there were no complaints of these symptoms interfering with their daily life. Rasmussen clinical and Lysholm scores were used to evaluate the functional rehabilitation of patients. The excellent-good rate of Rasmussen clinical score and Lysholm score both were 88.2%.

Though there is a difficulty in the direct reduction of posterolateral tibial plateau fracture under visualization via the anterolateral approach, satisfactory operation field and articular surface reduction can be achieved

through the knee positioned at an appropriate degree of flexion with a varus anterolateral rotation, and extension or hyperextension of the knee<sup>20,21</sup>. Kendal et al.<sup>20</sup> performed a cadaveric study of limb positioning for posterolateral tibial plateau fracture visualization using an anterolateral approach. They found maximal articular surface exposure of the lateral tibial plateau (58.2%, range: 52.9-63.4%) was obtained with the knee positioned at 110 degrees of flexion with a varus anterolateral rotatory vector, which greatly improved the surgery field. In our study, all patients have got a stable articular surface reduction through the anterolateral approach, and articular surface re-collapse has not occurred during follow-up.

Advantages of the anterolateral approach involve the following: (1) the position of the patient is easily placed, which is beneficial to the patient with multiple injuries and other quadrant tibial plateau fractures, not requiring repositioning; (2) cutting the coronary ligament/inframeniscotibial ligament and the joint capsule can directly enter into the knee joint, which can avoid iatrogenic neurovascular damage. (3) the anterolateral approach can avoid the occurrence of knee flexion contracture, which differs from the posterior approach. Studies have clarified that flexion contracture is a risk factor for knee osteoarthritis incidence, worse clinical outcomes, and the necessity of total knee arthroplasty<sup>22,23</sup>. (4) the secondary implant removal after fracture union is easily performed with less time and without the occurrence of neurovascular injury risk. Collectively, this approach deserves prevalence in clinical practice.

However, there are several limitations in this study. Firstly, the essence of a single-center and retrospective study may contribute to the bias of clinical data collection. Secondly, the sample size was relatively small because of the rarity of the fracture pattern.

## CONCLUSION

At present study, the outcomes demonstrated that the anterolateral approach could obtain satisfactory results for surgical treatment of the posterolateral tibial plateau fracture. Moreover, the anterolateral approach has the advantages of relatively easy manipulation, low risk of iatrogenic injury, and low complications. It is an effective and safe surgery method.

*Acknowledgments:* We would like to acknowledge the reviewers for their helpful comments on this paper. Thanks to Dr. Weikai Zhang and Dr. Hui Huang for helping review and revise this paper.

*Conflicts of Interest:* The authors declare they have no financial interests.

*Funding:* This research was funded by the National Health and Family Planning Commission of the People's Republic of China (Grant no. ZX-01-C2016157).

*Authors' Contributions:* Jianwen Li is the first author as well as Weikai Zhang and Hui Huang are the corresponding authors.

## REFERENCES

1. Chang SM, Zheng HP, Li HF, *et al.* Treatment of isolated posterior coronal fracture of the lateral tibial plateau through posterolateral approach for direct exposure and buttress plate fixation. *Arch Orthop Trauma Surg.* 2009; 129: 955-62.
2. Partenheimer A, Gösling T, Müller M, *et al.* [Management of bicondylar fractures of the tibial plateau with unilateral fixed-angle plate fixation]. *Unfallchirurg.* 2007; 110: 675-83.
3. Yu GR, Xia J, Zhou JQ, Yang YF. Low-energy fracture of posterolateral tibial plateau: treatment by a posterolateral prone approach. *J Trauma Acute Care Surg.* 2012; 72: 1416-23.
4. Li Q, Zhang YQ, Chang SM. Posterolateral fragment characteristics in tibial plateau fractures. *Int Orthop.* 2014; 38: 681-2.
5. Júnior MK, Fogagnolo F, Bitar RC, *et al.* TIBIAL PLATEAU FRACTURES. *Rev Bras Ortop.* 2009; 44: 468-74.
6. Huang YG, Chang SM. The posterolateral approach for plating tibial plateau fractures: problems in secondary hardware removal. *Arch Orthop Trauma Surg.* 2012; 132: 733-4.
7. Luo CF, Sun H, Zhang B, Zeng BF. Three-column fixation for complex tibial plateau fractures. *J Orthop Trauma.* 2010; 24: 683-92.
8. Lobenhoffer P, Gerich T, Bertram T, *et al.* [Particular posteromedial and posterolateral approaches for the treatment of tibial head fractures]. *Unfallchirurg.* 1997; 100: 957-67.
9. Schatzker J, McBroom R, Bruce D. The tibial plateau fracture. The Toronto experience 1968-1975. *Clin Orthop Relat Res.* 1979; 94-104.
10. Rossmann M, Fensky F, Ozga AK, *et al.* Tibial plateau fracture: does fracture classification influence the choice of surgical approach? A retrospective multicenter analysis. *Eur J Trauma Emerg Surg.* 2022; 48: 3635-41.
11. Marsh JL, Slongo TF, Agel J, *et al.* Fracture and dislocation classification compendium – 2007: Orthopaedic Trauma Association classification, database and outcomes committee. *J Orthop Trauma.* 2007; 21: S1-133.
12. Chang SM, Hu SJ, Zhang YQ, *et al.* A surgical protocol for bicondylar four-quadrant tibial plateau fractures. *Int Orthop.* 2014; 38: 2559-64.
13. Bernholt DL, DePhillipo NN, Grantham WJ, *et al.* Morphologic Variants of Posterolateral Tibial Plateau Impaction Fractures in the Setting of Primary Anterior Cruciate Ligament Tear. *Am J Sports Med.* 2020; 48: 318-25.
14. Garner MR, Warner SJ, Lorich DG. Surgical Approaches to Posterolateral Tibial Plateau Fractures. *J Knee Surg.* 2016; 29: 12-20.
15. Gavaskar AS, Gopalan H, Tummala NC, Srinivasan P. The extended posterolateral approach for split depression lateral tibial plateau fractures extending into the posterior column: 2 years follow up results of a prospective study. *Injury.* 2016; 47: 1497-500.

16. Heidari N, Lidder S, Grechenig W, Tesch NP, Weinberg AM. The risk of injury to the anterior tibial artery in the posterolateral approach to the tibia plateau: a cadaver study. *J Orthop Trauma*. 2013; 27: 221-5.
17. Carlson DA. Posterior bicondylar tibial plateau fractures. *J Orthop Trauma*. 2005; 19: 73-8.
18. Chen L, Xiong Y, Yan C, *et al*. Fibular Neck Osteotomy Approach in Treatment of Posterolateral Tibial Plateau Fractures: A Retrospective Case Series. *Med Sci Monit*. 2020; 26: e927370.
19. Hu S, Chen S, Chang S, Xiong W, Tuladhar R. Treatment of Isolated Posterolateral Tibial Plateau Fracture with a Horizontal Belt Plate through the Anterolateral Supra-Fibular-Head Approach. *Biomed Res Int*. 2020; 2020: 4186712.
20. Kendal JK, Clark D, Longino D, *et al*. VIS-IT: Visualizing the Injured Tibia-A Cadaveric Study of Limb Positioning for Posterolateral Tibial Plateau Fracture Visualization. *J Knee Surg*. 2020; 33: 132-7.
21. Chen HW, Luo CF. Extended anterolateral approach for treatment of posterolateral tibial plateau fractures improves operative procedure and patient prognosis. *Int J Clin Exp Med*. 2015; 8: 13708-15.
22. Campbell TM, McGonagle D. Flexion contracture is a risk factor for knee osteoarthritis incidence, progression and earlier arthroplasty: Data from the Osteoarthritis Initiative. *Ann Phys Rehabil Med*. 2021; 64: 101439.
23. Ritter MA, Lutgring JD, Davis KE, *et al*. The role of flexion contracture on outcomes in primary total knee arthroplasty. *J Arthroplasty*. 2007; 22: 1092-6.