

The position of the lateral tibial spine and the implications for high tibial osteotomy planning

Wouter VAN GENECHTEN^{1,2,3}, Gino MESTACH³, Yannick VANNESTE³, Annemieke VAN HAVER², Jozef MICHIESEN³, Peter VERDONK^{2,3,4}, Steven CLAES¹

¹Orthopedic department, AZ Herentals, Antwerp, Belgium; ²More institute, Antwerp, Belgium; ³Orthopedic department, University hospital Antwerp, Antwerp, Belgium; ⁴ORTHOCA, Antwerp, Belgium.

Correspondence at: Wouter Van Genechten, Orthopaedic department, University Hospital Antwerp, Belgium, Drie Eikenstraat 655, 2650 Edegem, Belgium, Phone: +32474053731, Email: Wouter.vangenechten22@gmail.com

The lateral tibial spine (LTS) is frequently proposed as a correction target in high tibial osteotomy (HTO), although little is known about its exact radiographic position. This study primarily aims to define the position and variance of the LTS. Secondly, this study wants to investigate the relevance of the LTS position on the mechanical tibiofemoral angle (mTFA°) while planning and postoperatively landing the weight-bearing line (WBL) on this landmark. The LTS position was studied on preoperative full-leg standing radiographs (FLSR) and computed tomography (CT) scans in 70 cases. 3D models of the tibia were created in Mimics 23.0 and measurements were conducted in 3-matic 15.0 (Materialise, Leuven®). Next, 100 HTO cases were retrospectively planned with the WBL through the LTS according to Dugdale's method on FLSR. Finally, 55 postoperative FLSR which had the WBL on the LTS ($\pm 2\%$) were assessed for mTFA° outcome. Statistics were conducted in GraphPad 8.0. The LTS was located at $58.3\% \pm 1.9$ [55-63%] in 2D and $57.3\% \pm 2.2$ [53-63%] in 3D showing a high correlation ($r=0.77$ [0.65 to 0.85]). The planned mTFA on the LTS was $181.8^\circ \pm 0.3$ (181.3° - 182.5°). On postoperative FLSR, the mTFA was $182.2^\circ \pm 0.6$ (180.9° - 183.1°). The lateral tibial spine is located at 57-58% on the tibial plateau with a 10% maximal variation range. Good agreement was found between 2D and 3D imaging modalities while evaluating its position in the coronal plane. When aiming the WBL through the LTS during valgus-producing HTO, a consistent realignment of 181-183° mTFA can be expected when performing accurate surgery.

Keywords: Knee, high tibial osteotomy, planning, target, imaging.

INTRODUCTION

High tibial osteotomy (HTO) is an established joint preserving strategy in the varus aligned lower limb to unload the medial arthritic knee compartment¹. The large majority of HTO procedures is currently planned on full-leg standing radiographs (FLSR) for which the Miniaci or Dugdale planning method is most commonly applied^{2,3}. The target axis on which the final correction should be aimed at, has been a matter of debate until today⁴. Recent osteotomy consensus papers propose an individualized approach based on the indication for knee osteotomy (cartilage procedure, meniscal transplant, isolated medial osteoarthritis (OA)), size of preoperative malalignment and the severity of cartilage damage⁵⁻⁷. Nevertheless, these correction targets are widely ranging from slight varus over neutral realignment towards the so-called Fujisawa point located at 62% or 62.5% of the tibial plateau width^{4,8}. The absence of literature consensus and proper target

guidelines leaves the chosen correction goal in clinical practice often subjected to the individual preference and experience of the surgeon.

Recently, more studies are using the lateral tibial spine (LTS) as an anatomical and radiographical landmark in valgus-producing osteotomy planning. This point is supposed to produce slight overcorrection (valgus) as to the neutral axis⁹⁻¹². Although the position of the LTS was once estimated to correspond with 55% of the tibial plateau (1.7 - 1.9° mechanical tibiofemoral angle (mTFA) valgus)¹⁰, thorough investigations about the position, variability and consequences for osteotomy planning were never performed on a large HTO patient population.

This study primarily aims to define the position and variance of the lateral tibial spine on the tibial plateau by in-person 2D (FLSR) and 3D (CT-scan) modality comparison in order to verify imaging projections of the tibial plateau anatomy. Secondly, the study wants to investigate the relevance of the LTS position on mTFA°

outcome while planning and postoperatively landing the weight-bearing line (WBL) on this landmark.

MATERIALS AND METHODS

A retrospective imaging study was performed by merging existing HTO databases (2016-2020) from two independent orthopedic centers. Local ethical committee approval was obtained in both hospitals to use imaging data for study purposes. Study was performed according to the general protection data regulation (GDPR) guidelines.

Patients who underwent a unilateral medial opening-wedge HTO were extracted from the database on the condition that a valid preoperative FLSR and a preoperative CT-scan of the index knee, taken within one year before surgery, were available. CT-scans were derived from a past prospective 3D HTO study at both orthopaedic centres, earlier approved by the local and university ethical committees. Measurements in the coronal plane included width of the tibial plateau (mm) and position of the lateral spine (mm). Measurements were performed from medial (0%) towards lateral (100%). Absolute values were converted to ratios and expressed as percentages (%) of the tibial plateau.

For 2D measurements, FLSR were first validated based on three criteria: patellar midline alignment, true antero-posterior (AP) view of the ankle joint and 1/3 visibility of the proximal fibula. Medial or lateral osteophyte formation at the tibial plateau borders was cautiously excluded from the tibial plateau width determination. Measurements were conducted in IMPAX 6.6 (Agfa Healthcare, Mortsel, Belgium) or Vue PACS 12.1 (Carestream, Rochester NY, USA) medical imaging software (Figure 1).

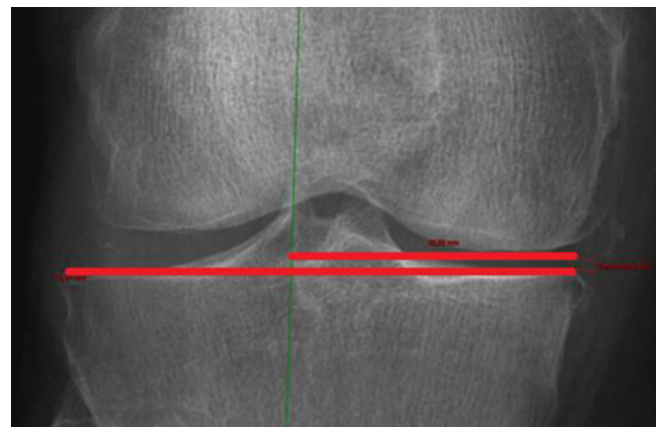


Figure 1. — Two-dimensional (2D) lateral tibial spine ratio measurements (red lines) on full-leg standing radiographs (FLSR). Medial corresponds to 0%.

For 3D measurements, Digital Imaging and Communications in Medicine (DICOM) files from knee CT-scan (0.5-0.8mm slice thickness and spacing) were loaded into the segmentation software Mimics® 23.0 (Materialise, Leuven, Belgium) to separate the femur and tibia from surrounding soft tissue. Segmentation threshold was customized and set to a minimum of 130-200 Hounsfield units (HU) to gain adequate shaping of the tibial plateau (Figure 2). The anatomical 3D model was then studied in 3-matic® 15.0 (Materialise, Leuven, Belgium). First, a projection plane was created aligned with the medial and lateral posterior condyles of the tibial plateau, starting from the distal tibial centre. Next, the tip of the tibial lateral spine was identified and the longest coronal diameter of the tibial plateau (medial-lateral) was determined with exclusion of osteophytes at the plateau borders. The anatomic tibia model with landmarks was projected using the ‘sketch’-tab in which absolute distances were measured (Figure

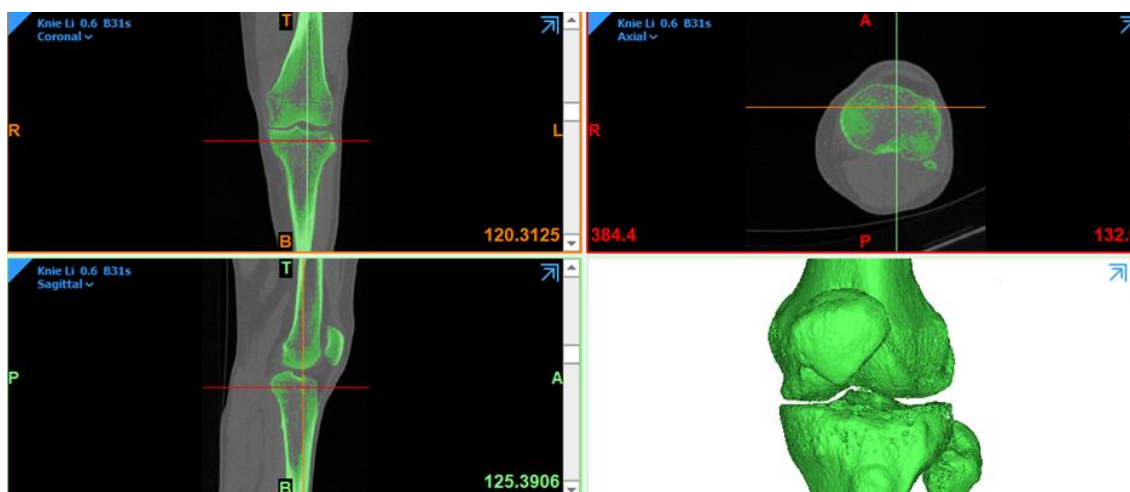


Figure 2. — CT-scan segmentation and 3D modelling of the index knee in Mimics 23.0.

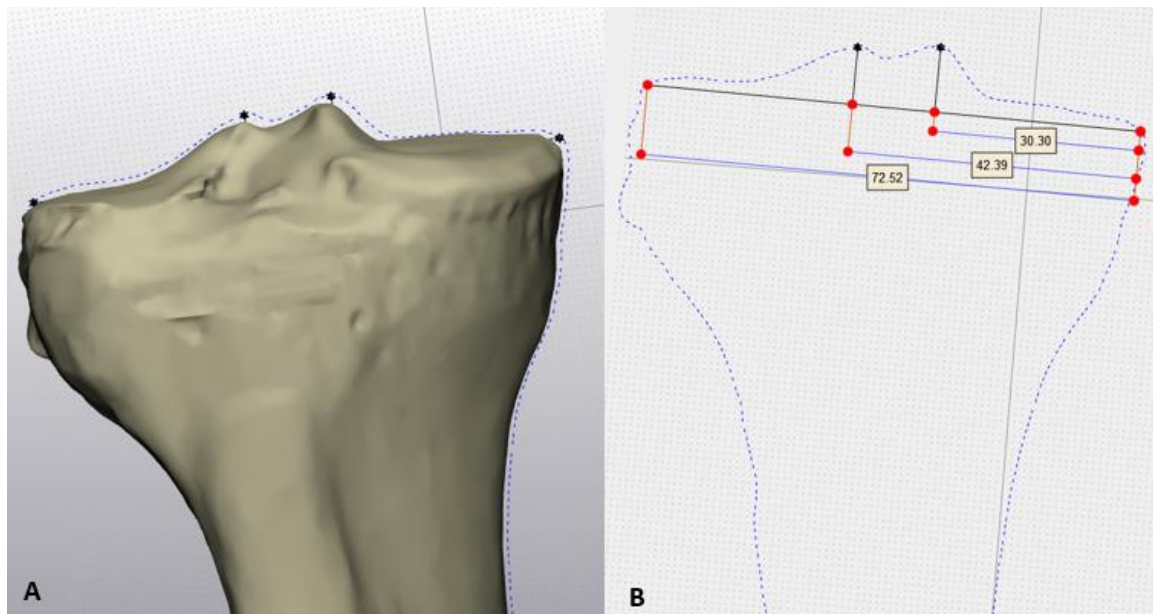


Figure 3. — (A) Three-dimensional (3D) measurement of the tibial spines by using the sketch projection tab in 3-matic 15.0. (B) The square-tool was used to determine the exact position of the spine tip on the tibial plateau width line. Medial corresponds to 0%.

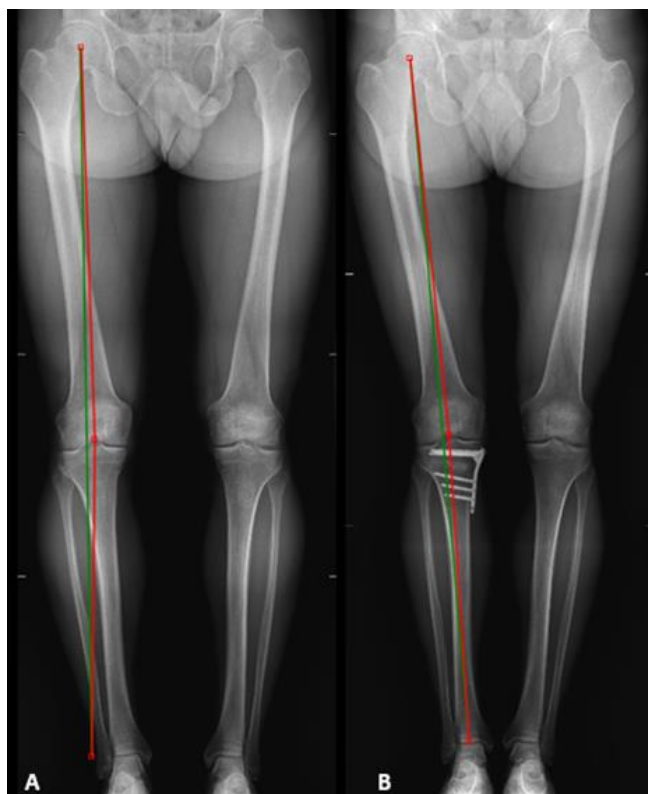


Figure 4. — (A) Planning of the WBL (green) on the LTS with $mTFA^\circ$ (red) determination according to Dugdale's planning method. (B) Postoperative FLSR with the WBL (green) running through the lateral tibial spine and $mTFA^\circ$ (red) measurement.

3a). The square-tool was used to determine the exact position of the lateral spine tip on the tibial plateau width line (Figure 3b).

The HTO database was then screened for unilateral medial opening-wedge HTO with valid preoperative FLSR according to the described criteria, but without preoperative 3D imaging. The first 100 eligible cases (database 04/2016 to 04/2017) were included and measurements were performed on FLSR in IMPAX 6.6 (Agfa Healthcare, Mortsel, Belgium). Again, width of the tibial plateau (mm) and position of the LTS (mm) were determined. Next, the WBL was drawn from the hip centre crossing the LTS and ending at the floor. The planned $mTFA^\circ$ was then measured as described by Dugdale et al.² (Figure 4a). Correlation between LTS position and $mTFA^\circ$ was determined.

The HTO database was finally reviewed for cases with a valid 3 month postoperative FLSR and having the WBL crossing the lateral tibial spine ($\pm 2\%$) (Figure 4b). The width of the tibial plateau (mm), the position of the LTS (mm) and the WBL (%) were measured on postoperative FLSR in IMPAX 6.6 (Agfa Healthcare, Mortsel, Belgium) and correlated with the postoperative $mTFA^\circ$ to verify the planning outcomes on the LTS.

All imaging measurements were performed once by two blinded observers (orthopaedic residents). As final outcome, the average of both measuring points was calculated. Descriptive statistics were outlined as mean, standard deviation (SD), minimum and maximum. Outliers were removed for final analysis according to the extreme studentized deviate method (Grubbs' test). Normalized data distribution was determined by the D'Agostino's and Pearson omnibus normality test. The intraclass correlation coefficient

Table I. — Overview of the radiological outcomes (mean±SD (min-max)) with respective interobserver reliability *r* [95% CI].

Parameter	Imaging modality	Outcome	Interobserver reliability <i>r</i> [95% CI]
Lateral tibial spine position (n=70)			
LTS (%)	2D (FLSR)	58.3%±1.9 (55-63)	0,84 [0.75-0.89]
	3D (CT-scan)	57.3%±2.2 (53-63)	0,91 [0.85-0.94]
Planning on lateral tibial spine (n=99)			
WBL on LTS (%)	2D (FLSR)	58.4%±1.7 (54-63)	0,90 [0.86-0.94]
mFTA°	2D (FLSR)	181.8°±0.3 (181.3-182.5)	0.67 [0.55-0.77]
Landing on lateral tibial spine (n=55)			
WBL on LTS (%)	2D (FLSR)	58.6%±1.7 (55-63.5)	0.64 [0.42-0.79]
mFTA°	2D (FLSR)	182.2°±0.6 (180.9-183.1)	0.76 [0.60-0.86]

LTS, lateral tibial spine; WBL, weight-bearing line; mFTA°, mechanical femorotibial angle (°); FLSR, full-leg standing radiograph.

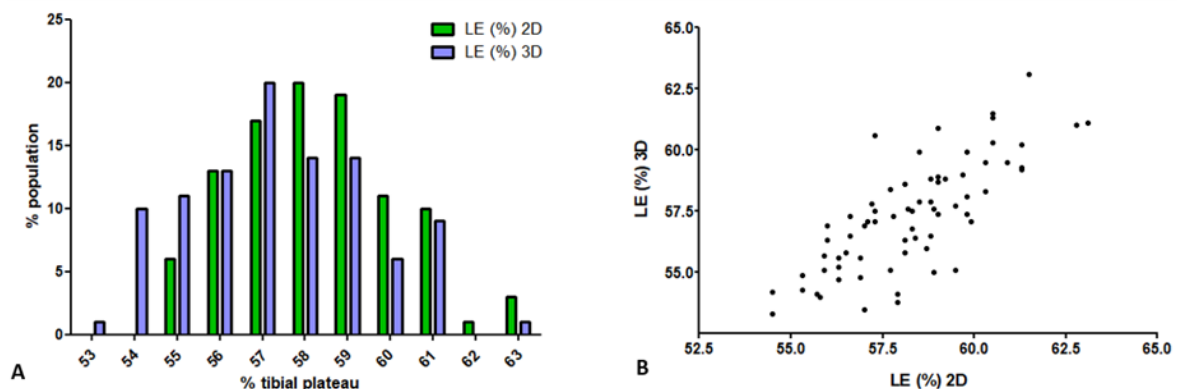


Figure 5. — (A) Lateral tibial spine positioning and distribution on the tibial plateau by 2D and 3D comparison. (B) Correlation outcomes of the lateral tibial spine location for 2D and 3D imaging modalities ($r=0.77$ (0.65 - 0.85) – $p<0.001$).

(ICC) ‘*r*’ with [95% confidence interval (CI)] and the interobserver reliability were analyzed by the Pearson or Spearman test, depending on presence of normal distribution. Significance level alpha was set at 0.05. All statistical tests were conducted in GraphPad Prism version 8.0.0 for Windows (GraphPad Software, San Diego, California USA, www.graphpad.com)

RESULTS

Seventy HTO subjects (aged 45.5y±12.0, 84% male, 100% Caucasian, 51% right side) were found to have both a valid preoperative FLSR and preoperative CT-scan of the index knee. The LTS was located at 58.3%±1.9 (55-63) in 2D and 57.3%±2.2 (53-63) in 3D (Table I) showing a good correlation ($r=0.77$ [0.65-0.85]) (Figure 5a/b).

Analysis of the first 100 HTO subjects (aged 53.4y±10.6, 70% male, 100% Caucasian, 46% right side) showed a LTS position of 58.4%±1.7 (54-63). One case was found to be an outlier (LTS of 64.8%) and consequently excluded. The planned mFTA was

181.8°±0.3 (181.3°-182.5°) (Table I). A moderate degree of correlation existed between LTS position and planned mFTA° ($r=0.53$ [0.37-0.66]) – $p<0.001$) (Figure 6a).

Fifty-five subjects (aged 54.0y±9.4, 80% male, 100% Caucasian, 49% right side) were found to have a valid postoperative FLSR with the WBL crossing the lateral tibial spine (±2%) after HTO surgery. The postoperative WBL was 58.6%±1.7 (55-63.5%) with a corresponding postoperative mFTA° of 182.2°±0.6 (180.9°-183.1°) (Table I). The correlation ($r=0.36$ [0.11-0.57]) – $p=0.007$) between both parameters was considered weak (Figure 6b).

DISCUSSION

Nowadays, the lateral tibial spine is frequently proposed as a correction target in HTO, although little is known about the exact radiographic position and variance with respect to preoperative osteotomy planning. This study revealed that the LTS is located at 57-58% on the tibial plateau showing a 10% maximal variation range

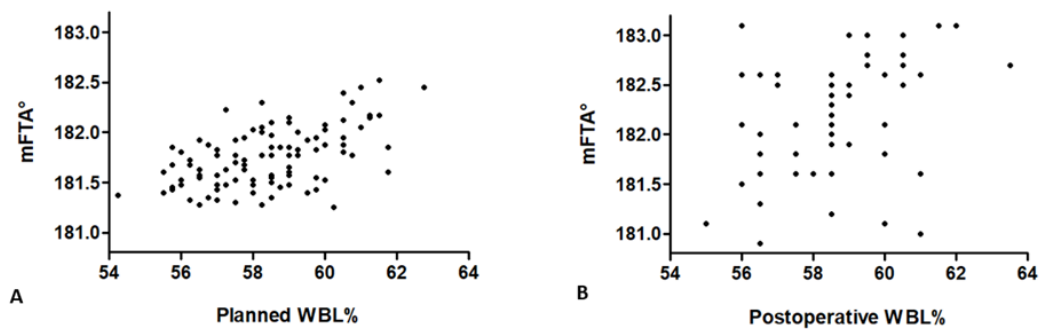


Figure 6. — Correlation outcomes respectively of the (A) planned and (B) postoperative WBL% with the mFTA° while aiming for the lateral spine on the tibial plateau. ((A) $r=0.53$ [0.37–0.66] – $p<0.001$ and (B) $r=0.36$ [0.11–0.57] – $p=0.007$).

around its average position (54-63%). The 2D with 3D correlation was good ($r=0.77$) with a difference of 1% on 2D (58.3%) relative to 3D (57.3%) measurements. Further, planning the WBL on a FLSR through the lateral tibial spine yielded a $181.8^{\circ}\pm 0.3$ (181.3° - 182.5°) mTFA valgus correction as was confirmed by the postoperative realignment outcomes ($182.2^{\circ}\pm 0.6$ (180.9° - 183.1°) mTFA).

The Fujisawa-point at 62,5% has historically been proposed as the benchmark target in valgus-producing osteotomy planning⁸. Lately, some authors and surgeons are advocating the LTS as correction target⁹⁻¹¹, potentially because of apprehension to overcorrection. This might result in esthetically inferior results and aberrant gait patterns while risking to overload the lateral compartment¹⁰, the onset of patellofemoral symptoms¹³ and increased coronal inclination (excessive MPTA and joint line obliquity)^{14,15}. The general tendency of slight under-correction relative to the planning seems therefore more desirable compared to definitive overcorrection⁴. Nevertheless, Sung-Sahn Lee et al. (2020) demonstrated similar short-term clinical outcomes (< 2 year) between aiming for the LTS or for the Fujisawa point (62-62.5%)¹². After all, the slight difference in obtained correction might be subtle and only become relevant in certain individuals or in long-term outcomes.

An important finding of this study is that the common assumption that the LTS has a fixed position on the tibial plateau is false. A surprisingly large variation of 10% was observed for the LTS position (54-63%). Moreover, in 4% of 2D cases, the LTS was coinciding with the Fujisawa point at 62-63% of the tibial plateau⁸. Therefore, while planning a (valgus-producing) HTO on FLSR, surgeons should be aware of the average LTS position (57-58%) and its substantial variation present in the described Caucasian HTO population. Noteworthy is the study by Van de Pol et al. which aimed the intraoperative WBL crossing the LTS and

correctly estimated its position on 58%, as shown by our data¹¹. However, they anticipated a spontaneous postoperative correction increase towards valgus after weightbearing, resulting in a final WBL realignment of 62.5% or 3° mTFA¹¹. On the other hand, Martay et al. corresponded the apex of the LTS with 55% (1.7 - 1.9° mTFA valgus) on the tibial plateau¹⁰. In line with these results, Tripon et al. recently found an average LTS position of 54% on 3D models from different ethnicities¹⁶. Although a similar variation of 10% (48.9-57.2%) was found, its average position is contrasting our results that showed that the LTS was located beyond 54% on the tibial plateau in 90% ($n=60/70$) using 3D model projection. Reasons for discrepancy however have not been found. Exactly in line with our results is the study by Xu Jiang et al. which showed a $57.7\%\pm 2.1$ position of the LTS top¹⁷. Planning realignment surgery with the WBL on the LTS yielded $182.1^{\circ}\pm 0.5$ mTFA in their Chinese population compared to $181.8^{\circ}\pm 0.3$ in our study on Caucasians. The similarity of LTS position among ethnicities, as suggested by Tripon et al., seems therefore confirmed¹⁶.

Further, the current study found a good correlation ($r=0.77$) for the LTS location comparing FLSR with 3D CT-scan reconstruction. Considering 3D measurements as more precise, the average LTS on 2D was found to be located exactly 1% further on the tibial plateau (58.3%). In general, this comparison confirms that the individual 3D anatomy of the tibial plateau is well-projected on a valid FLSR, which makes this imaging modality suitable for knee osteotomy planning. Still, attention should be paid to patient setup during FLSR, as clinically relevant measurement errors occur once exceeding $>9^{\circ}$ of limb rotation that worsen in combination with $>15^{\circ}$ of knee flexion¹⁸.

Osteotomy planning with the WBL through the LTS corresponded to $181.8^{\circ}\pm 0.3$ (181.3° - 182.5°) mTFA. Postoperative realignment outcomes with the WBL on the LTS ($\pm 2\%$) were confirming the expected 1-3°

valgus correction as a reliable interval. A systematic review by Van den Bempt et al. found that the overlapping correction target considered 'acceptable' for all included HTO studies was 2-3° valgus⁴. In addition, Heijens et al. earlier described a 2° valgus threshold (coronal hypomochlion) after which the joint line convergence angle (JLCA) makes a linear decrease (the point after which the medial compartment gets radiographically 'unloaded')¹⁹. His team proposed an ideal correction between 2-5° valgus based on JLCA changes. However, current evidence by finite element analyses about optimal load redistribution between a diseased medial and healthy lateral knee compartment is inconclusive²⁰⁻²². In a preliminary model, Martay et al. estimated the ideal balance at 55% (1.7°-1.9° mechanical valgus) while Zheng et al. showed balanced loading at 4.3° valgus for the femoral and 2.9° for the tibial cartilage^{20,21}. According to Trad et al., this point should even be located at 4.5° of valgus which seems to interfere with the clinical consequences of overcorrected osteotomies²².

The authors are aware that observer bias might be a potential concern in radiological studies. Therefore, all measurements were conducted by two blinded observers showing good IOC agreement (Table I). In brief, this study provides fundamental knowledge about the lateral spine position on the tibial plateau in a Caucasian HTO patient population. The implications for HTO planning are in the 10% variation range of the LTS position, which corresponds to an individual planned and postoperative realignment of 1-3° valgus.

CONCLUSION

The lateral tibial spine is located at 57-58% with a 10% maximal variation range on the tibial plateau. Good agreement was found between 2D and 3D imaging modalities while evaluating its position in the coronal plane. When aiming the WBL through the lateral tibial spine during valgus-producing HTO on full-leg standing radiographs, a consistent realignment of 181-183° mTFA can be expected when performing accurate surgery.

Funding: This research did not receive any specific grant from funding agencies in the public, commercial, or not-for-profit sectors.

Acknowledgement: None.

Conflict of interest: None declared.

REFERENCES

1. Coventry mb. Osteotomy of the upper portion of the tibia for degenerative arthritis of the knee. A preliminary report. *J Bone Joint Surg Am* [Internet]. 1965 Jul;47(47):984-90. Available from: <http://www.ncbi.nlm.nih.gov/pubmed/14318636>
2. Dugdale T, Noyes F, Styer D. Preoperative planning for high tibial osteotomy. The effect of lateral tibiofemoral separation and tibiofemoral length. *Clin Orthop*. 1992;(274):248-64.
3. Elson DW, Petheram TG, Dawson MJ. High reliability in digital planning of medial opening wedge high tibial osteotomy, using Miniaci's method. *Knee Surg Sports Traumatol Arthrosc*. 2015;23(7):2041-8.
4. Van den Bempt M, Van Genechten W, Claes T, Claes S. How accurately does high tibial osteotomy correct the mechanical axis of an arthritic varus knee? A systematic review. *Knee* [Internet]. 2016;23(6):925-35. Available from: <http://dx.doi.org/10.1016/j.knee.2016.10.001>
5. Snow M, Jermain P, Mandalia V, Murray J, Khakha R, McNicholas M, et al. A 2021 consensus statement on osteotomies around the knee by the UK Knee Osteotomy consensus Group (KOG). *Knee* [Internet]. 2021;33(December):73-83. Available from: <https://doi.org/10.1016/j.knee.2021.08.034>
6. Dawson MJ, Ollivier M, Menetrey J, Beaufils P. Osteotomy around the painful degenerative varus knee: a 2022 ESSKA formal consensus. *Knee Surg Sports Traumatol Arthrosc* [Internet]. 2022;(0123456789):1-3. Available from: <https://doi.org/10.1007/s00167-022-07024-0>
7. Feucht MJ, Minzlaff P, Saier T, Cotic M, S??dkamp NP, Niemeyer P, et al. Degree of axis correction in valgus high tibial osteotomy: proposal of an individualised approach. *Int Orthop*. 2014;38(11):2273-80.
8. Fujisawa Y, Masuhara K, Shiomi S. The effect of high tibial osteotomy on osteoarthritis of the knee. An arthroscopic study of 54 knee joints. *Orthop Clin North Am* [Internet]. 1979 Jul;10(3):585-608. Available from: <http://www.ncbi.nlm.nih.gov/pubmed/460834>
9. Van Genechten W, Van den Bempt M, Van Tilborg W, Bartholomeeusen S, Van Den Bogaert G, Claes T, et al. Structural allograft impaction enables fast rehabilitation in opening-wedge high tibial osteotomy: a consecutive case series with one year follow-up. *Knee Surg Sports Traumatol Arthrosc* [Internet]. 2020;28(12):3747-57. Available from: <https://doi.org/10.1007/s00167-019-05765-z>
10. Martay JL, Palmer AJ, Bangerter NK, Clare S, Monk AP, Brown CP, et al. A preliminary modeling investigation into the safe correction zone for high tibial osteotomy. *Knee* [Internet]. 2018 Mar;25(2):286-95. Available from: <http://www.ncbi.nlm.nih.gov/pubmed/29395747>
11. van de Pol GJ, Verdonschot N, van Kampen A. The value of the intra-operative clinical mechanical axis measurement in open-wedge valgus high tibial osteotomies. *Knee*. 2012;19(6):933-8.
12. Lee SS, Lee H II, Cho ST, Cho JH. Comparison of the outcomes between two different target points after open wedge high tibial osteotomy: The Fujisawa point versus the lateral tibial spine. *Knee* [Internet]. 2020;27(3):915-22. Available from: <https://doi.org/10.1016/j.knee.2020.01.007>
13. Lee SS, So SY, Jung EY, Kim HJ, Lee BH, Wang JH. Predictive Factors for Patellofemoral Degenerative Progression After Opening-Wedge High Tibial Osteotomy. *Arthroscopy* [Internet]. 2019;35(6):1703-10. Available from: <https://doi.org/10.1016/j.arthro.2019.01.032>
14. Akamatsu Y, Kumagai K, Kobayashi H, Tsuji M, Saito T. Effect of Increased Coronal Inclination of the Tibial Plateau After Opening-Wedge High Tibial Osteotomy. *Arthroscopy* [Internet]. 2018;34(7):2158-2169.e2. Available from: <https://doi.org/10.1016/j.arthro.2018.01.055>

15. Nakayama H, Schröter S, Yamamoto C, Iseki T, Kanto R, Kurosaka K, et al. Large correction in opening wedge high tibial osteotomy with resultant joint-line obliquity induces excessive shear stress on the articular cartilage. *Knee Surg Sports Traumatol Arthrosc.* 2018;26(6):1873-8.
16. Tripon M, Sautet P, Argenson J, Jacquet C, Martz P, Ollivier M. Is the lateral tibial spine a reliable landmark for planning tibial or femoral valgus osteotomies ? *Orthop Traumatol Surg Res.* 2022;108:1-5.
17. Jiang X, Li B, Xie K, Ai S, Hu X, Gao L, et al. Lateral tibial intercondylar eminence is a reliable reference for alignment correction in high tibial osteotomy. *Knee Surg Sports Traumatol Arthrosc.* 2021;Online ahe.
18. Nguyen HC, Gielis WP, van Egmond N, Weinans H, Slump CH, Sakkers RJB, et al. The need for a standardized whole leg radiograph guideline: The effects of knee flexion, leg rotation, and X-ray beam height. *J Cartil Jt Preserv [Internet].* 2021;1(3):100022. Available from: <https://doi.org/10.1016/j.jcjp.2021.100022>
19. Heijens E, Kornherr P, Meister C. The coronal hypomochlion: A tipping point of clinical relevance when planning valgus producing high tibial osteotomies. *Bone Joint J.* 2016;98(5):628-33.
20. Martay JL, Palmer AJ, Bangerter NK, Clare S, Monk AP, Brown CP, et al. A preliminary modeling investigation into the safe correction zone for high tibial osteotomy. *Knee [Internet].* 2018;25(2):286-95. Available from: <https://doi.org/10.1016/j.knee.2017.12.006>
21. Zheng K, Scholes CJ, Chen J, Parker D, Li Q. Multiobjective optimization of cartilage stress for non-invasive, patient-specific recommendations of high tibial osteotomy correction angle - a novel method to investigate alignment correction. *Med Eng Phys.* 2017;42:26-34.
22. Trad Z, Barkaoui A, Chafra M, Tavares JMR. Finite element analysis of the effect of high tibial osteotomy correction angle on articular cartilage loading. *J Eng Med.* 2018;232(6):553-64.