

Primary trapeziectomy with Regjoint™, a poly-L/D-lactide spacer, a two-year follow-up study with new radiological assessment tool

Svetlana BOGAERT¹, Nicolas CUYLITS², Konstantinos DROSSOS², Anne LEJEUNE², Monika TOOULOU³, Nader CHAHIDI²

¹Erasme Hospital, Brussels, Belgium; ²Centre médical du Parc, Hand surgery department, Brussels, Belgium; ³CHU Charleroi, Charleroi, Belgium.

Correspondence at: Bogaert Svetlana, Avenue Ptolémée, 14, 1180 Brussels, Belgium, Phone: 00 32 477498640, Email: bogaertsvelana@gmail.com

The aim of this retrospective study was to evaluate the potential bony erosion and the clinical and radiological results of primary trapeziectomy with Regjoint™ interposition, in patients with peritrapezial arthritis. Data were recorded on twenty patients over a period of two years (January 2015-December 2016). On average 24 months, patients were reconvened for a post-operative evaluation (subjective evaluation of pain, function and patient satisfaction; clinical evaluation with strength and mobility measures; post-operative X-rays). On X-rays, 2 criteria were evaluated: the bony erosion and the shortening of the thumb column (trapezium+metacarpal height measure, ratio between first and second metacarpal bones, a new radiological assessment tool based on a trapezoid relationship gradation). In most patients, surgery relieved pain and offered good functional results, according to the Quick Disabilities of the Arm, Shoulder and Hand scale. Following surgery, our patients showed a subjective improvement, both in terms of pain and functional results. For plain X-ray, only 3 patients showed an osteolytic lesion (maximum of 2.8 millimeters) on the first metacarpal base. A statistically significant reduction in the thumb column height was generally observed on follow-up X-rays. However, all of these radiologic changes were present without any clinical impact. We show that the Regjoint™ spacer is an available alternative in the surgical treatment of peritrapezial arthritis. We did not highlight any significant associated complications, no important adverse tissue reaction or bone erosion, no pain or functional disorder.

Type of study/level of evidence Therapeutic IV.

Keywords: Poly-L/D-lactide (PLDLA),osteoarthritis, trapezometacarpal, trapeziectomy, thumb.

INTRODUCTION

Trapeziometacarpal joint (TM CJ) osteoarthritis is a common and disabling pathology, most frequently occurring in the fifth decade of life, to peri- and postmenopausal women¹⁻⁴.

In the first line of treatment, most patients can be relieved, but not cured, via conservative therapies. When symptoms become disabling and refractory, several surgical options can be proposed such as: simple trapeziectomy^{5,8}; trapeziectomy with interposition^{5,7}, ligament reconstruction^{5,8} or suspension^{1,5}; total joint replacement arthroplasty^{9,10} or arthrodesis^{5,11,12}. The gold standard treatment remains simple trapeziectomy^{10,13}.

At our centre, the primary treatment choice is total joint replacement. When TM CJ or scapho-trapezotrapezoidal joint (STTJ) arthritis is severe, or in cases of loss of trapezium height, a trapeziectomy is proposed to our symptomatic patients. The main complication of trapeziectomy is the shortening of the thumb

column by proximal migration of the first metacarpal bone. This situation may lead to a weakening of thumb opposition^{7,14,15}, to painful scaphometacarpal conflict and Z deformity. To avoid this, the addition of ligamentous suspension or several interpositions are proposed. Regarding the interposition, the spacer can be biological^{18,16,17} or synthetic^{18,19,20,21,29}.

The trapeziectomy with ligamentous reconstruction and/or interposition did not show any superiority and can demonstrate (depending on the studies) a higher rate of complication^{5,23-25}.

No synthetic implants obtained totally satisfactory results^{5,7,26} and the possibility of complications (reactive synovitis or osteolysis, foreign body reaction, subluxation) remains the main reason why synthetic implant interpositions were not the treatment of choice in the majority of reviews⁵.

The Regjoint™ spacer (Scaffdex, Tampere, Finland) is a porous bioresorbable poly-L/D-lactide copolymer, with an L-D monomer content of 96%-4% respectively

(PLDLA 96/4). With a relatively rapid absorption time (in human hands)²⁷, this interposition functions as a temporary porous spacer, facilitating scar tissue ingrowth and development of a dense fibrous pseudarthrosis in the articular space, without leaving any foreign material behind (as shown on experimental studies)^{28,29}. Histologically, in human hands, there is an infiltration of the spacer by fibroblasts, followed by a capsular formation and finally the development of a fibrous tissue up to the centre of the spacer. After one year, rare PLDLA fibres are still present and the resorption is complete after three years²⁷. The original spacer composition was an L-D monomer level of 70%-30% causing an inflammatory reaction with osteolysis. This complication was avoided by changing the L-D monomer level ratio to 96%-4%^{28,29,30}.

This study focused on the evaluation of potential bone erosion and assesses the efficiency and safety of trapeziectomy with Regjoint™ interposition in cases of peritrapezial arthritis. The aim was to evaluate the results of the Regjoint™ spacer.

MATERIALS AND METHODS

Between January 2015 and December 2016, we performed a retrospective review of patients with confirmed radiological signs of major TMCJ osteoarthritis associated with major STTJ arthritis or loss of trapezium height (not eligible for total TMCJ prosthesis replacement), managed by total trapeziectomy with Regjoint™ (PLDLA 96/4) interposition.

Inclusion criteria were: primary trapeziectomy with Rejoint™ interposition and follow-up equal to or greater than one year.

Exclusion criteria were: a follow-up of less than 12 months and patients with prior TMC and STT joints operations.

We identified 23 patients who underwent Regjoint™ surgery, with at least 12 months follow-up. Three patients were excluded from the study because they underwent a secondary trapeziectomy for total implant arthroplasty revision.

The twenty patients (22 thumbs) finally included in the study were reconvened for a clinic visit during which we took our different measurements.

The surgical technique was standardised and performed by five experienced hand surgeons.

An arcuate dorsal incision was made over trapezium bone. The skin and subcutaneous structures were retracted. The dissection was proceeding between the extensor pollicis longus and the extensor pollicis brevis. When the TMCJ was exposed, we performed

a H aperture in the articular capsule. The trapezium was fragmented and the fragments were removed with gouge pliers. We completed the resection by the ablation of all internal osteophytes. The Regjoint™ spacer was placed and fixed with two PDS 4-0 stitches on the palmar and radial capsule.

In order to maintain the thumb in opposition and the space between the scaphoid and the first metacarpal base, two subcutaneous K wires of 1,5 mm were placed transversally under fluoroscopic control between the first and the second metacarpal bones.

A Manovac drain was placed in the trapeziectomy site and capsular closure was performing with PDS 4-0. Nylon 5-0 was used for the cutaneous closure suture.

A wrist and thumb cast was worn for three weeks.

The K wires were removed four weeks later and physiotherapy commenced for 18 sessions. The progressive resumption of activities began from the sixth postoperative week and activities without restrictions started on average after two months.

The patients were reconvened for a clinical evaluation on average 24 months (12 to 62 months). We have chosen a minimal one-year follow-up because, theoretically, the spacer is absorbed at this time²⁷⁻³⁰. The same doctor performed a subjective evaluation of pain, function, patient satisfaction and a clinical evaluation (strength and mobility measurements). The pain was evaluated by gradation with the visual analogue scale (VAS) and by the presence or absence of subjective decrease (yes/no question). The functional evaluation was performed by the Quick Disability of the Arm, Shoulder and Hand (Quick DASH) scale³¹ and by the presence or absence of subjective improvement (yes/no question). A satisfaction evaluation (score between zero (total dissatisfaction) and ten (optimal satisfaction)) of their experiences was performed and the patients were requested to respond if they would have the same operation again. The impact on strength was measured by a grip strength evaluation using the Jamar dynamometer and by measuring the opposition strength (key and tip) using a mechanical Pinch Gauge. Mobility was measured for opposition movements (by Kapandji scale³²), palmar and radial thumb abductions and flexion/extension movements of metacarpophalangeal (MCP) joint (using a goniometer). When the thumb was fully abducted, the thumb palmar and radial abductions were measured as the angle between the thumb axis and the index finger axis.

For the 18 patients with an unilateral operation, our measurements were compared to the contralateral non-operated hand. The two other patients, who had sequential bilateral surgery, were excluded from these

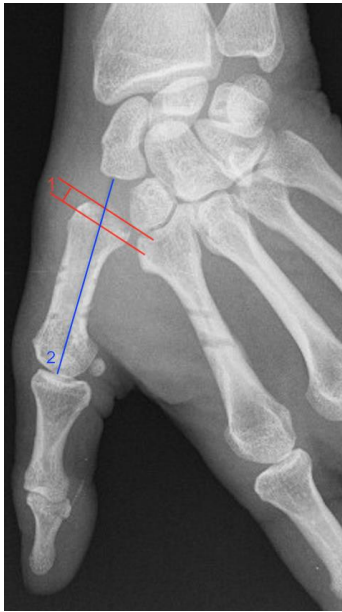

Figure 1. — Radiographic measurements.
1: Erosion cavity measurement.
2: Trapezium + metacarpal (TMC) height measurement.

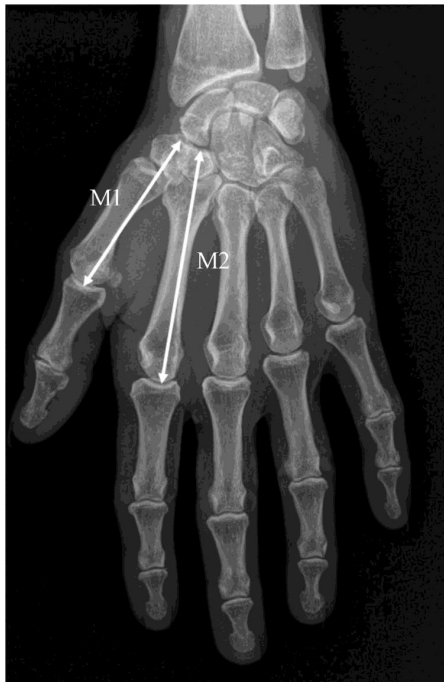

Figure 2. Ratio M1/M2
M1 = distal scaphoid surface to 1er metacarpal distal surface. M2 = distal scaphoid surface to 2nd metacarpal distal surface). Reproduced with the kind permission of Pascal Ledoux (Ledoux P. M1/M2 ratio for radiological follow-up of trapeziometacarpal surgery. *Hand Surg Rehabil.* 2017;36:146-147).

comparisons but the average measurements of strength and mobility were still performed on the 20 patients (22 thumbs). Due to a lack of preoperative data, comparison with preoperative values was not possible.

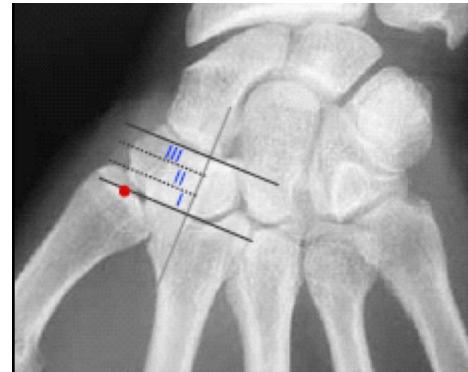


Figure 3. Trapezoid relationship gradation for collapse.
New tool for the evaluation of the thumb column proximal migration. Grade 1: projection at the distal third of the trapezoid. Grade 2: projection at the middle third of the trapezoid. Grade 3: projection at the proximal third of the trapezoid.

Possible clinical adverse events were also recorded.

The radiological measurements were made on pre and postoperative X-rays to realise our comparisons. The postoperative X-rays was performed at the moment of the study postoperative clinical evaluation (24 months). The X-rays included anteroposterior, profile and oblique (3/4) plain views³.

Two criteria were evaluated: the bony erosion and the shortening of the thumb column.

The metacarpal erosion was quantified by measuring the height of erosion cavity on the profile view (distance in millimeters between the borders and the centrum of proximal metacarpal surface) (Figure 1).

The osteolysis of the carpal bones was also investigated, on plain xray.

- The first measurement used to evaluate thumb shortening, in comparison to the preoperative measurement, was the trapezium + metacarpal (TMC) height (Figure 1). It was defined as the distance (in millimeters) between the distal surface of the scaphoid and the distal surface of the first metacarpal bone on the profile view.
- The ratio M1/M2 was secondly used to evaluate the thumb column height (Figure 2)³³. This ratio is independent of radiographic conditions and concomitant presence of other diseases in the hand and wrist. The mesures were made on the posteroanterior view. M1 was defined as the distance between the distal scaphoid surface and the first metacarpal distal surface. M2 was measured as the distance from the distal scaphoid surface to the second metacarpal distal surface.
- In an attempt to further assess metacarpal proximal migration, a new radiological assessment tool,

based on a trapezoid relationship gradation, was designed. Regarding anteroposterior X-ray, three grades were defined according to the metacarpal base position relating to the different thirds of trapezoidal bone. The trapezoidal bone is divided into three thirds (three lines perpendicular to the trapezoidal axis) and the position of the base center of first metacarpal bone was noted according to the first, the second or the third third (Figure 3). A reduction of the trapezial space (collapse) (by arthritic changes or trapeziectomy) was defined as a grade two or three.

Radiographic pre and postoperative comparisons were made only with paired data. The radiographic averages measures (seen before) were calculated with all X-rays available (some preoperative xray were missing).

A D'Agostino & Pearson normality test was systematically performed for continuous variables. When normality was assessed, a paired t student test was used to analyse the inter-group comparisons. When the data was not considered parametric, a Wilcoxon matched-pairs signed rank test was used instead. For non-continuous variables, proportions were compared using a Chi-square test. If the p-value was inferior to 0.05, the differences were considered statistically significant.

RESULTS

Our final study population consisted of 20 patients with primary TMCJ arthritis (17 females, three males). The age ranged from 52 to 80 years old, with an average age of 67. 18 patients were right-handed and two were left-handed.

Table I. — Strengths evaluation.

	Postoperative average strenght*	Opposite hand average strenght*	P value**
GRIP (kg)	18 (6-38)	17 (0-36)	0,9465 (NS)
KEY PINCH (kg)	5 (2-9)	6 (2-11)	0,3296 (NS)
TIP PINCH (kg)	4 (0-6)	4 (0-7)	0,3108 (NS)

NS: non-significant / S : significantly different (p<0,005). kg: kilograms. * Mean values and range of values made on the 20 patients (22 thumb), including the bilateral surgery. **Statistical paired inter-group comparisons were made by a t student test on the 18 patients in whom an unilateral operation was performed.

Table II. — Mobilities evaluation.

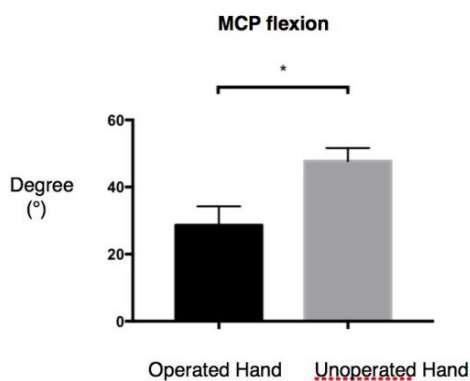
	Postoperative average mobility*	Opposite hand average mobility*	P value**
MCP EXTENSION (deg)	-20 (-55-20)	-21 (-45-0)	0,7865 (NS)
MCP FLEXION (deg)	32 (0-55)	44 (20-65)	0,0256 (S)
KAPANDJI (/10)	9 (7-10)	10 (9-10)	0,0312 (S)
PALMAR ABDUCTION (deg)	55 (40-85)	58 (45-75)	0,2385 (NS)
RADIAL ABDUCTION (deg)	62 (45-100)	68 (45-130)	0,3438 (NS)

NS: non-significant / S: significantly different (p<0,005). Deg: degree. MCP: metacarpophalangeal. * Mean values and range of values made on the 20 patients (22 thumb), including the bilateral surgery. **Statistical paired inter-group comparisons by a t student test (MCP extension/flexion, abductions,) and Wilcoxon matched-pairs signed rank test (Kapandji) were made on the 18 patients in whom an unilateral operation was performed.

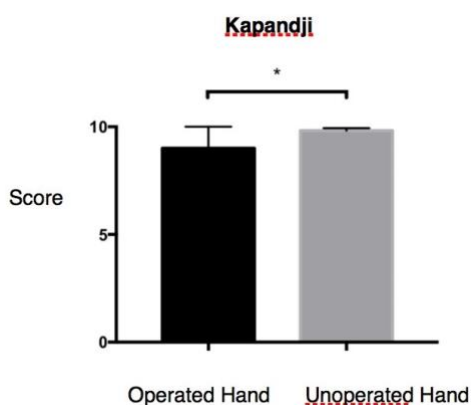
Table III. — Radiological evaluation.

	Preoperative average*	Postoperative average*	P value**
TMC HEIGHT (mm)	56 (49-65)	48 (42-60)	< 0,001 (NS)
M1/M2	0,67 (0,62-0,75)	0,63 (0,55-0,71)	0,0263 (S)
MC HEIGHT (mm)	45 (40-52)	44 (38-50)	0,511 (NS)
MC EROSION (mm)	0.3 (0-5)	0,2 (0-2,8)	0,8437 (NS)
P1 SUBLUXATION (mm)	4 (0-8)	0 (0-5)	0,0001 (S)

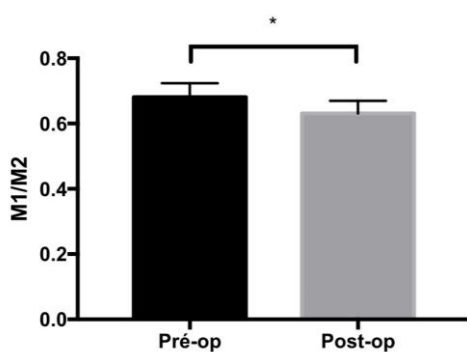
NS: non-significant / S : significantly different (p<0,005). mm: millimetres. TMC: trapezo-metacarpal. MC: metacarpal. P1: first phalanx. * Mean values and range of values. The radiographic averages were calculated with all x-ray available. **Pre and post operative comparisons were made only with paired data, exclusion of patient with absence of pre or post operation data. Statistical paired inter-group comparisons by a t student test were made for the TMC height, the M1/M2 ratio, the MC height and the MC erosion. A Wilcoxon matched-pairs signed rank test was made for the subluxation comparison.



Graphic 1. — MCP Flexion mobility evaluation.



Graphic 2. — Kapandji mobility evaluation.



Graphic 3. — M1/M2 evaluation.

100% of patients declared a pain diminution and the average VAS was 1 (0-6) after surgery. 82% of patients experienced a subjective functional gain and the average postoperative Quick Dash score was 23 (0-57). The average satisfaction score was 8/10 (0-10). 95% of patients have also declared that they would choose to have the operation again. Only one patient stated that they would not do the surgery again.

Our Grip, Key pinch and Tip pinch measurements are presented in Table I. We did not find any statistically significant differences between the measured postoperative strengths and the opposite hand.

The different mobilities are presented in Table II. The postoperative palmar abduction, radial abduction and MCP extension did not present any statistically significant differences between the postoperative and the opposite hand measurements. The postoperative MCP flexion and Kapandji score demonstrate a statistically significant difference compared to the opposite hand. The median difference for the Kapandji score was 1 less for postoperative scores and the postoperative metacarpophalangeal flexion was on average 19 degrees lower.

The radiological results are presented in Table III. Only three patients (15%) had a minimal bone erosion, with a maximal erosion of 2.8 millimeters and no clinical consequences. One case developed osteolysis of the distal scaphoid. Neither postoperative metacarpal height nor metacarpal bone erosion demonstrated a statistically significant difference in comparison to the preoperative X-ray. However, the postoperative TMC height and the M1/M2 ratio presented a statistically significant difference with the preoperative evaluation, corresponding to the proximal migration and the height reduction of the thumb column (without clinically significant association).

We noted an overall metacarpal migration grade deterioration, which was statistically significant (chi-square test; $p=0,0468$). Regarding the reduction of the trapezial space, we found 53% grade 2 (9 cases) and 18% grade 3 (3 cases) in preoperative X-rays. In comparison, after surgery, we had 26% grade 2 (5 cases) and 58% grade 3 (11 cases). Noted that we had 5 grades 1 (no collapse) preoperatively and 3 postoperatively.

We did not find any infection or real adverse tissue reactions. One patient had developed a regional pain complex syndrome. Three patients displayed RegJoint™ calcification but none of the patients had any clinical repercussions.

DISCUSSION

The primary aim of this study was to evaluate whether the Regjoint™ PLDLA 96/4 spacer degradation causes peri prosthesis osteolysis. This complication was reported in three Mattila et al. studies^{34,35,36} and one study by Kennedy et al.⁷

The two first Mattila's series (focused on partial trapeziectomy^{34,35}), demonstrated 22 osteolysis of varying severity, with seven clinical foreign body reactions and three patients who required revision surgery. These results contrast with our series and with previous animal experimental studies. In fact, the PLDLA 96/4 spacer showed a good biocompatibility in

vivo and mild tissue reactions were merely observed in a few animal experimental study reports²⁸. Furthermore, the studies which evaluated the use of PLDLA 96/4 spacers in MCP, TMC and carpometacarpal joints in rheumatism patients showed no evidence of significant osteolysis or adverse tissue reactions^{27,37,38}.

Our study demonstrated the osteolysis of the metacarpal base in 15% of the patients, which is a lower result than those from Mattila et al series^{34,35}. Moreover, the average erosion depth was 0,2mm which is much less than the results recorded by Mattila et al. (average: 2 mm)^{34,35} and Kennedy et al. (average: 3.1 mm)⁷, and none of these osteolysis induced a clinical manifestation in our patients. Regarding the development of foreign body reactions, we did not find any clinical signs (pain, stiffness or swelling), as Kennedy et al.⁷. The first explanation could be determined by the type of trapeziectomy leading to an inhomogeneous distribution of forces on the spacer. In Mattila's studies^{34,35}, the trapezium was partially excised and the spacer placed in the residual space in contact with a cancellous bone. This can subject the spacer to very high recurrent forces (shear stress and friction). The PLDLA filaments gradually lose their tensile force during the first six months, after which the mass begins to disappear^{27,29}, but this phenomenon could be altered by application of increased stresses to the spacer. Irregularly distributed stresses could cause premature wear on the spacer and loose bone debris could trigger an adverse tissue reaction. Furthermore, their population was relatively younger and probably more active than our patients, with presumably higher functional requirements and constraints.

Thus, by performing a complete trapeziectomy, we could, perhaps, ensure a better constraints distribution due to the spacer being placed between two complete articular surfaces and avoid osteolysis and bone resorption. It is probably this element which explains the decrease in the rate of osteolysis (17 peri-spacer osteolysis in the 33 patients) in the third study of Mattila conducted on the interposition of Regjoint after total trapeziectomy³⁶. Even if these results are better than their two first studies^{34,35}, they continue to contrast with our series (less metacarpal and scaphoid osteolysis). Two facts can bring an element of explanation for these different results. As explained by Kennedy et al.⁷, a recent manufacturer's safety notice estimated that of 6,000 RegJoint spacers since 2011, only 15 spacer removals have been reported to date and in four of these 15 cases, tight insertion of the spacer with possible loss of porous spacer quality may be associated with foreign body reaction. Thus, it is essential trying to decrease

the pressure on the spacer by selecting the correct spacer size and preserving the interposition space by setting up distraction K wires in such a way as to block any recoil of the thumb column during the first period of the Regjoint™ integration. This procedure was also used by Tiihonen et al.³⁷ and they also did not find any foreign body reactions.

The secondary aim of our study is to evaluate whether the spacer may restore and maintain the thumb anatomy, strength and mobility after a minimum of one year (minimal period for advanced degradation of the spacer until the stabilisation state of fibrous tissue replacement²⁸).

Thereby, we observed in our patients a decrease in the height of the thumb column, but not associated with any clinically functional consequences, as per Pomares et al.³⁹ who also found this in their 10-year follow-up study on suspensionplasty or tendon interposition.

Regarding the different strength analyses, we did not demonstrate any statistically significant differences between the operated and the opposite hand. Our patients therefore keep an acceptable strength.

In terms of mobility, the surgery causes an average decrease of 19° in flexion and a median reduction in the Kapandji score of 1, but without major clinical repercussions. We found that the mobility reduction has a minute impact on function if stability and indolence of the thumb column are assured.

All patients reported a satisfactory reduction in pain.

Finally, we compared our results to the literature about ligamentoplasty and RegJoint™ interposition.

Regarding the ligamentoplasty and trapezectomy literature^{1,16,20,40,41}, our study show similar results in terms of strengths and mobilities and good level of QuickDASH and VAS. These comparisons demonstrated that the Regjoint™ interposition can be a reliable option in the therapeutic arsenal of TMCJ arthritis.

Concerning the RegJoint™ literature, our mean postoperative QuickDASH score are in the range of the other studies^{7,34,35,36}. There are different factors which can promote variation of this score. It can be influenced by the length of the follow-up, by the difference between the mean age of patients in the studies (as the normative QuickDASH scores increased with age⁴²) and by the different types of surgery performed (primary total trapeziectomy versus primary partial trapeziectomy or arthroplasty revision). Finally, several other pathologies can influence the QuickDash score, specifically in the upper arm (elbow and shoulder).

Note that our VAS scored better than in the four aforementioned studies.

In addition, in comparison with the Regjoint™ literature, our results are similar of those from the 3 Mattila studies^{34,35,36} regarding strengths and mobilities, but superior to Kennedy's study⁷ confirming the hypothesis that placing the Regjoint™ as a salvage procedure without a total trapezium resection can alter the functional recovery.

The different limitations of our study should be pointed out:

1. The lack of preoperative data, impeding the pre and postoperative comparison of strengths and mobilities.
2. As a retrospective study, we cannot clearly define the various follow-up times. With a defined follow-up sequence, we could have carried out a chronological evaluation of all patients.
3. Many of these patients have bilateral osteoarthritis, which may have altered our benchmark.
4. The population size is small, limiting the power of the study.
5. The prolonged nature of the study meant that the long term complications such as potential late bone erosion and potential diminution of the space between the first metacarpal basis and the scaphoid (trapezial void) could be assessed.

CONCLUSION

Concerning the Regjoint™, we have shown that this spacer is safe with low biological activity. We did not highlight any significant complications: no adverse tissue reactions, no important bone erosion, no pain or functional disorders. On the contrary, the patients showed subjective improvements both in terms of pain and functional results. It is important to note that performing a complete trapeziectomy could ensure a better constraints distribution and avoid osteolysis and bone resorption. We have therefore demonstrated that this technique can be a reliable option for the treatment of TMCJ arthritis.

Acknowledgements: We would like to thank dr. Morgan gason for his participation in the data recording and for his involvement in this article and dr. Anne lejeune for her autorisation to use her patients and for her encouragement for this article.

Declaration of conflicting interests: The authors declared no potential conflicts of interest with respect to the research, authorship, and/or publication of this article.

Funding statement: This research received no specific grant from any funding agency in the public, commercial, or not-for-profit sectors.

Ethical approval declaration: This study was approved by the ethics committee of Brugmann hospital, Belgium.

Informed consent declaration: Informed consent was not sought for this article because of retrospective design of the study (with data review) and no therapeutic act was given to the patient (during the study).

REFERENCES

1. Martinez-Martinez F, Garcia-Hortelano S, García-Paños JP, Moreno-Fernández JM, Martín-Ferrero MÁ. Comparative clinical study of 2 surgical techniques for trapeziometacarpal osteoarthritis. *Rev Esp Cir Orthop traumatol.* 2016;60(1):59-66.
2. Baker RHJ, Al-Shukri J, Davis TRC. Evidence-Based Medicine: Thumb Basal Joint Arthritis. *Plasr Reconstr Surg.* 2017 Jan;139(1):256-266.
3. Berger AJ, Momeni A, Ladd AL. Intra and Interobserver Reliability of the Eaton Classification for Trapeziometacarpal Arthritis : A Systematic Review. *Clin Orthop Relat Res.* 2014 Apr;472(4):1155-1159.
4. Andrzejewski A., Ledoux P. Maïa trapeziometacarpal joint arthroplasty: Survival and clinical outcomes at 5 years' follow-up. *Hand Surgery and Rehabilitation* 38 (2019) 169-173.
5. Glyka M, Karen V, Achilleas T. Surgical Treatment of Osteoarthritis of the Carpometacarpal Joint of the Thumb: A Systematic Review. *Plast Reconstr Surg.* 2004 Aug;114(2):421-32.
6. Gervis WH. Osteo-arthritis of the trapezio-metacarpal joint treated by excision of the trapezium. *Proc R Soc Med.* 1947;40:492.
7. Kennedy A-M. , Barker J., Estfan R., Packer G.J. The use of the RegJoint implant for base of thumb osteoarthritis: Results with a minimum follow-up of 2 years. *Hand Surgery and Rehabilitation* 39 (2020) 53-58.
8. Burton RI, Pellegrini VD. Surgical management of basal joint arthritis of the thumb: Part II. Ligament reconstruction with tendon interposition arthroplasty. *J Hand Surg Am.* 1986;11:324-332.
9. Martin-Ferrero M. Ten-year long-term results of total joint arthroplasties with ARPE implant in the treatment of trapeziometacarpal osteoarthritis. *J Hand Surg Eur Vol.* 2014;39:826-832.
10. Toffoli A., Teissier J. MAÏA Trapeziometacarpal Joint Arthroplasty: Clinical and Radiological Outcomes of 80 Patients With More than 6 Years of Follow-Up. *J Hand Surg Am.* 2017;42(10):838.e1-e8.
11. Vermeulen GM, Brink SM, Slijper H, Feitz R, Moojen T M, et al. Trapeziometacarpal arthrodesis or trapeziectomy with ligament reconstruction in primary trapeziometacarpal osteoarthritis: A randomized controlled trial. *J Bone Joint Surg Am.* 2014;96:726-733.
12. Rizzo M, Moran SL, Shin AY. Long-term outcomes of trapeziometacarpal arthrodesis in the management of trapeziometacarpal arthritis. *J Hand Surg Am.* 2009;34(1):20e26.
13. Dumartinet-Gibaud R , Bigorre N., Raimbeau G., Jeudy J., Saint Cast Y. Arpe total joint arthroplasty for trapeziometacarpal osteoarthritis: 80 thumbs in 63 patients with a minimum of 10 years follow-up. *Journal of Hand Surgery (European Volume)* 0(0) 1-5.
14. Vandenbroucke J, De Schrijver F, De Smet L, Fabry G. Simple trapeziectomy for treatment of trapeziometacarpal osteoarthritis of the thumb. *Clin Rheumatol* 1997;16:239-42.
15. Ziad Abdallah, Marc Saab, Thomas Amouyel, Elvire Guerre, Christophe Chantelot, Nadine Sturbois-Nachef. Total trapeziectomy for osteoarthritis of the trapeziometacarpal joint: Clinical

- and radiological outcomes in 21 cases with minimum 10-year follow-up. *Orthopaedics & Traumatology: Surgery & Research* 106 (2020) 775-779.
16. Gangopadhyay S, McKenna H, Burke FD, Davis TR. Five- to 18-year follow-up for treatment of trapeziometacarpal osteoarthritis: a prospective comparison of excision, tendon interposition, and ligament reconstruction and tendon interposition. *J Hand Surg Am.* 2012;37(3):411e417.
 17. Thompson J. Surgical treatment of trapeziometacarpal arthrosis. *Adv Orthop Surg.* 1986;10:105-20.
 18. Swanson AB. Flexible implant arthroplasty for arthritic finger joints. Rational, technique and results of treatment. *J Bone Joint Surg.* 1972;54A:435-55.
 19. Vitale MA, Taylor F, Ross M, Moran SL. Trapezium prosthetic arthroplasty (silicone, Artelon, metal, and pyrocarbon). *Hand Clin.* 2013;29:37-55.
 20. Colegate-Stone TJ, Garg S, Subramanian A, Mani GV. Outcome of trapeziectomy with and without pyrocarbon interposition to treat primary arthrosis of the trapeziometacarpal joint. *Hand Surg.* 2011;16(1):49-54.
 21. Swanson AB, De Groot Swanson G, De Heer DH, Pierce TD, Randall K, et al. Carpal bone titanium implant arthroplasty. 10 years' experience. *Clin Orthop Relat Res.* 1997 Sep;(342):46-58.
 22. Muermans S, Coenen L. Interpositional arthroplasty with Gore-Tex, Marlex or tendon for osteoarthritis of the trapeziometacarpal joint. A retrospective comparative study. *J Hand Surg Br.* 1998 Feb;23(1):64-8.
 23. Wajon A, Carr E, Edmunds I, Ada L. Surgery for thumb (trapeziometacarpal joint) osteoarthritis. *Cochrane Db Syst Rev.* 2009 Oct 7;(4).
 24. Vermeulen GM, Slijper H, Feitz R, Hovius SER, Moojen TM, et al. Surgical management of primary thumb carpometacarpal osteoarthritis: a systematic review. *J Hand Surg Am* 2011; 36:157-69.
 25. Wajon A, Vinycomb T, Carr E, Edmunds I, Ada L. Surgery for thumb (trapeziometacarpal joint) osteoarthritis. *Cochrane Database Syst Rev* 2015; 23(2):CD004631.
 26. Cootjans K, Vanhaecke J., Dezillie M., Barth J., Pottel H., et al. Joint Survival Analysis and Clinical Outcome of Total Joint Arthroplasties With the ARPE Implant in the Treatment of Trapeziometacarpal Osteoarthritis With a Minimal Follow-Up of 5 Years. *J Hand Surg Am.* 2017;42(8):630e638.
 27. Honkanen PB, Kellomäki M, Kontinen YT, Mäkelä S, Lehto MUK. A midterm follow-up study of bio reconstructive polylactide scaffold implants in metacarpophalangeal joint arthroplasty in rheumatoid arthritis patients. *J Hand Surg Eur.* 2009;34: 179-85.
 28. Waris E, Ashammakhi N, Lehtimäki M; Tulamo RM, Kellomäki M, et al. The use of biodegradable scaffold as an alternative to silicone implant arthroplasty for small joint reconstruction: an experimental study in minipigs. *Biomaterials.* 2008;29:683-91.
 29. Lansman S, Paakko P, Ryhänen J, Kellomäki, M; Waris, E; et al: Poly-L/D-lactide (PLD-LA) 96/4 fibrous implants: histological evaluation in the subcutis of experimental design. *J Craniofac Surg* 2006;17:1121-1128.
 30. Kellomäki M, Puumanen K, Waris T, Törmälä P: In vivo degradation of composite membrane of P(e-CL/LLA) 50/50 Film and P(L/D)LA 96/4 mesh. In: Stallforth H, Revell P(Eds.) *Materials for Medical Engineering.* Weinheim, Wiley-VCH,2000:73-79.
 31. Beaton DE, Wright JG, Katz JN. Development of the Quick DASH: comparison of three item-reduction approaches. *J Bone Joint Surg Am* 2005;87:1038-46.
 32. Kapandji A. Clinical test of apposition and counter-apposition of thumb. *Ann Chir Main.* 1986;5:67-73.
 33. Ledoux P. M1/M2 ratio for radiological follow-up of trapeziometacarpal surgery. *Hand Surg Rehabil.* 2017;36:146-147.
 34. Mattila S, Waris E. Unfavourable short term outcomes of a poly-L/ D-lactide scaffold for thumb trapeziometacarpal arthroplasty. *J Hand Surg Eur.* 2016;41: 328-34.
 35. Mattila S, Ainola M, Waris E. Bioabsorbable poly-L/D-lactide (96/4) scaffold arthroplasty (RegJoint™) for trapeziometacarpal osteoarthritis: a 3-year follow-up study. *J Hand Surg Eur.* 2017 Aug 26;0(0):1-7.
 36. Mattila S, Haapamäki V, Waris E. Unfavourable early outcomes of total trapeziectomy with RegJoint interposition: a report of 38 osteoarthritic hands in 34 patients. *Journal of Hand Surgery (European Volume)* 2020, Vol. 45(2) 167-172.
 37. Tiihonen RP, Skyttä ET, Kaarela K, Ikävalko M, Belt E. Reconstruction of the trapeziometacarpal joint in inflammatory joint disease using interposition of autologous tendon or poly-L-D-lactic acid implants: a prospective clinical trial. *J Plast Surg Hand Surg.* 2012;46:113-9.
 38. Tiihonen R, Honkanen PB, Belt EA, Ikävalko M, Skyttä ET. The mean seven years' results of the use of poly-L/D-lactic acid (PLDLA) interposition implant and bone packing in revision metacarpophalangeal arthroplasty: a prospective cohort study. *Scand J Surg* 2012;101:26 5-70.
 39. Pomares G, Delgrande D, Dap F, Dautel G. Minimum 10-year clinical and radiological follow-up of trapeziectomy with interposition or suspensionplasty for basal thumb arthritis. *Orthop Traumatol Surg Res.* 2016;102(8):995e1000.
 40. Ulrich-Vinther M, Puggaard H, Lange B. Prospective 1-year follow-up study comparing joint prosthesis with tendon interposition arthroplasty in treatment of trapeziometacarpal osteoarthritis. *J Hand Surg Am.* 2008;33(8):1369e1377.
 41. Yeoman TFM, Stone O, Jenkins PJ, McEachan JE. The long-term outcome of simple trapeziectomy. *J Hand Surg Eur* 2019;44:146-50.
 42. Aasheim T, Finsen V. The DASH and the QuickDASH instruments. Normative values in the general population in Norway. *J Hand Surg Eur* 2014;39 :140-4.
 43. Vandenbroucke J, De Schrijver F, De Smet L, Fabry G. Simple trapezectomy for treatment of trapeziometacarpal osteoarthritis of the thumb. *Clin Rheumatol* 1997;16:239-42.
 44. Ziad Abdallah, Marc Saab, Thomas Amouyel, Elvire Guerre, Christophe Chantelot, Nadine Sturbois-Nachef. Total trapeziectomy for osteoarthritis of the trapeziometacarpal joint: Clinical and radiological outcomes in 21 cases with minimum 10-year follow-up. *Orthopaedics & Traumatology: Surgery & Research* 106 (2020) 775-779.