

Meta-analysis of InterTan, PFNA and PFNA-II internal fixation for the treatment of unstable intertrochanteric fractures in elderly individuals

W. WANG¹, B. NI¹, H. SHEN¹, H. LU¹

¹Department of Orthopaedics, Xinhua Hospital, Shanghai Jiaotong University School of Medicine, Shanghai, China.

Correspondence at: Hua Lu, Department of Orthopaedics, Xinhua Hospital, Shanghai Jiaotong University School of Medicine, No. 1665 Kongjiang Road, Shanghai, 200092, China. Tel.: +86-021-25077955. Fax: +86-21-25077970. E-mail: luhua@xinhumed.com.cn

Elderly individuals are often affected by osteoporosis and have poor stability after fracture reduction. Moreover, there is still controversy regarding the clinical effects of the treatment for unstable intertrochanteric fractures in the elderly. The Cochrane, Embase, PubMed, and other databases were searched, and a meta-analysis of the literature on the treatment of unstable intertrochanteric fractures of the elderly with InterTan, PFNA, and PFNA-II was conducted. Seven studies were screened, with a total of 1236 patients. Our meta-analysis results show that InterTan is not significantly different from PFNA in terms of operation and fluoroscopy times, but it takes longer than PFNA-II. In terms of postoperative screw cut, pain, femoral shaft fracture, and secondary operations, InterTan is superior to PFNA and PFNA-II. Conversely, in terms of intraoperative blood loss, hospital stay, and postoperative Harris score, there is no significant difference between InterTan and PFNA and PFNA-II. Compared to PFNA and PFNA-II, InterTan internal fixation has advantages in the treatment of unstable intertrochanteric fractures in elderly individuals in terms of screw cutting, femoral shaft fractures, and secondary operations. However, InterTan operation and fluoroscopy times take longer than PFNA and PFNA-II.

Keywords: Unstable intertrochanteric fractures; InterTan; PFNA; PFNA-II; Internal fixation.

INTRODUCTION

Femoral intertrochanteric fractures account for about 50% of proximal femoral fractures and about 4% of all fractures¹. Elderly people with osteoporosis have a mortality rate of 27-30% compared to elders without osteoporosis². With the general increase of an aging population, the incidence of osteoporosis is also increasing every year.² For simple fractures of the intertrochanteric line (AO type 31-A1), no significant difference exists in clinical efficacy between intramedullary and extramedullary fixations. For comminuted fractures of the intertrochanteric line (AO type 31-A2) and inverse intertrochanteric fractures (AO classification 31-A3), the fracture stability and the biomechanics of extramedullary eccentric fixation are poor, which can easily cause hip varus and internal fixation failure. In clinical practice, intramedullary fixation systems are mostly adopted.³

Because elderly individuals requiring fracture reduction are often accompanied by osteoporosis and have poor stability after the procedure, it is essential to choose a reliable internal fixation system, that can enhance clinical efficacy. Commonly used intra-

medullary fixation systems include proximal femoral anti-rotation intramedullary nail (PFNA), Asian proximal femoral anti-rotation intramedullary nail (PFNA-II), and proximal femur combined tension interlocking intramedullary nail (InterTan, IT). Many studies have reported the clinical efficacy of these systems to treat intertrochanteric fractures in elderly individuals. However, there is still controversy regarding the clinical effects of A2 and A3 types of treatment for intertrochanteric fractures in the elderly.

The clinical results obtained from different studies are often inconsistent. Nevertheless, the medical body of evidence suggests that each of these has clear advantages. In this meta-analysis, we reviewed the relevant evidence-based literature to compare the advantages and disadvantages of InterTan with PFNA and PFNA-II for the treatment of unstable intertrochanteric fractures in elderly individuals, with human unstable intertrochanteric fractures providing a reference.

METHODS

PubMed, Cochrane, and Embase databases were consulted for studies written in English, from the

establishment of the database to July 2020. The search terms used were: Intertrochanteric Fracture, Fractures, Hip, Trochanteric Fractures, Fractures, Trochanteric, Intertrochanteric Fractures, Fractures, Intertrochanteric, Subtrochanteric Fractures, Fractures, Subtrochanteric, InterTan, PFNA, Proximal Nail-rotation, PFNA, Proximal Femoral Nail-rotation, PFNA II.

The inclusion criteria were: (1) The diagnosis as an unstable intertrochanteric fracture of the femur; (2) The studies including InterTan, PFNA, and PFNA-II treatment strategies, without other intervention measures; (3) a follow-up time of at least 12 months; (4) no coexistence of other diseases affecting hip joint mobility; (5) an ASA score <4 . (6) The studies written in English.

The exclusion criteria were: (1) the study samples including pathological fractures or other diseases that affect hip joint function; (2) the inclusion of type A1 fractures; (3) a follow-up time <12 months; (4) the repetitive studies, three-dimensional model research or review; (5) inability to extract effective information; (6) low-quality studies.

Randomized controlled trials were scored according to the modified Jadad scale. We excluded studies scoring 1-3 points and included studies scoring 4-7 points. Non-randomized controlled trials were scored according to the NOS scoring scale (>5 points were included in the study). Two reviewers blinded for the studies' authors and affiliations independently screened the literature and scored the selected articles according to the above scale. When different opinions coexisted regarding the included literature, these were resolved by a third reviewer making a final decision. A standardized data extraction form was used to extract: general information from the literature, including authors' names, publication time, research type, sample age, sample size, and follow-up time; meta-analysis data from the literature, including intraoperative fluoroscopy time, intraoperative blood loss, length of hospital stay, postoperative screw cut-out, and postoperative femoral shaft fracture; information regarding second surgery after operation; Harris score after surgery.

The included studies were analyzed with the Revman software (version 5.3). When there were binary variables, the odds ratios (OR) were calculated for each study; for continuous variables, we adopted mean differences (MD) as an effect size indicator. The statistical significance was evaluated using 95% confidence intervals (CI) and established at P -values <0.05 . To evaluate the heterogeneity between groups, we performed a Q-statistic test (whereby Q test $P < 0.1$ signifies heterogeneity and $P > 0.1$, signifies no

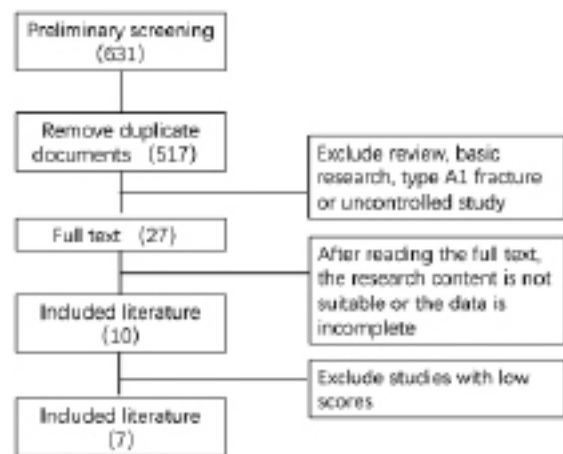


Fig 1. — Flowchart of the studies' selection process.

heterogeneity), and I^2 value statistic test (whereby $I^2 < 50\%$, $I^2 \geq 50\%$, and $I^2 \geq 75\%$, signify no heterogeneity, heterogeneity, and severe heterogeneity between groups, respectively. For studies exhibiting severe heterogeneity, we screened the papers individually and conducted sensitivity analyses to observe whether the homogeneity and results would change significantly and to investigate the reasons for the heterogeneity further.

RESULTS

Following an initial inspection, 631 papers were obtained. After manual deletion of duplicates, 517 papers were included. Following titles and abstracts scrutiny, 27 documents were retained. Ten documents were included after reading the full text. The documents with low scores were eliminated, leaving seven final documents included in this meta-analysis (Figure 1)⁴⁻¹⁰.

Five studies reported comparisons of operation time, including three InterTan vs PFNA internal fixation and 2 InterTan vs PFNA-II. There was no significant difference in operation time between InterTan and PFNA (MD = -2.97, 95%CI [-12.02, 6.09], $P = 0.52$). InterTan was found to require a longer operation time than PFNA-II (MD = -16.60, 95%CI [-23.22, -9.99], $P < 0.00001$). A significant difference between InterTan and PFNA and PFNA-II was found (MD = -8.22, 95%CI [-17.47, 1.03], $P = 0.02$) (Figure 2).

Four studies reported a comparison of intraoperative fluoroscopy time;^{6-8,11} two with IT vs PFNA internal fixation,^{7,11} and two with IT vs PFNA-II internal fixation^{6,8}. Regarding fluoroscopy time, there was no significant difference between IT and PFNA (MD = -1.45, 95%CI [-3.31, 0.41], $P = 0.13$). The IT intraoperative fluoroscopy time was significantly

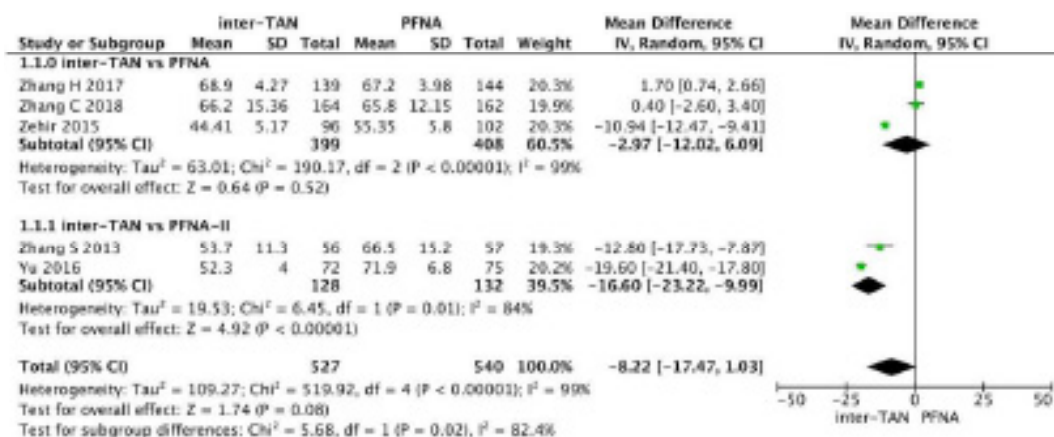


Fig. 2. — Forest plot of intraoperative fluoroscopy time.

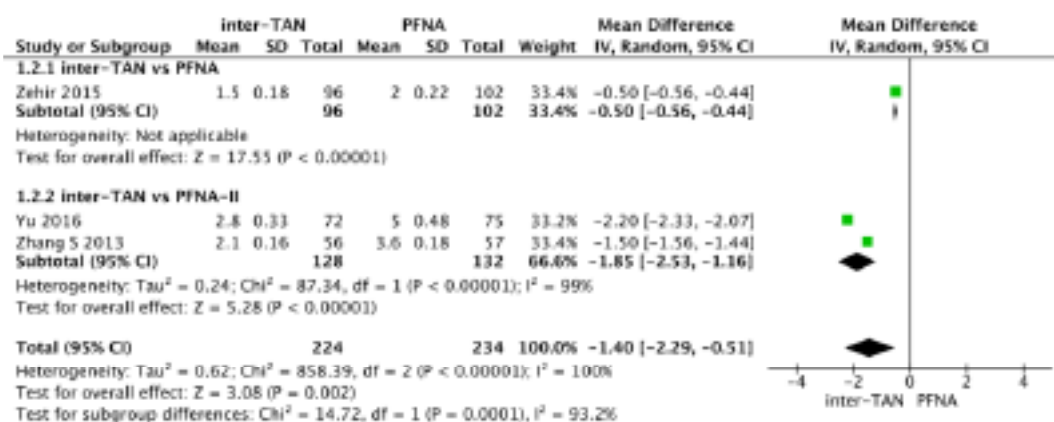


Fig 3. — Forest plot of operation time.

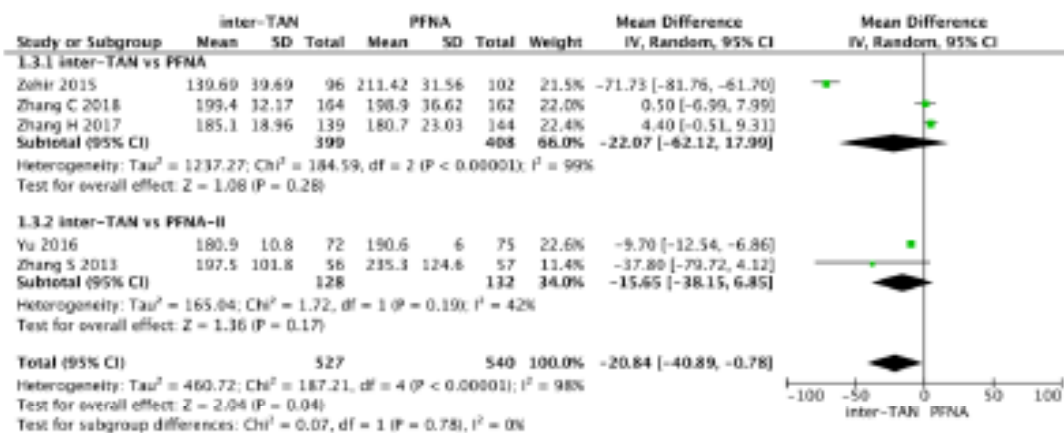


Fig 4. — Forest plot of intraoperative blood loss.

longer than that of PFNA-II (MD=-1.85, 95 % CI [-2.53, -1.16], P<0.05) (Figure 3).

There was no significant difference in intraoperative blood loss. Three studies compared InterTan vs PFNA and two studies InterTan vs PFNA-II. No significant difference was found between InterTan and PFNA (MD=-22.07, 95%CI [-62.12,17.99], P=0.28) or

between InterTan and PFNA-II (MD=-15.65, 95%CI [- 38.15, 6.85], P=0.17) (Figure 4).

Four studies reported a comparison of length of hospital stay, with an overall significant difference (MD=-0.50, 95%CI [-0.98, 0.02], P=0.04). However, our meta-analysis results showed that there was no significant difference between InterTan and

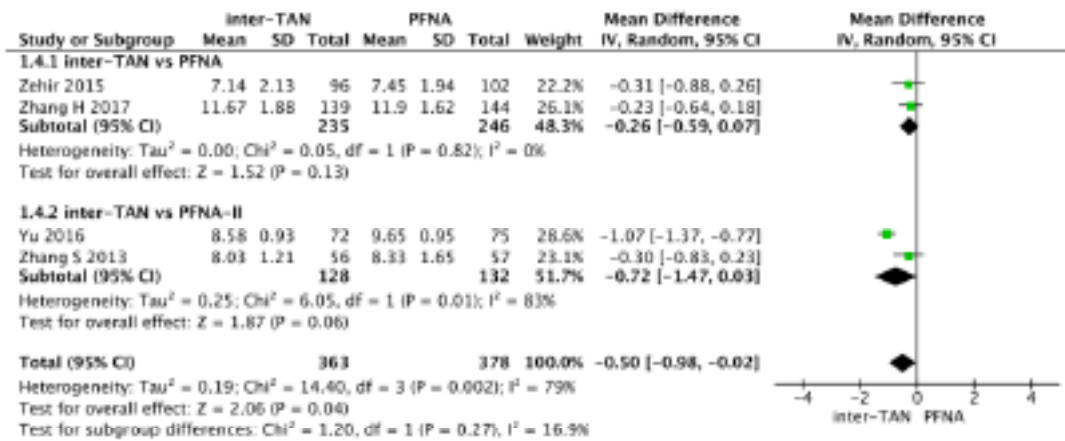


Fig 5. — Forest plot of length of hospital stay.

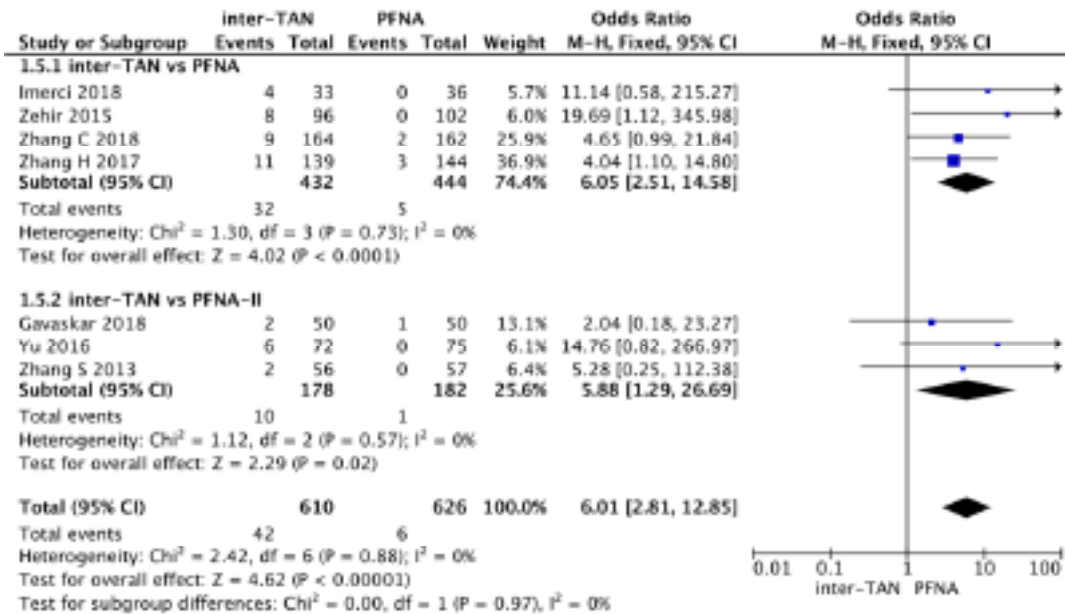


Fig 6. — Forest plot of postoperative screw cut-out.

PFNA (MD=-0.26, 95%CI[-0.59, 0.07], P=0.13) or between InterTan and PFNA-II (MD= -0.72, 95%CI [-1.47, 0.03], P=0.06) (Figure 5).

All the included studies reported data on postoperative screw cut-out. Overall, our meta-analysis results showed significant differences between the studies (OR=6.01, 95%CI [2.81, 12.85], P<0.00001), with small heterogeneity. Screw cut-out was found to be more likely in InterTan than PFNA (OR=6.05, 95%CI [2.51, 14.58], P<0.0001) and PFNA-II (OR=5.88, 95%CI [1.29, 26.69], P=0.02) (Figure 6).

Overall, the occurrence of postoperative femoral shaft fractures was statistically different between the studies (OR=4.40, 95%CI [2.05, 9.43], P=0.0001). InterTan was found to cause fewer femoral shaft fractures than PFNA surgery (OR=3.84, 95%CI [1.63, 9.01], P=0.002)

or PFNA-II surgery (OR= 7.06, 95%CI [1.24, 40.07], P=0.03) (Figure 7).

A second surgery after the operation is another undesired shock for the patient. A total of six studies reported a comparison of a second surgery after operation. The overall heterogeneity was small, and the results were significantly different (OR=3.97, 95%CI [2.46, 6.41], P<0.00001). While InterTan showed a significantly higher incidence of secondary operations than PFNA (OR=4.10, 95%CI [2.45, 6.86], P>0.00001), no significant difference between InterTan and PFNA-II was found (OR=3.19, 95%CI [0.84, 12.08], P=0.09) (Figure 8).

All studies reported a comparison of postoperative Harris scores. Overall, there was no significant difference between them (MD=-0.19, 95%CI [-1.39,

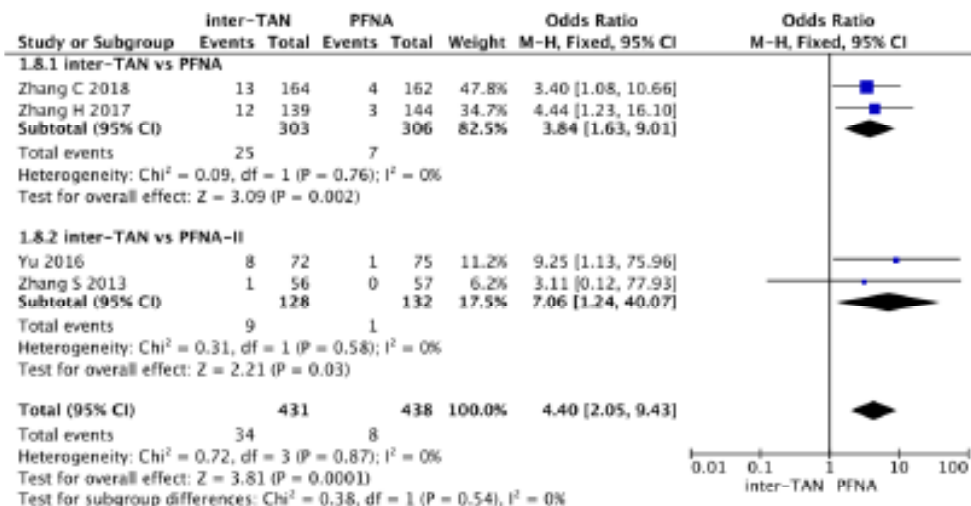


Fig 7. — Forest plot of postoperative femoral shaft fracture.

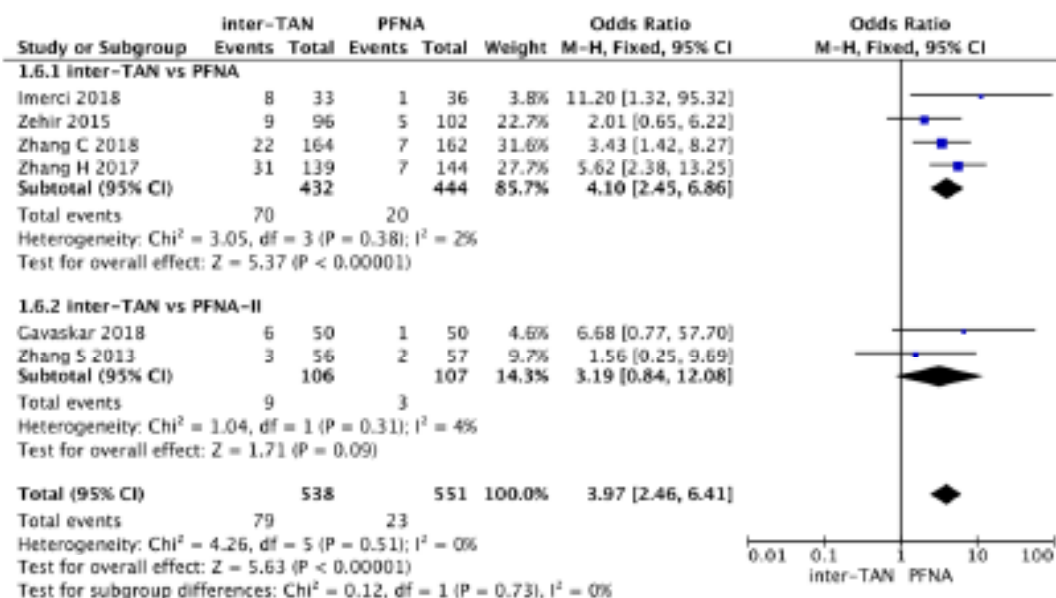


Fig 8. — Forest plot of second surgery.

1.01], $P=0.75$). There was no significant difference between InterTan and PFNA ($\text{MD}=-0.26$, $95\% \text{CI} [-1.29, 0.78]$, $P=0.63$) or between InterTan and PFNA-II ($\text{MD}=-0.01$, $95\% \text{CI} [-3.09, 3.11]$, $P=1.00$) (Figure 9).

DISCUSSION

Femoral intertrochanteric fractures are likely to occur in elderly individuals with osteoporosis and are mostly low-energy injuries. As the population of our country gradually ages, the incidence of femoral intertrochanteric fractures has progressively increased and received more attention from orthopedic physicians¹¹. Early surgical internal fixation and functional exercise are currently recognized as the

main forms of treatment. For simple two-part fractures, intramedullary fixation or extramedullary fixation yield good clinical outcomes. But for comminuted fractures and intertrochanteric line fractures, the biomechanics of extramedullary fixation are an inadequate solution. Indeed, extramedullary fixation carries a high risk of adverse consequences such as hip varus and broken nails postoperatively. Therefore, intramedullary fixation is generally preferred¹². The choice of a given intramedullary fixation system to achieve optimal clinical outcomes has always been a matter of debate^{13,14}.

The most widely used intramedullary fixation systems are PFNA, PFNA-II, and InterTan. PFNA internal fixation consists of three parts: main nail, proximal spiral blade, and distal locking screw. Its advantages include the following: it is a simple operation requiring

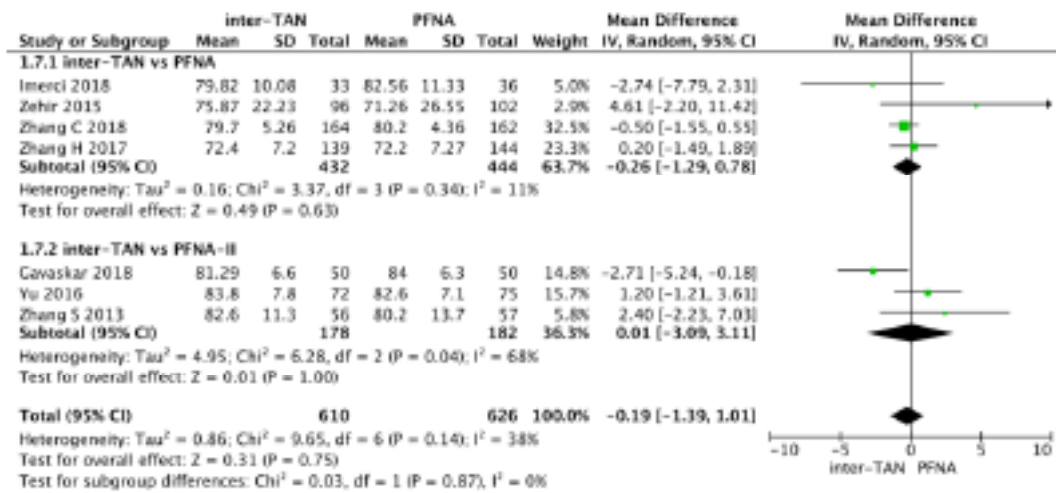


Fig. 9. — Forest plot of postoperative Harris score.

Table I. — Characteristics of the included studies.

Study	Year	Age	Sample/size	Fracture classification (OA)	Follow-up time (M)	Quality
Imerci [5]	2018	>60	36/33	A3	12	7(Jadad)
Gavaskar [6]	2018	78/77	50/50	A2,A3	12	6(NOS)
Zehir [7]	2015	77.2/76.8	102/96	A2,A3	12	7(NOS)
Zhang S [8]	2013	72.4/72.9	57/56	A2,A3	12	6(Jadad)
Yu [9]	2016	>60	75/72	A2,A3	18	7(NOS)
Zhang H [10]	2017	>65	144/139	A2	38-45	7(NOS)
Zhang C [11]	2018	>60	162/164	A2	38-48	8(NOS)

only one screw blade at the proximal end after driving in the main nail, and one locking nail at the distal end, which reduces operation time; the proximal screw blade can be automatically locked, which confers a better anti-rotation effect; the spiral blade compresses the cancellous bone to form a nail channel, which increases the bone density around the blade while the compressed cancellous bone increases the blade anchoring force improving its stability¹⁵. Its limitations are: the routinely employed PFNA is mostly straight, while the medullary cavity of a normal femoral shaft has a certain curvature (anterior arch). After the distal end is locked, the main nail does not match the force line of the femoral medullary cavity, resulting in the tail of the main nail applying pressure on the anterior cortex of the distal femur which may lead to secondary bone; the spiral blade movement in the axial direction is greater than that in the vertical direction. If the spiral blade penetrates deeper, the screw may be cut; poor location of the nail entry point may cause tearing of the greater tuberosity¹⁶.

PFNA-II is an intramedullary fixation system based on PFNA, specifically designed for Asian bones characteristics. The proximal diameter, deflection

angle, and diameter of the spiral blade of the main nail are smaller than those of PFNA; the flat distal design reduces the cortical bone contact rate¹⁷. The key characteristics of InterTan include: a trapezoidal cross-section of the main nail, which increases its anti-rotation force; the proximal double screw fixation has better compression and anti-femoral head rotation effects; the distal bifurcated groove design avoids stress concentration and prevents marrow fractures of the distal femoral shaft thanks to its internal nails^{18,19}.

The seven articles included in this study all comprised A2 and A3 unstable fractures. We analyzed five continuous variables (operation time, fluoroscopy time, intraoperative blood loss, hospital stay, Harris score) and four binary postoperative variables (screw cut, hip and thigh pain, femoral shaft fracture, secondary surgery). We found that InterTan operation and fluoroscopy times were not significantly different from PFNA, but longer than for PFNA-II. However, there is a high degree of heterogeneity among the studies, and even when each study was excluded one by one, there was still no significant change in the heterogeneity. This may be related to the difference in operating habits of different surgeons. Zehir et al.⁶

believe that sufficient experience in intraoperative nail locking can result in shortened operation time. Yu et al.⁸ believe that InterTan operation time was long owing to the trapezoidal design of the proximal end of the InterTan main nail and the smaller medullary cavity of the patient. To evaluate whether the patient's femoral structure was abnormal, a full-length femur image was taken before the operation. The patient's posture during the operation was adjusted to ensure that the main nail and the medullary cavity axis were consistent. The nail point can reduce the difficulty in inserting the main nail, thus shortening the operation time²⁰.

In terms of intraoperative bleeding and hospital stay, our meta-analysis revealed that there were no significant differences between the three surgical procedures. The InterTan and PFNA groups presented higher heterogeneity. Zehir et al.⁶ showed that PFNA resulted in significantly more intraoperative blood loss than InterTan. Similarly, there was a statistically significant difference in terms of operation time between the two systems. The results of this meta-analysis provide a combined synthesis of the four related studies, increasing the overall sample size, therefore granting more convincing results than each individually. The heterogeneity between each study may be ascribed to the different operating habits of each surgeon. There was no significant difference in intraoperative blood loss between Inter-Tan and PFNA-II, but patients in the Inter-Tan group had lower hemoglobin after surgery, indicating that the postoperative latent blood loss in the InterTan group was more than that of PFNA-II²¹. This may be due to the pressurized two-screw design of the InterTan system which can damage the medullary cavity. Conversely, PFNA-II only requires the insertion of a thinner spiral blade, which does not damage the cancellous bone.

In terms of postoperative femoral shaft fractures, InterTan causes fewer femoral shaft fractures than PFNA and PFNA-II. There was no heterogeneity among these groups, and our meta-analysis results were consistent with those of the studies between the groups. In terms of Harris hip score after surgery, InterTan showed no significant difference between PFNA and PFNA-II. Zhang et al.¹⁰ followed up the Harris scores after PFNA and InterTan every three months up to 18 months after surgery. They concluded that, within 12 months after surgery, the Harris scores of the two groups gradually increased. There was no difference in Harris scores between 12 and 18 months after surgery. The heterogeneity between the InterTan and PFNA-II groups is relatively high. After excluding articles one at a time, we found that Gavaskar⁵'s research was the

source of heterogeneity. Gavaskar⁵'s research showed that the Harris score of patients after InterTan operation is higher, and it is believed that the Harris score of the hip joint is affected by postoperative rehabilitation and patient compliance. According to Gavaskar, the Harris score is largely influenced by a patient's subjective feelings. Active management during the perioperative period, careful rehabilitation, and psychological counseling post-operation are beneficial to improving the Harris score after surgery.

In terms of secondary operations after surgery, InterTan was inferior to PFNA, while there was no significant difference with PFNA-II, nor heterogeneity between the groups. As a special group, the elderly are in an overall poorer condition, and a second operation after surgery is a considerable shock for them. As mentioned, the integrity of the lateral wall is very important for fracture stability. Studies have shown that the surgical failure rate of intertrochanteric fractures with a lateral wall injury using extramedullary fixation is seven times that for the treatment of intertrochanteric fractures with an intact lateral wall²². The main nail of the intramedullary nail can support the lateral wall to a greater extent, reducing the likelihood of secondary operations due to an incomplete lateral wall. The main reasons for the need of a secondary operation reported in the articles analyzed in this meta-analysis were the following: head screw migration, cut-out, femoral shaft fracture, femoral head collapse, deep infection. The influence of the lateral wall on the second operation was not mentioned. Once again, this proves the intramedullary fixation effectiveness for lateral wall injuries and fractures.

A main limitation of this study relates to the authors' skills in compiling the relevant literature. Therefore, some papers that meet the inclusion criteria might have been missed. Although patient details such as age, preoperative general condition, and fracture type are restricted, the variables are reduced as much as possible. The effect of surgery also depends on the operator's skills, which can lead to biased results; although the included fracture types were all unstable, the lateral wall of type A2.1 fractures was intact, type A2.2 and type A2.3 Injury to the lateral wall of the fracture, type A3 is an inverse intertrochanteric fracture, there are still differences in the postoperative clinical efficacy. Because of these limitations, further clinical studies are still required to collect better clinical evidence and suggest the most suitable treatments for unstable intertrochanteric fractures.

CONCLUSIONS

Compared to PFNA and PFNA-II, InterTan internal fixation has advantages for the treatment of unstable intertrochanteric fractures in elderly individuals regarding aspects such as screw cutting, femoral shaft fractures, and secondary operations. However, the operation and fluoroscopy times are longer than for PFNA and PFNA-II.

Availability of data and materials: The datasets used and/or analyzed during the current study are available from the corresponding author on reasonable request.

Competing interests: The authors declared no potential conflicts of interest with respect to the research, authorship, and/or publication of this article.

REFERENCES

- Zhu Y, Chen W, Sun T, Zhang Q, Liu S, Zhang Y. Epidemiological characteristics and outcome in elderly patients sustaining non-simultaneous bilateral hip fracture: a systematic review and meta-analysis. *Geriatr Gerontol Int* 2015;15:11-18.
- Petryla G, Uvarovas V, Bobina R, Kurtinaitis J, Khan SA, Versocki A, et al The one-year mortality rate in elderly patients with osteoporotic fractures of the pelvis. *Arch Osteoporos*. 2020;20;15(1):15.
- Dash SK, Panigrahi R, Palo N, Priyadarshi A, Biswal M. Fragility Hip Fractures in Elderly Patients in Bhubaneswar, India (2012-2014): A Prospective Multicenter Study of 1031 Elderly Patients. *Geriatr Orthop Surg Rehabil* 2015; 6:11-15.
- Emmerson BR, Varacallo M, Inman D. Hip Fracture Overview. 2020. In: StatPearls [Internet]. Treasure Island (FL): StatPearls Publishing; 2020 Jan-.
- Imerci A, Aydogan NH, Tosun K. A comparison of the InterTan nail and proximal femoral nail antirotation in the treatment of reverse intertrochanteric femoral fractures. *Acta Orthop Belg* 2018; 84:123-131.
- Gavaskar AS, Tummala NC, Srinivasan P, Hitesh G, Bhupesh K, Santosh S. Helical blade or the integrated lag screws: a matched pair analysis of 100 patients with unstable trochanteric fractures. *J Orthop Trauma*. 2018;32:274-277.
- Zehir S, Şahin E, Zehir R. Comparison of clinical outcomes with three different intramedullary nailing devices in the treatment of unstable trochanteric fractures. *Ulus Travma Acil Cerrahi Derg*, 2015;21:469-476.
- Zhang S, Zhang K, Jia Y, Yu B, Feng W. InterTan nail versus Proximal Femoral Nail Antirotation-Asia in the treatment of unstable trochanteric fractures. *Orthopedics* 2013; 36: e288-e294.
- Yu W, Zhang X, Zhu X, Hu J, Liu Y. A retrospective analysis of the InterTan nail and proximal femoral nail anti-rotation-Asia in the treatment of unstable intertrochanteric femur fractures in the elderly. *J Orthop Surg Res* 2016;11: 10-16.
- Zhang H, Zhu X, Pei G, Zeng X, Zhang N, Xu P, et al. A retrospective analysis of the InterTan nail and proximal femoral nail anti-rotation in the treatment of intertrochanteric fractures in elderly patients with osteoporosis: a minimum follow-up of 3 years. *J Orthop Surg Res* 2017;12:147-154.
- Zhang C, Xu B, Liang G, Zeng X, Zeng D, Chen D, et al. Optimizing stability in AO/OTA 31-A2 intertrochanteric fracture fixation in older patients with osteoporosis. *J Int Med Res* 2018; 46: 1767-1778.
- Socci AR, Casemyr NE, Leslie MP, Baumgaertner MR. Implant options for the treatment of intertrochanteric fractures of the hip: rationale, evidence, and recommendations. *Bone Joint J* 2017;99-B(1):128-133.
- Schipper IB, Marti RK, Van der Werken CHR. Unstable trochanteric femoral fractures: extramedullary or intramedullary fixation: review of literature. *Injury* 2004;35:142-151.
- Roberts KC, Brox WT, Jevsevar DS, Sevarino K. Management of Hip Fractures in the Elderly. *J Am Acad Orthop Surg* 2015; 23:131-137.
- Palm H, Jacobsen S, Sonne-Holm S, Gebuhr P; Hip Fracture Study Group. Integrity of the lateral femoral wall in intertrochanteric hip fractures: an important predictor of a reoperation. *J Bone Joint Surg Am* 2007; 89: 470-475.
- Irgit K, Richard R D, Beebe M J, Bowen TR, Kubiak E, Horwitz DS. Reverse oblique and transverse intertrochanteric femoral fractures treated with the long cephalomedullary nail. *J Orthop Trauma* 2015; 29: e299-e304.
- Roberts KC, Brox WT, Jevsevar DS, Sevarino K. Management of hip fractures in the elderly. *J Am Acad Orthop Surg* 2015;23:131-137.
- Zhang W, Antony Xavier RP, Decruz J, Chen YD, Park DH. Risk factors for mechanical failure of intertrochanteric fractures after fixation with proximal femoral nail antirotation (PFNA II): a study in a Southeast Asian population. *Arch Orthop Trauma Surg* 2020.
- Hoffmann S, Paetzold R, Stephan D, Püschel K, Buehren V, Augat P. Biomechanical evaluation of interlocking lag screw design in intramedullary nailing of unstable pertrochanteric fractures. *J Orthop Trauma* 2013; 27: 483-490.
- Nüchtern JV, Ruecker AH, Sellenschloh K, Rupperecht M, Püschel K, Rueger JM, et al. Malpositioning of the lag screws by 1-or 2-screw nailing systems for pertrochanteric femoral fractures: a biomechanical comparison of gamma 3 and InterTan. *J Orthop Trauma* 2014; 28: 276-282.
- Zhu JF, Xu WX, Liu H. Case-control study on InterTan intramedullary nail in treating coronal femoral intertrochanteric fracture in elderly. *Zhongguo Gu Shang* 2016;29:1130-1134.
- Hao Z, Wang X, Zhang X. Comparing surgical interventions for intertrochanteric hip fracture by blood loss and operation time: a network meta-analysis. *J Orthop Surg Res* 2018;13:157.
- Seyhan M, Turkmen I, Unay K, TimucinOzkut A. Do PFNA devices and InterTan nails both have the same effects in the treatment of trochanteric fractures? A prospective clinical study. *J Orthop Sci* 2015; 20: 1053-1061.