

VOLAR DISLOCATION OF THE PROXIMAL INTERPHALANGEAL JOINT OF THE FINGER : AN INDICATION FOR URGENT OPERATIVE TREATMENT

I. DEGREEF¹, L. DE SMET¹, G. FABRY¹

Two patients are described with persistent acute volar dislocation of the middle phalanx of a finger. Closed reduction was impossible due to intra-articular interposition of the lateral slip of the extensor mechanism, combined with a tear of a collateral ligament. It is important to recognize these injuries at an early stage and an operative treatment is required.

Keywords : proximal interphalangeal joint ; dislocation ; operative treatment ; extensor tendon.

Mots-clés : articulation interphalangiennne proximale ; luxation ; traitement opératoire ; tendon extenseur.

INTRODUCTION

Volar dislocation of the proximal interphalangeal joint (PIP) is a rare injury. Most cases are caused by direct force working on the middle phalanx. In many cases a closed reduction was incomplete with a persistent subluxation and a rotatory displacement. Unrecognised or accepted as normal, this situation leads to a stiff PIP joint.

Johnson and Greene in 1966 (6) described a case of an irreducible subluxation of the PIP joint of a third finger. The ulnar lateral slip of the extensor mechanism was dislocated volarly, and interposed into the PIP joint. The ulnar collateral ligament was torn. The ulnar condyle of the proximal phalanx was trapped between the central slip and the ulnar lateral slip (6). Since Johnson and Greene, 10 authors have described a similar situation with an intact central slip of the extensor mechanism : all together described another 16

cases, all treated surgically in the acute stage (within four weeks after the accident) (1-5 ; 7-11).

We report two additional cases.

CASE REPORTS

Case 1

A 46-year-old woman presented with pain in her right ring finger. She had fallen on her right hand 2 weeks earlier. Since the accident pain, swelling and rubor persisted over the PIP joint. Flexion or extension of the joint was impossible. The PIP joint was held in 20° flexion.

Radiographs demonstrated a volar subluxation of the PIP joint with some rotation. A small dorsal avulsion fracture was seen (fig. 1).

Open reduction was done under regional anaesthesia. The radial collateral ligament was found to be torn. The extensor mechanism was intact,

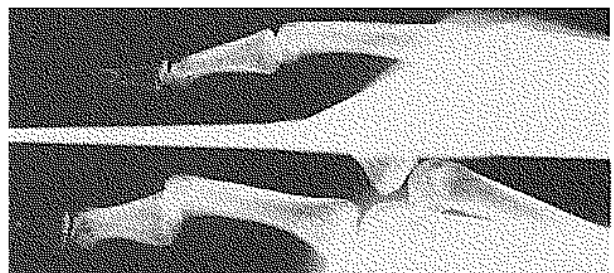


Fig. 1. — Radiograph of case 1.

Department of Orthopaedic Surgery, U.Z. Pellenberg, Weligerveld 1, B-3212 Pellenberg, Belgium.

Correspondence and reprints : L. De Smet.

but the radial lateral slip was dislocated palmarly. After reduction of this extensor slip, complete reduction of the PIP joint was possible. The collateral ligament was repaired. A temporary fixation in extension for 10 days with a K-wire was done. Mobilization was started after two weeks. At three months postoperatively the PIP joint moved from 10° lack of extension to 85° of flexion.

Case 2

A 57-year-old painter was seen 19 days after an accident. His right index finger had been caught beneath a ladder. He was treated by his physician with a splint. There was no mobility in the PIP joint. Eleven days later a closed reduction was attempted. Important lateral instability was obvious afterwards. When he was seen at our department the PIP joint was stiff and fixed in 20° of flexion. Radiographs demonstrated a volar subluxation of the PIP joint, with a rotational component (fig. 2).

An open exploration was performed. The ulnar lateral slip was dislocated palmarly. The ulnar collateral ligament was torn and was trapped within the joint. The ligament and the ulnar lateral slip were removed from the joint and the PIP joint could be reduced. An external fixator was applied. Seven days later active motion was started but the joint remained very stiff. Mobility was very limited, over a few degrees.

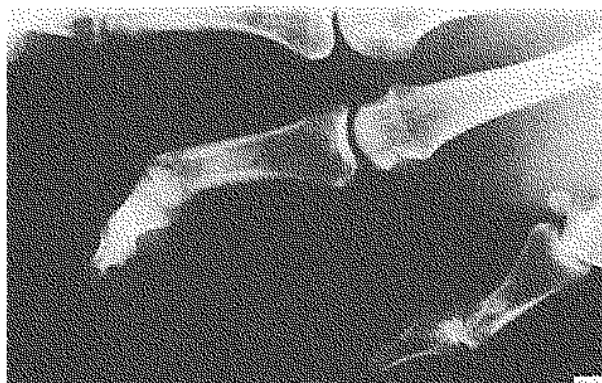


Fig. 2. — Radiograph of case 2.

Table I. — Summary of previously reported cases

Cases (ref.)	Age (years)	Sex	Side	Finger	Tear	Interposition	Result	Immobilization
1 (1)	27	M	R	V	NN	—	00/100	15 d
2 (1)	29	M	L	II	UCL	—	00/090	10 d
3 (2)	22	F	L	M	NN	CS	00/100	14 d
4 (3)	55	F	R	II	UCL	—	00/095	2 d
5 (3)	51	F	R	II	UCL	—	45/075	4 d
6 (4)	23	M	L	II	UCL	CS	10/100	21 d
7 (4)	17	F	L	V	UCL	CS	00/100	21 d
8 (4)	78	F	L	M	UCL	—	10/090	10 d
9 (5)	24	M	R	III	UCL	CS	00/100	21 d
10 (6)	58	F	L	III	NN	CS	00/100	7 d
11 (6)	17	M	L	IV	NN	CS	10/090	14 d
12 (7)	31	F	L	II	UCL	CS	15/095	21 d
13 (7)	23	F	R	II	UCL	CS	10/080	21 d
14 (8)	14	M	L	IV	UCL	CS	12/093	NN
15 (8)	31	M	R	IV	RCL	RLS	08/100	NN
16 (9)	34	M	L	II	UCL	RLS	10/90	14 d
17 (10)	24	F	R	II	UCL	—	10/095	14 d
18 (11)	28	F	R	II	UCL	CS	00/100	21 d

NN : not noted

UCL : ulnar collateral ligament

RCL : radial collateral ligament

CS : central slip

RLS : radial lateral slip

ULS : ulnar lateral slip

DISCUSSION

Volar dislocation of the PIP joint is a rare injury and is usually irreducible. This is due to the interposition of the collateral ligament or a partial entrapment of the extensor tendon in the joint. Usually one of the condyles of the proximal phalanx is caught between the central and lateral slips. A review of the literature could illustrate 18 similar cases (Table I). Persistent subluxation of the PIP joint of a finger requires open exploration and reduction. However when reduction of the volar dislocation of a PIP joint is very easy, a rupture of the central slip of the extensor tendon is probably associated and this too will require open exploration and repair (3).

A method of closed reduction by specific manoeuvres has been described by Dray and Eaton (3). Gentle traction with both MCP and PIP flexed has to be applied and then with a rotatory motion the intra-articular portion of the lateral band can be disengaged, allowing congruous reduction of the PIP joint. If this does not succeed or when the dislocation relapses, an open procedure is required.

REFERENCES

1. Auquit-Auckbur I., Duparc F., Millez P., Thomine J. Luxations palmaires récentes de l'articulation interphalangienne proximale. Rev. Chir. Orthop., 1997, 83, 60-64.
2. De Smet L., Vercauteren M. Palmar dislocation of the proximal interphalangeal joint requiring open reduction. A case report. J. Hand Surg., 1984, 9-A, 717-718.
3. Dray G., Eaton R. in Green D. (ed.) Operative Hand Surgery. Churchill Livingstone, New York, 3rd ed., 1993, 773-774.
4. Grant I. Irreducible rotational anterior dislocation of the proximal interphalangeal joint. A spin drier injury. J. Hand Surg., 1993, 18-B, 648-651.
5. Inoue G., Maeda N. Irreducible palmar dislocation of the proximal interphalangeal joint of the finger. J. Hand Surg., 1990, 15-A, 301-304.
6. Johnson F., Greene M. Another cause of irreducible dislocation of the proximal interphalangeal joint of a finger. J. Bone Joint Surg., 1966, 48-A, 542-544.

7. Kilgore E., Newmeyer W., Brown L. Post-traumatic trapped dislocations of the proximal interphalangeal joint. J. Trauma, 1976, 16, 481-487.
8. Murakami Y. Irreducible volar dislocation of the proximal interphalangeal joint of the finger. The Hand, 1974, 6, 87-89.
9. Neviasser R., Wilson J. Interposition of the extensor tendon resulting in persistent subluxation of the proximal interphalangeal joint of the finger. Clin. Orthop., 1972, 83, 118-120.
10. Ostrowski D., Nemkin R. Irreducible palmar dislocation of the proximal interphalangeal joint. Orthopaedics, 1985, 8, 84-86.
11. Posner M., Wilenski M. Irreducible volar dislocation of the proximal interphalangeal joint of a finger caused by interposition of an intact central slip. J. Bone Joint Surg., 1978, 60-A, 133-134.
12. Wang K., Hsu K., Shih C. Irreversible volar rotatory dislocation of the proximal interphalangeal joint. Orthop. Rev., 1994, 23, 886-888.

SAMENVATTING

I. DEGREEF, L. DE SMET, G. FABRY. Palmaire luxatie van het PIP gewricht : een indicatie voor open behandeling.

Twee nieuwe gevallen van persisterende subluxatie van het PIP gewricht van de vinger na een palmaire luxatie. Bij beiden werd een interpositie van de extensorpees (laterale slip) en een ruptuur van een collateraal ligament gevonden.

De laattijdige behandeling van deze gevallen heeft waarschijnlijk geleid tot een matig en slecht resultaat.

RÉSUMÉ

I. DEGREEF, L. DE SMET, G. FABRY. Luxation palmaire de l'articulation IPP : une indication au traitement chirurgical.

Deux cas de subluxation persistante de l'IPP d'un doigt après luxation palmaire sont décrits. Dans les deux cas une interposition de la bandelette externe de l'extenseur et une rupture d'un ligament collatéral ont été trouvées. Le retard thérapeutique est probablement la cause du résultat médiocre obtenu chez ces deux patients.