



## Bilateral osteochondritis dissecans of the shoulder

Barbara J. C. FAVIER, Daniël M. C. JANSSEN

*From the Department of Orthopedics and Traumatology at St.-Trudo Hospital, Sint-Truiden in Belgium*

**Osteochondritis dissecans as a pathology is predominantly described in the knee, elbow and ankle. Osteochondritis dissecans of the humeral head is a more uncommon reported injury. We present a case of a bilateral osteochondritis dissecans of the humeral head in a 16-year-old soccer player and an algorithm for treatment of OCD of the humeral head.**

**To our knowledge this has never been described so specifically in literature before.**

**Keywords :** osteochondritis dissecans; chondral defect; humeral head; humeral defect; shoulder arthroscopy.

### INTRODUCTION

Osteochondritis dissecans (OCD) is a relatively uncommon condition mainly affecting the capitellum, femoral condyle or talar dome. Other locations are only described in case reports with no clear evidence on etiology or treatment. Of all OCD cases, only 0.6-1.6% occur in the shoulder, of which both the humerus and the glenoid have been reported (1,2). Repetitive microtrauma, overuse injury or precipitant trauma is most commonly hypothesized as the underlying pathology, although the definite cause of OCD in humeral head is unknown.

This case report describes the rare case seen in our clinic of a bilateral OCD of the humeral head in a young soccer player.

### CASE REPORT

A 16-year-old male patient with bilateral shoulder pain presented at our orthopedic clinic. The pain in his right shoulder had been present for 2,5 years and he had been experiencing pain in his left shoulder for the past 2 months. Pain in his right shoulder was preceded by a minor trauma during soccer and with the help of proper physiotherapy the pain was partially under control, but he has not been able to perform heavy tasks due to crepitus and pain. The pain in his left shoulder originated with no prior trauma and had been increasing over time.

Clinical inspection showed no postural abnormalities or muscle atrophy. There was a full range of motion (FROM) of both shoulders with a clear painful arc bilaterally between 85 and 110 degrees of abduction. The rotator cuff muscles show a normal force and there were no signs of instability or scapular dyskinesia. The Constant Murley score of the right shoulder was 90.5 and

---

■ Barbara J. C. Favier, MD

■ Daniël M. C. Janssen, MD

*Department of Orthopedics and Traumatology at St.-Trudo Hospital, Sint-Truiden in Belgium.*

Correspondence: Barbara Favier, Van Arteveldestraat 53-1, 2060 Antwerp, Belgium,

E-mail: barbarafavier@gmail.com

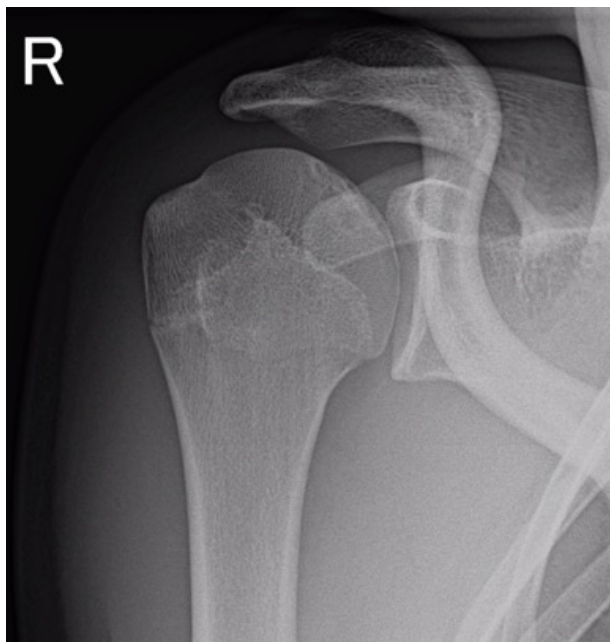
©2022, Acta Orthopædica Belgica.

---

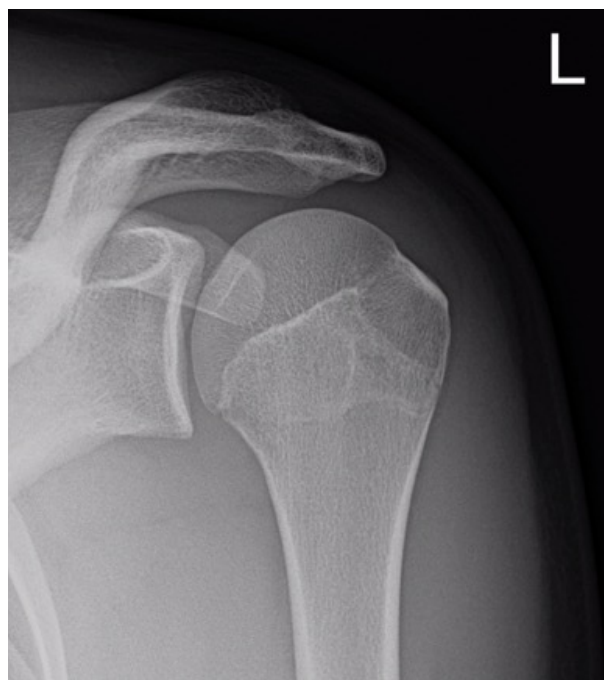92 of the left shoulder. The QuickDASH score was 6.8% for the right shoulder and 11.4% for the left shoulder.

Primarily X-rays were obtained of both shoulders, showing osteochondral lesions in both caput humeri (figure 1 and 2). Afterwards, an MRI-scan of both shoulders was performed, which confirmed a bilateral osteochondral lesion of the caput humeri in identical location posterosuperior of the humeral head (figure 3 and 4). Seemingly there was no bone edema present around the lesions, so the radiographic lesions were recognized as older lesions.

Considering that the patient had limited complaints, a conservative treatment was initiated with relative rest, suspension of overhand sport activity, non-steroid anti-inflammatory drugs and physiotherapy for muscle strengthening and stabilization exercises. At 9 months follow-up the patient's left shoulder was completely pain free with full range of motion. His right shoulder also showed a full range of motion, but heavy exercises occasionally caused fatigue of the right shoulder. Right shoulder Constance score increased to 95 and to 100 for the left shoulder. The QuickDASH



*Fig. 1.* – X-ray of the right humeral head (caput humeri) with central flattening of the head and irregular subchondral bone.



*Fig. 2.* – X-ray of the left humeral head (caput humeri) with subtle central flattening of the head without irregularities of the subchondral bone.

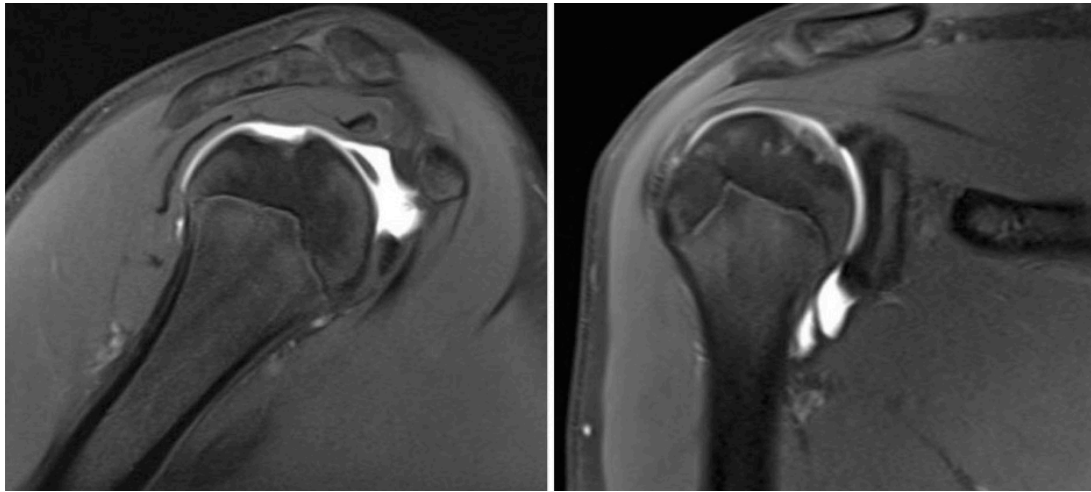
score of the right shoulder decreased to 4.5% and the left shoulder to 0.0%.

Newly obtained MRI-scans of both shoulders showed a bilateral stable situation with no progression of the osteochondral lesions.

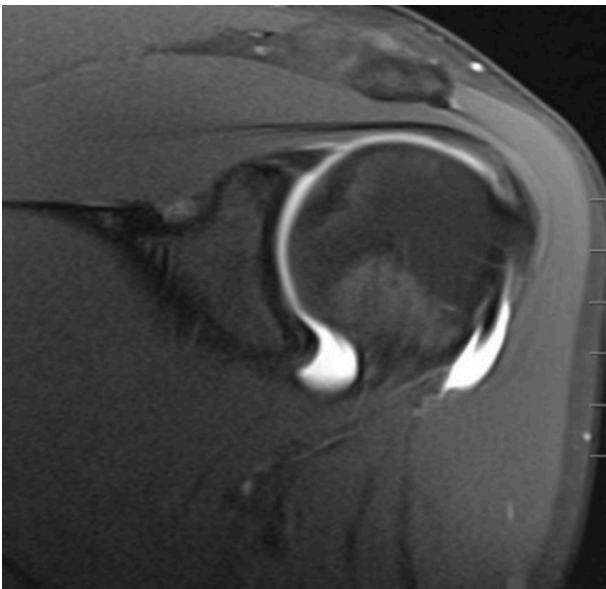
## DISCUSSION

The humeral head is a fairly uncommon location for OCD lesions. Mostly, OCD occurs in the ankle, the elbow and the knee and most lesions are unilaterally. A recent literature search resulted in 19 case reports describing OCD of the humeral head. For the review of these case reports, we decided to use only the available English reports, which resulted in 13 remaining articles (3-5, 7-20).

Only Hamada et al. (7) describe a bilateral occurrence of OCD in a 12 year old male patient. In contrast with our case, this case was treated with bilateral shoulder arthroscopy. In the right shoulder the treatment consisted of removal of a partial detached fragment with debridement, curettage and drilling in the humeral defect. In the left shoulder no arthroscopic intervention was



**Fig. 3.** – Frontal and sagittal T2-weighted MRI image of the right humeral head (caput humeri) with a central osteochondral lesion without bone edema.



**Fig. 4.** – Frontal T2-weighted MRI image of the left humeral head (caput humeri) with a central osteochondral lesion without bone edema.

performed, because only softening and dimpling of the anterosuperior humeral cartilage was found during arthroscopy. All other reports describe unilateral OCD.

All articles describe pain as the main complaint at presentation of the patient, mainly activity related pain. No clear underlying cause can be described, but most commonly the pain is preceded by a minor trauma. Other common symptoms include

restricted range of motion and crepitus. As these symptoms are not specifically linked to OCD and can also occur in a range of differential diagnoses, imaging is used to make the final diagnosis of OCD of the humeral head. Plain X-rays are the primary choice, but to define and stage the defect (such as overlying cartilage condition), additional radiography through MRI-scan is advised. A staging system for humeral head OCD has not been developed yet due to low reported incidence, but a staging similar to that developed for other joints can be utilized. For example, OCD of the knee has been classified based on radiological and arthroscopic findings. There are different classification systems, like the Bedouelle or the SofCOT classification based on MRI-scan findings (19). These radiological descriptions could be used for humeral OCD as well.

Additional information provided by the previous case reports show that the most common location of the OCD lesion of the humeral head is the superior aspect of the proximal humerus, but medial OCD lesion has been described as well (14). Because a clear underlying mechanism that causes OCD of the humeral head is still unknown, this can be hypothesized through two mechanisms. Firstly, because vascular disruption can elicit subchondral injury and the superomedial aspect of the humeral head shows the highest risk for compromised blood

supply due to the anatomic distribution of the intraosseous blood vessels (11). A second possible cause was described by Mima et al. (14), who suggest that in an elevated arm position the superior aspect of the humeral head faces the glenoid cavity, and mechanical load is increased in the superior aspect of the humeral head when micro-trauma occurs in this position.

In the 13 case reports that we studied, different treatment options have been described for OCD of the humeral head. Treatment can be conservative or surgically, depending on the symptoms and whether the lesion is stable or unstable. When the lesion shows no disruption of the articular cartilage with subchondral bone-lesion transition radiographically, it is considered as a stable lesion (20).

In case of an unstable fragment most authors in literature preferred surgical treatment with arthroscopic stabilization of the fragment or removal of the fragment, debridement and antegrade drilling (5). A third surgical option is auto- or allograft interposition for larger defects, either open or arthroscopically (10,15).

In Table I we summarized the treatment for OCD of the humeral head of the 13 different reported cases.

Of the case reports that describe conservative treatment including activity adjustment, temporary suspension of sport activities and physical therapy, 2 (Anderson et al. and Mahirogullari et al.) reports described persisted pain after conservative treatment, whereby the authors decided to treat the lesion surgically by arthroscopic resection of loose bodies and debridement or drilling. This was followed by 2 weeks of relative rest and then active physiotherapy. At the end the patients had good postoperative results (2,13).

Arguments for conservative treatment include a stable OCD lesion and the fact that the shoulder is not a weightbearing joint surface, with less occurrence of patient complaints after conservative treatment of the lesion (5). Surgical treatment can be enforced when the OCD lesion is unstable, occurrence of loose bodies or if there is a larger defect. Also, failure of conservative treatment can be an indication for surgery.

Table I. – Different case reports and their reported treatment

Year	Author	Treatment	Follow-up	Outcome
1983	Anderson et al.	Conservative → Drilling	6 weeks	FROM
1988	Ishakawa et al.	Concervative	8 months	No pain
1992	Hamada et al.	Drilling - none	19 months	No pain
1997	Johnsson et al.	Allograft	3 years	No pain, RTS
2002	Pydisetty et al.	Conservative	6 months	No symptoms
2005	Debeer et al.	Conservative	6 months	No symptoms
2006	Park et al.	Autograft	31 months	No symptoms
2008	Mahirogullari et al.	Conservative → Debridement	10 months	No symptoms
2012	Lunden et al.	Drilling	4 months	No pain, RTS
2016	Mima et al.	Stabilization	4 years	ASES 89.2 SSV 70%; CS
2017	Pham et al.	Autograft	26 months	92
2017	Jafari et al.	Conservative	6 months	No pain
2019	Gill et al.	Stabilization	1 year	OSS 71; CS 92

In our case the treating surgeon decided to treat the 'stable' OCD-lesions conservatively with good follow-up results clinically and radiographically at 6 months.

With appropriate classification and clinical work-up, an algorithm can be followed as proposed by Accadbled et al. (1) to determine which type of treatment is best suited for your patient. Dipaola et al. (4) have described the staging of an OCD lesion in 1991 based on MRI-scan, which has been applied to different anatomical locations. They describe the use of this classification to distinguish between stable and unstable lesion, and determine that stage 1 and 2 are stable, whereas stage 3 and 4 can be considered unstable lesions. The most distinct

difference on MRI-scan is that stage 2 still shows a heterogenous area of mixed signal intensity is seen behind the lesion, whereas stage 3 will show a homogenous area behind the lesion of intermediate signal intensity, which is the underlying synovial fluid separating the lesion from the subchondral bone.

Though MRI-scan has always been considered the gold standard for differentiating OCD lesions, differentiation and diagnosis with CT-scan for OCD lesion of the knee by Clanton and DeLee also showed excellent diagnostic results for OCD of the capitellum (18). This classification also distinguishes stable (stage 1 and 2) and unstable (stage 3 and 4). We suggest using either the proposed MRI- or CT-scan classification as the guideline for treatment, by

Table II. – Algorithm for the treatment of OCD of the humeral head based on MRI- or CT-scan

<i>Stage</i>	<i>MRI findings</i> <sup>(20)</sup>	<i>CT findings</i>	<i>Treatment options</i>	<i>Follow-up</i>
<b>1 (stable)</b>	Thickening of articular cartilage and low signal changes	Depressed osteochondral fracture	-Conservative with 6 weeks relative rest and 3 months sport stop	None if symptom free
<b>2 (stable)</b>	Articular cartilage breached; low-signal rim behind fragment indicating fibrous attachment	Osteochondral defect attached by an osseous bridge	-Conservative treatment -Arthroscopic debridement	Postoperatively: direct mobilization, 3 months sport stop
<b>3 (unstable)</b>	Articular cartilage breached; high-signal rim behind fragment indicating synovial fluid between fragment and underlying subchondral bone	Detached non-displaced fragment	-Arthroscopic debridement and antegrade drilling -Arthroscopic stabilization	Postoperatively: 2 weeks immobilization, 4 weeks intermittent unloaded mobilization, 3 months sport stop
<b>4 (unstable)</b>	Loose body	Displaced fragment	-Arthroscopic debridement and antegrade drilling -Arthroscopic stabilization -Grafting	Postoperatively: 2 weeks immobilization, 4 weeks intermittent unloaded mobilization under shoulder height, 3-6 months sport stop

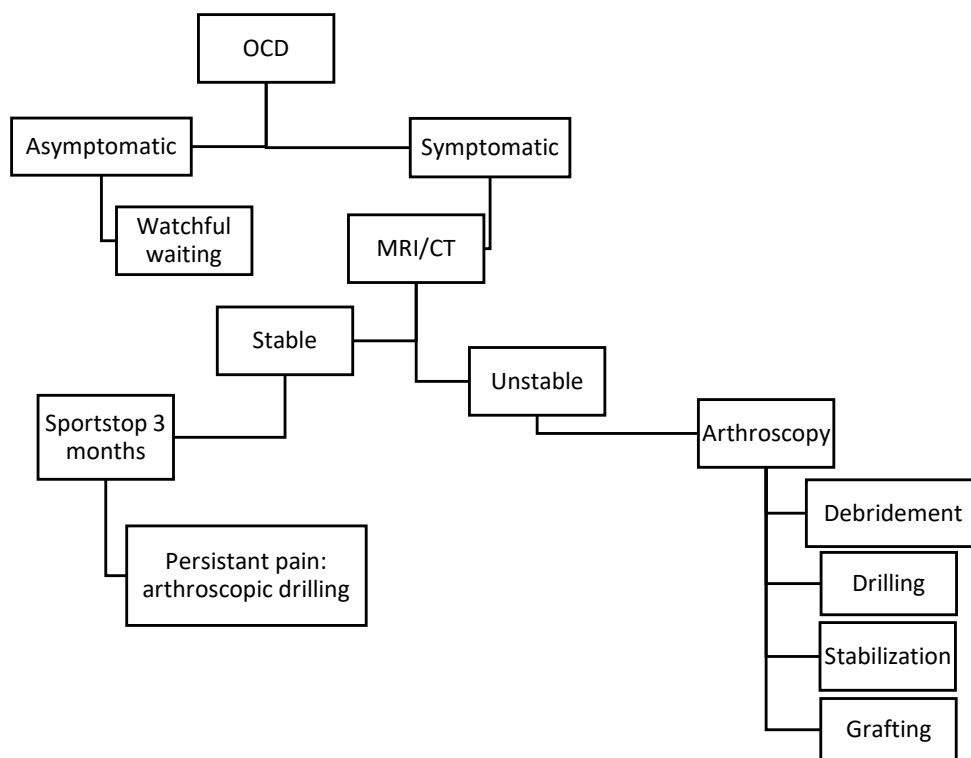


Fig. 5. – Algorithm for the treatment of OCD of the humeral head.

determining the difference between a stable and an unstable lesion, which will help you decide on your treatment method.

Surgical technique is based on size and mobility of the fragment. Reconstruction can be done when the lesion has detached or is too large without the possibility for fixation the fragment. Reconstruction includes ice picking or placement of a biological membrane.

## CONCLUSION

OCD of the humeral head is a relatively uncommon cause of shoulder pain which can be diagnosed through radiography, in particular MRI-scan. Definite treatment of the lesion can be conservatively or surgically depending on the clinical and radiological findings, of which both have been described to have good final results.

## REFERENCES

1. Weiss JM, Nikizad H, Shea KG, Gyurdzhyan S, Jacobs JC, Cannamela PC, *et al.* The Incidence of Surgery in Osteochondritis Dissecans in Children and Adolescents. *Orthop J Sport Med.* 2016;4(3).
2. Edmonds EW, Heyworth BE. Osteochondritis dissecans of the shoulder and hip. *Clin Sports Med.* 2014;33(2):285-94.
3. Gill J, Tytherleigh-Strong G. Osteochondritis dissecans with associated secondary chondromatosis in an adolescent shoulder. *Shoulder Elb.* 2019;11(4):275-81.
4. Ishikawa H, Ueba Y, Yonezawa T, Kurosaka M, Ohno O, Hirohata K. Osteochondritis dissecans of the shoulder in a tennis player. *Am J Sports Med.* 1988;16(5):547-50.
5. Johnson DL, Warner JJP. Osteochondritis dissecans of the humeral head: Treatment with a matched osteochondral allograft. *J Shoulder Elb Surg.* 1997;6(2):160-3.
6. Park TS, Kim TS, Cho JH. Arthroscopic osteochondral autograft transfer in the treatment of an osteochondral defect of the humeral head: Report of one case. *J Shoulder Elb Surg.* 2006;15(6):31-6.
7. Lunden JB, Legrand AB. Osteochondritis dissecans of the humeral head. *J Orthop Sports Phys Ther.* 2012;42(10):886.
8. Mima Y, Matsumura N, Ogawa K, Iwamoto T, Ochi K, Sato K, *et al.* Osteochondritis dissecans on the

- medial aspect of the humeral head. *Int J Shoulder Surg.* 2016;10(2):89-91.
9. **Jafari D, Shariatzadeh H, Mazhar FN, Okhovatpour MA, Razavipour M.** Osteochondritis dissecans of the humeral head: A case report and review of the literature. *Arch Bone Jt Surg.* 2017;5(1):66-9.
  10. **Pham TT, Kany J, Lakhal W, De Gauzy JS, Accadbled F.** Arthroscopic osteochondral autograft transfer for juvenile osteochondritis dissecans of the humeral head: A case report. *JBJS Case Connect.* 2017;7(3):3-7.
  11. **Lunden JB, Legrand AB.** Osteochondritis dissecans of the humeral head. *J Orthop Sports Phys Ther.* 2012;42(10):886.
  12. **Hamada S, Hamada M, Nishiue S, Doi T.** Osteochondritis dissecans of the humeral head. *Arthrosc J Arthrosc Relat Surg.* 1992;8(1):132-7.
  13. **Mahirogullari M, Chloros GD, Wiesler ER, Ferguson C, Poehling GG.** Osteochondritis dissecans of the humeral head. *Jt Bone Spine.* 2008;75(2):226-8.
  14. **Pydisetty R V., Prasad SS, Kaye JC.** Osteochondritis dissecans of the humeral head in an amateur boxer. *J Shoulder Elb Surg.* 2002;11(6):630-2.
  15. **Anderson WJ, Guilford WB.** Osteochondritis dissecans of the humeral head. An unusual cause of shoulder pain. *Clin Orthop Relat Res.* 1983;173:166-8.
  16. **Versier G, Dubrana F.** Treatment of knee cartilage defect in 2010. *Orthop Traumatol Surg Res.* 2011;97:S140-53.
  17. **Keough N, de Beer T, Uys A, Hohmann E.** An anatomical investigation into the blood supply of the proximal humerus: surgical considerations for rotator cuff repair. *JSES Open Access.* 2019;3(4):320-7.
  18. **van den Ende KIM, Keijsers R, van den Bekerom MPJ, Eygendaal D.** Imaging and classification of osteochondritis dissecans of the capitellum: X-ray, magnetic resonance imaging or computed tomography? *Shoulder Elb.* 2019;11(2):129-36.