



Non-contact wound area assessment by digital planimetry using photo editing software

Pradyumna Krishna MAJUMDAR, Umesh YADAV, Rakesh K. GUPTA, Raj Singh POTALLIA, Vinit VERMA

From the Dept. of Orthopaedics, PGIMS, Rohtak, Haryana, India

To objectively assess wound healing utilizing a novel digital photo planimetry method. 58 wounds mostly of traumatic origin were studied. In method I (control or gold standard), a transparent plastic graph paper sheet with 2.5 mm squares was placed on the wound to trace the wound edges. This was scanned and analyzed in Adobe Photoshop (PS6) to estimate the area. In the novel method (method II), we clicked a photo with one-inch lines marked (on either side of the wound). This photo was similarly assessed in PS6. A two-sample t-test was used for analysis. Photos were clicked every third day. The time taken to calculate the resultant area was also noted. 484 photos and 1936 values were analyzed. The mean areas obtained were 10690 mm² and 10859 mm² respectively by methods I and II. The mean difference was 0.824%, 95% CI [-0.05, 1.60] and p = 0.923. The inter and intra-observer variation was < 2% for all readings. The time taken by the novel method was much lesser than the time-tested method (mean = 82 sec vs 178 sec; p < 0.01). The difference in area by the two methods is not statistically significant. The accuracy of both methods is therefore comparable. Our novel method is easier, more cost-effective, equally accurate, safer and reproducible in comparison with the transparency squares method, especially for flat or 2-dimensional wounds.

Keywords: Non-contact; wound; area; assessment; digital planimetry; photoshop; transparency.

INTRODUCTION

Wound healing is a complex process that depends on several variables. A universally accepted objective way to assess this is not clearly defined but the decrease in wound size and volume is generally accepted as the way. Several methods have been used to evaluate this including serial measurement using graph paper method, transparency sheet weighing method, ruler measurements, acetate tracings, Visitrak®, Planimator app for Android, 3-dimensional (3D) cameras scrutiny, stereophotogrammetry, laser and structured light analysis (1-6).

Many, like the graph paper square counting method, are riddled with interobserver variation; Visitrak, laser & structured light analysis and 3D cameras by the expense involved. Additionally, 3D cameras have not demonstrated greater accuracy to manual planimetry (4,7).

The study sought to find out how the novel method compared to the standard method used for

-
- Pradyumna Krishna Majumdar,
 - Umesh Yadav,
 - Rakesh K. Gupta,
 - Raj Singh Potalia,
 - Vinit Verma

Dept. of Orthopaedics, PGIMS, Rohtak, Haryana, India.

Correspondence : Dr. Pradyumna K. Majumdar, 17/11J, PGIMS Campus, Rohtak, 124001 Haryana, India. M: 8059220723.

Email : Pradyumnakm@gmail.com

© 2022, Acta Orthopædica Belgica.

area assessment in terms of accuracy, cost, ease, safety, and reproducibility.

MATERIALS & METHODS

Fifty-eight wounds mostly of traumatic origin were studied. The wounds were cleaned and debrided if required. Large circumferential wounds were excluded from the study due to anticipated difficulty in processing and analyzing area by the new method. There were 50 flat wounds and eight 3D wounds. Two methods of area estimation were compared.

The area by Method I using a transparent plastic graph paper sheet with 2.5 mm blocks was considered the true area. An online A4 graph paper template with 2.5 mm blocks was laser printed onto a transparent plastic sheet. The outline of the wound was traced onto this, after surface sterilization with surgical spirit (Figure 1). This sheet was scanned and saved in JPEG format after cleaning of the under surface. It was imported into Adobe® Photoshop® CS6 (PS6) (trial version). The calibration of the 'measurement tool' in the software to the 2.5 mm squares in the image was done. The wound outline was traced with the 'lasso tool' and the area was calculated automatically by the software (true area) (Figures 2 & 3).

Method II is being proposed as a replacement. For calibration, a permanent marker was used to mark two one-inch long blocks (one on either side of the wound) with a stencil made for this purpose (Figure 4). A skin marking pen was not used as daily dressing and washing would fade the mark with time. Wound photographs were taken from an approximate distance/height of 50 cm, perpendicular to the skin surface. For 3D or partially circumferential wounds, more than one photo was taken and the photos were stitched together in the same software. The marked lines/blocks were used for calibration on importing the photo to PS6. The area was estimated as mentioned earlier.

One 'set' comprised of eight values – two readings each by two observers for two images (one by either method). An average of the four values obtained from each method was used for analysis. Images were obtained every third day (days 3, 6,

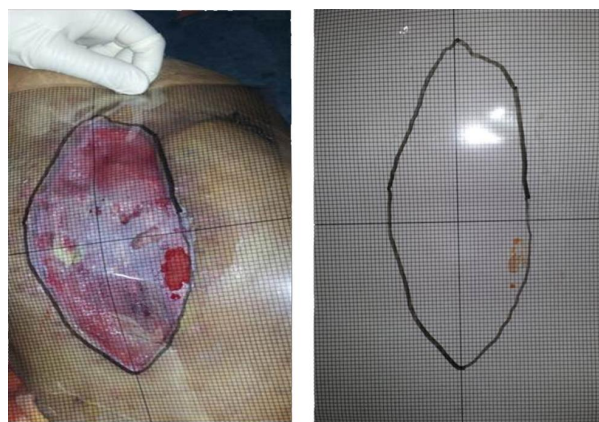


Figure 1. — A4 graph paper template (2.5 mm blocks) with an outline of the wound.

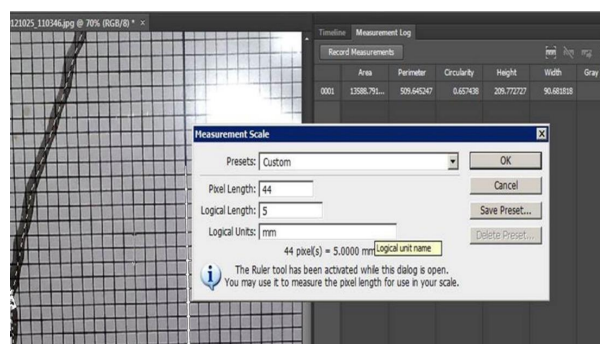


Figure 2. — Calibration of the 'measurement tool'. Two square lengths (5 mm) used here.

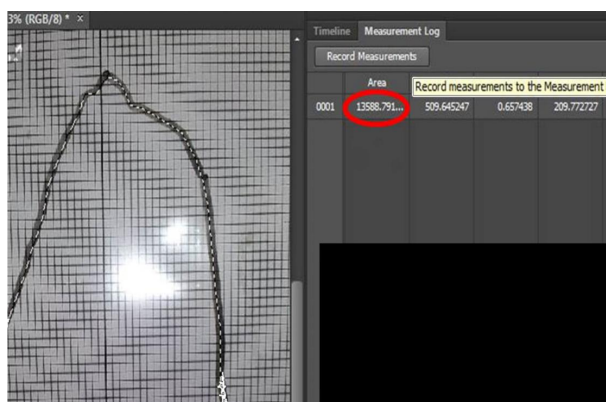


Figure 3. — The area was calculated automatically by the software method I.

9, etc.). These wounds were followed for the next few weeks till healing by secondary intention or coverage by skin grafting or flap. The time taken to calculate the resultant area was noted.

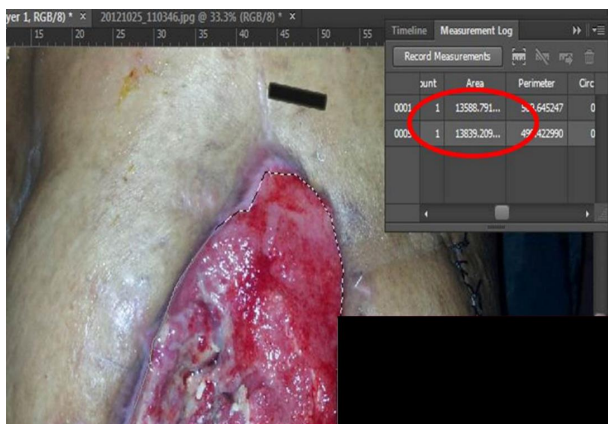


Figure 4. — One-inch long block marked with a permanent marker on side of wound visible as the area is calculated by the software (method II) and compared with method I.

An online two-sample t-test and confidence interval (www.usablestats.com, www.socscistatistics.com) was used to check the significance of the difference between the estimation of the area by the two methods.

RESULTS

Fifty-eight wounds in a mixed demographic population and diagnosis were selected for the study and images obtained by two methods described above were analyzed in a way to reduce bias in PS6.

Each wound had an average of 4 sets of images (range = 3-7 sets), before coverage or healing. So, in total, we had 242 sets of photographs (484 photos) and 1936 values. For the final analysis, 484 values were used after averaging (as mentioned earlier). A summary of the results obtained is shown in Table 1.

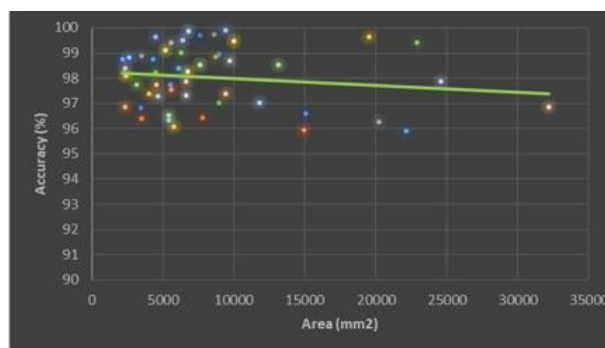


Figure 5. — Accuracy vs area in relatively flat wounds.

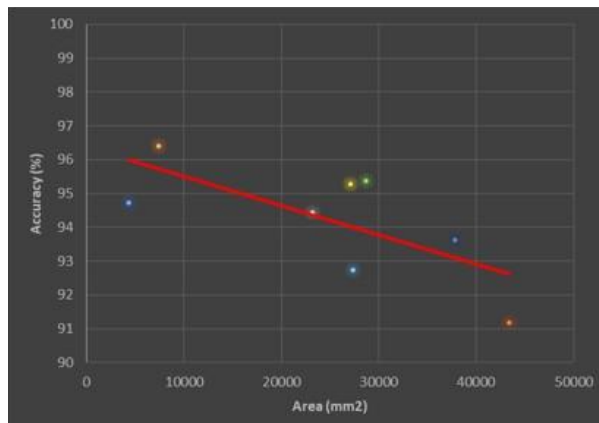


Figure 6. — Accuracy vs area in small 3D/circumferential wounds.

The inter and intraobserver variation was < 2% for all readings. These differences are not statistically significant. Therefore, the accuracy and reliability of both methods is comparable. Additionally, the accuracy of the readings was more for relatively flat wounds versus 3-dimensional /circumferential

Table 1. — Summary of the results

	Method I (n = 242)	Method II (n = 242)
Range of areas (mm ²)	2126.9-39897.4	2153.5-43416.0
Mean area (mm ²)	10690	10859
p-value	0.923	
Difference	Mean = 0.824%, 95% CI [0.05, 1.60]	
Mean duration to estimate area (sec)	178	82
p-value	< 0.01	

wounds. The accuracy seemed to decrease slightly with size for flat wounds while it fell rapidly for 3D wounds (Figures 5 & 6).

The time taken by the novel method was much lesser than the time-tested method (Table 1), though generally larger wounds took longer to trace and retrace on the computer.

DISCUSSION

Numerous methods for wound area assessment have been used in clinical practice and research including the traditional outlining of wound edges onto a transparent plastic film and the relatively recent computer-aided digital planimetry. Each method has its advantages as well as shortcomings.

The ease of photography and analysis with minimal training led us to develop this method of planimetry. Tracing on film is a contact method albeit with minimal pain and risk of infection. The tracing on film, scanning into the computer and subsequently tracing margins in the software takes time and maybe cumbersome when large series of wounds are studied. These limitations of the film-based technique have been overcome here by the novel method of perpendicular photography and direct analysis on the computer. Where digital planimetry was used, similar results concerning minimal interobserver variation were seen (5,7). This method is probably the best for flat wounds of limbs and pressure sores.

Li, et al, used a similar method that we used for true area and concluded that the transparency method was the best among all those available to them (5). However, our novel method is easier, more cost-effective, equally accurate and reproducible in comparison to their transparency method. In many setups, it is not possible to avail of the latest methods like 3-dimensional (3D) cameras scrutiny, stereophotogrammetry, laser and structured light analysis.

The limitations of method II include decreased accuracy in circumferential wounds. Here method I is superior.

CONCLUSION

This new digital planimetry method using Adobe Photoshop is not only fast and accurate but is easy and ethical as no physical contact is made with the wound, so no pain or chance of contamination. It also involves minimal expense as the software is trialware and almost everyone has good mobile cameras. We recommend the usage of this technique for objective assessment of the area and thus healing in essentially flat or 2-dimensional wounds. Also, it provides a photographic record for future research and documentation.

REFERENCES

1. Chang AC, Dearman B, Greenwood JE. A Comparison of Wound Area Measurement Techniques: Visitrak Versus Photography. *Eplasty*. 2011;11.
2. Foltynski P. Ways to increase precision and accuracy of wound area measurement using smart devices: Advanced app Planimator. *PLoS One*. 2018;13(3):e0192485.
3. Khoo R, Jansen S. The Evolving Field of Wound Measurement Techniques: A Literature Review. *Wounds Compend Clin Res Pract*. 2016;28(6):175-81.
4. Williams KJ, Sounderajah V, Dharmarajah B, Thapar A, Davies AH. Simulated Wound Assessment Using Digital Planimetry versus Three-Dimensional Cameras: Implications for Clinical Assessment. *Ann Vasc Surg*. 2017;41:235-40.
5. Li P-N, Li H, Wu M-L, Wang S-Y, Kong Q-Y, Zhang Z, et al. A Cost-Effective Transparency-Based Digital Imaging for Efficient and Accurate PLoS One. 2012;7(5).
6. Bohannon RW, Pfaller BA. Documentation of wound surface area from tracings of wound perimeters. *Clinical report on three techniques. Phys Ther*. 1983;63(10):1622-4.
7. Rajbhandari SM, Harris ND, Sutton M, Lockett C, Eaton S, Gadour M, et al. Digital imaging: an accurate and easy method of measuring foot ulcers. *Diabet Med J Br Diabet Assoc*. 1999;16(4):339-42.