



Open reduction in treatment of neglected elbow dislocation in children

Ahmed EL MOULOUA, El Mouhtadi AGHOUTANE, Amine EL KHASSOUI, Tarik SALAMA, Redouane EL FEZZAZI

From the Pediatric Orthopedic department, Mother and Child Unit, University Hospital Mohamed VI, University Cadi Ayyad, Marrakech, Morocco

Elbow dislocation in children is uncommon condition in children, it's occurred in 3 to 6% of all elbow injuries. Only case reports and small series reported in the literature. The aim of our study is to evaluate the outcomes of open reduction of neglected elbow dislocation (NED) in children. A retrospective review of 26 neglected elbow dislocation was treated by open reduction at our institution between January 2010 and December 2018 was performed. Age, mechanism of injury, associated fracture, manipulation by bone-setters, infectious complications, were recorded. The SOFCOT criteria was used to assess the stiffness of the elbow in preoperative and in postoperative. Besides, in postoperative we used DI SCHINO Criteria to assess useful ROM and subjective criteria to evaluate pain and performance of daily activity. A total of 26 patients with a mean age of 10 years ranging from 5 to 14 years, were identified and followed for a median of 4 years postoperatively. The median duration before presentation was 5 months ranges from 22 days to 5 years. All patients except one were manipulated by bonesetters with massage and manipulation. The dislocation was postero-lateral in 15 cases (58%). 17 patients (65%) have associated fracture. 17 patients went for internal approach, 5 posterior approach, and 4 with combined internal and external approach. Reduction of the ulnar humeral joint was assisted with a lengthening of the triceps with a Speed V-Y muscle plasty in 13 patients. According to SOFCOT criteria at the last follow-up we obtained 15(58%) of minim and moderate elbow stiffness, and according to DI-SCHINO criteria at the last follow-up, 7(27 %) has a very good result, 7(27%) has a good result. The open

reduction and the early rehabilitation remain the key stone of treatment of NED in children regardless the chronicity of the injury. Prevention remains the best way to improve the prognosis of neglected elbow dislocations.

Keywords: Elbow dislocation; children; neglected.

INTRODUCTION

Elbow dislocation in children is an uncommon condition in children, it's occurred in 3 to 6% of all elbow injuries (1-4). It's considered neglected when it has been left unreduced for more than 3 weeks (5-8). It's frequent in developing countries because of poverty and ignorance (9), and the majority of patients are manipulated by bonesetter with massage and manipulation making the elbow stiffness worse.

■ Ahmed El Mouloua, MD,
■ El Mouhtadi Aghoutane, MD,
■ Amine El Khassoui, MD,
■ Tarik Salama, MD,
■ Redouane El Fezzazi, MD.
Pediatric Orthopedic department, Mother and Child Unit, University Hospital Mohamed VI, University Cadi Ayyad, Marrakech, Morocco.

Correspondence : Ahmed El Mouloua MD, Pediatric Orthopedic department, Mother and Child Unit, University Hospital Mohamed VI, University Cadi Ayyad, Marrakech, Morocco, Cell number: +33749033912 / +212665496802.
Email : elmouloua.ahmed@gmail.com
© 2022, Acta Orthopædica Belgica.

Most elbow dislocations are posterior but can be posterolateral or anterior (9,10). The type of elbow dislocation is determined by the presence or not of associated fracture; it's called simple when there is no fracture, and complex dislocation when there is (11,12). Several techniques have been described to reduce elbow neglected dislocation, from the closed reduction under general anesthesia, to open reduction with ligaments reconstruction, or hinged external fixator (12). Our study aims to evaluate the outcomes of open reduction of neglected elbow dislocation (NED) in children.

PATIENTS AND METHODS

A total of 26 patients were referred to our institution for NED between January 2010 and December 2018. We included patients with NED > 3 weeks and with a minimum of 6 months of follow-up, we excluded patients with congenital elbow dislocation and those who have been lost of follow-up. There were 17 boys and 9 girls. The left side was involved in 19 patients. There was no case of bilateral dislocation. All patients except one were manipulated by bonesetters with massage and manipulation. One patient was unsuccessfully treated in another institution 2 years ago, and was lost to follow up, was presented to our institution for stiffness of the elbow and restriction of range of motion (ROM).

The surgery was performed under general anesthesia with a pneumatic tourniquet in the arm. 17 patients went for internal approach, 5 for posterior approach, and 4 for a combined internal and lateral approach. The ulnar nerve is identified, released, and protected by gentle traction with a surgical loop. The heterotopic ossification and the fibrous tissue are carefully excised to avoid cartilage damage. The collateral ligaments, anterior capsule, and sometimes when needed the posterior capsule are gently released. Reduction of the ulnar humeral joint was assisted with a lengthening of the triceps with a Speed V-Y muscleplasty in 13 patients, and excision of the radial head in 2 patients. Stabilization with Kirschner wires was needed in 15 patients, with Trans-olecranon Kirschner wire in 13 patients and radio-capitellar joints in 2 patients. Repair of the

collateral ligaments was performed in 16 patients. Reduction and osteosynthesis were performed when a fracture was associated. Interscalene brachial plexus block with a continuous catheter insertion system was performed in a patient without elbow fixation to begin early physiotherapy. The wound was closed in layers over a suction drain which was kept for 24 hours.

The elbow is kept in a posterior above-elbow plaster of Paris lab for 3 weeks, then the plaster and the k-wire are removed except in the case of associated fracture. Active range of motion in flexion and extension was commenced the next day after surgery in patients without fixation, 3 weeks postoperatively in patients with fixation of the elbow, and at 6 weeks in patients with associated fractures. Figures 1-2 below show preoperative, postoperative plain radiographs, and postoperative clinical photographs of one of the patients.

Patients were followed up clinically and radiologically at 3 weeks, 3 months, 6 months, 12 months, and every year after. The SOFCOT (13) criteria

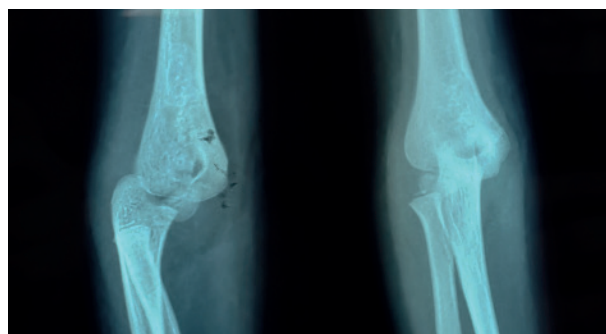


Figure 1. — Lateral and Anteroposterior radiograph in preoperative

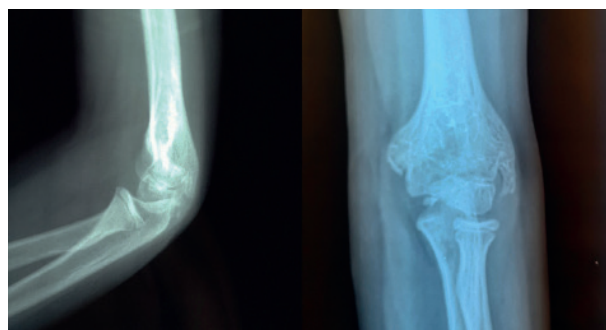


Figure 2. — Lateral and Antero-posterior radiograph in postoperative

were used to assess the stiffness of the elbow in preoperative and in postoperative. These criteria are based on the ROM of the elbow, minimal stiffness ROM > 90°, moderate stiffness when ROM between 61° to 90°, severe stiffness when ROM between 31°-60°, and very severe when ROM is < 30°. Besides, in postoperative we used DI SCHINO (14) Criteria to assess useful ROM and subjective criteria to evaluate pain and performance of the daily activity.

RESULTS

The mean age was 10 years ranging from 5 to 14 years. There were 17(65%) boys, with a male to female ratio of 2:1. All the patients were right-handed and the majority 19 (73%) of the luxation occurred in the non-dominant elbow. The common injury mode was a fall from the height in 21 (81%) of cases. The median duration, before presentation, was 5 months, ranging from 22 days to 5 years, and 16 (62%) presented before 3 months. Stiffness of the elbow was the motif of consultation in all cases. At the presentation. All the patients had a disturbed Nelaton triangle, and a widened joint when a lateral condyle fracture is associated, and 11 (42.3%) had a blocked elbow in extension. The mean follow-up was 4 years, ranging from 6 months to 9 years. Baseline patients' characteristics are summarized in Table I.

The Dislocation was postero-lateral in 15 (58%) of cases and posterior in 11 (42%) of cases. The elbow dislocation was simple in 9 (35%) patients and complex in 17 (65%) patients with 10 medial epicondylar fractures, 6 lateral condylar fractures, and 1 radial fracture. The postoperative complications recorded 4 cases of heterotopic calcifications. There was no case of instability or recurrence.

According to SOFCOT (13) criteria, at the last follow-up, we obtained 15(58%) of minim and moderate elbow stiffness. And according to DI-SCHINO (14) criteria at the last follow-up, 7 (27 %) have a very good result, 7 (27%) have a good result, 10 (38%) have a fair result, and 2 (8%) have a poor result. The very good and good results were obtained in patients with a duration of symptoms less than 3 months. Table II compares the results before and

after surgery. Table III presents subjective results after surgery.

Table I. — Demographic characteristics of the patients

Demographic characteristics of the patients:	Number of patients
Age	10 years (4-14 years)
Gender:	
Male	17
Female	9
Side:	
Right	7
Left	19
Duration of symptoms:	
< 3 months	16
>3 and < 6 months	6
> 6month	4
Origin:	
Urban	5
Rural	21
Mode of injury:	
Fall from height	21
Road traffic injury	1
Sport accident	4
Type of dislocation:	
Simple	9
Complex	17

Table II. — Result according to SOFCOT criteria before and after surgery

SOFCOT Criteria	Preoperative	Postoperative
Minimal stiffness	0	8
Moderate stiffness	2	7
Severe stiffness	7	7
Very severe stiffness	17	4

Table III. — Subjective results after surgery

Subjective criteria	Frequency
Pain:	
No pain	23
After effort	2
Chronic	1
Feeding oneself	2
Putting shirt	3
Sportive activity	4
Writing	1

DISCUSSION

Treatment of neglected elbow dislocation in children is a challenge for every pediatric surgeon. It's a common condition in developing countries due to several factors as poverty, ignorance, health system inaccessibility, and finally the expensive cost of treatment for parents. The majority of the patients consult bonesetters, who manipulate the elbow with massage and traction, aggravating the elbow stiffness, and delaying consultation in adequate hospital structures.

Elbow dislocation is considered neglected when it's left unreduced for more than 3 weeks (5-8). During this period, several phenomena occur, starting from the second week after dislocation making the closed reduction difficult, and impossible in the third week. These phenomena are characterized by a retraction of the triceps, collateral ligaments and the capsule, heterotopic ossification, and extensive articular fibrosis. The anterior and posterior capsule retraction is responsible for the elbow stiffness (15). The stiffness of the elbow leads to a restriction of the range of motion (ROM), with a fixed arm which affects the practice of daily activities especially in children, it may deteriorate their self-esteem.

The goal of treatment is to obtain an anatomic reduction and stable elbow to restore a functional ROM of the elbow. The indication of treatment in children with NED is not consensual, it depends on the age of the patient, chronicity, and ROM at presentation. In patients with satisfactory ROM, even with an elbow dislocation, some authors preferred abstention (16-18). In addition to the current study, various studies surrounding the pediatric population have reported satisfying functional outcomes, even in patients with above 3 months NED. Irianto et al (19) have reported a ROM greater or equal to 70° in all patients treated for NED of beyond 3 months, by open reduction. Attaraf et al (20) have reported very good and good results in 18 patients treated with open reduction. In our study, 10/26 have NED for more than 3 months, and 80% (8/10) have a good ROM at the last follow-up. Based on our results and the others series, the open reduction is the best option for treatment of the NED in children regardless of the chronicity of the injury.

Several techniques have been described to achieve a stable and painless elbow with a functional ROM. A hinged elbow distraction device was proposed for 6-8 weeks especially in children, but it was not advocated anymore because of the high failure outcome (21). The lengthening of the triceps through a posterior approach, as described by Speed (22), improves the ROM. On the other hand, it provokes a weakness of the triceps, delays physiotherapy, and increases post-surgical pain (23). Recent techniques have been described by Anderson et al. (23) to length the triceps without VY muscle plasty. Rather by the repeated piercing of the percutaneous tendon with an 18 G needle, in only patients with simple dislocation. Different approaches can be used to reduce the elbow, posterior, internal, lateral, or combined internal and lateral approach. It all depends on the surgeon's preferences.

Until the moment, there is no clear consensus about the need for reconstruction of elbow ligaments to maintain stability. Advocates of ligaments reconstruction suggest that the non-reconstruction of the collateral ligaments can cause an elbow instability, once the ROM is restored (24). Critics of ligaments reconstruction, however, claim that the non-anatomic potential ligaments reconstruction could restrict the ROM and can subject the articular surfaces to increased pressure and development of arthritis (7,8). To avoid the non-isometric ligaments reconstruction, Aminata et al (25) has described a "box loop" ligament reconstruction in NED with excellent results. Besides that, some authors suggest using a hinged external fixator after open reduction to provide more stability and to commence early physiotherapy (19,23,26,27). In our series, the ligaments reconstruction was performed in 16 patients to provides more stability when the elbow appears unstable in intraoperative. None of our patients developed elbow instability or had recurrent elbow dislocation.

Conflicting views have been expressed about performing ulnar nerve transposition or not, the overall emphasis should be on careful dissection and avoid incarcerating it within the joints with reduction maneuver. In our series, we didn't perform any transposition of the ulnar nerve and no case of nerve palsy was noted.

In the current study, the perioperative complications noted were 4 cases of heterotopic calcifications which did not influence the ROM in any patient, and it was managed by physical therapy.

Until the moment, there is no clear consensus about the postoperative protocol. Most authors prefer immobilization between 10 to 21 days (18-20,28), to maintain reduction, avoid more triceps contraction, and commence early rehabilitation. Early rehabilitation was associated with good outcomes, and most authors recommend it (20,29,30).

Our findings are consistent with those of other studies of NED in children which obtained good results with open reduction regardless of the duration of the symptoms (19,20). However, as reported by many authors, the complex NED is associated with poor outcomes (7,20). This study has several limitations. First, due to its retrospective design, surgery performed by different surgeons, small sample size, heterogeneous techniques, lack of control group. However, this is the largest series of NED in children treated by open reduction.

The treatment of NED in children remains a challenge for every pediatric surgeon, due to apparent conflicting goals of restoring functional ROM and maintaining elbow's stability with the minimum soft tissue injuries. The early diagnosis of elbow dislocation by careful analysis of the X-ray is the best guarantee of good outcomes. The open reduction and the early rehabilitation remain the keystone of treatment of NED in children regardless of the chronicity of the injury. Finally, prevention remains the best way to improve the prognosis of neglected elbow dislocations. It must rest on two main pillars. The first is the fight against traditional treatment. And the second pillar of this prevention is improving the supply of care, in terms of affordability for the poor, as well as the speed and quality of treatment for acute dislocations of the elbow.

REFERENCES

1. Subasi M, Isik M, Bulut M, Cebesoy O, Uludag A, Karakurt L. Clinical and functional outcomes and treatment options for pediatric elbow dislocations: Experiences of three trauma centers. *Injury*. 2015;46(2):14-18.
2. Kozin SH, Abzug JM, Safier S, Herman MJ. Complications of pediatric elbow dislocations and Monteggia fracture-dislocations. *Instr Course Lect*. 2015;64:493-498.
3. Lieber J, Zundel SM, Luithle T, Fuchs J, Kirschner H-J. Acute traumatic posterior elbow dislocation in children. *J Pediatr Orthop Part B*. 2012;21(5):474-481.
4. Sinikumpu J-J, Lautamo A, Pokka T, Serlo W. Complications and radiographic outcome of children's both-bone diaphyseal forearm fractures after invasive and non-invasive treatment. *Injury*. 2013;44(4):431-436.
5. Naidoo KS. Unreduced posterior dislocations of the elbow. *J Bone Joint Surg Br*. 1982;64(5):603-606.
6. Freeman BL III. Old unreduced dislocations. In: Crenshaw AH, editor. *Campbell's operative orthopedics*. Vol I, 9th ed. St Louis: Mosby; 1998. p.2673-2674.
7. Mehta S, Sud A, Tiwari A, Kapoor SK. Open reduction for late-presenting posterior dislocation of the elbow. *J Orthop Surg (Hong Kong)*. 2007;15(1):15-21.
8. Elzohairy MM. Neglected posterior dislocation of the elbow. *Injury*. 2009;40(2):197-200.
9. Andrew HC. Old unreduced dislocations. In: Frederick M, James HB, Canale ST, editors. *Campbell's operative orthopaedics*. 13th ed., vol. 61. Elsevier Inc.; 2017. p. 3155-3159
10. Daphne MB, Whitcomb P, Graham JW. Elbow fractures and dislocations. In: *Rockwood and green's fractures in adults*. 8th ed. Wolters Kluwer; 2015. p.1180-1190.
11. Linscheid RL, Wheeler DK. Elbow Dislocations. *JAMA*.1965;194(11):1171-1176.
12. Islam S, Jahangir J, Manzur RM, Chowdury AAA, Tripura N, das A. Management of neglected elbow dislocations in a setting with low clinical resources. *Orthop Surg*. 2012; 4(3):177-181.
13. Esteve P, Valentin P, Deburge A, Kerboul M. Post-traumatic stiffness and ankylosis of the elbow in children. *Rev Chir Orthop Reparatrice Appar Mot*. 1971;57(1):25-86.
14. Di Schino M, Breda Y, Grimaldi F, Lorthioir J, Meriem Y. Traitement chirurgical des luxations négligées du coude (A propos de 81 observations). *Rev Chir Orthop*. 1990;(76):303-310.
15. Morrey B, Sanchez-Sotelo J, Morrey M. Elbow Stiffness: Basic Science and Overview dislocations. In: *The Elbow and Its Disorders*. 5th éd. Philadelphia: ElsevierInc; 2018. p.529-34.
16. Fowles JV, Kassab MT, Douik M. Untreated posterior dislocation of the elbow in children. *J Bone Joint Surg Am*. 1984;66(6):921-926.
17. El Alami ZF, Teklali Y, Dendane MA, Amrani A, El Madhi. Les luxations du coude négligées chez l'enfant (à propos de 33 cas). *Le journal de l'orthopédie*. 2002;693-695.
18. Teklali Y, Afifi A, Amrani A, El Alami, El Madhi A. Stiffness after neglected elbow trauma in children: report of 57 cases. *Eur J Orthop Surg Traumatol*. 2004;14(1):35-37.
19. Irianto KA, Parung R, Sukmajaya WP. Open reduction in neglected elbow dislocation in children: a case series. *Universa Med*. 2019;38(1):63-68.

20. Atarraf K, Arroud M, Chater L, Afifi MA. La luxation chronique du coude chez l'enfant : à propos de 20 cas. *Pan Afr Med J.* 2014;18:348.
21. Lyons RP, Armstrong A. Chronically unreduced elbow dislocations. *Hand Clin.* 2008;24(1):91-103.
22. Speed J. An operation for unreduced posterior dislocation of the elbow. *South Med J.* 1925;18(3):193-197.
23. Anderson DR, Haller JM, Anderson LA, Hailu S, Chala A, O'Driscoll SW. Surgical Treatment of Chronic Elbow Dislocation Allowing for Early Range of Motion: Operative Technique and Clinical Results. *J Orthop Trauma.* 2018;32(4):196-203.
24. Krishnamoorthy S, Bose K, Wong KP. Treatment of old unreduced dislocation of the elbow. *Injury.* 1976;8(1):39-42.
25. Aminata IW, Efar TS, Canintika AF. Chronically unreduced elbow dislocation treated with box-loop ligament reconstruction: The first case series. *J Clin Orthop Trauma.* 2019;10(1):123-126.
26. Jupiter JB, Ring D. Treatment of unreduced elbow dislocations with hinged external fixation. *J Bone Joint Surg Am.* 2002;84(9):1630-1635.
27. Coulibaly NF, Tiemdjo H, Sane AD, Sarr YF, Ndiaye A, Seye S. Posterior approach for surgical treatment of neglected elbow dislocation. *Orthop Traumatol Surg Res.* 2012;98(5):552-558.
28. Salihu M, Arojuraye S, Ai A, Usman M, Ndubuisi O, Ayeni F. Old unreduced elbow dislocation: Patients' perspectives on outcome of open reduction. *Surgeon.* 2021;19(2):87-92.
29. Maru ND, Sayani K, Ramesh. A rare case of pediatric neglected elbow dislocation treated with speed procedure. *Gujarat Med J.* 2015;70:103-104
30. Ivo R, Mader K, Dargel J, Pennig D. Treatment of chronically unreduced complex dislocations of the elbow. *Strat Traum Limb Recon.* 2009;4(2):49-55.