

# DEVELOPMENT OF A DESMOID TUMOR AT THE SITE OF A TOTAL HIP REPLACEMENT

M. GEBHART<sup>1</sup>, M. FOURMARIER<sup>1</sup>, O. HEYMANS<sup>1</sup>, J. ALEXIOU<sup>2</sup>, P. YENGUÉ<sup>1</sup>, N. DE SAINT-AUBAIN<sup>3</sup>

Extra-abdominal desmoid tumors are locally aggressive benign soft tissue tumors arising from the connective tissue of muscle and overlying fascia or aponeuroses. Location around the hip occurs in about 10% of all desmoid tumors. The authors report the development of a desmoid tumor around the hip 45 months after implantation of a total hip prosthesis.

Endocrine and physical factors seem to play an important role in the development of the disease. Moreover, an association has been reported between trauma and desmoid tumor. Desmoid tumors developing around silicon implants have also been described. However, no association between hip prostheses and desmoid tumors has been published in the world literature. Although soft tissue tumors induced by metallic implants have been observed clinically, we still seek a coherent explanation for the exact pathogenesis.

**Keywords :** desmoid tumor ; prosthesis.

**Mots-clés :** tumeur desmoïde ; prothèse.

## INTRODUCTION

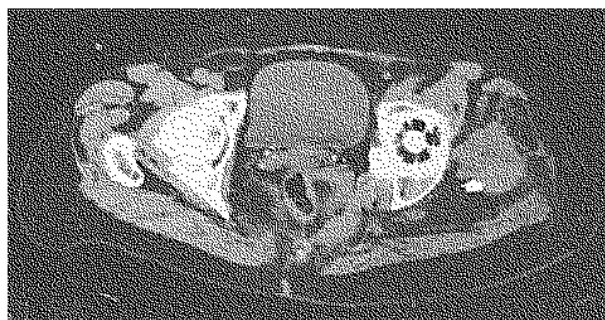Extra-abdominal desmoid tumors are locally aggressive benign soft tissue tumors arising in connective tissue of muscle and in overlying fascias or aponeuroses. Clinically, this tumor is characterized by a deeply seated, firm, soft tissue mass with a tendency to infiltrate the surrounding tissues. Pain and local tenderness occur only at a later stage of the natural history of this tumor. Desmoid tumors within the pelvis or around the hip joint represent only 10% of the cases of this type of tumor.

Multiple causes have been evoked as possible origins for the development of a desmoid tumor. Despite a thorough search of the world literature, we did not find any reports describing the devel-

opment of a desmoid tumor at the site of a total hip replacement. We report such a case. A review of the literature concerning desmoid tumors, and particularly their pathogenesis, has been included.

## CASE REPORT

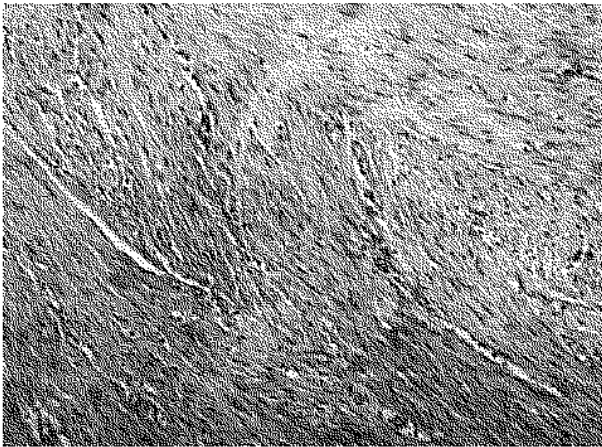
A 69-year-old female presented in 1990 with osteoarthritis of the left hip joint. A total hip replacement, using a Charnley-Müller prosthesis, was performed. No tumor was identified during the operative procedure. Initially, the patient's rehabilitation program did not cause any difficulty, and the patient's gait was considered normal 2 months after surgery. Two years after the operation, the patient noted increasing pain and discomfort around the hip. Medical work-up revealed a mass around the prosthetic hip joint (fig. 1) and



*Fig. 1.* — Computed tomodensitometry of the left hip showing a desmoid tumor developing around the proximal femur.

<sup>1</sup> Department of Orthopedics, <sup>2</sup> Department of Radiology and <sup>3</sup> Department of Pathology, Institut Bordet, Brussels, Belgium.

Correspondence and reprints : M. Gebhart, 1, rue Héger-Bordet, B-1000 Brussels, Belgium.



*Fig. 2.* — Histological aspect of the tissue showing a typical pattern of desmoid tumor with its interlacing bundles of fibroblastic cells.

a biopsy confirmed the diagnosis of desmoid tumor (fig. 2). The tumor was initially considered as unresectable in another hospital, and a trial with chemotherapy was started, using adriamycin and isophosphamide without any effect on the tumor. Hemipelvectomy was considered, but was refused by the patient. She then consulted at our cancer center, and a marginal resection of several tumor locations arising within the pseudo-capsule of the hip prosthesis was performed in 1994. Full-dose radiotherapy (6000 rads) was administered at the tumor site. Currently, 45 months after surgery, no recurrent tumor has been demonstrated.

## DISCUSSION

The term “desmoid tumor” was first coined by Müller in 1838. However, aggressive fibromatosis, non metastasizing sarcoma and low-grade fibrosarcoma have also been used. Posner *et al.* (17) consider desmoid tumors as malignant soft-tissue tumors. In addition, the American Cancer Society lists this tumor as a low-grade soft-tissue sarcoma (20). Despite the aggressive local behavior, the rare occurrence of metastases and the absence of malignant cell characteristics permit classification of this tumor in the group of benign tumors rather than low-grade malignant tumors. Indeed,

low-grade fibrosarcomas have at least one mitosis per 10 high-power fields. One virtually never sees mitoses in a desmoid tumor (17). Moreover, reports describing the occurrence of desmoid tumor metastases probably correspond to a misdiagnosed primary tumor. On the other hand, Hardy's and Barbin's works suggest a possible malignant transformation of a benign desmoid tumor into a low-grade fibrosarcoma (1, 9). Typical desmoid tumors with low-grade fibrosarcoma foci within the same specimen have also been described (1). These findings suggest a continuum between benignity and malignity.

These tumors arise in musculo-aponeurotic structures. Forty-five to 50% (18) of them occur in the abdominal area, surrounding the rectus abdominis. The extra-abdominal desmoid tumors (40-45%) show a slight predilection for the shoulder or pelvic muscles (18). Desmoid tumors arising in the hip represent 5 to 10% of the cases. Mesenteric locations represent 3 to 10% (18).

Reitamo *et al.* (18) and Dahn *et al.* (3) evaluated the incidence of this tumor at about 2-4/100000 persons/year. Desmoid tumors predominate in young patients, especially between 25 and 40 years of age (6, 17). They rarely affect infants or the very elderly (6). Women are more commonly affected than men, but the literature data vary in this regard (4, 5, 13, 17, 18). There is no evidence of any increased incidence in a particular race (6).

Endocrine and physical factors seem to play an important role in the development of the disease. Indeed, 50% of women who develop desmoid tumors are described as “estrogen predominant” (10, 19). Estrogen-related growth is suggested by the inhibitory effect of antiestrogens and interruption of growth and even tumor regression after menopause (3, 6, 15). However, the estrogen-receptor protein seems to be within normal limits (10, 24).

Physical factors such as blunt and surgical trauma or radiation have been described as a trigger mechanism for the development of desmoid tumors (10). Lopez *et al.* note in 28% of cases an association between trauma and desmoid tumor (13). However, only surgical trauma could be accurately verified. Thirty-two percent of extra-abdominal desmoid tumors were associated with

previous surgical trauma (10). The history of non-surgical trauma, often associated with desmoid tumors, is less clear since it is based only on speculation. Nevertheless, many such cases were described in the world literature (6, 23). Enzinger and others also described postirradiation desmoid tumors (1, 6).

Several soft tissue tumors have been induced by carcinogen exposure like nickel sulfide (7, 11, 16) (leiomyosarcoma, rhabdomyosarcoma, fibrosarcoma) but there are no reports of the development of desmoid tumors in such experiments. Desmoid tumors have not been described in association with the use of any carcinogen. On the other hand, intramuscular injections of titanium powder in mice induced fibrosarcoma and lymphosarcoma (14).

The prefibroblast derives from the mesoblast, which arises from the primary embryonic germ layer, the mesoderm. The prefibroblast represents a "stem cell" and, in a proper biochemical environment, it can give rise to a collagenoblast, lipoblast, myoblast, osteoblast or chondroblast (9). Therefore, it should not be surprising that several different connective tissue cellular elements may be found in one tumor. Furthermore, these findings suggest that a carcinogenic element may induce several foci of soft tissue tumors.

Bioprosthetic implants have been described in association with desmoid tumors. In fact, several case reports of desmoid tumors arising from a capsule around silicon breast implants have been published (12, 21). Another silicon device that has been associated with the development of desmoid tumors is the cerebrospinal fluid shunt (8). Multiple intramuscular injections have been described as causing the development of a desmoid tumor (10). The question remains whether it is caused by multiple trauma or by a silicon needle.

The association of a desmoid tumor with a hip prosthesis has never been reported. However, hip prostheses are made of different metal alloys (stainless steel, Cr-Co, Cr-Ni, Ti), hydroxyapatite and polyethylene. Even if the evidence is not clear, these chemical products could be carcinogenic. Svensson *et al.* (22) reported a case of a soft tissue pseudotumor developing around a hip prosthesis. It was a granulomatous lesion, probably induced

by metal. In fact, in uncemented stainless steel implants, the contact surface between bone and metallic implant may cause increased release of metallic iron. Further, corrosion may occur and a vicious cycle may ensue, with progressive release of iron causing tissue irritation. Histologically, metal particles are commonly found in tissue around a hip prosthesis.

On the other hand, the development of a desmoid tumor around a hip prosthesis may be induced only by the surgical trauma, as several types of implants have been associated with desmoid tumors.

The natural history of an untreated desmoid tumor is usually a slow, relentless growth with invasion of adjacent structures (17). Furthermore, the clinical features depend on the tumor localization. Despite their histological benignity, desmoid tumors tend to recur without adequate treatment. Lopez *et al.* (13) for instance reported a recurrence rate of 60% in adults and 88% in children. Recurrence usually becomes apparent during the first 2 or 3 years following the initial resection. Cases with two or more recurrences are not rare (6, 17).

Most authors believe that the best hope for the primary cure of the disease consists in total excision of the tumor (4). Unfortunately even when surgical and histological margins are clear of tumor, the recurrence rate is high. However, re-excision of residual or recurrent disease is indicated when possible, because the recurrence rate following a second and even a third excision is at most equal to or even lower than the recurrence rate after the first attempt (4). Wide or marginal resection is not recommended by all authors; some favor on the other hand surgical abstention, emphasizing the benignity of the tumor and the self-limiting tumor growth (2, 19). Posner *et al.* (17) evaluate the five-year survival rate at 92%.

## CONCLUSIONS

Desmoid tumors developing around silicon devices have been reported. However, no association between desmoid tumors and hip prostheses has been described before. Although soft tissue tumor

induced by metal remains a hypothesis, experimental studies report an association between metal injection (Ni, Cr, Ti) and development of fibrosarcoma or leiomyosarcoma in mice. Surgical trauma may also be the trigger mechanism in the development of a desmoid tumor around an artificial hip joint. On the other hand, one may not reject the possible relationship between desmoid tumor and a metallic implant.

Nevertheless, experimental studies report the association between metal injection (Ni, Cr, Ti) and the development of fibro- or leiomyosarcoma in mice.

Because of the high recurrence rate, wide excision with tumor-free margins is the only efficient treatment for desmoid tumors. In practice, this benign tumor must be treated locally as a malignant one, and very often radiation therapy is necessary to achieve good local control. Nevertheless, some authors favour abstention.

## REFERENCES

1. Barbin J. Y., Duveau D., Aillet G., Dabouis G., Lacroix H., Remadi J. P., Michaud J. L. Les tumeurs desmoïdes : un diagnostic et une thérapeutique difficiles. *Chirurgie*, 1992, 118, 511-515.
2. Cole N. M., Guiss L. W. Extra-abdominal desmoid tumors. *Arch. Surg.*, 1969, 98, 530-533.
3. Dahn I., Jonsson N., Lundh G. Desmoid tumors. A series of 33 cases. *Acta Chir. Scand.*, 1963, 126, 305-314.
4. Easter D. W., Halasz N. A. Recent trends in the management of desmoid tumors. Summary of 19 cases and review of the literature. *Ann. Surg.*, 1989, 210, 765-769.
5. Enzinger F. M., Shiraki M. Musculo-aponeurotic fibromatosis of the shoulder girdle (extra-abdominal desmoid) : analysis of 30 cases followed up for 10 or more years. *Cancer*, 1966, 21, 1131-1140.
6. Enzinger F. M., Weiss S. W. *Soft tissue tumors*. Mosby, St Louis, 1992, pp. 201-227.
7. Gilman J. P. W. Metal carcinogenesis. II. A study on the carcinogenic activity of cobalt, copper, iron, and nickel compounds. *Cancer Res.*, 1962, 22, 158-162.
8. Gonzalez-Darder J., Alacreu J. B., Garcia-Vazquez F. Desmoid tumor arising around the distal tubing of a cerebrospinal fluid shunt. *Surg. Neurol.*, 1986, 26, 365-367.
9. Hardy J. D. The ubiquitous fibroblast. Multiple oncogenic potential with illustrative cases. *Ann. Surg.*, 1987, 205, 445-455.
10. Häyry P., Reitamo J. J., Tötterman S., Hopfner-Hallickainen D., Sivula A. The desmoid tumor. II. Analysis of factors possibly contributing to the etiology and growth behavior. *Am. J. Clin. Path.*, 1982, 77, 674-680.
11. Hildebrand H. F., Biserte G. Nickel sub-sulphide-induced leiomyosarcoma in rabbit white skeletal muscle. *Cancer*, 1979, 43, 1358-1374.
12. Jewett S. T., Mead J. H. Extra-abdominal desmoid tumor arising from a capsule around a silicone breast implant. *Plast. Reconstr. Surg.*, 1979, 63, 577-579.
13. Lopez R., Kemalyan N., Moseley H. S., Dennis D., Vetto R. M. Problems in diagnosis and management of desmoid tumors. *Am. J. Surg.*, 1990, 159, 450-453.
14. Lauwerys R. *Toxicologie industrielle et intoxication professionnelle*. Paris, Masson, 1992, pp. 242-252.
15. McDougall A., McGarrity G. Extra-abdominal desmoid tumor. *J. Bone Joint Surg.*, 1979, 61-B, 373-380.
16. Ohmori T., Uruga N., Komi K., Tabei K., Tabei R., Shibata T. The role of bone fracture at the site of carcinogen exposure on nickel carcinogenesis in the soft tissue. *Japan. J. Cancer Res.*, 1990, 81, 1247-1252.
17. Posner M. C., Shiu M. H., Newsome J. L., Hajdu S. I., Gaynor J., Brennan M. F. The desmoid tumor. Not a benign disease. *Arch. Surg.*, 1989, 124, 191-196.
18. Reitamo J. J., Häyry P., Nykyri E., Saxen E. The desmoid tumor. I. Incidence, sex, age- and anatomical distribution in the Finnish population. *Am. J. Clin. Path.*, 1982, 77, 665-673.
19. Reitamo J. J., Scheinin T. M., Häyry P. The desmoid syndrome. New aspects in the cause, pathogenesis and treatment of the desmoid tumor. *Am. J. Surg.*, 1986, 151, 230-237.
20. Russel W. O., Cohen J., Enzinger F. M. A clinical and pathologic staging system for soft tissue sarcoma. *Cancer*, 1981, 31, 271-280.
21. Schuh M. E., Radford D. M. Desmoid tumor of the breast following augmentation mammoplasty. *Plast. Reconstr. Surg.*, 1994, 95, 603-604.
22. Svensson O., Mathiesen E. B., Reinholt F. P., Blomgren G. Formation of a fulminant soft-tissue pseudotumor after uncemented hip arthroplasty. *J. Bone Joint Surg.*, 1988, 70-A, 1238-1242.
23. Urist M. R. Trauma and neoplasm. Report of a case of desmoid tumor following simple fracture of the radius and ulna. *Am. J. Surg.*, 1957, 93, 682-693.
24. Weiss S. W., Langloss J. M., Shmookler B. M. Estrogen receptor protein in bone and soft tissue tumor. *Lab. Invest.*, 1986, 54, 689-695.

## SAMENVATTING

*M. GEBHART, M. FOURMARIER, O. HEYMANS, J. ALEXIOU, P. YENGUE, N. DE SAINT-AUBAIN. Ontwikkeling van een desmoïdtumor ter hoogte van een totale heupprothese.*

Extra-abdominale desmoïde tumoren zijn agressief goedaardige tumoren van de weke weefsels die in de bindweefsels van spieren, fascia en aponeurosen optreden. De localisatie in de heup is ongeveer 10% van het totale aantal desmoïde tumoren.

De auteurs melden een geval van dergelijke tumor welke verschijnt ter hoogte van de heup 45 maanden na de plaatsing van de prothese. De endocriene factoren en de fysische factoren lijken een rol te spelen in het verschijnen van dit letsel. Bepaalde auteurs hebben trouwens een associatie tussen trauma en desmoïde tumor gevonden. Ook werden ze beschreven rond siliconenimplant. Dergelijke associatie blijft evenwel zeldzaam. Wij vonden geen coherente uitleg om de pathogenese van dit letsel te verklaren.

## RÉSUMÉ

*M. GEBHART, M. FOURMARIER, O. HEYMANS, J. ALEXIOU, P. YENGUE, N. DE SAINT-AUBAIN. Apparition d'une tumeur desmoïde au niveau de la hanche après arthroplastie par prothèse totale.*

Les tumeurs desmoïdes extra-abdominales sont des tumeurs bénignes agressives des tissus mous qui naissent à partir du tissu conjonctif des muscles et des fascias et aponévroses sus-jacents. La localisation à la hanche représente environ 10% du total des tumeurs desmoïdes. Les auteurs présentent le cas d'une tumeur desmoïde qui est apparue au niveau de la hanche 45 mois après implantation d'une prothèse totale. Les facteurs endocriniens et les facteurs physiques semblent jouer un rôle important dans l'apparition de cette lésion. Certains ont noté par ailleurs une association entre traumatisme et tumeur desmoïde. On a aussi décrit des tumeurs desmoïdes apparues autour d'implants en silicone. Cependant, l'association d'une tumeur desmoïde et d'une prothèse de hanche n'a pas encore été publiée dans la littérature mondiale. Bien que l'on ait observé en clinique des cas d'induction d'une tumeur des tissus mous par implants métalliques, nous n'avons pas pu trouver une explication cohérente à la pathogénie de la lésion ici rapportée.