



Improved long-term functional outcome after a latissimus dorsi transfer with or without subscapularis muscle lengthening or release

Stijn DE JOODE, Lazin GERMAWI, Martijn SCHOTANUS, Juul VAN DER LINGEN, Tom VAN MULKEN, Ferry VAN NIE, Steven SAMIJO

From the Department of Orthopaedic Surgery and Traumatology, Zuyderland Medical Center, location Heerlen, the Netherlands

A brachial plexus birth injury (BPBI) can lead to a limited shoulder function, especially abduction and external rotation. One of the treatment options to restore those shoulder functions is a latissimus dorsi transfer (LDT). The aim of this study is to analyze long-term functional outcome after a single LDT and compare these results with LDT combined with subscapularis muscle lengthening (SSL) or subscapularis muscle release (SSR).

This cohort study included 39 patients (≤ 12 years old) with one-sided BPBI. All patients had an internal rotation- and adduction contracture without glenohumeral joint deformity. A LDT was performed with or without SSL or SSR, resulting in 3 patient study groups. Demographic data and pre- and post-operative-Mallet scores were collected and analysed for each group.

The median age was 4.0 years (IQR 3.1) and there were no differences in patient demographics. In all patients surgery improved external rotation and overall shoulder function, at 9.8 years follow-up. Also, the total Mallet score increased significantly with 1.7 ($p=0.001$) in our (entire) study cohort.

A LDT, with a SSL or SSR in case of an intra-operative internal contracture, improves shoulder function and preserves external rotation in patients (≤ 12 years old) with BPBI, at a follow up of 9.8 years.

Keywords: brachial plexus birth injury ; latissimus dorsi transfer ; subscapularis lengthening ; subscapularis release ; long-term follow-up.

INTRODUCTION

A brachial plexus birth injury (BPBI) occurs in 0.4-5.1 of 1000 childbirths due to lateral traction on the baby's head during birth (1-8). Shoulder dystocia, a high birth weight (≥ 4 kg) and assisted delivery are major risk factors associated with brachial plexus birth injuries (4). Due to increased birth weights, the

- Stijn De Joode^{1,4,5}
- Lazin Germawi¹
- Martijn Schotanus^{1,5}
- Juul Van der Lingen¹
- Tom Van Mulken²
- Ferry Van Nie³
- Steven Samijo¹

¹Department of Orthopaedic Surgery and Traumatology, Zuyderland Medical Center, location Heerlen, the Netherlands.

²Department of Plastic Surgery, Maastricht University Medical Center, Maastricht, the Netherlands.

³Department of Neurosurgery, Zuyderland Medical Center, location Heerlen, the Netherlands.

⁴Department of Orthopaedic Surgery and Traumatology, Spital Grabs, Grabs, Switzerland.

⁵Care and Public Health Research Institute (CAPHRI) Maastricht, Maastricht, the Netherlands.

Correspondence : Stijn Gerardus Coenraad Johanna de Joode, Department of Orthopaedic Surgery and Traumatology, Zuyderland Medical Centre, PO Box 5500, 6130 MB Sittard-Geleen, The Netherlands. Phone : 0031622829553, ORCID ID: 0000-0002-8217-0120.

Email : sdejoode55@gmail.com

© 2021, Acta Orthopædica Belgica.

incidence of BPBI rises, despite advancements in obstetric care (5-6).

A brachial plexus lesion may lead to shoulder rotator cuff muscle imbalances which could result in a glenohumeral internal rotation and adduction contracture. This shoulder condition can be followed by glenohumeral dysplasia, i.e. glenoid retroversion and posterior humeral head (sub)luxation (1-3,6-9).

Although 70% of BPBI cases recover spontaneously within 6-months after birth, surgical plexus reconstruction is required in 30% of BPBI cases in order to improve shoulder and arm function (8). Whether or not primary surgical reconstruction has been performed, secondary surgical procedures are sometimes necessary to improve upper extremity function. A specific disability in such, is the lack of external rotation and abduction of the affected shoulder. To improve those specific movements, a latissimus dorsi transfer (LDT) can be considered (1-3,7-9). If the latissimus dorsi muscle is not of good quality, the teres major muscle as well can be transferred to the major tuberosity of the humeral head (double transfer). In some cases external rotation of the shoulder is inhibited due to contracture of the subscapularis muscle. In these cases, LDT has been combined with either lengthening of the subscapularis muscle by performing a Z-incision at the insertion (SSL), or a release at the origin at the scapula (SSR). To our knowledge, no studies compared the results of a single LDT with a LDT + SSL or a LDT + SSR before. Moreover, few studies described the results of a single LDT in BPBI at long term follow-up.

It can be expected that the transferred tendon strength remains the same even multiple years after the operation. However, it is hypothesized that the transferred tendon could adapt to stretching with elongation of the muscle-tendon unit, resulting in a diminished tenodesis effect and therefore a decreased function of the shoulder, i.e. abduction and external rotation (10-12). Therefore it can be questioned whether the short-term gain of function will remain the same during longer follow-up. The aim of this study is to assess the long-term (> 5 year) functional outcome after a single LDT and compare these results with LDT combined with SSL or SSR.

MATERIALS AND METHODS

In this single-center hospital-based cohort study, we reviewed the medical records of patients with BPBI who underwent a single LDT or a LDT combined with either SSL or SSR between 1994 and 2008 in the Netherlands. The study was approved by our Institutional Review Board and informed consent was obtained from all individual participants included in this study (IRB, METC Z ; File nr. 17N168).

Using our institutional database, 72 BPBI patients who had undergone a latissimus dorsi transfer were identified. The medical records of those patients were manually reviewed by two independent medical researchers. After reviewing the medical records, 39 patients (≤ 12 years old) were included. All included patients had an internal rotation- and adduction contracture.

Our exclusion criteria were inadequate power of the latissimus dorsi muscle before surgery (MRC-scale <5) (13), a double transfer, a greater pectoralis lengthening or release or secondary surgery at the affected shoulder, prior to the LDT. Also, patients with impaired elbow- or hand function measured by the Gilbert-Raimondi function score (14) and the Raimondi function score (14) were excluded, since good pre-operative elbow- and hand function is essential for a functional arm after the operation.

The final study population was divided into the following three groups : 1) patients that underwent a single LDT, 2) patients that underwent LDT + SSL and 3) patients that underwent LDT + SSR.

Surgical procedures and follow-up

All patients underwent surgery under general anesthesia. During the single LDT (extensively described by J.M. Abzug, 2017 (9)), the patient was positioned at the lateral side. The latissimus dorsi muscle was identified, released and cut at the insertion of the humerus. Afterwards the tendon was tunneled under the posterior deltoid muscle and attached to the major tuberculum of the humerus using a Mitek anchor (Du puy/Synthes) or a Biocork 3.5 screw (Artrex). The tension of the subscapularis muscle and the internal rotation contracture was

observed. During the surgical procedure, no muscle relaxants were used. The surgeon decided intra-operatively whether to perform a single LDT or a LDT combined with a SSL or SSR, depending on the amount of muscle tension and internal rotation contracture. Post-operatively, the patient was put in a cast in 70 degrees abduction and at least 60 degrees external rotation during 6 weeks.

The operation was preferably executed before the age of 7 years old. This has shown to give better results, possibly due to increased soft tissue remodel-ability and decreased amount of shoulder deformity (3,15-17). During the period patients in this study cohort underwent their surgery, there was little consensus in the literature about which surgical procedure to perform. No teres major tendon transfers or greater pectoral muscle releases were done in this study cohort.

During follow-up, patients were intensively treated by a physiotherapist to maintain strength and range of motion of the upper extremity.

Every 2 years, patients were invited at the out-patient clinic for a medical interview and physical examination. During these follow-up appointments the function of the hand, arm and shoulder was evaluated and the Mallet-score was assessed. A score of 25 means maximum active shoulder function, 0 means no shoulder function at all (16). Follow-up for this study ended if patients were admitted for a new shoulder operation.

Statistics

Descriptive statistics were used to describe the patient, baseline and follow-up characteristics of the

population. Shapiro-Wilk test was used to test the Mallet-scores for normal distribution. Paired sample T-tests were used for normally distributed Total Mallet-scores of the overall population. Parametric data are presented as mean \pm standard deviation (SD), such as Total Mallet-score in the overall population. Non-parametric data are presented as median with the interquartile range (IQR). A p-value of ≤ 0.05 was considered as statistically significant. All statistical analyses were performed using SPSS version 23.0.

RESULTS

In our institutional database of 72 BPBI patients who underwent a latissimus dorsi transfer, 39 children (n=19 boys) met the inclusion criteria. After reviewing the medical records, 33 patients were excluded. Twelve of these patients had secondary shoulder surgery prior to the LDT, 18 patients underwent a different operation technique, one patient had a double sided BPBI, one patient was older than 12 years old and in one patient there was missing follow up data.

The 39 included patients were all operated by the same surgeon who is experienced in performing surgery in BPBI patients. The included patients had a median age of 4.0 years at the time of surgery (IQR 3.1) and a median birth weight of 4000 grams (IQR 580). Thirteen out of 39 patients (33%) had brachial plexus reconstructive nerve surgery prior to the LD-transfer. The overall median follow-up time was 9.8 years (IQR 4.4). All patient characteristics of included patients and the separate treatment groups

Table I. — Baseline characteristics

	Single LDT	LDT + SSL	LDT + SSR	Total
No. of patients n (%)	7 (18)	20 (51)	12 (31)	39
Gender, male n (%)	5 (71)	5 (33)	9 (75)	19 (49)
Median Birth Weight, gram (IQR)	3975 (1127)	4100 (480)	3950 (790)	4000 (580)
Right sided, n (%)	4 (57)	11 (55)	7 (58)	22 R, 17 L
Prior nerve surgery	5	4	4	13
Median age at surgery, years (IQR)	6.1 (2.8)	3.9 (2.9)	3.1 (2.4)	4.0 (3.1)
Median Follow-up, years (IQR)	4.3 (6.6)	9.6 (3.3)	10.8 (2.5)	9.8 (4.4)

*Abbreviations : LDT= latissimus dorsi transfer, SSL=subscapularis muscle lengthening, SSR=subscapularis muscle release, IQR= interquartile range.

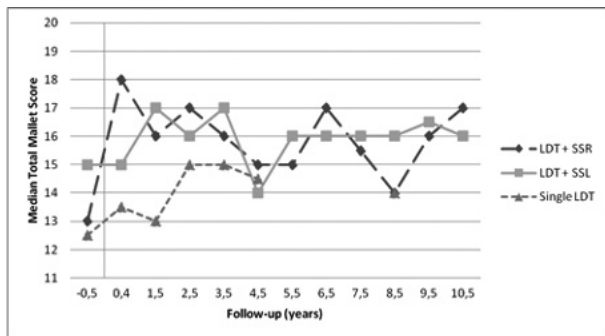


Figure 1. — Median Total Mallet Score during follow-up in the different groups. *Abbreviations : LDT= latissimus dorsi transfer, SSL= subscapularis muscle lengthening, SSR= subscapularis muscle release. A Minimum of 5 patients was set for a dot in the figure.

are presented in Table I. Follow-up ended earlier for one patient in the LDT + SSL group, since a humeral internal rotation osteotomy was performed. No other additional shoulder surgery was performed during the follow-up period.

Malletscore

The median Mallet-scores are presented in Table II. Comparing the three groups, an increased external rotation was observed in all groups. There was an increased active abduction and hand-to-neck function in the single LDT group and the LDT + SSR group. Hand-to-mouth function was increased in both the LDT + SSL and LDT + SSR group. Total mallet score improved in all three groups.

Table II. — Median mallet-scores before surgery and after latest follow-up

	Before surgery (IQR)	After follow-up (IQR)	Difference
Active abduction			
Single LDT	2.5 (1.0)	3.0 (1.0)	0.5
LDT + SSL	4.0 (0.0)	4.0 (1.0)	0.0
LDT + SSR	3.5 (1.0)	4.0 (1.0)	0.5
Total	4.0 (1.0)	4.0 (1.0)	0.0
External rotation			
Single LDT	2.0 (2.0)	3.0 (2.0)	1.0
LDT + SSL	2.0 (0.0)	3.0 (2.0)	1.0
LDT + SSR	2.0 (0.0)	3.0 (2.0)	1.0
Total	2.0 (0.0)	3.0 (2.0)	1.0
Hand-to-neck			
Single LDT	2.0 (1.0)	2.5 (1.0)	0.5
LDT + SSL	3.0 (0.0)	3.0 (1.0)	0.0
LDT + SSR	3.0 (1.0)	3.5 (2.0)	0.5
Total	3.0 (1.0)	3.0 (2.0)	0.0
Hand-to-back			
Single LDT	2.0 (1.0)	2.0 (1.0)	0.0
LDT + SSL	4.0 (2.0)	3.0 (1.0)	-1.0
LDT + SSR	3.0 (2.0)	2.5 (1.0)	-0.5
Total	3.0 (2.0)	3.0 (1.0)	0.0
Hand-to-mouth			
Single LDT	3.0 (1.0)	3.0 (1.0)	0.0
LDT + SSL	2.0 (0.0)	3.0 (1.0)	1.0
LDT + SSR	2.5 (1.0)	3.0 (1.0)	0.5
Total	2.0 (1.0)	3.0 (1.0)	1.0
Total Mallet score			
Single LDT	12.5 (5.0)	14.5 (3.0)	2.0
LDT + SSL	15.0 (3.0)	16.0 (3.0)	1.0
LDT + SSR	13.0 (3.0)	16.5 (5.0)	3.5
Total	13.0 (4.0)	16.0 (3.0)	3.0

*Abbreviations : LDT= latissimus dorsi transfer, SSL=subscapularis muscle lengthening, SSR=subscapularis muscle release, IQR= interquartile range.

There was no group with decreased active shoulder abduction, active shoulder external rotation, hand-to-neck, hand-to-mouth or total Mallet score at final follow-up compared with preoperative data. A decrease in hand-to-back function was observed in the LDT + SSL group (-1,0), and the LDT + SSR group (-0,5).

A small decrease in shoulder function was noticed during follow-up in all patient groups, compared to the results 6-months after surgery (Figure 1). Nevertheless, a significant increase of mean total Mallet-score of 1.7 ($p=0.001$, 95% CI -2.6 - -0.7) was measured before- (13.8 ± 1.9) and after 9.8 years follow-up (15.5 ± 2.5) in the total study population. The mean Mallet-scores were only calculated for the total population, since the 3 treatment groups were not normally distributed.

DISCUSSION

The aim of this study was to assess the long-term functional outcome after a single LDT and compare these results with LDT combined with SSL or SSR. The results of the present study show that the latissimus dorsi tendon transfer, with a SSL or SSR in case of an intra-operative internal contracture, is a good surgical technique to improve and preserve overall shoulder function ; especially abduction and external rotation, in children with brachial plexus birth injury at a median follow up of 9.8 years.

In patients with a brachial plexus birth injury different operating techniques are used to improve arm and shoulder function (9,18,19). For improvement of abduction and external rotation, a LDT or LDT combined with a teres major transfer, or a lower trapezius transfer is performed. However, there is still little consensus about which operative technique is best or should be combined (19). To our knowledge, no studies compared the results of a single LDT with a LDT + SSL or a LDT + SSR before. Moreover, few studies described the results of a single LDT in BPBI at long term follow-up.

The present study showed similar results as the study of Greenhill et al. where a combined latissimus dorsi and teres major transfer (double transfer) was performed (20). In that study a Mallet score improvement in abduction, external rotation

and a total Mallet score of respectively 0.5, 1.3 and 2.3 after 4.1 years follow-up was found. When comparing matched cohorts, they found that external rotation was significantly better when a double transfer was performed compared to an isolated teres major transfer. In addition to a single LDT or double transfer, a pectoral major release can be considered when the latter is considered to be a contributing source of an adduction contracture. Though, Kirkos et al. (21) showed an improvement of abduction and external rotation, ten years after a double transfer combined with pectoral and subscapularis muscle release. These results are similar to the results in the LDT + SSR group in this study, indicating that pectoralis muscle release might not be necessary.

In the present study, subscapularis muscle release showed better function compared to subscapularis muscle lengthening in active abduction score, hand-to-neck score, hand-to-back score and total Mallet score. However, subscapularis muscle lengthening showed slightly better results in hand-to-mouth function. Unfortunately, these results could not be tested on significance, since the patient groups were too small. Both patient groups showed a decrease in internal rotation (hand-to-back score). This was expected, since the major function of subscapularis muscle is internal rotation and this function might get impaired by surgery regardless whether the procedure is lengthening at the insertion or release at the origin at the scapula. The question remains whether a subscapularis muscle release should be done instead of subscapularis muscle lengthening, since the subscapularis muscle release group had a better total Mallet score.

During the follow-up period, we noticed a small decrease in shoulder function in all patient groups compared to the results 6-months after surgery (Figure 1). This finding is in line with the results reported by Kirkos et al. (13). In that study, a slight decrease in shoulder function during a 10-years follow-up was found compared to the results directly after the operation. The reason for this decrease still remains unclear. It is hypothesized that this gradual worsening of rotational movement of the shoulder could be due to shrinking of surrounding glenohumeral soft tissues and/or deformity and degenerative changes

affecting the humeral head (21). This theory is strengthened by a MRI study conducted by Kozin et al. (11) which showed that latissimus dorsi and teres major transfers, with or without concomitant musculotendinous lengthening, did not reduce humeral head subluxation or improve glenohumeral joint realignment at 3-years follow-up (11). Another cause of decreased shoulder abduction after surgery could be the weight gain of the arm during the child's growth, in combination with less muscle power to facilitate arm movements due to BPBI. It is also theorized that the transferred tendon could adapt to stretching with elongation of the muscle-tendon unit, resulting in a decreased tenodesis effect (10-12). Though, in the meta-analysis by Namdari et al. a strength improvement in abduction of 1.2 kg following a LDT in irreparable rotator cuff tears after 34 to 53 months follow-up was found (22). However, the basic pathology was different.

Since there are few long-term follow-up studies in BPBI, the cause of this slight decrease after LDT in shoulder function remains unclear.

To our best knowledge, the present study is the first long-term follow-up which assess functional outcome after a single latissimus dorsi transfer combined with or without subscapularis muscle lengthening or release. Some comments need to be made on interpretation of the results. First, even though our study is among the largest cohorts of patients that underwent LDT, a significant difference between the 3 study groups cannot be concluded due to the small numbers in the different groups. The reason for this, is the small incidence of patients with BPBI who are in need of tendon transfer surgery. Second, this study is a retrospective cohort study, which increases the risk of selection bias and loss to follow bias. Third, no randomisation was done as an intention to treat principle was used. More prospective randomized research is needed to investigate long-term functional outcome in different tendon transfer techniques in children with brachial plexus birth injury.

This study shows that patients (<12 years old) with a brachial plexus birth injury who underwent a latissimus dorsi tendon transfer, with a SSL or SSR in case of an intra-operative internal contracture, improve in abduction, external rotation and overall

shoulder function at a median follow-up of 9.8 years.

REFERENCES

1. **Edwards TB, Baghian S, Faust DC, Willis RB.** Results of latissimus dorsi and teres major transfer to the rotator cuff in the treatment of Erb's palsy. *Journal of pediatric orthopedics.* 2000 ; 20(3) : 375-9.
2. **Suenaga N, Minami A, Kaneda K.** Long-term results of multiple muscle transfer to reconstruct shoulder function in patients with birth palsy : eleven-year follow-up. *Journal of pediatric orthopedics.* 1999 ; 19(5) : 669-71.
3. **Murabit A, Gnarra M, O'Grady K, Morhart M, Olson JL.** Functional outcome after the Hoffer procedure. *Plastic and reconstructive surgery.* 2013 ; 131(6) : 1300-6.
4. **Evans-Jones G, Kay SP, Weindling AM, Cranny G, Ward A, Bradshaw A, et al.** Congenital brachial palsy : incidence, causes, and outcome in the United Kingdom and Republic of Ireland. *Archives of disease in childhood Fetal and neonatal edition.* 2003 ; 88(3) : F185-9.
5. **Chauhan SP, Rose CH, Gherman RB, Magann EF, Holland MW, Morrison JC.** Brachial plexus injury : a 23-year experience from a tertiary center. *American journal of obstetrics and gynecology.* 2005 ; 192(6) : 1795-800 ; discussion 800-2.
6. **Hoeksma AF, Wolf H, Oei SL.** Obstetrical brachial plexus injuries : incidence, natural course and shoulder contracture. *Clinical rehabilitation.* 2000 ; 14(5) : 523-6.
7. **Pondaag W, Malessy MJ, van Dijk JG, Thomeer RT.** Natural history of obstetric brachial plexus palsy : a systematic review. *Developmental medicine and child neurology.* 2004 ; 46(2) : 138-44.
8. **van der Holst M, Vlieland TP, Meesters JJ, Bekkering WP, Nagels J, Nelissen RG.** Evaluation of shoulder function after secondary surgery in children with Neonatal Brachial Plexus Palsy. *Journal of pediatric rehabilitation medicine.* 2015 ; 8(3) : 187-96.
9. **Abzug JM, Kozin SH.** Evaluation and management of brachial plexus birth palsy. *The Orthopedic clinics of North America.* 2014 ; 45(2) : 225-32.
10. **Gerber C, Rahm SA, Catanzaro S, Farshad M, Moor BK.** Latissimus dorsi tendon transfer for treatment of irreparable posterosuperior rotator cuff tears : long-term results at a minimum follow-up of ten years. *J. Bone Joint Surg. Am.* 2013 ; 95(21) : 1920-6.
11. **Kozin SH, Chafetz RS, Shaffer A, Soldado F, Filipone L.** Magnetic resonance imaging and clinical findings before and after tendon transfers about the shoulder in children with residual brachial plexus birth palsy : a 3-year follow-up study. *J. Pediatr. Orthop.* 2010 ; 30(2) : 154-60.
12. **Ersen A, Ozben H, Demirhan M, Atalar AC, Kapicioglu M.** Time-dependent changes after latissimus dorsi transfer : tenodesis or tendon transfer? *Clin. Orthop. Relat. Res.* 2014 ; 472(12) : 3880-8.

13. **James MA.** Use of the Medical Research Council muscle strength grading system in the upper extremity. *J. Hand Surg. Am.* 2007 ; 32(2) : 154-6.
14. **Haerle M, Gilbert A.** Management of complete obstetric brachial plexus lesions. *J. Pediatr. Orthop.* 2004 ; 24(2) : 194-200.
15. **Aydin A, Ozkan T, Onel D.** Does preoperative abduction value affect functional outcome of combined muscle transfer and release procedures in obstetrical palsy patients with shoulder involvement? *BMC Musculoskelet Disord.* 2004 ; 5 : 25.
16. **Waters PM, Peljovich AE.** Shoulder reconstruction in patients with chronic brachial plexus birth palsy. A case control study. *Clin. Orthop. Relat. Res.* 1999(364) : 144-52.
17. **Waters PM.** Update on management of pediatric brachial plexus palsy. *J. Pediatr. Orthop. B.* 2005 ; 14(4) : 233-44.
18. **Bahm J.** The Surgical Strategy to Correct the Rotational Imbalance of the Glenohumeral Joint after Brachial Plexus Birth Injury. *J. Brachial Plex Peripher Nerve Inj.* 2016 ; 11(1) : e10-e7.
19. **Julka A, Vander Have KL.** Shoulder sequelae of neonatal brachial plexus injuries : orthopedic assessment and management. *J. Pediatr. Rehabil. Med.* 2011 ; 4(2) : 131-40.
20. **Greenhill DA, Smith WR, Ramsey FV, Kozin SH, Zlotolow DA.** Double Versus Single Tendon Transfers to Improve Shoulder Function in Brachial Plexus Birth Palsy. *J. Pediatr. Orthop.* 2017.
21. **Kirkos JM, Kyrkos MJ, Kapetanios GA, Haritidis JH.** Brachial plexus palsy secondary to birth injuries. *J. Bone Joint Surg. Br.* 2005 ; 87(2) : 231-5.
22. **Namdari S, Voleti P, Baldwin K, Glaser D, Huffman GR.** Latissimus dorsi tendon transfer for irreparable rotator cuff tears : a systematic review. *J. Bone Joint Surg. Am.* 2012 ; 94(10) : 891-8.