



Reintervention rates following hallux valgus correction with the original and a modified Kramer osteotomy

Christoph KNOTH, Jo Ellen WELTER, Ralph ZETTL, Florian HESS

From the Department of Orthopedics and Traumatology, Cantonal Hospital Frauenfeld, Frauenfeld, Switzerland

Numerous surgical techniques to correct hallux valgus deformities are performed worldwide, some of which were developed to address problems associated with existing techniques.

This retrospective study investigated patient's outcomes and reintervention rates following the original Kramer osteotomy (KO) and a modified version of the KO (MKO). Results of radiological and clinical were gathered from medical records and long-term follow-up visits.

Angular measurements significantly improved and only three minor postoperative complications occurred after both procedures. No significant loss of correction was detected at long-term follow-up. The reintervention rate in the MKO group was 53% and the malalignment rate in the KO group was 18%.

Despite promising angular results, both techniques had important weaknesses. MKO had a high reintervention rate, which was even more clinically problematic than malalignment after KO. Given the vast array of surgical techniques to treat this condition, we conclude that better performing options should be considered.

Keywords : Hallux valgus ; Kramer osteotomy ; Forefoot surgery ; First metatarsal osteotomy

INTRODUCTION

Numerous surgical techniques to treat hallux valgus deformity have been described in the medical literature. Some techniques were designed to prevent the most prevalent complications associated

with existing techniques (1, 2, 11, 14). Comparisons of these techniques, particularly with regard to the effectiveness of addressing these targeted complications, are lacking.

The Kramer osteotomy is one common treatment for hallux valgus that has been in use for over 30 years (18, 19). Some attempts to modify this technique (10, 23) were aimed at addressing problems related to the K-wire fixation (e.g., wound healing problems, malalignment of the first metatarsal head and dislocation of the fixation) (4, 9, 10, 17). At our institution, we modified the technique by stabilizing the first metatarsal head with an angular stable implant (LINK® internal hallux fixator, Waldemar LINK GmbH & Co. KG, Hamburg, Germany) (17). In addition to increased stabilization, we wanted to avoid temporary arthrodesis and stiffness of first metatarso-phalangeal joint stemming from Kirschner wire transfixation (12).

-
- Christoph Knoth
 - JoEllen Welter
 - Ralph Zettl
 - Florian Hess

Department of Orthopedics and Traumatology, Cantonal Hospital Frauenfeld, Frauenfeld, Switzerland

Correspondence : Christoph Knoth, Department of Orthopedics and Traumatology, Cantonal Hospital Frauenfeld, Frauenfeld, Switzerland.

E-mail: christoph.knoth@orh.ch

©2020, Acta Orthopaedica Belgica.

No benefits or funds were received in support of this study. The authors report no conflict of interests. No funding was utilized for the purposes of this study.

Although an earlier study of our modified technique indicated favourable short- and long-term outcomes in terms of angular measurements, the technique was associated with a high implant removal rate (17). The objective of this retrospective study was to expand our investigative scope by comparing outcomes (i.e., changes in angular measurements, and complications and reintervention rates) after the original Kramer osteotomy (KO) with a Kirschner wire and a modified version of this technique (MKO) using a Link® internal hallux fixer. We hypothesized that outcomes would be better after undergoing the modified technique since it was designed to prevent the difficulties associated with the original technique.

MATERIAL AND METHODS

This retrospective study used data collected pre-operatively, and at short- and long-term assessments. Data were extracted from medical records of patients who underwent treatment for hallux valgus deformity at our institution from 2004 to 2012. Patients who were available for

long-term postoperative assessments had additional radiological and clinical exams. The two surgical techniques used during this time were the Kramer osteotomy and a modified Kramer osteotomy. All patients provided written informed consent for participation, and the local ethics commission approved this study (01.53.01(2013/2006/KAP)012).

Of the 114 feet surgically treated, 72 had a MKO and 42 had a KO. We intended to make the groups homogeneous by excluding cases when a lateral release or more than two additional procedures were simultaneously performed (Figure 1). Consequently, 89 cases (49 MKO and 40 KO) were included in the analysis.

The same surgeon performed all the operations with the patients under general or spinal anaesthesia. A detailed description of our modified technique has been provided in an earlier publication (Figure 2A-C) (17). An important distinction between the two approaches was that a 2 mm K-wire was inserted percutaneously into the first digit and advanced into the proximal first metatarsal bone (Figure 2D)

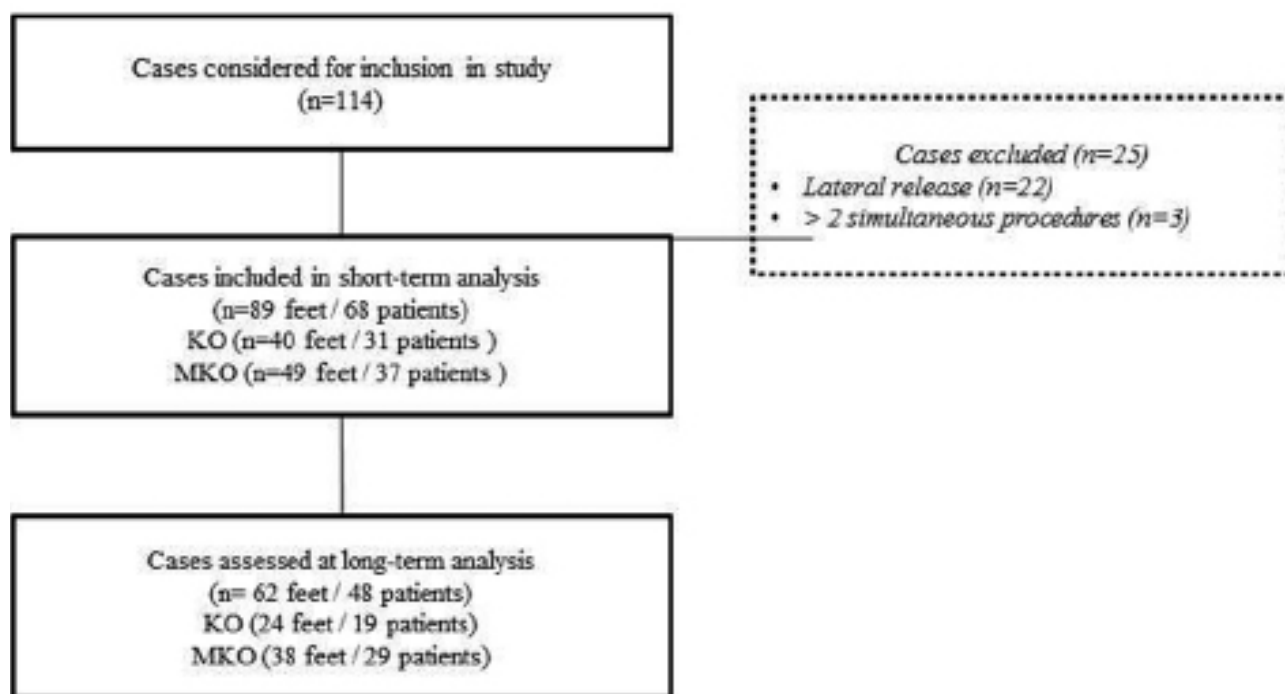


Fig. 1. Flow diagram of study inclusion and assessments

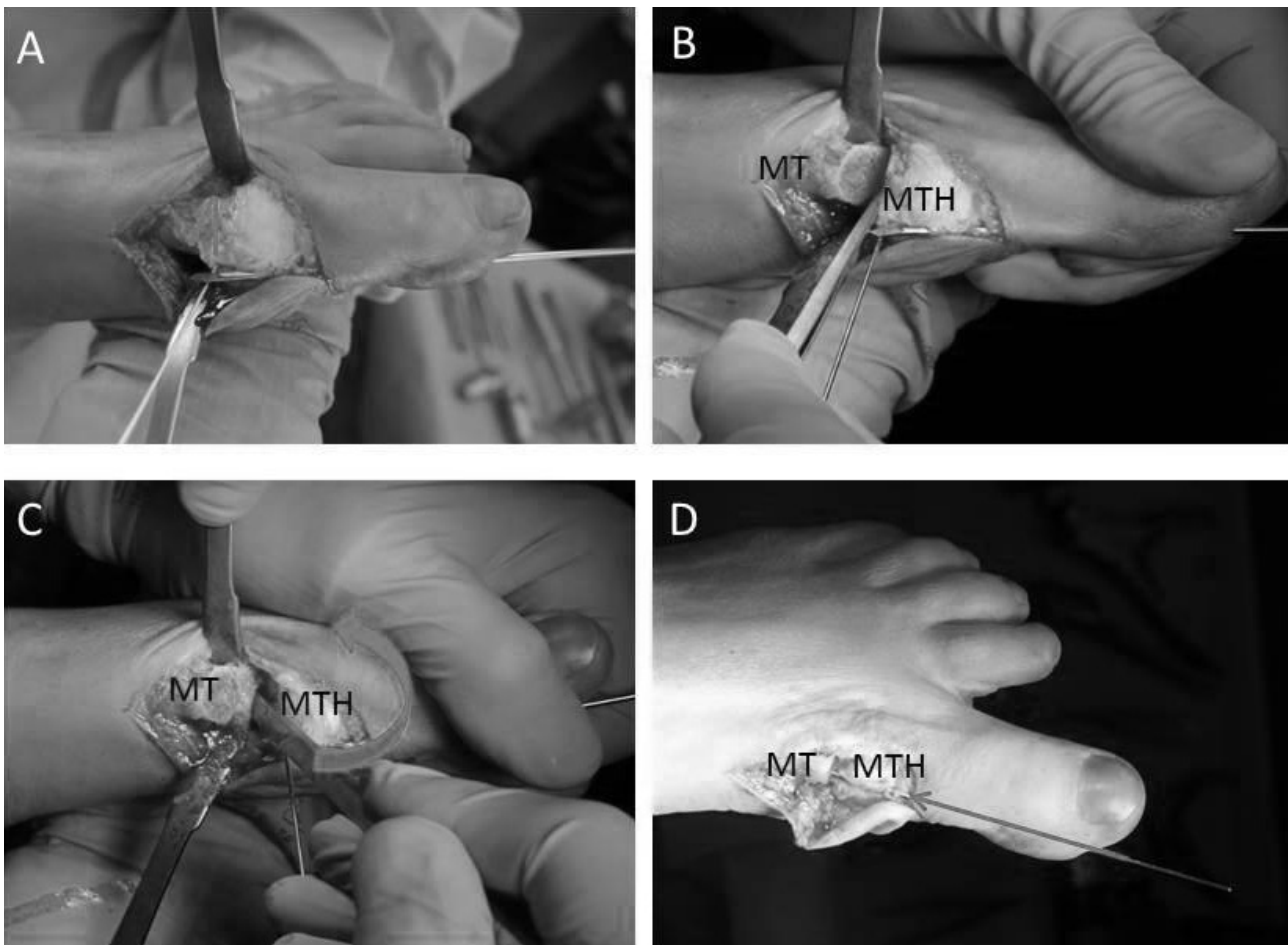


Fig. 2. — A : Subcapital wedge osteotomy ; B-C : Percutaneous insertion of the K-wire and lateralization of the head with a chisel ; D : Insertion of the K-wire into the first metatarsal shaft

during the original KO. For the modified Kramer osteotomy, stabilization of the metatarsal head was done with an angular implant (internal hallux fixator, Waldemar LINK GmbH & Co. KG, Hamburg, Germany) (Figure 3 A/B).

Postoperative care was similar for both procedures and patients were given analgesic medication in accordance with the WHO scheme (25). For the first six weeks, full weight-bearing while using a forefoot relief shoe was allowed. The initial follow-up visit was 2.5 weeks after surgery, and clinical and radiological exams were conducted at six and twelve-week follow-up visits. For patients who underwent the KO, the K-wire was removed after six weeks.

Radiological and clinical assessments were used to measure patient progress and compare

outcomes between the groups. Short-term radiological measurements were done three months post-operatively, and long-term results were determined using both radiological and clinical assessments. These were performed at a median of five years (range 3-12). Included in the analyses were age at time of operation; gender; bilateral operation; additional procedures carried out simultaneously; measurements of hallux valgus angle (HVA), the intermetatarsal angle (IMA), and the distal metatarsal articular angle (DMAA); postoperative complications (e.g. wound healing, malalignment of first metatarsal head, metatarso-phalangeal joint restriction); and the Foot Function Index (FFI) (5) and American Orthopaedic Foot and Ankle Society (AOFAS) forefoot scores (16, 24).

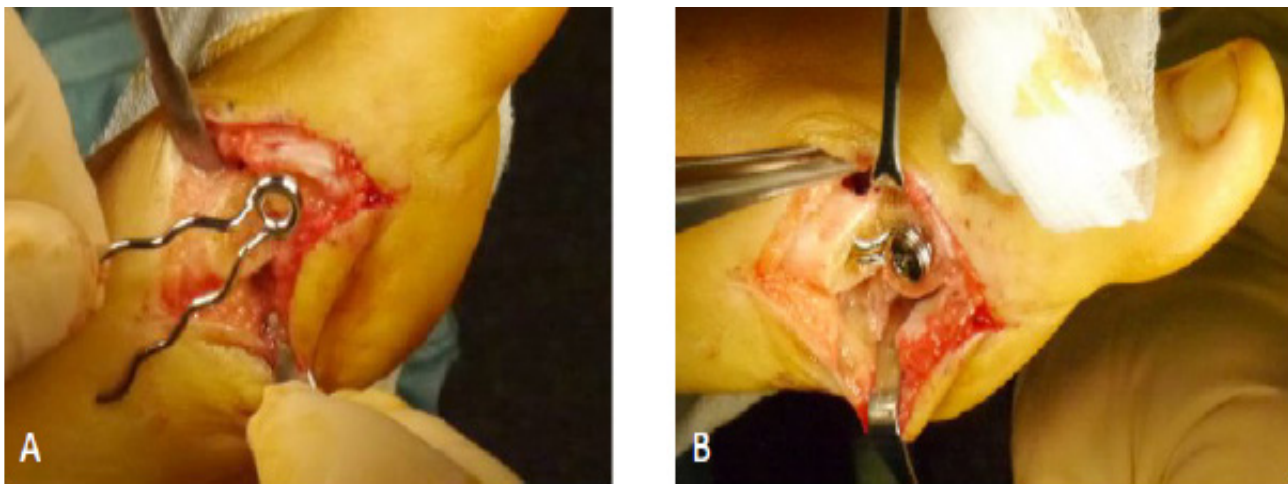


Fig. 3. — A: The internal fixator; B: The fixator in place to stabilize the osteotomy

Standing dorso-plantar and lateral x-rays were performed preoperatively and repeated at the six and twelve-week follow-up visit (Figure 4). Only dorso-plantar x-rays were done for long-term assessments. The angular measurement method developed by Coughlin was used to measure the HVA, IMA between first and second intermetatarsal shaft axis, and the DMAA (7). HVA was grouped into the following categories: mild = ≤ 25 degrees, moderate = 26-40 degrees, and severe = 41-50 degrees, and IMA categories were: mild = < 13 degrees, moderate = 13-15 degrees, and severe = 16-20 degrees.

The FFI and the AOFAS assessment tools were used at long-term follow-up visits only. To measure the first metatarso-phalangeal joint motion (dorsiflexion plus plantarflexion), we used the AOFAS score with the following restriction categories: mild (≥ 75 degrees), moderate (30-74 degrees) and severe (< 30 degrees). We identified cases of malalignment as plantar or dorsal deviation of the metatarsal shaft axis in lateral standing x-rays, and reintervention was defined as surgical revision, reoperation or implant removal.

All analyses were done using IBM® SPSS® Version 21.0 (Armonk, NY). Descriptive statistics were used to present demographic data and distribution of the clinical scores and results of the radiological assessments. The Fisher's exact or chi square tests were used to compare

categorical variables. We used inferential statistics to measure intragroup changes over time (paired t-test or Wilcoxon signed rank test) and intergroup comparisons (t-test and Mann Whitney U tests), with an alpha level set at < 0.05 for two-sided testing. However, given the multiple intragroup comparisons at various time points, the Bonferroni correction was used to establish an adjusted significance level of < 0.025 . We used the statistical program G*Power 3.1.9.2 (University of Kiel, Germany) for post hoc calculation of power given an alpha level of 0.05, group sample sizes (49 vs. 40), and effect size (using reintervention rates 53% vs. 5%). Proportions based on inequality of two independent groups according to Fisher's exact test resulted in a power of 0.99.

RESULTS

Although most demographic and baseline clinical characteristics were comparable between the two surgical technique groups (Table 1), statistical testing revealed that two key variables were inherently different - the median age ($p=0.005$) and the distribution of pre-operative HVA angle categories ($p=0.04$). The preference of the surgeon led to a selection bias that was difficult to overcome, in spite of our efforts to narrow study inclusion parameters. As a result, our original investigation to compare the techniques and make inferences based on statistically tests was not feasible and,

REINTERVENTION RATES FOLLOWING HALLUX VALGUS CORRECTION

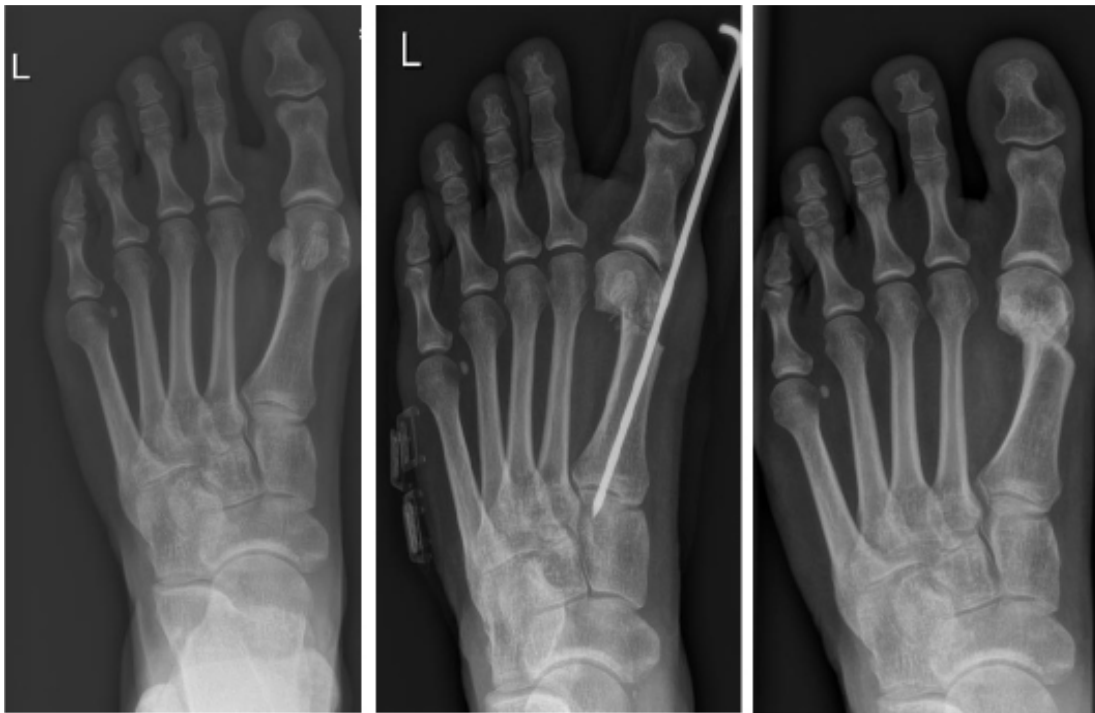

Fig. 4. — Full weight-bearing dorso-plantar x-rays taken preoperatively, and 6-week and long-term follow-up examinations

Table I. — Patient characteristics according to operative technique

Baseline characteristic	Modified Kramer Osteotomy	Original Kramer Osteotomy	p-value
Age at operation (years)	53 (41-57) ^a range 22-78	42 (26-53) ^a range 16-67	0.005 ^d
Number of males	3	2	0.58 ^c
Number of patients with bilateral operation	9	7	0.53 ^b
Number of patients with subsequent operation on contralateral foot	3	1	0.40 ^c
Number of feet undergoing another procedure during primary operation	13	12	0.48 ^b
Hallux valgus angle (HVA)			
Mild (≤ 25 degrees)	28	13	0.04 ^b
Moderate (26-40 degrees)	20	24	0.09 ^b
Severe (41-50 degrees)	1	3	0.32 ^c
Intermetatarsal angle (IMA)			
Mild (<13 degrees)	28	23	0.99 ^b
Moderate (13-15 degrees)	14	12	0.99 ^b
Severe (16-20 degrees)	7	5	0.99 ^c

^aMedian (interquartile range); ^bChi square test; ^cFisher's exact test; ^dMann Whitney U test

consequently, limited to descriptive analyses. However, we present intra-group results using statistical testing.

A total of 37 patients (49 feet) underwent the MKO and 32 (40 feet) had the original KO. Twenty-five feet had between one and two additional procedures carried out simultaneously on the same foot (27% MKO, 30% KO) : hammer-toe and claw-toe corrections, metatarsal II-IV base osteotomy, retrocapital MT-V osteotomy, and subcapital MT-V osteotomy.

Both surgical groups showed significant improvements according to the HVA, DMAA and IMA three-month postoperative assessments (Table 2). Seventy percent of the cases (62/89) were available for long-term assessments at a median of 5 years (IQR 4-7, range 3-8) for MKO and 6 years (IQR 3-6, range 3-12) for the KO. The number of patients assessed at long-term follow-up visits was 29 (38 feet) in MKO group and 19 (24 feet) in the KO group. The reasons for lack of participation in follow-up visits were missing/outdated patient contact information (11), refusal (7) or death (3).

Results from the 62 feet assessed at the long-term visit indicated the FFI median score was less favourable in the KO group (12, IQR 10-16) than the MKO group (2, IQR 0-4). The median AOFAS scores were 92 (IQR 80-95) for MKO and 85 (IQR 78-95). There was no significant loss of correction in either group since the three-month postoperative measurements (HVA, DMAA, IMA) (Table 2). With regard to metatarso-phalangeal joint restrictions, the finding per category for the MKO group and the KO group, respectively, were as follows : 58% and 46% mild, 37% and 54% moderate, and 5% and 0 severe.

Table 3 presents short- and long-term complications / corrective action. In the MKO group, two patients with pseudoarthrosis needed revision and plate fixation (8 and 16 months, respectively). In addition, one patient with recurrent hallux valgus subsequently underwent the same procedure three years later. Complications in the KO group included one wound infection around the K-wire that was treated with topical antiseptics, one hallux varus that needed a tendon transfer, and one reoperation due to a prominent medial metatarsal shaft. The

Table II. — Short- (n=89) and long-term (n=62) radiological outcomes according to surgical technique

Measurement	Modified Kramer Osteotomy	Original Kramer Osteotomy
HVA Preoperative ^a	25.5 (±5.9)	27.9(±7)
HVA 3 Months ^a	13.9(±6.1)	12.2(±8)
p-value (intra-group preop./3 months) ^c	0.001	0.001
HVA Long-term Follow Up (LTFU) ^a	13.8 (±6)	12.7 (±10.2)
p-value (intra-group 3 months/LTFU) ^c	0.66	0.70
DMAA Preoperative ^b	19 (15-26)	20 (15.5-25.5)
DMAA 3 Months ^b	8 (5.5-12)	6(1-10.5)
p-value (intra-group preop./3 months) ^d	0.001	0.001
DMAA Long-term Follow Up ^b	9 (7-12)	3 (1-14)
p-value (intra-group 3 months/LTFU) ^d	0.93	0.65
IMA Preoperative ^b	12 (10.5-14.5)	12 (11-14)
IMA 3 Months ^b	5 (4-7.5)	7 (4-9)
p-value (intra-group preop./3 months) ^d	0.001	0.001
IMA Long-term Follow Up ^b	6 (5-8)	7 (5-8)
p-value (intra-group 3 months/LTFU) ^d	0.89	0.063

^aMean (standard deviation); ^bMedian (interquartile range); ^cPaired t-test; ^dWilcoxon signed-rank test; Bonferroni adjusted level of significance <0.025

Table III. — Postoperative complications and reinterventions according to surgical technique

Complication / Reintervention	Modified Kramer Osteotomy (n=49)	Original Kramer Osteotomy (n=40)
Wound healing problems	-	1 (3%)
Surgical revision/reoperation/implant removal	26 (53%)	2 (5%)
Severe stiffness of first MTPJ	1 (2%)	-
Malalignment of first metatarsal head	-	7 (18%)

only cases of malalignment (plantar, dorsal) were detected in the KO group and did not require further treatment. Unplanned implant removal was done in 23 of the cases in the MKO group. No cases of transfer metatarsalgia needing operative treatment occurred in either group. Reinterventions occurred at a median of 13 months postoperatively (IQR 6-20; range 3-63).

DISCUSSION

Most patients who underwent the original or the modified Kramer osteotomy experienced significant improvements in angular measurements that were sustained over time. The most notable differences were malalignment of first metatarsal head in the original KO group (18%) and reinterventions in the MKO group (53%).

Recently published reports describe minimally invasive techniques (based on the original Kramer technique) with similar results to other techniques with low complication rates (3, 6, 10, 20). Contrary to these findings, Poggio et al. found higher care burdens, complication rates and costs within the first postoperative year after the original KO when compared to the Scarf osteotomy (22). In addition, postoperative x-rays indicated a high rate of first metatarsal malalignment and dislocation of the first metatarsal head when using K-wire stabilization. Kadakia et al. reported dorsal angulated alignment of the first metatarsal in 69% of the cases (mean 0.8 degrees (6-15) at first follow-up, 15.9 degrees (10-22) at final follow-up). Thirty-eight percent of the patients had recurrent hallux valgus and one patient developed osteonecrosis of the first metatarsal head (15).

A weakness of the KO, especially when performed as a percutaneous procedure, seems to be inadequate

fixation with the K-wire that can lead to dislocation of the first metatarsal head and additional operations (15). Although many studies fail to report on plantar or dorsal alignment of the first metatarsal head, two studies found misaligned first metatarsal heads in 55.6% and 61% of the cases, respectively (8, 20). In addition, Faour-Martin et al. reported dorsal or plantar malalignment in 33.1% of the cases and mild metatarsalgia of the lesser toes that was treated conservatively (9). Three patients needed further surgery and Weil osteotomy was performed on the affected metatarsals. Due to a high rate of hallux valgus recurrence after minimally invasive distal osteotomy in cases of HVA greater than 30 degrees, Huang et al. discouraged use of this procedure (13).

In this cohort, we were able to achieve good exposure during osteotomy and the metatarsal could be assessed in every plane. We observed more cases of malalignment in the KO group, with dorsal or plantar alignment in 18% of the cases. No further interventions were needed to treat metatarsalgia of the lesser toes in patients with malalignment. No cases of osteonecrosis or non-union were found in either group. The absence of dislocations in the modified group seems to support the hypothesis that fixation with a K-wire continues to be a weakness.

Our findings indicate that the modified technique was effective at avoiding temporary arthrodesis of first metatarso-phalangeal joint, a complication that other authors found with the original technique. A decreased range of motion in the first MTPJ six weeks following percutaneous Kirschner wire fixation in 31% and 13.9% (less than 30 degrees) of the patients were reported by Markowski et al. (21) and Faour-Martin et al. (9), respectively. Likewise, Mangan et al. (20) showed that 6.8% of the cases had a first MTPJ range of motion of less than 30 degrees. The majority of our patients experienced

mild restrictions, which resulted in good function and mobility.

A shortcoming of our investigation was that the selection bias during treatment allocation resulted in younger patients undergoing the original technique more often than the modified version. Although young patients were also treated with the internal fixator, the angular stable implant was the method of choice for older patients with poorer bone quality. Likewise, the distribution of HVA categories was different, which led to a higher amount of mild cases treated with the MKO. Again, the physician preference played a role in this decision with the tendency for MKO in older patients with poorer bone quality. These important differences necessitated a change in our analysis plan since intergroup comparisons using statistical testing were no longer appropriate.

Perhaps the most clinically relevant finding from this study was the high reintervention rate (53%) after MKO, that resulted in additional costs and burden for the patients. When viewed as a staged process with the potential for implant removal, which was largely our attitude in our previous publication, this technique was effective at addressing the problems associated with the K-wire. Nevertheless, we conclude that this high reintervention rate is clinically more problematic than the challenges of stability with the K-wire. Given the issues associated with both techniques, we encourage practitioners to search for other reliable and well-performing techniques currently available to treat hallux valgus deformities.

RESEARCH ETHICS AND PATIENT CONSENT

All procedures performed in studies involving human participants were in accordance with the ethical standards of the institutional and/or national research committee and with the 1964 Helsinki declaration and its later amendments or comparable ethical standards. Informed consent was obtained from all individual participants included in the study.

REFERENCES

1. **Barouk LS.** Scarf osteotomy for hallux valgus correction. Local anatomy, surgical technique, and combination with other forefoot procedures. *Foot Ankle Clin* 2000 ; 5 : 525-58.
2. **Beckingham AC.** Identifying problems for nursing research. *Int Nurs Rev* 1974 ; 21 : 49-52.
3. **Bonnel F, Canovas F, Poiree G, et al.** [Evaluation of the Scarf osteotomy in hallux valgus related to distal metatarsal articular angle : a prospective study of 79 operated cases]. *Rev Chir Orthop Reparatrice Appar Mot* 1999 ; 85 : 381-6.
4. **Bosch P, Wanke S, Legenstein R.** Hallux valgus correction by the method of Bosch : a new technique with a seven-to-ten-year follow-up. *Foot Ankle Clin* 2000 ; 5 : 485-98, v-vi.
5. **Budiman-Mak E, Conrad KJ, Roach KE.** The Foot Function Index : a measure of foot pain and disability. *J Clin Epidemiol* 1991 ; 44 : 561-70.
6. **Chou LB, Mann RA, Casillas MM.** Biplanar chevron osteotomy. *Foot Ankle Int* 1998 ; 19 : 579-84.
7. **Coughlin MJ, Saltzman CL, Nunley JA, 2nd.** Angular measurements in the evaluation of hallux valgus deformities : a report of the ad hoc committee of the American Orthopaedic Foot & Ankle Society on angular measurements. *Foot Ankle Int* 2002 ; 23 : 68-74.
8. **Enan A, Abo-Hegy M, Seif H.** Early results of distal metatarsal osteotomy through minimally invasive approach for mild-to-moderate hallux valgus. *Acta Orthop Belg* 2010 ; 76 : 526-35.
9. **Faour-Martin O, Martin-Ferrero MA, Valverde Garcia JA, et al.** Long-term results of the retrocapital metatarsal percutaneous osteotomy for hallux valgus. *Int Orthop* 2013 ; 37 : 1799-803.
10. **Gadek A, Liszka H.** Mini-invasive mitchell-kramer method in the operative treatment of hallux valgus deformity. *Foot Ankle Int* 2013 ; 34 : 865-9.
11. **Ganel A, Chechick A, Farine I.** Chevron osteotomy. *Clin Orthop Relat Res* 1981 : 300.
12. **Giannini S, Cavallo M, Faldini C, et al.** The SERI distal metatarsal osteotomy and Scarf osteotomy provide similar correction of hallux valgus. *Clin Orthop Relat Res* 2013 ; 471 : 2305-11.
13. **Huang PJ, Lin YC, Fu YC, et al.** Radiographic evaluation of minimally invasive distal metatarsal osteotomy for hallux valgus. *Foot Ankle Int* 2011 ; 32 : S503-7.
14. **Johnson KA, Cofield RH, Morrey BF.** Chevron osteotomy for hallux valgus. *Clin Orthop Relat Res* 1979 : 44-7.
15. **Kadokia AR, Smerek JP, Myerson MS.** Radiographic results after percutaneous distal metatarsal osteotomy for correction of hallux valgus deformity. *Foot Ankle Int* 2007 ; 28 : 355-60.
16. **Kitaoka HB, Alexander IJ, Adelaar RS, et al.** Clinical rating systems for the ankle-hindfoot, midfoot, hallux, and lesser toes. *Foot Ankle Int* 1994 ; 15 : 349-53.

17. **Knöth C, Carow L, Zettl R, et al.** Short- and long-term outcomes following hallux-valgus correction : a modified Kramer osteotomy. *Arch Orthop Trauma Surg* 2016 ; 136 : 1349-55.
18. **Kramer J.** Die Kramer-Osteotomie zur Behandlung des Hallux valgus und des Digitus quintus varus. *Operat Orthop Traumatol* 2 (1990) 1990 ; 1 : 29-38
19. **Lamprecht E KJ.** Die Metatarsale-I-Osteotomie nach Kramer zur Behandlung des Hallux valgus. *Orthop Praxis* 1982 : 635-45.
20. **Magnan B, Pezze L, Rossi N, Bartolozzi P.** Percutaneous distal metatarsal osteotomy for correction of hallux valgus. *J Bone Joint Surg Am* 2005 ; 87 : 1191-9.
21. **Markowski HP BP, Rannicher V.** Surgical technique and preliminary results of percutaneous neck osteotomy of the first metatarsal for hallux valgus. *Foot* 1992 ; 2 : 93-8.
22. **Poggio D, Melo R, Botello J, et al.** Comparison of postoperative costs of two surgical techniques for hallux valgus (Kramer vs. scarf). *Foot Ankle Surg* 2015 ; 21 : 37-41.
23. **Redfern D, Vernois J, Legre BP.** Percutaneous Surgery of the Forefoot. *Clin Podiatr Med Surg* 2015 ; 32 : 291-332.
24. **Riskowski JL, Hagedorn TJ, Hannan MT.** Measures of foot function, foot health, and foot pain : American Academy of Orthopedic Surgeons Lower Limb Outcomes Assessment : Foot and Ankle Module (AAOS-FAM), Bristol Foot Score (BFS), Revised Foot Function Index (FFI-R), Foot Health Status Questionnaire (FHSQ), Manchester Foot Pain and Disability Index (MFPDI), Podiatric Health Questionnaire (PHQ), and Rowan Foot Pain Assessment (ROFPAQ). *Arthritis Care Res (Hoboken)* 2011 ; 63 : S229-39.
25. **WHO.** World Health Organization. Cancer Pain Relief. Geneva : *World Health Organization*, 1986.