



A prospective randomized study comparing the direct anterior approach in the lateral decubitus position versus the standard posterolateral approach for total hip arthroplasty

Hao-ran YU, Zi-yu LI, Jue-hua JING, Jian TANG, Qi-liang CAO, Wen-dan CHENG

From the Second Affiliated Hospital of Anhui Medical University, Hefei, China

There have been a large number of studies comparing the direct anterior approach (DAA) in the supine position with the standard posterolateral approach (PLA) for total hip arthroplasty (THA). However, there have been few studies on DAA in the lateral decubitus position (LDAA). Therefore, this prospective randomized study was conducted to compare the early clinical, laboratory and radiological outcomes between patients who underwent the LDAA or the PLA for THA.

Seventy-two patients were randomly divided into two groups. The patients in one group accepted THA via the LDAA, and the patients in the other group accepted THA via the PLA. All operations were performed by an experienced orthopedic surgeon, who is skilled in both approaches. All preoperative and postoperative data were collected by other well-trained researchers. The data collected included length of incision, operation time, intraoperative blood loss, post-operation drainage, length of stay, orientation of acetabular component, position of femoral prosthesis, complication rates, perioperative transfusion rates, serum creatine kinase (CK), serum C-reactive protein (CRP), serum myoglobin (MYO), postoperative hemoglobin (HGB), visual analogue scores (VAS), and Harris hip scores (HHS).

Compared with the PLA, the LDAA offered the benefits of shorter incision ($P < 0.001$), less intraoperative blood loss ($P < 0.001$), less postoperative drainage ($P < 0.001$), and shorter length of stay ($P < 0.001$). In addition, the LDAA caused lower levels of CK, CRP, and MYO and higher levels of postoperative

HGB. The LDAA group received a lower score ($P < 0.001$) in the VAS and a higher score ($P < 0.001$) in the HHS. However, the LDAA required a longer operation time than the PLA ($P < 0.001$). No significant differences were found in complication rates, perioperative transfusion rates, orientation of the acetabular component, or the position of femoral prosthesis between the two groups.

Compared with the PLA, our results showed that for THA, the LDAA is more minimally invasive, and the patients in the LDAA group achieved a faster functional recovery with less muscle damage and better pain relief.

Keywords: direct anterior approach ; lateral decubitus position ; posterolateral approach ; total hip arthroplasty.

-
- Hao-ran Yu*
 - Zi-yu Li*
 - Jue-hua Jing.
 - Jian Tang.
 - Qi-liang Cao.
 - Wen-dan Cheng.

*Hao-ran Yu and Zi-yu Li contributed equally to this study.
Department of Orthopaedic Surgery, The Second Affiliated Hospital of Anhui Medical University, Hefei, China.

Correspondence: Wen-dan Cheng, Department of Orthopaedic Surgery, The Second Affiliated Hospital of Anhui Medical University, Hefei, China. Tell: 17305604490

E-mail : sunyccc@126.com

©2020, Acta Orthopaedica Belgica.

Conflict of interest: All authors declare that they have not received any funding or other benefits in support of this study. No relevant financial relationships to disclose.

INTRODUCTION

Total hip arthroplasty (THA) is an effective therapeutic method for end-stage disease of the hip. It is widely used around the world, and relieves the pain of millions of people. THA can be performed by several approaches, including the posterolateral approach (PLA) and direct anterior approach (DAA) (22). The PLA is often called the “Southern” or “Moore” approach, and is the most popular surgical approach for THA at the present time (5). The DAA was first described by Smith-Peterson in 1949 (3), and it was also known as the “Hueter” approach by Judet and O’Brien who described it in the 1950s (14,21).

The initial requirement of the patient was to relieve the pain and restore joint function through THA; however, patients gradually began to hope for a quicker recovery (10). It is well known that the postoperative recovery rate is significantly related to the injury caused by the operation, so orthopedists looked for the most minimally-invasive approach for THA. However, controversy remains over which approach is more minimally invasive. With the rise of minimally-invasive surgical techniques, the DAA has gained the interest of orthopedists again in recent years. Because no muscles are detached during the surgical procedure, the DAA is regarded as a real minimally-invasive approach to the hip. The dissection involved in the DAA occurs between the sartorius and tensor fasciae latae (TFL), and therefore causes less tissue damage to reach the hip joint compared with the traditional PLA (1,3). Several studies have reported many benefits of this muscle-sparing approach, such as shorter incision length, shorter hospital stay, shorter rehabilitation times, lower visual analogue scores (VAS) and quicker return to normal function (1,19,31). The vast majority of studies (2,25,31) compared the difference between standard PLA and DAA in the supine position. In contrast, few studies have reported the results of the DAA in the lateral decubitus position (LDAA), which is currently becoming more and more popular. DAA could be done with traction on a special table or without traction on an ordinary operating table. However, the LDAA can be performed in the lateral decubitus

position on an ordinary operating table, in the same way as the PLA. We hypothesized that the difference of body position may have an effect on the preoperative and postoperative evaluation indicators, so the same position may make the DAA and PLA more comparable than previous studies. The main aim of our study was to try to demonstrate which approach is more minimally invasive by comparing the early clinical, laboratory and radiological outcomes between the LDAA and the standard PLA. In addition, the study explored which approach was more advantageous in terms of radiological outcomes.

MATERIALS AND METHODS

A randomized prospective study was designed to compare the early clinical, laboratory and radiological outcomes between the LDAA and standard PLA in patients undergoing primary THA. The study was approved by the Ethics Committee of the second affiliated hospital of Anhui Medical University, Hefei, China. All patients provided signed consent forms.

Patient Selection

Between 01-09-2016 and 31-03-2017, a total of 72 patients (Fig. 1) were included in this prospective

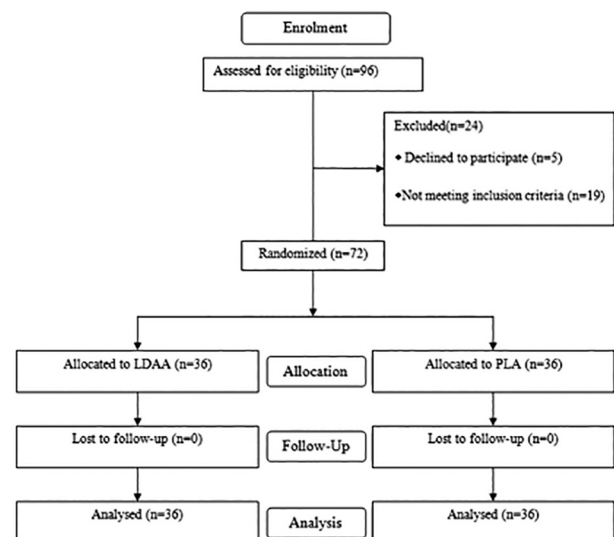


Fig. 1. — CONSORT flow chart. LDAA, direct anterior approach in the lateral decubitus position; PLA, posterolateral approach

randomized controlled study and they were followed up to 6 months postoperatively. The inclusion criteria were as follows: (1) Various types of hip disease, such as osteoarthritis of the hip, femoral head necrosis (Ficat 3 or 4 type), or hip dysplasia (Crowe 1 or 2 type); and (2) primary unilateral THA. The exclusion criteria comprised: (1) inability to tolerate surgery; (2) hip dysplasia (Crowe 3 or 4 type); (3) pathological lesions; (4) prior hip surgery; (5) patients with poor compliance; (6) severe osteoporosis; and (7) hip revision operation. All participants meeting the inclusion criteria were randomly allocated to either the LDAA or PLA group according to computer-generated random numbers. A researcher who did not take part in patient recruitment, treatment, or evaluation independently prepared the randomization sequence. Postoperative evaluation was accomplished by other independent researchers. The surgeon was blinded to the approach protocol.

The main aim of this study was to assess which approach is more minimally invasive, so the primary outcome indicator was muscle damage and a power analysis was conducted using 80% power and an alpha value of 5%. The creatine kinase (CK) has been proven to be a reliable objective serum marker to evaluate muscle damage (30). In an analysis, limited data were used to analyze the rise and change in CK levels after THA, suggesting that 58 patients were required to detect differences between the two groups. Even with a 5% potential loss to follow-up, the total needed is only 61 patients, but in order to increase the power, the study eventually included 72 patients.

LDAA (6) was performed with the patient in a lateral decubitus position on an ordinary operating table. A straight incision approximately 8 cm long is made, starting from 2 cm distal and 2 cm lateral of the anterior superior iliac spine and pointing at capitula fibula. After making an incision in the skin, the subcutaneous fat and fascia was dissected layer by layer, until the TFL muscle was seen. The Hueter interval between the sartorius and TFL muscle was exposed when the TFL muscle was split with the surgical knife handle. The ascending branch of the lateral circumflex femoral artery was then dissociated and ligated carefully.

Two blunt retractors were then placed on the top of the acetabulum and the outside of the greater trochanter of the femur to mobilize the TFL muscle laterally and an additional Hoffman hook was placed below the neck of the femur to mobilize the rectus femoris muscle medially. After the Hueter interval was sufficiently exposed, the fat covering the anterior hip capsule could be seen. When the fat and the anterior capsule had been cleared, the femoral neck, femoral head, and acetabulum were then exposed. The femoral neck was cut with an oscillating saw at 0.5 cm from the base of the femoral neck. The femoral head was then removed with a corkscrew. Three blunt retractors were placed at the two o'clock, four o'clock, and seven o'clock positions of the acetabulum in order to fully expose the acetabulum. Then the surgeon resected the limbic capsule of the acetabulum, labrum, and osteophyte with an electrotome or a rongeur. We used an acetabular file to remove acetabular cartilage until the subchondral bone was bleeding uniformly, after which the acetabular component was positioned. Next, we needed to fully release the posterior capsule above the lateral femur. Two blunt retractors were positioned at the lateral and posterior aspects of the greater trochanter of the femur, and a two-pronged hook was placed under the lesser trochanter. Meanwhile, a surgical assistant moved the surgical leg to a position of adduction, hyperextension and external rotation, and another assistant pushed the proximal femur forward to allow adequate exposure. After medullary reaming of the proximal femur was completed, the appropriate femoral prosthesis could be inserted and the hip joint restored. After this the hip joint's stability in all directions was checked. Finally, we sutured the fascia and the skin and positioned a drainage tube in place.

The PLA (18) was performed with the patient in a lateral decubitus position on an ordinary operating table. A skin incision 10 cm in length was made at the apex of the greater trochanter of the femur, with a slight curve to the posterior. After transection of the skin, subcutaneous tissue and superficial fascia, the TFL and the gluteus maximus muscle were split. The end point of the shorter external rotators on the greater trochanter of the femur could then

be exposed. After the gluteus medius was pulled with a blunt retractor, the end point of the shorter external rotators could be cut along the surface of the greater trochanter of the femur. The posterior capsule was then exposed after backward retraction of the shorter external rotators. When the capsule was cut, the femoral head and femoral neck were then visible. Further internal rotation of the leg, along with flexion, adduction, and gentle traction then allowed for hip dislocation. After cutting the femoral neck at 0.5 cm from the base, we were able to pull out the femoral head. The same installation procedure was used for the acetabular component as in the LDAA. After installation of the acetabular component, the leg was internally rotated, flexed, and adducted to deliver the proximal femur for preparation. The subsequent surgical procedure was similar to the LDAA. Finally, it was necessary to repair the posterior capsule and the shorter external rotators, which was not necessary with the LDAA.

Similar perioperative and postoperative protocols were utilized in both the LDAA and PLA groups. All patients received the same multimodal analgesia before surgery. Half an hour before surgery, all patients received prophylactic antibiotic (cefuroxime sodium), and the antibiotic dose was adjusted according to weight. All patients received low molecular weight heparin at 24 hours after surgery in order to prevent deep vein thrombosis (DVT). Moreover, all patients were given oral rivaroxaban at 10 milligrams once a day for two weeks. All patients began gentle activity at the first day after surgery. However, for the PLA group, combined hip flexion $> 90^\circ$ and internal rotation past the neutral plane were avoided, while there was no need to restrict hip movement of the LDAA group. The discharge standard required a good surgical wound, hip flexion of 90° and hip abduction of 40° .

Two well-trained researchers collected all the perioperative evaluation indicators, which included incision, operation time, intraoperative blood loss, postoperative drainage, postoperative hemoglobin (HGB) levels, postoperative damage indicator levels, postoperative inflammatory marker levels, length of stay, blood transfusion cases and the number of complications which occurred. Reported complications included infection, dislocation, lower

extremities DVT, nerve damage and prosthesis loosening. In addition, we used the Harris hip scores (HHS) system (27) for evaluation of preoperative and postoperative joint function, while pain severity was evaluated by VAS scoring (4). Anteroposterior pelvic radiographs were obtained on the 2nd postoperative day. The anteversion and abduction of the acetabular component were measured using the Pradhan method (23) (Fig. 2). First, we drew a horizontal line along the lower edge of the double tear drop. Then, we made an ellipse from the projection of the acetabular cup anteversion. The angle (α) between the long axis of the ellipse and the horizontal line is the abduction of the acetabular cup. A point M is marked one fifth of the distance (b) along the long axis (a) of the ellipse. The perpendicular line of a line through

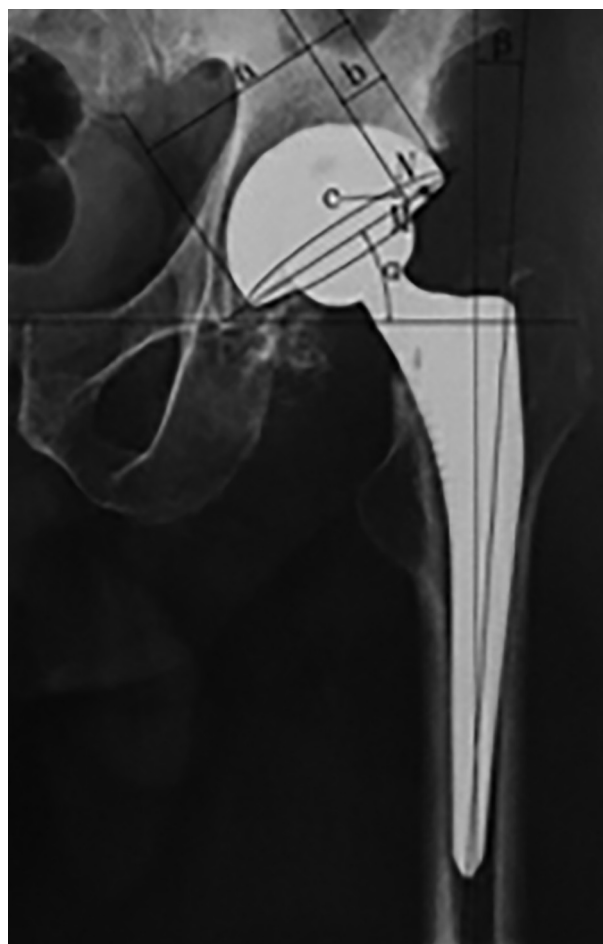


Fig. 2. — Measurement of the acetabular cup acetabular, acetabular cup abduction, and femoral prosthesis position

point M intersects with the ellipse at point N. The distance between point M and point N is marked “c”. Acetabular cup anteversion = $\sin^{-1}(c/0.4a)$. The position of the femoral prosthesis was measured using the Nakata method (19). The stem alignment of varus or valgus positioning of less than 3° was considered a neutral position. The angle (β) was measured between the long axis of the femoral prosthesis and the long axis of the femur (Fig. 2).

Statistical analyses were performed using SPSS Statistics (Version 20.0, IBM Corporation, Armonk, NY, USA). Differences were considered statistically significant when the P-value was less than 0.05 ($P < 0.05$). The demographic characteristics and results of the groups are given as mean (SD). The continuous clinical parameters and functional outcomes were analyzed by Student’s t-test. The Pearson chi-squared test was used to analyze discontinuous variables.

RESULTS

The LDAA and PLA groups were similar in demographic characteristics (Table I), including age, body mass index (BMI), gender composition and the proportion of right hips. The two groups were comparable in preoperative ASA grade (Table I), visual analogue scores (VAS) (Table I), HHS

(Table I), HGB levels (Fig. 3), C-reactive protein (CRP) level (Fig. 4), and CK levels (Fig. 5), however, there was a slightly higher average preoperative myoglobin (MYO) level for the LDAA group (Fig. 6), but these MYO levels were within the normal range.

The mean operation times were significantly different ($P < 0.001$; Table II), being 13 minutes longer in the LDAA group. There were statistically significant difference in the mean incision ($P < 0.001$; Table II), mean length of hospital stay ($P < 0.001$; Table II), mean intraoperative blood

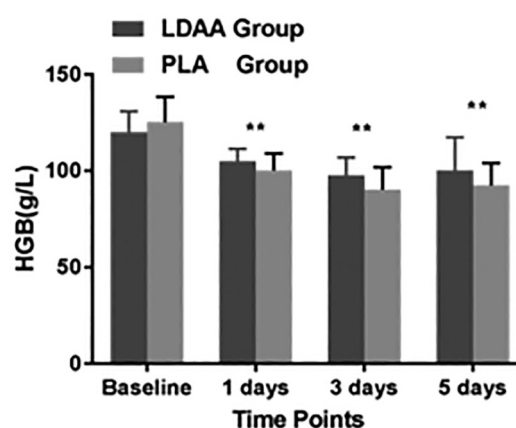


Fig. 3. — HGB levels in the two groups. HGB, hemoglobin; Baseline, preoperative outcome. ** = a significant difference between groups

Table I. – Preoperative demographic and clinical data

Demographic, Mean (SD)	LDAA Group (n = 36)	PLA Group (n = 36)	P-value
Age, y	63.42(5.83)	64.11(5.67)	0.610
Gender, male/female	16/20	17/19	0.561
Operative side, right/left	23/13	22/14	0.059
BMI, kg/m ²	23.97(2.92)	24.98(2.87)	0.143
ASA grade	1.78(0.54)	1.83(0.50)	0.654
HHS	42.75(6.96)	44.97(7.38)	0.193
VAS	5.50(0.43)	5.49(0.48)	0.959
Hip osteoarthritis	21	22	
Femoral head necrosis	13	12	
DDH, Crowe I/II	2	2	

SD, standard deviation; LDAA, direct anterior approach in the lateral decubitus position; PLA, posterolateral approach; BMI, body mass index; ASA, American Society of Anesthesiologists; HHS, Harris hip score; VAS, Visual analogue score; DDH, developmental dysplasia of the hip

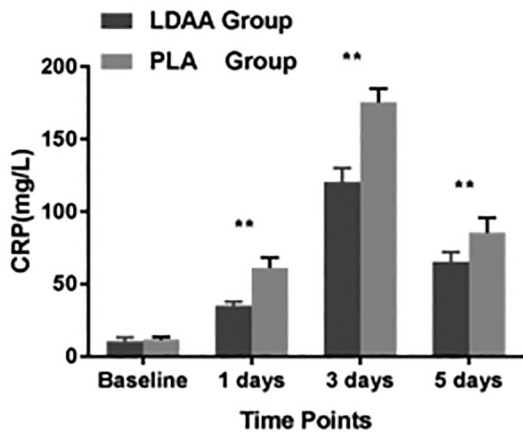


Fig. 4. — CRP levels of the two groups. CRP, C-reactive protein; Baseline, preoperative outcome. ** = a significant difference between groups

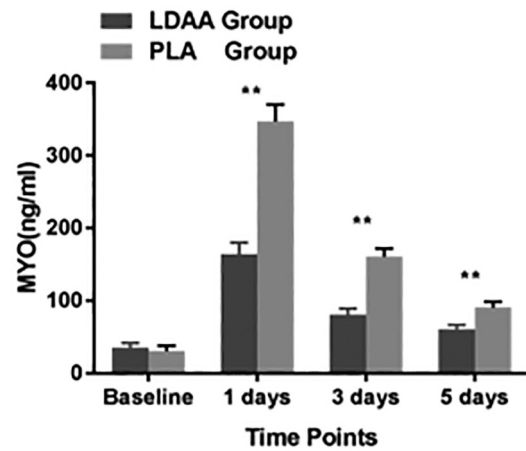


Fig. 6. — MYO levels of the two groups. MYO, myoglobin; Baseline, preoperative outcome. ** = a significant difference between groups

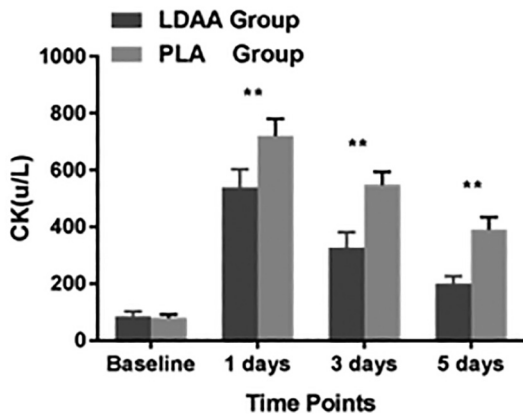


Fig. 5. — CK levels of the two groups. CK, creatine kinase; Baseline, preoperative outcome. ** = a significant difference between groups

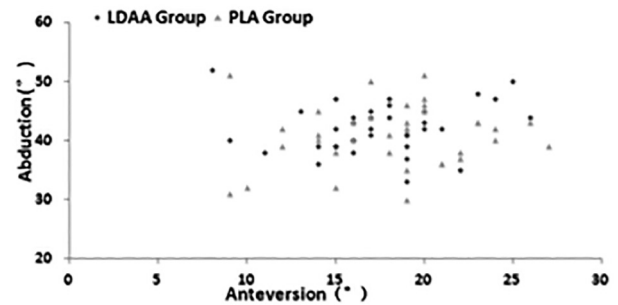


Fig. 7. — Scatter plot comparing variability in acetabular component position between the two groups

loss ($P < 0.001$; Table II) and mean postoperative drainage ($P < 0.001$; Table II) between the two groups. The LDA was associated with shorter mean incision length, shorter mean length of stay, lower mean intraoperative blood loss, and lower mean postoperative drainage. The average HGB levels of the LDA group was significantly higher on postoperative days 1, 3 and 5 ($P < 0.05$; Fig. 3). The rate of perioperative transfusions was similar between the two groups ($P > 0.05$; Table II).

Comparison of radiological outcomes showed that the average angle of cup anteversion was similar between the LDA group (17.41°) and the PLA group (18.13° , $P = 0.473$), and the average

angle of cup abduction was similar between the LDA group (42.17°) and the PLA group (40.86° , $P = 0.245$). There was a similar variance in acetabular component anteversion and acetabular component abduction between the two groups ($P > 0.05$; Table II and Fig. 7). There was no statistically significant difference in the probability of stem neutral position between the two groups ($P > 0.05$; Table II).

For postoperative days 1 through 3, the LDA group was associated with lower average VAS score ($P < 0.001$; Table III). Conversely, the LDA group was associated with higher average HHS at 6 weeks, 3 months and 6 months postoperatively ($P < 0.001$; Table III).

On postoperative days 1, 3, and 5, the LDA group was associated with lower levels of the inflammatory marker CRP ($P < 0.001$; Fig. 4). Similarly, the levels of the muscle damage markers

Table II. – Surgical and postoperative data

Variable, Mean (SD)	LDAA Group (n = 36)	PLA Group (n = 36)	P-Value
Incision, cm	8.23(0.44)	10.32(0.46)	P < 0.001
Operation time, min	74.61(4.85)	61.64(5.29)	P < 0.001
Intraoperative blood loss, ml	168.50(30.40)	286.36(30.79)	P < 0.001
Postoperation drainage, ml	91.58(10.14)	127.44(11.30)	P < 0.001
Length of stay, d	4.05(0.71)	5.44(0.77)	P < 0.001
Cup anteversion, deg	17.41(9.97)	18.13(4.51)	0.473
Cup abduction, deg	42.17(4.17)	40.86(5.22)	0.245
Stem neutral, n(%)	33(92%)	32(89%)	0.159
Blood transfusion, n	2	3	0.188
Complication, n	0	1	1.400

LDAA, direct anterior approach in the lateral decubitus position; *PLA*, posterolateral approach

Table II. – Postoperative VAS and HHS

Variable, Mean (SD)	LDAA Group (n = 36)	PLA Group (n = 36)	P-Value
VAS			
Score at 1 day	3.50(0.37)	4.10(0.38)	P < 0.001
Score at 2 day	2.39(0.35)	3.19(0.31)	P < 0.001
Score at 3 day	1.60(0.23)	2.31(0.27)	P < 0.001
HHS			
Score at 6 weeks	80.33(3.40)	75.02(3.53)	P < 0.001
Score at 3 months	86.81(4.50)	80.03(4.00)	P < 0.001
Score at 6 months	93.14(3.09)	88.06(3.29)	P < 0.001

VAS, Visual analogue score; *HHS*, Harris hip score; *LDAA*, direct anterior approach in the lateral decubitus position; *PLA*, posterolateral approach

CK and MYO were lower than in the PLA group (P < 0.001; Fig. 5 and Fig. 6).

During the six-month follow-up period, there was no significant difference in postoperative complication rates between the two groups (P > 0.05; Table II). Only one postoperative complication (dislocation) occurred in the PLA group, while no complications occurred in the LDAA group.

DISCUSSION

THA can be performed by a variety of approaches. However, controversy remains over which is the most “minimally invasive” approach since minimally-

invasive THA was proposed. Theoretically, the DAA can be considered a minimally-invasive approach because it is performed in an intermuscular plane without detaching any muscles. Of course, this assumption requires some objective indicators for confirmation. The muscle damage indicators and inflammation should be objective indicators which could be used to evaluate muscle damage (17). However, many previous studies obtained a variety of outcomes when the muscle damage indicators and inflammation were used to evaluate muscle damage (3,8,11). In our study, we chose CK and MYO as muscle damage indicators, while CRP was chosen as an indicator of inflammation. Our results

showed that the LDAA is associated with lower levels of CK, MYO, and CRP in the immediate postoperative period, a result which is similar to those of two prospective studies (3,31). These results suggested that the LDAA causes less muscle damage, which is probably related to the fact that no muscles are detached during the surgical procedure. In contrast, the PLA involves detachment of parts of the shorter external rotators, resulting in muscle damage. Although no muscles were detached in the LDAA, the damage indicators and inflammation markers were significantly higher than preoperative levels. We believe this might be due to parts of muscles suffering damage from the retractors.

Our results showed that the LDAA required a shorter incision than the PLA, which is consistent with prospective studies (31). Compared with the PLA, the LDAA was associated with longer operation time and less blood loss. Many surgeons tended to think that the longer an operation lasts, the more blood is lost. However, the LDAA was performed in an intermuscular plane without detachment of any muscles. In addition, the ascending branch of the lateral circumflex femoral artery, which might cause more blood loss, had been ligated in advance. In contrast, not only did the PLA require detachment of the abductor muscles, but it also resulted in a longer surgical incision. Although the operation time for the LDAA was slightly longer than that the PLA, the blood loss was less than the PLA. However, a variety of results have been reported by other studies (1,9,28). Spaans et al. (28) and de Verteuil et al. (9) found that the DAA resulted in longer operation time and more blood loss, while Alecci et al. (1) found no difference in operation time or blood loss between the DAA and the direct lateral approach in their study. Our results also showed that there was less mean postoperative drainage in the LDAA group compared with the PLA group. The average HGB level of the LDAA group was higher than the PLA group on the postoperative days examined, which might be due to the reduced blood loss and reduced postoperative drainage. However, there was no significant difference in the rate of perioperative transfusions between the two groups.

There was a significant difference in the average VAS score between the LDAA and PLA groups.

The LDAA was associated with a lower VAS score on the postoperative days examined. The results were similar to those of some previous studies (7,24). Better pain relief allowed patients to perform functional exercises earlier, which likely influenced the postoperative functional recovery and the length of stay. Our study showed that the HHS of the LDAA group was higher than that of the PLA group at 6 weeks, 3 months, and 6 months postoperatively. These results were not exactly consistent with the results of one previous study (2,31). However Barrett et al. (2) reported that a group treated by the DAA gained higher HHS than the PLA group at 6 weeks postoperatively. Cheng et al. (31) also obtained a similar result at 3 months after surgery. These outcomes support the theory that the DAA group could recover faster during the early postoperative stage. The PLA group was associated with worse pain relief and function during the early postoperative stage. We consider that detachment of the shorter external rotators might be the main reason. Compared with the PLA, our study showed that the LDAA was associated with shorter length of stay. It is likely that since the LDAA allowed the patients to recover more quickly, they were able to reach the discharge standard earlier, which reduced the need for a longer hospital stay. Two previous studies (1,12) have yielded similar results.

The orthopedic surgeons were concerned about the orientation of the component, because it can influence the stability and the longevity of the implants (29). We found no significant difference in acetabular component anteversion or acetabular component abduction between the two groups. We consider that the orientation of the component depends mainly on the doctor's experience and the intraoperative position. In our study, all operations were performed with the patient in the decubitus position by the same experienced surgeon, which might contribute to the similar variance in acetabular component anteversion and abduction. Different results were reported by Hamilton et al. (13) and Maeda et al. (15), who found that the LDAA was more stable than other approaches in regard to the variation of cup position. Nakata et al. (20) believed that the best position for a femoral prosthesis was the "neutral position". Our study showed that there

is no significant difference in the probability of stem neutral between the two groups, which is similar to the results of a previous study (20).

In our study, there was no significant difference in postoperative complication rates between the two groups. A previous study (28) reported that the DAA was associated with higher complication rates, and suggested that the learning curve for the DAA was the main reason. At least 46 surgeries were needed to complete the learning curve (28). The surgeon who performed the operations in our study had completed more than 100 surgeries with the LDAA before deciding to carry out the study, which avoided the impact of a learning curve. In addition, the LDAA in our study was performed in the lateral decubitus position, which might reduce complication rates (16).

To our knowledge, our study is the only prospective randomized study to compare the LDAA with the standard PLA. However, our study had several limitations. First, our study involved a small sample size and short follow-up period. Furthermore, we only collected data in one hospital, and all operations were performed by a single surgeon. A prospective, multi-center, large sample and long follow-up study may provide stronger evidence to assess the advantages and disadvantages of the two approaches. Finally, we did not carry out gait analysis, which has been reported in other studies.

CONCLUSIONS

Compared with the PLA, our results showed that for THA, patients treated by the LDAA could achieve a faster functional recovery with less muscle damage and better pain relief. In addition, the LDAA was associated with shorter incision, less intraoperative blood loss, less postoperative drainage and shorter length of stay than the PLA. However, no significant differences were found in complication rates, perioperative transfusion rates, orientation of acetabular component or position of the femoral prosthesis.

REFERENCES

1. **Alecci V, Valente M, Crucil M et al.** Comparison of primary total hip replacements performed with a direct anterior approach versus the standard lateral approach : perioperative findings. *J Orthop Traumatol* 2011 ; 12 : 123-129.
2. **Barrett WP, Turner SE, Leopold JP.** Prospective randomized study of direct anterior vs postero-lateral approach for total hip arthroplasty. *J Arthroplasty* 2013 ; 28 : 1634-1638.
3. **Bergin PF, Doppelt JD, Kephart CJ et al.** Comparison of minimally invasive direct anterior versus posterior total hip arthroplasty based on inflammation and muscle damage markers. *J Bone Joint Surg Am* 2011 ; 93 : 1392-1398.
4. **Brokelman RB, Haverkamp D, van Loon C.** The validation of the visual analogue scale for patient satisfaction after total hip arthroplasty. *Eur Orthop Traumatol* 2012 ; 3 : 101-105.
5. **Chechik O, Khashan M, Lador R et al.** Surgical approach and prosthesis fixation in hip arthroplasty world wide. *Arch Orthop Trauma Surg* 2013 ; 133 : 1595-1600.
6. **Chen Min, Luo Zhengliang, Ji Xiaofeng et al.** Direct Anterior Approach for Total Hip Arthroplasty in the Lateral Decubitus Position : Our Experiences and Early Results.[J] *J Arthroplasty* 2017; 32 : 131-138.
7. **Christensen CP, Jacobs CA.** Comparison of Patient Function during the First Six Weeks after Direct Anterior or Posterior Total Hip Arthroplasty (THA) : A Randomized Study. *J Arthroplasty* 2015 ; 30 : 94-97.
8. **De Anta-Diaz B, Serralta-Gomis J, Lizaaur-Utrilla A.** No differences between direct anterior and lateral approach for primary total hip arthroplasty related to muscle damage or functional outcome. *Int Orthop* 2016 ; 40 : 2025-2030.
9. **de Verteuil R, Imamura M, Zhu S et al.** A systematic review of the clinical effectiveness and cost-effectiveness and economic modelling of minimal incision total hip replacement approaches in the management of arthritic disease of the hip. *Health Technol Assess* 2008 ; 12 : iii-iv, ix-223.
10. **Dosanjh S, Matta JM, Bhandari M et al.** The final straw : a qualitative study to explore patient decisions to undergo total hip arthroplasty. *Arch Orthop Trauma Surg* 2009 ; 129 : 719-727.
11. **Fink B, Mittelstaedt A, Schulz MS.** Comparison of a minimally invasive posterior approach and the standard posterior approach for total hip arthroplasty A prospective and comparative study. *J Orthop Surg Res* 2010 ; 5 : 46.
12. **Fransen B, Hoozemans M.** Direct anterior approach versus posterolateral approach in total hip arthroplasty : one surgeon, two approaches. *Acta Orthop Belg* 2016 ; 82 : 240-248.
13. **Hamilton WG, Parks NL, Huynh C.** Comparison of Cup Alignment, Jump Distance, and Complications in Consecutive Series of Anterior Approach and Posterior Approach Total Hip Arthroplasty. *J Arthroplasty* 2015 ; 30 : 1959-1962.

14. **Judet J, Judet R.** The use of an artificial femoral head for arthroplasty of the hip joint. *J Bone Joint Surg Br* 1950 ; 32-B : 166-173.
15. **Maeda Y, Sugano N, Nakamura N et al.** The Accuracy of a Mechanical Cup Alignment Guide in Total Hip Arthroplasty (THA) Through Direct Anterior and Posterior Approaches Measured with CT-Based Navigation. *J Arthroplasty* 2015 ; 30 : 1561-1564.
16. **Melman WP, Mollen BP, Kollen BJ et al.** First experiences with the direct anterior approach in lateral decubitus position : learning curve and 1 year complication rate. *Hip Int* 2015 ; 25 : 251-257.
17. **Mjaaland KE, Kivle K, Svenningsen S.** Comparison of markers for muscle damage, inflammation, and pain using minimally invasive direct anterior versus direct lateral approach in total hip arthroplasty : A prospective, randomized, controlled trial. *J Orthop Res* 2015; 33 : 1305-1310.
18. **Moretti Vincent M, Post Zachary D.** Surgical Approaches for Total Hip Arthroplasty.[J]. *Indian J Orthop* 2017; 51 : 368-376.
19. **Moskal JT, Capps SG, Scaneli JA.** Anterior muscle sparing approach for total hip arthroplasty. *World J Orthop* 2013 ; 4 : 12-18.
20. **Nakata K, Nishikawa M, Yamamoto K.** A clinical comparative study of the direct anterior with mini-posterior approach : two consecutive series. *J Arthroplasty* 2009 ; 24 : 698-704.
21. **O'Brien RM.** The technic for insertion of femoral head prosthesis by the straight anterior or Hueter approach. *Clin Orthop* 1955 ; 6 : 22-26.
22. **Post Z, Moretti V.** Surgical approaches for total hip arthroplasty. *Indian J Orthop* 2017 ; 51 : 368.
23. **Pradhan R.** Planar anteversion of the acetabular cup as determined from plain anteroposterior radiographs. *J Bone Joint Surg Br* 1999 ; 81 : 431-435.
24. **Renken F, Renken S, Paech A et al.** Early functional results after hemiarthroplasty for femoral neck fracture : a randomized comparison between a minimal invasive and a conventional approach. *BMC Musculoskelet Disord* 2012 ; 13 : 141.
25. **Rykov K, Reininga IHF, Sietsma MS et al.** Posterolateral vs Direct Anterior Approach in Total Hip Arthroplasty (POLADA Trial) : A Randomized Controlled Trial to Assess Differences in Serum Markers. *J Arthroplasty* 2017 : 32 : 3652-3658.
26. **Smith-Petersen MN.** Approach to and exposure of the hip joint for mold arthroplasty. *J Bone Joint Surg Am* 1949 ; 31A : 40-46.
27. **Söderman P, Malchau H.** Is the Harris hip score system useful to study the outcome of total hip replacement? *Clin Orthop Relat Res* 2001 ; 384 : 189-19.
28. **Spaans AJ, van den Hout JA, Bolder SB.** High complication rate in the early experience of minimally invasive total hip arthroplasty by the direct anterior approach. *Acta orthopaedica* 2012 ; 83 : 342-346.
29. **Wan Z, Boutary M, Dorr LD.** The influence of acetabular component position on wear in total hip arthroplasty. *J Arthroplasty* 2008 ; 23 : 51-56.
30. **White J, Kelly M.** C-reactive protein level after total hip and total knee replacement. *J Bone Joint Surg Br* 1998 ; 80 : 909-911.
31. **Zhao HY, Kang PD, Xia YY et al.** Comparison of Early Functional Recovery After Total Hip Arthroplasty Using a Direct Anterior or Posterolateral Approach : A Randomized Controlled Trial. *J Arthroplasty* 2017 ; 32 : 3421-3428.