



“Less is More” for low grade lumbar spondylolytic spondylolisthesis

Arun-Kumar KALIYA-PERUMAL, Tsai-Sheng FU, Chi-Chien NIU, Po-Liang LAI

From the Department of Orthopaedic Surgery, Spine Division, Bone and Joint Research Center, Chang Gung Memorial Hospital and Chang Gung University College of Medicine, Taoyuan, Taiwan

We analysed if in-situ posterior stabilization and posterolateral fusion without decompression is appropriate for low grade lumbar spondylolytic spondylolisthesis (LLSS). Patients in whom posterior stabilization and interbody fusion with decompression was performed were Group 1 [n = 27; Age = 48.7±13] and those in whom in-situ posterior stabilization and posterolateral fusion without decompression was performed were Group 2 [n = 37; Age = 46.3±16.4]. All preoperative parameters, intra-operative blood loss, duration of surgery and period of hospitalization were similar between the groups. Statistical comparison of outcomes at 2-years follow-up demonstrated no significant difference in back pain score [p = 0.61], sciatic pain score [p = 0.23] and functional assessment [p = 0.71]. Even though we do much less on performing in-situ posterior stabilization and posterolateral fusion without decompression, it offers similar results as that of posterior stabilization and interbody fusion with decompression in selective LLSS patients.

Keywords: Low back pain ; sciatica ; spondylolisthesis ; spinal fusion; spinal stenosis.

INTRODUCTION

Posterior stabilization with fusion and decompression has evolved as an acceptable treatment modality for patients with lumbar spondylolytic spondylolisthesis (3). Interbody fusion is widely practiced for the biomechanical advantage

it offers over conventional posterolateral fusion. Apart from mechanical stability, interbody fusion brings both direct and indirect decompression. The technique involves approaching the disc and preparing it for cage placement, for which one or more posterior elements are usually removed; this offers direct decompression. Indirect decompression is by the distraction occurring due to placement of an interbody cage. These may be vital, but whether it is necessary in low grade lumbar spondylolytic spondylolisthesis (LLSS) (Meyerding's Grade 0, I and II, i.e., less than 50 % translation) needs

■ Arun-Kumar Kaliya-Perumal^{1,2}, MS.

■ Tsai-Sheng Fu³, MD.

■ Chi-Chien Niu³, MD.

■ Po-Liang Lai³, MD., PhD.

¹Spine Fellow, Department of Orthopaedic Surgery, Spine Division, Bone and Joint Research Center, Chang Gung Memorial Hospital and Chang Gung University College of Medicine, Taoyuan, Taiwan; ²Associate Professor, Department of Orthopaedic Surgery, Melmaruvathur Adhiparasakthi Institute of Medical Sciences and Research, Affiliated to The Tamil Nadu Dr MGR Medical University, Tamil Nadu, India; ³Professor, Department of Orthopaedic Surgery, Bone and Joint Research Center, Spine Division, Chang Gung Memorial Hospital and Chang Gung University College of Medicine, Taoyuan, Taiwan.

Correspondence: Dr. Po-Liang Lai, Department of Orthopaedic Surgery, Spine Division, Chang Gung Memorial Hospital, No. 5, Fuxing St., Guishan Dist., Taoyuan City 33305, Taiwan; Tel: +886-3-328-1200 #3612, Fax: +886-3-3278113

E-mail : polianglai@gmail.com

©2020, Acta Orthopædica Belgica.

Conflict of interest: All authors declare that they have not received any funding or other benefits in support of this study. No relevant financial relationships to disclose.

to be studied. Besides that, the risk of handling neural structures when placing a cage should be considered.

Hence, optimising treatment modality for LLSS should be done with clear understanding about the causative factors. Pars interarticularis performs a vital function of aiding the facet joints to withstand the shear forces acting between adjacent vertebrae. When there is a defect in the pars, intervertebral discs are forced to withstand shear forces but eventually fail (5). This leads to collapse of the disc resulting in low back pain corresponding to that level. A reduced intervertebral disc space implies a consequent decrease in room for the exiting nerve root, which may result in sciatic symptoms (6).

In most circumstances, presentation of LLSS can be diverse and sometimes even asymptomatic (8,19). Predominant axial pain without sciatic symptoms is said to be mechanical in origin; but when coupled with sciatica, the reduced foraminal space and the neural irritation caused by the abnormal movement should be considered (4,12). Such neural irritation can be addressed by offering mere mechanical stability i.e., posterior stabilization and posterolateral fusion where neither direct nor indirect decompression occurs (9,14,21). This surgery is believed to be biomechanically adequate when anterior load sharing is preserved (14). However, some surgeons prefer doing decompression as a routine, even if not indicated, at least as a prophylactic measure (1). Our intention is to analyse whether doing less offers more i.e., whether posterior stabilization and posterolateral fusion alone can offer similar results as that of posterior stabilization and interbody fusion with decompression.

METHODS

A retrospective single center study was formulated by selecting two groups of patients from our hospital records who underwent posterior stabilization and fusion, with or without decompression for single level LLSS during 2003 - 2010. Our selection was non-randomised and historically controlled which included consecutive patients operated by the same surgical team with necessary data for a retrospective analysis. Group 1 were those patients we encountered initially in whom

posterior stabilization, decompression and interbody fusion was performed (Fig 1). Group 2 were relatively recent patients in whom in-situ posterior stabilization and posterolateral fusion without decompression was performed (Fig 2). We only included patients with single level LLSS who were refractory to conservative management including medications and physiotherapy prior to surgery. Patients with neurological deficits, multi-level segmental instability, other concomitant degenerative pathologies of spine and those with one or more data missing were excluded.

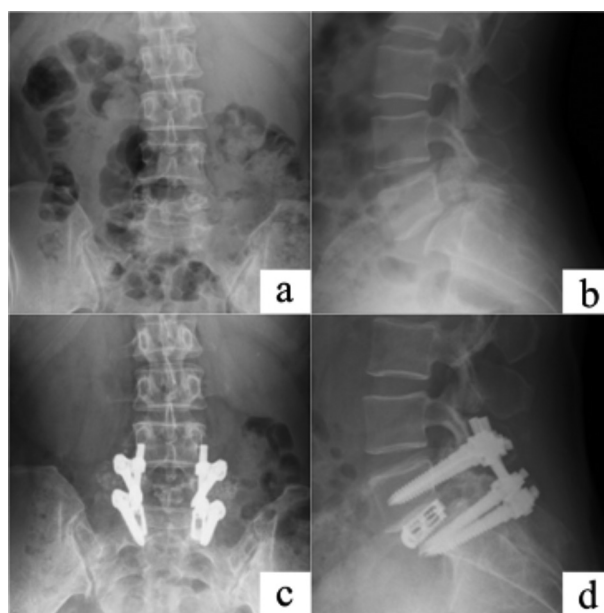


Fig. 1. — Case scenario of a patient from Group 1 who underwent posterior stabilization, decompression and interbody fusion. 1a – Anteroposterior view X-ray image; 1b – Lateral view X-ray image showing spondylolysis and more than 25 percent anterior translation of L5 vertebra over S1; 1c and 1d – Postoperative anteroposterior and lateral view x-ray images showing posterior stabilization and interbody fusion with cages.

Firstly, the demographic data of patients in both the groups were tabulated. Pain was differentiated as low back pain of mechanical origin (felt during rest or routine activity especially at the lower lumbar region) and sciatic pain of neurologic origin (felt occasionally but elicited by straight leg raising test). Rating of pain was done using numeric rating scale (NRS) pain score, with 0 as no pain and 10 as most severe pain. Functional status was assessed using Oswestry disability index. Preoperative antero-posterior (AP),

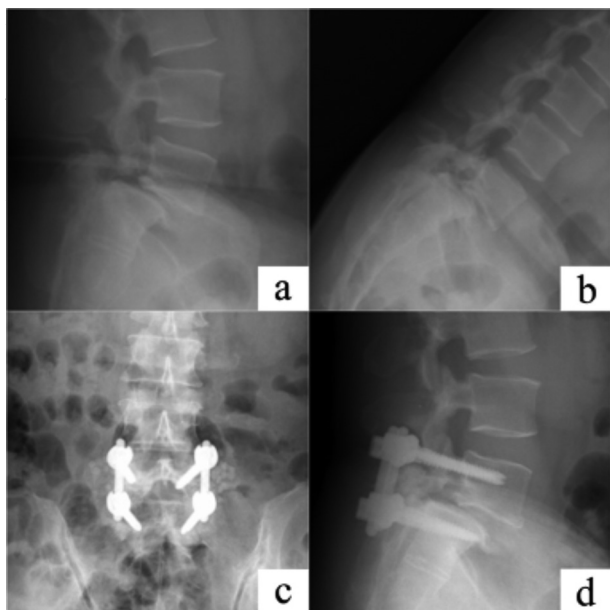


Fig. 1. — Case scenario of a patient from Group 1 who underwent posterior stabilization, decompression and interbody fusion. 1a – Anteroposterior view X-ray image; 1b – Lateral view X-ray image showing spondylolysis and more than 25 percent anterior translation of L5 vertebra over S1; 1c and 1d – Postoperative anteroposterior and lateral view x-ray images showing posterior stabilization and interbody fusion with cages.

lateral and dynamic lateral view standing X-rays were available for assessment in our picture archiving and communication system (PACS). The percentage of translation of one vertebra over another was digitally measured in all lateral view X-rays to determine the grade of spondylolisthesis as per Meyerding's grading system and also to check for dynamic instability (13). MRI images were mainly used to determine if there was a discogenic component or a hypertrophied facet causing neurological compromise. It was also useful for screening adjacent lesions. However, if there was any such adjacent level pathology, those patients were excluded from this study.

Direct decompression by removal of the lamina, pars and inferior facet of the upper vertebra was routinely done in Group 1 patients and the removed local bone was used as graft for fusion; also, the distraction occurring due to the placement of an interbody cage would contribute for indirect decompression in these patients. However, Group 2 patients underwent in-situ posterior stabilization without decompression i.e., neither direct nor indirect decompression; hence, there

was inavailability of local bone chips for doing a posterolateral fusion. This requirement was met with iliac crest autograft which was placed after thorough decortication of the transverse process. Duration of surgery and amount of blood loss were noted.

Patients were mobilized wearing a lumbar brace from the second postoperative day. All patients tolerated the rehabilitation protocols well and were discharged after a week of hospitalization. Patients were restricted doing routine activity until three months following procedure and were advised to continue using the lumbar brace. Patients were evaluated every 3 months for one year and once in 6 months thereafter until two years. Clinical outcome analysis using NRS pain scoring and ODI was done at two year follow up. Follow up was also focused on assessment of failure of fusion and screw loosening using X-ray images; however, routine CT scanning was not done to justify this. A comparison was done between the two groups pertaining to post procedural pain scores and functional assessment using ODI. This interpretation will be the inference from our retrospective analysis.

Statistical calculations were done using Graph Pad Prism 5 [GraphPad Software Inc., San Diego, CA]. Student's "T" test was used to analyse all continuous variables and Fischer's exact test for categorical variables. A probability value of less than 0.05 was considered statistically significant. This study was performed in compliance with the 1964 declaration of Helsinki, its later amendments or comparable ethical standards.

RESULTS

TA total of 64 patients [Age = 47.3 ± 15 years; Male = 23; Female = 41] were selected for this study. Group 1 [n = 27; Age = 48.7 ± 13 (20 – 70) years] and Group 2 [n = 37; Age = 46.3 ± 16.4 (20 – 73) years] were formed based on the operative technique as described in methods. On analysing their data retrospectively, it was noted that all patients had symptoms for a minimum duration of 6 months and were refractory to conservative management. Clinical examination parameters including NRS back pain score, NRS sciatic pain score and preoperative functional assessment using ODI were tabulated (Table I).

Table I. — Preoperative parameters

Variables	Group 1	Group 2	Probability value
Number of patients	n = 27	n = 37	-
Age (Years)	48.7 ± 13	46.3 ± 16.4	p = 0.53
Preoperative NRS ^a back pain score	5.5 ± 2.2	5.5 ± 2.4	p = 0.99
Preoperative NRS sciatic pain score	3.5 ± 3.2	4 ± 3	p = 0.54
Preoperative ODI ^b functional score	42.9 ± 26.6	37.7 ± 23	p = 0.41
Grade of listhesis	Grade 1 = 22; Grade 2 = 5	Grade 1 = 23; Grade 2 = 14	p = 0.11

^aNumeric Rating Scale; ^bOswestry Disability Index; Values are represented as mean ± standard deviation; Probability value less than 0.05 was considered statistically significant

Based on Meyerding's grading, Group 1 consisted of 22 patients with grade 1, and 5 patients with grade 2 spondylolistheses; Group 2 consisted of 23 patients with grade 1, and 14 patients with grade 2 spondylolistheses. This grading remained the same when radiological instability was assessed using dynamic lateral view radiographs. For interpretation, both Grade 1 and Grade 2 spondylolisthesis will be considered as Low Grade ($\leq 50\%$). Among Group 1, the pathological level was L3-L4 in 3 patients, L4-L5 in 8 patients and L5-S1 in 16 patients. Among Group 2, the pathological level was L4-L5 in 13 patients and L5-S1 in 21 patients. The groups did not show any statistically significant difference pertaining to preoperative parameters and were considered to be appropriately matched (Table I).

Operative parameters including blood loss [p = 0.60] and duration of surgery [p = 0.36] did not reveal any significant difference irrespective of the surgical technique used. This could be because in both the groups after initial stabilization using pedicle screws, decompression had to be performed in Group 1 and adequate autograft harvesting had to be done in Group 2; this was equally time consuming and was accountable for the blood loss. The period of hospitalization was also similar between both the groups [p = 0.87]. Early outcome analysis at 3, 6 or 12 months was not performed as we did not have documented data regarding NRS pain score or ODI functional score of that period. Our 2-year outcome analysis revealed notable decrease in pain

scores indicating considerable improvement in both the groups. Functional assessment using ODI also revealed significant betterment among both the groups when compared to preoperative status.

Statistical comparison of outcomes between both the groups to analyse if one had an edge over another, demonstrated no significant difference regarding NRS back pain score [p = 0.61], NRS sciatic pain score [p = 0.23] and functional assessment using ODI [p = 0.71] (Table II). None of the patients showed signs of fusion failure or screw loosening during the entire follow up period. Even though Group 1 patients had the advantage of decompression, Group 2 patients demonstrated similar 2-year outcomes.

DISCUSSION

Spondylolisthesis is regarded as one of the major causes for low back pain (7). Its etiology can be multifactorial and presentations may vary. Isthmic or spondylolytic spondylolisthesis presenting with a defect in the pars interarticularis is the most common variety (2). Unlike other types of spondylolisthesis, isthmic variety does not induce stress on the facet joints due to the discontinuity of pars interarticularis. Hence, the shear forces to be acting on the facet joint are translated to the intervertebral discs. If the intervertebral discs give way, the spondylolisthesis is expected to progress (11).

Table II. — Results

Variables	Group 1	Group 2	Probability value
Duration of surgery (minutes)	184.9 ± 48.8	175.2 ± 36.5	p = 0.36
Blood loss (ml)	316.7 ± 217.1	276.8 ± 350.5	p = 0.60
Hospitalization (days)	7.1 ± 1.2	7.2 ± 2	p = 0.87
NRS ^a back pain score (2 years)	1.7 ± 2.1	1.9 ± 1.6	p = 0.61
NRS sciatic pain score (2 years)	1.2 ± 1.6	1.8 ± 1.9	p = 0.23
ODI ^b functional score (2 years)	19.2 ± 20.8	17.5 ± 16.9	p = 0.71

^aNumeric Rating Scale; ^bOswestry Disability Index; Values are represented as mean ± standard deviation; Probability value less than 0.05 was considered statistically significant.

Pain occurring due to lumbar spondylolisthesis may present with 2 components. Initially there is axial pain localised to the lower back occurring due to mechanical instability; later due to the neural irritation provoked by abnormal motion and foraminal narrowing, radicular pain may develop along the course of an affected nerve (4,12). However, not all patients present with both these pain components. Some may present with only axial or radicular pain, and some even asymptomatic (8). Our patients presented with moderate axial back pain as quantified with NRS pain score during their first hospital visit; however, most patients reported an increase in the intensity of pain during work which urged them to sort intervention. Patients included in this study, not only had axial pain but also a component of sciatic pain which was annoying them.

We consider it important to assess if the sciatic pain component can be well addressed with in-situ fixation and posterolateral fusion, especially when there is a fibrous scar tissue around the pars and an enlarged facet joint which may irritate the nerve root. However, it should be noted that we did not include patients with radiological evidence of a significant concomitant disc prolapse at the same level causing obvious neurological compromise, as this demands a definite decompression.

Considering their facile approach, we used the Numeric Rating Scale (NRS) to assess pain and Oswestry Disability Index (ODI) to assess functional status (10,22). Plain lateral view radiographs and dynamic flexion extension stress lateral view radiographs are highly efficient in diagnosing segmental instability (16,20). Hence,

grading of spondylolisthesis was done as per the widely recognised method of Meyerding, using the plain lateral view X-ray image (13). Besides that, an MRI is absolutely necessary to evaluate the status of the intervertebral discs, neural foramen and facet joints of the affected level and also to identify other concomitant adjacent pathologies that can cause symptoms.

A trail of conservative management is deemed extremely important, especially in low grade spondylolisthesis, as some patients are likely to have better prognosis with conservative measures (15). All our patients were refractory to conservative management and hence surgery was performed. Our hypothesis is that when mechanical instability is appropriately addressed with in-situ stabilization and fusion, the abnormal motion is brought to a halt and further neurological irritation is prevented. This will eventually relieve the patient from both axial back pain and sciatic pain (21). Even though, neither direct nor indirect decompression was performed for the patients in the in-situ fixation group, similar pain relief was obtained as that of the patients in whom adequate decompression was performed as a routine. Both interbody fusion and posterolateral fusion when coupled with posterior stabilization offered adequate stability so that neither the listhesis progressed nor the symptoms recurred during our follow up.

The fibrous scar tissue located surrounding the pars defect in spondylolytic spondylolisthesis is also of concern (17). We noticed that when this fibrous tissue is exuberant and coupled with facet hypertrophy, it can cause notable neurological compromise. It is also said to possess fine nerve

endings which may have nociceptive function (18). Among patients who undergo decompression, neither the fibrous tissue surrounding the pars or the facet hypertrophy is distressing, as they are adequately removed. Even though these issues were not addressed with in-situ fixation without decompression, similar 2-year outcomes were achieved. This phenomenon needs to be studied.

Literature analysing the effect of in-situ posterior stabilization and posterolateral fusion for LLSS is insufficient. Tsirikos AI et al. reported excellent clinical outcomes and patient satisfaction with mere posterolateral fusion without stabilization or decompression in children and adolescents (21). This was similar to our concept of only stabilizing the affected level; however, the adult population is completely different. Concomitant degeneration along with instability may warrant some decompression; however, our 2-year outcomes were in contrast to this understanding.

For interpretation purposes, doing posterior stabilization and interbody fusion with decompression is termed as “doing more” as it requires handling of neural structures thereby posing a potential risk; in contrast, mere in-situ posterior stabilization and posterolateral fusion is termed “doing less” as it is only a stabilizing procedure. Based on our result, we feel that “doing less” is preferable than the complexity of “doing more” and there is actually no need to do a lot where a little will do. This proves that “less is more” in terms of surgery for LLSS.

Being a retrospective study, there are few methodological shortcomings. It should be noted that the selection of patients was consecutive and not randomised. The surgical procedure of fusion was different, and we did not study if one fusion technique was biomechanically better than another; this may have biased our results. It would have been more empirical to discuss the 3, 6 and 12 months’ follow-up pain scoring and functional status; however, it was not discussed due to lack of data.

CONCLUSIONS

In-situ posterior stabilization and posterolateral fusion without decompression offers similar results as that of posterior stabilization and interbody fusion with decompression in selective LLSS patients at two years follow up. Based on our findings, the role of decompression in selective LLSS can be deemed questionable. Besides that, when mechanical instability was appropriately addressed, further neurological irritation was prevented and symptoms eventually decreased. These findings could be of clinical importance; however, study limitations need to be considered and results be interpreted with caution.

REFERENCES

1. **Cheung JP, Cheung PW, Cheung KM, Luk KD.** Decompression without Fusion for Low-Grade Degenerative Spondylolisthesis. *Asian Spine J.* 2016 ; 10 : 75-84.
2. **Ganju A.** Isthmic spondylolisthesis. *Neurosurg Focus.* 2002 ; 13 : E1.
3. **Ghogawala Z, Dziura J, Butler WE, et al.** Laminectomy plus Fusion versus Laminectomy Alone for Lumbar Spondylolisthesis. *N Engl J Med.* 2016 ; 374 : 1424-34.
4. **Harmon PH.** Indications for spinal fusion in lumbar diskopathy, instability and arthrosis. I. Anatomic and functional pathology and review of literature. *Clin Orthop Relat Res.* 1964 ; 34 : 73-91.
5. **Jaumard NV, Welch WC, Winkelstein BA.** Spinal facet joint biomechanics and mechanotransduction in normal, injury and degenerative conditions. *J Biomech Eng.* 2011 ; 133 : 071010.
6. **Kalichman L, Hunter DJ.** Diagnosis and conservative management of degenerative lumbar spondylolisthesis. *Eur Spine J.* 2008 ; 17 : 327-35.
7. **Kalichman L, Kim DH, Li L, et al.** Spondylolysis and spondylolisthesis: prevalence and association with low back pain in the adult community-based population. *Spine (Phila Pa 1976).* 2009 ; 34 : 199-205.
8. **Libson E, Bloom RA, Dinari G.** Symptomatic and asymptomatic spondylolysis and spondylolisthesis in young adults. *Int Orthop.* 1982 ; 6 : 259-61.
9. **Lin TY, Liao JC, Tsai TT, et al.** The effects of anterior vacuum disc on surgical outcomes of degenerative versus spondylolytic spondylolisthesis: at a minimum two-year follow-up. *BMC Musculoskelet Disord.* 2014 ; 15 : 329.
10. **Longo UG, Loppini M, Denaro L, Maffulli N, Denaro V.** Rating scales for low back pain. *Br Med Bull.* 2010 ; 94 : 81-144.

11. **Melnyk AD, Kingwell SP, Zhu Q, et al.** An in vitro model of degenerative lumbar spondylolisthesis. *Spine (Phila Pa 1976)*. 2013 ; 38 : E870-7.
12. **Mulholland RC.** The myth of lumbar instability: the importance of abnormal loading as a cause of low back pain. *Eur Spine J*. 2008 ; 17 : 619-25.
13. **Niggemann P, Kuchta J, Grosskurth D, et al.** Spondylolysis and isthmic spondylolisthesis: impact of vertebral hypoplasia on the use of the Meyerding classification. *Br J Radiol*. 2012 ; 85 : 358-62.
14. **Oda I, Abumi K, Yu BS, Sudo H, Minami A.** Types of spinal instability that require interbody support in posterior lumbar reconstruction: an in vitro biomechanical investigation. *Spine (Phila Pa 1976)*. 2003 ; 28 : 1573-80.
15. **Omidi-Kashani F, Ebrahimzadeh MH, Salari S.** Lumbar Spondylolysis and Spondylolytic Spondylolisthesis: Who Should Be Have Surgery? An Algorithmic Approach. *Asian Spine Journal*. 2014 ; 8 : 856.
16. **Pitkanen MT, Manninen HI, Lindgren KA, et al.** Segmental lumbar spine instability at flexion-extension radiography can be predicted by conventional radiography. *Clin Radiol*. 2002 ; 57 : 632-9.
17. **Rajasekaran S, Subbiah M, Shetty AP.** Direct repair of lumbar spondylolysis by Buck's technique. *Indian J Orthop*. 2011 ; 45 : 136-40.
18. **Schneiderman GA, McLain RF, Hambly MF, Nielsen SL.** The pars defect as a pain source. A histologic study. *Spine (Phila Pa 1976)*. 1995 ; 20 : 1761-4.
19. **Standaert CJ, Herring SA.** Spondylolysis: a critical review. *Br J Sports Med*. 2000 ; 34 : 415-22.
20. **Sun Y, Wang H, Yang D, et al.** Characterization of radiographic features of consecutive lumbar spondylolisthesis. *Medicine (Baltimore)*. 2016 ; 95 : e5323.
21. **Tsirikos AI, Sud A, McGurk SM.** Radiographic and functional outcome of posterolateral lumbosacral fusion for low grade isthmic spondylolisthesis in children and adolescents. *Bone Joint J*. 2016 ; 98-B : 88-96.
22. **Vincent JI, Macdermid JC, Grewal R, Sekar VP, Balachandran D.** Translation of oswestry disability index into Tamil with cross cultural adaptation and evaluation of reliability and validity. *Open Orthop J*. 2014 ; 8 : 11-9.