



Results of “Trochanteric Femoral Nailing (TFN)” in comminuted unstable trochanteric fractures

S. MANDAL, U. BANERJEE, A.S. MUKHERJEE, P. SAHA, S. MANDAL, S. KUNDU

From the West Bengal University of Health Sciences

Unstable trochanteric fractures and fractures with reverse obliquity pose difficulty in fixation. In recent years, intramedullary nails, for the treatment of comminuted and unstable intertrochanteric hip fractures, are becoming more popular relative to conventional, sliding hip screws.

The purpose of our study was to evaluate the result of Trochanteric femoral nailing in comminuted, unstable Trochanteric femur fracture in terms of anatomical restoration and functional outcome.

It is a prospective and without control study. Trochanteric femoral nailing has been done in comminuted unstable inter-trochanteric fracture femur (AO A2.2 to A3.3) of 25 patients and they are followed up postoperatively for at least 12 months. Pre-operative and post-operative clinical and radiological parameters are compared accordingly.

Union in all cases. Overall complication rate 12% including some implant related complications. Functional outcome on Harris Hip Score is comparable with standard literature.

For treatment of intertrochanteric hip fractures, particularly with comminuted fracture fragments, intramedullary devices offer beneficial features, such as closed insertion, a shorter lever arm, and controlled telescoping of the head-neck fragment.

Insertion of the nail through the tip of the greater trochanter requires less dissection and may lead to less blood loss and fewer wound complications, as well as earlier postoperative mobility. Further biomechanical and clinical studies are necessary to validate the efficacy of the trochanteric femoral nail.

Level of Evidence : Level III therapeutic study.

Keywords : Trochanteric Femoral Nailing ; Treatment options for unstable comminuted trochanteric fractures ; Trochanteric Fixation nail.

INTRODUCTION

Hip fractures remain epidemic among the elderly population, with >300,000 new fractures worldwide occurring each year (1). Unstable intertrochanteric fracture with postero-medial instability and a fracture with reverse obliquity is a great challenge for Orthopaedic surgeons (2). History has provided a variety of implants in surgeon's arsenal [Jewett nail, Holt nail, Massie nail, Ken-Pugh nail, Sliding hip screw devices, Cephalo - medullary nails]. But none are proved to be absolutely effective (3).

■ Dr. Subhadip Mandal, MS orthopaedics, DNB (ortho), MBBS

■ Dr. U. Banerjee, MS orthopaedics, DNB ortho,

■ Dr. A.S. Mukherjee, MS orthopaedics, MBBS

■ Dr. P. Saha, MS orthopaedics, MBBS

■ Dr. Subhajyoti Mandal, MBBS

■ Dr. Srikanta Kundu, MS Ortho, MBBS

West Bengal University of Health Sciences

Correspondence : Dr. Subhadip Mandal, C/o Dr. Subhas ch. Mandal, North-schooldanga, Sukanta-statue, PO+DIST-Bankura, State : West Bengal, India 722101. +918900602915

E-mail : subhadip.mandal007@gmail.com

© 2019, Acta Orthopædica Belgica.

No benefits or funds were received in support of this study.
The authors report no conflict of interests.

Acta Orthopædica Belgica, Vol. 85 - 4 - 2019

Interestingly the short-comings of 'Lag screw and side plate constructs' are loss of purchase, pulling off of the side plate, disengagement of the screw & barrel, over-impaction of fracture fragments, significant loss of limb length, delay in rehabilitation & ambulation (4,5). On the other hand the gamma nail and the PFN have failure rates of [7 - 18 %] such as collapse of the fracture area, cut out of the screws and fracture of the femur shaft (6,7,8). In this scenario, we started evaluation of the results of Trochanteric Femoral nail for comminuted and unstable trochanteric fractures with limited but encouraging published reports (9).

MATERIALS AND METHODS

Ethical Committee of the concerned Institution had granted Ethical approval for this study and it has been performed in accordance with the Ethical standards of the 1964 Declaration of Helsinki as revised in 2000. Written Informed consent in three languages (Local, National and English) were obtained from every patient, prior to include them in the study.

A prospective and without control study was conducted in 25 patients with closed comminuted unstable inter-trochanteric fracture femur (AO A2.2 to A3.3) in the period of Sept 2011 to Aug 2014. Skeletally immature patients, patients with pathological fractures, patients with compound fractures, patients with head injury and other system injuries, associated pre-existing joint diseases in the same or opposite limb and patients with associated neurovascular complications were excluded from study. All the patients were operated with Trochanteric femoral nail (TFN).

Regarding the design of the nail (3) (Fig. 1a, 1b), it is a 3rd generation cephalomedullary nail, made of 316LVM alloy. It has a medio-lateral angle of 6 degrees, available in 9, 10, 11 and 12 mm diameter sizes with fixed length of 180mm. Two options of proximal locking, stabilisation screw (6.4mm) and cervical screw (8mm), and static and dynamic distal locking. Angle between nail and cervical screw is 130 degrees.

Regarding operative procedure, under regional (Spinal or Epidural) anaesthesia on fracture table


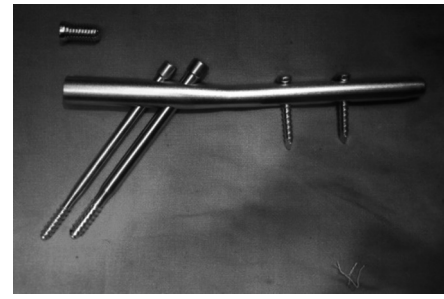


Fig. 1a, 1b. — TFN and associated instrumentation.



Fig. 2. — Positioning.

(Fig. 2) closed reduction of the fracture is done under image-intensifier (if possible). Otherwise mini-open reduction with bone-lever or a steinman pin is achieved. Serially, creation of entry-portal (Fig. 3), insertion of guide-wire (Fig. 4) and progressive reaming upto lesser-trochanter (Fig. 5) is done. After assembling the nail (Fig. 6) it is inserted so

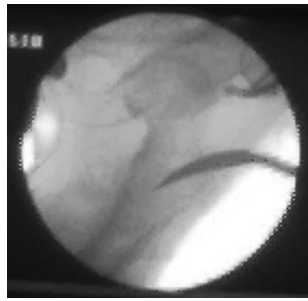


Fig. 3. — Entry point.

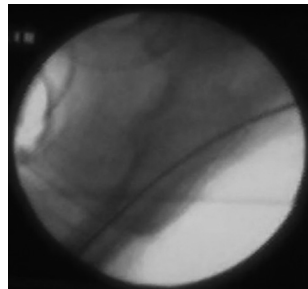


Fig. 4. — Guide-wire.

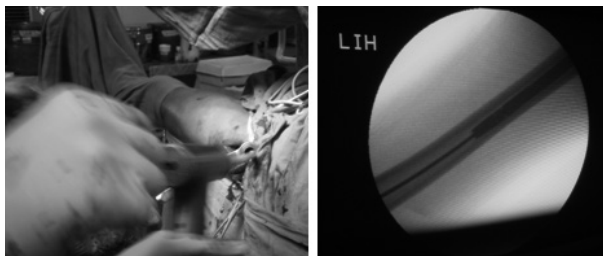


Fig. 5. — Reaming.

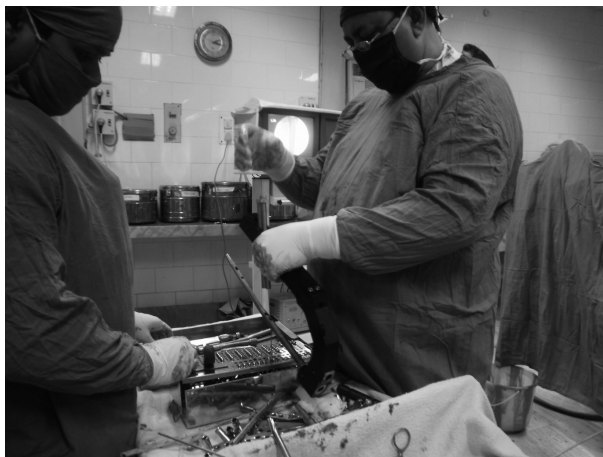

Fig. 6. — Nail assembly.

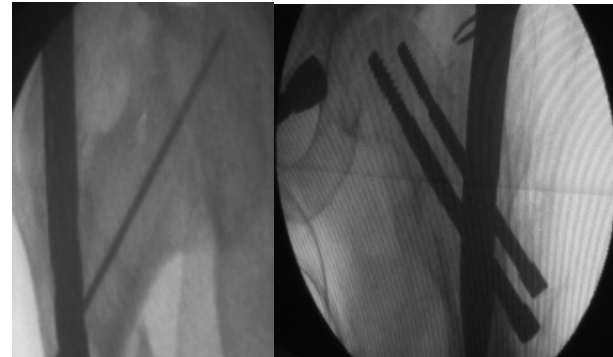


Fig. 7a, 7b. — Proximal locking.

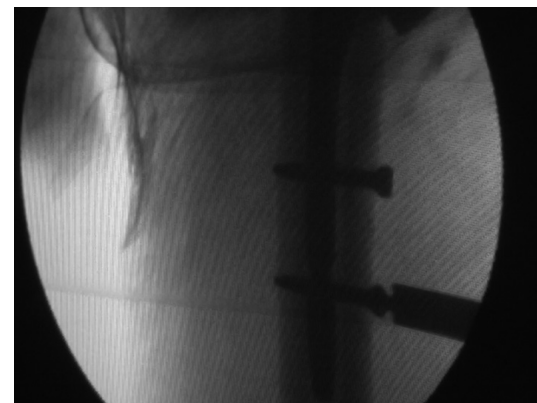


Fig. 8. — Distal locking.

that inferior screw be placed just superior to calcar in AP view and in central position in true lateral view of femoral head and neck. Finally, Proximal locking (Fig. 7a, 7b) and Distal locking through jig. (Fig. 8)

In rehabilitation, active quadriceps, ankle and toe movements from day-1, followed by non-weight bearing active knee flexion. Partial weight bearing given as soon as possible ; dictated by fracture geometry, post-operative reduction and stability of fixation, usually at 3-4 weeks. Full weight bearing advised on clinical and radiological evidence of union.

Regarding follow-up protocol, clinical and radio-logical evaluation done at 2 weeks, 6 weeks, 12 weeks and then as required for the next 9 months. Clinical union is considered as absence of tenderness at fracture site and absence of pain with full weight bearing. Functional status is judged by Harris hip score : At 10 wks, and 14 wks post



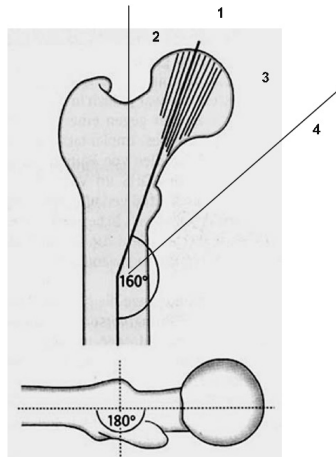


Fig. 9a. — Garden Alignment Index.

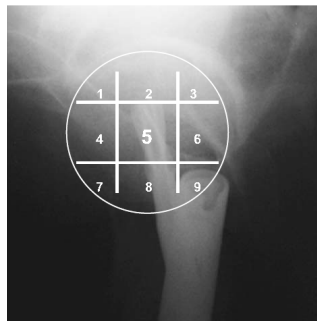


Fig. 9b. — Cleveland Index.

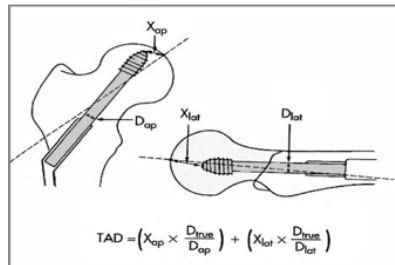


Fig. 9c. — The Tip-apex distance (TAD) measurement.

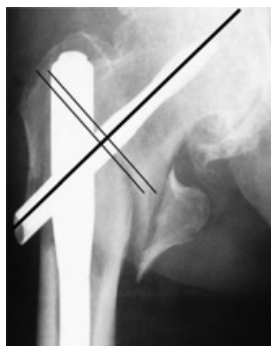


Fig. 9d. — Measurement of the Fracture gap.

operatively. Based on the radiology, the following are noted : fracture union, extent of fracture collapse, medial displacement, neck-shaft angle alteration, implant failure, and change in implant position. Additionally evaluation of Garden alignment index (10) (Fig. 9a) and Cleveland index (10) (Fig. 9b), with measurement of Tip-apex distance (10) (Fig. 9c) and Fracture-gap (10) (Fig. 9d) is simultaneously done at each follow-up visit.

RESULTS

In our study all cases show UNION, 64% cases within 14 wks and 28% cases within 20 wks. Rest 8% beyond 20 wks, (Fig. 10). The average duration of surgery was 88 min. The average time for image intensifier use was 135.5 seconds. In 40% cases blood transfusion was not required, most of which were done after closed reduction. Rest 35% cases required single unit BT and 25% cases needed two units.

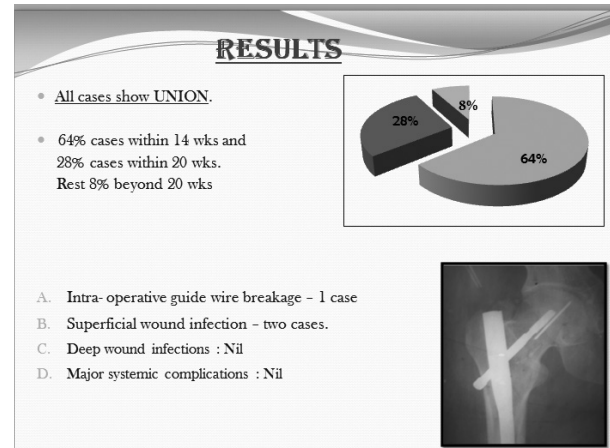
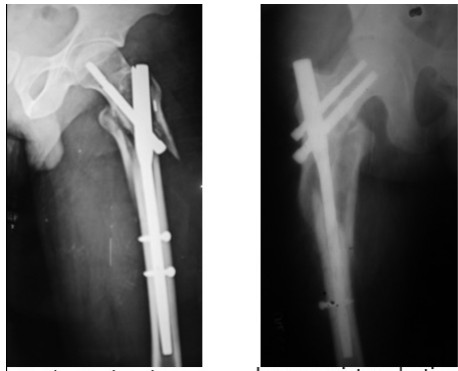
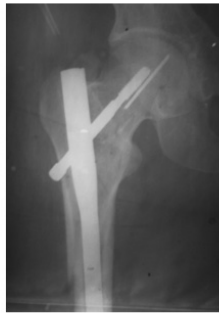
Fig. 10. — Pie Diagram showing - Rate of union.

Regarding complications, intra-operative guide wire breakage happened in a case (Fig. 11), superficial wound infection occurred in two cases and there was no incidence of deep wound infection. No incidence of major systemic complications were encountered. Varus deformity (Fig. 12) was occurred in three cases (12%) in the range of (120-105) deg. Among them, post-operative nail breakage occurred in a case (at the site of a screw hole) (Fig. 13) and limb shortening happened in two cases. One of them



Guide wire breakage and inability to insert hip pin. Inappropriate reduction.



Guide wire breakage and inability to insert neck screw

Fig. 11. — Guide-wire breakage.

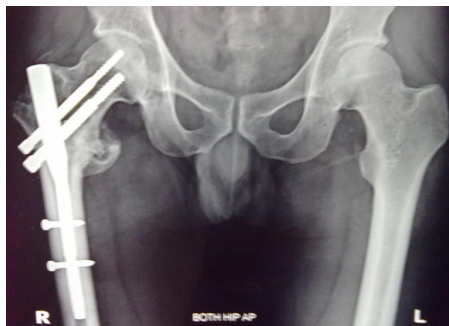

Fig. 12. — Varus deformity.

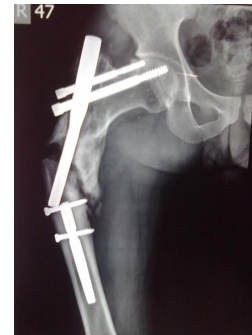

Fig. 13. — Nail breakage.

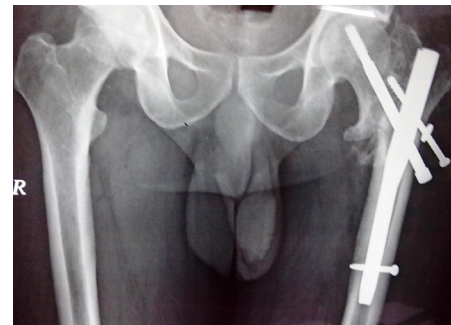


Fig. 14. — Reverse Z effect.

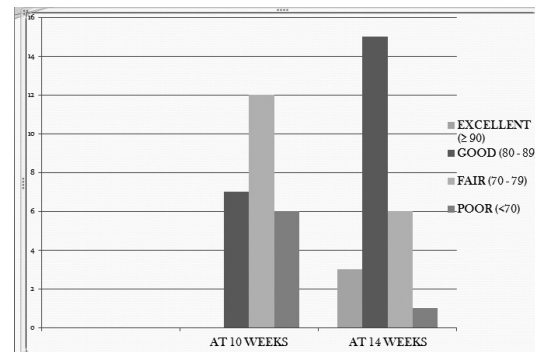


Fig. 15. — Bar Diagram showing - HARRIS HIP SCORE at 10 wks & 14 wks.

had shortening of one cm and was associated with reverse Z deformity (Fig. 14). Another one had shortening of two cm and that was asso with hip pain & sig. ipsilateral knee stiffness.

Regarding HARRIS HIP SCORE and Cleveland Index the results has been depicted in Fig. 15 and Fig. 16 respectively. The Tip-Apex distance (TAD) was on average 12.5 mm, (min 6/max 30). Regarding the fracture gap, a gap was noted on first post-operative X-ray in 9 cases (36%) as shown in (Fig. 17).

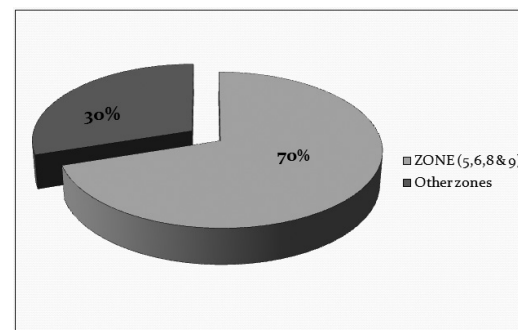


Fig. 16. — Pie diagram showing assessment of Cleveland Index.

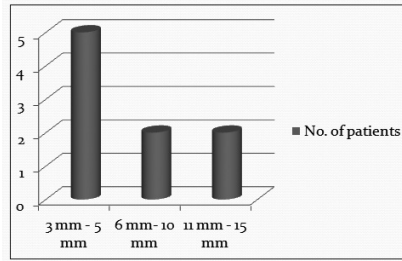


Fig. 17. — Bar Diagram showing distribution of patients according to Fracture Gap.

DISCUSSION

The trochanteric femoral nail is an effective load bearing device that incorporates the principles and theoretical advantages of all the intra medullary devices (3).

In our study, 25 patients were in the range of (32-72) years with male/female (1 :4) in ratio. Fourteen of the fractures were left sided, ten fractures right sided, one bilateral. Mode of Injury was domestic fall 28%, road traffic accident 48%, fall from height 24 %. Age and sex distribution of patients were comparable with the standard literatures (11,12). Major trauma (road traffic accident) was the commonest aetiology (55%), whereas 45% fractures occurred due to accidental fall from height especially in elder population (11). Mean time of interval between injury and surgery was 6 days (range 2 to 17 days). 50% cases were operated within 10 days and another 32% were operated between 0-5 days of admission. Comparable with the series of Sadowski et al. (11) and Boldin C et al. (13) which operated on 6th day 35% and 33% respectively. Cases which are associated with other injuries and co morbid conditions were operated later on.

Regarding associated fractures, in our study distal radius fracture was most frequent, both were in elderly people. Others were ipsilateral both bone forearm fracture, contralateral intertroch femur fracture, ipsilateral clavicle fracture, and ipsilateral shaft of radius fracture mostly in road traffic accident cases. Average duration of surgery in our series was 88 min comparable with Celebi et al. (14) series 95 min. As experience gained over time the duration gradually decreases. Cases operated after closed reductions were completed earlier.

The usage time for image intensifier was 135.5 seconds. Results were comparable to the series Kostal .R et al 2003 (15) of 80 sec and Pavelka .T et al 2003 of 90 sec (16). With successive cases, radiation exposure progressively decreased. Requirement of Blood transfusion depends upon the OT duration and intra-operative blood loss.

In our series, all cases show union. No experience of delayed union and non-union in this study. In the studies by A. Lenich et al. (17) and Ekstrom et al (18) reported no case of non union in their series. Sadowski et al. (2002) (11) reported a 5.6% rate of non union. Regarding HARRIS HIP SCORE, at 10 weeks 75% of cases scored fair to good results and at 14 weeks 90% cases scored more than 70 and most of them were in excellent to good category. Two cases (8%) showed poor result. Both of them were had multiple co-morbidities and did not performed rehabilitation exercises postoperatively. Results were comparable with literatures of Ruecker AH et al. 2009 [HHS (75.1+/-13.4) at 16 weeks] (19) and Loubignac F et al. 2009 [mean HHS 80 at 16 weeks] (20).

Garden alignment index has been used as a tool for judging the quality of the fracture reduction (18). In 32% we saw very well, in 28% good, in 20% satisfying and in 20% bad results. Of note, we did not detect more implant related complications in the patient group with satisfying to bad results.

Regarding the Fracture gap and the low fracture site contact, no significant rotational instability or cutting out of the implant found in subsequent follow-up. We confer it as a sign for the strong stability of implant as suggested by Lenich et al 2006 (17). In most of the cases, radiologic follow-up showed fracture impaction after 6-8 weeks. (Fig. 18a,18b).

Because of the physiological 12 deg anteversion of the neck of femur, the Cleveland zones 5, 6, 8 and 9 are in an area of no rotation forces. We placed most of the tip of cervical screw in zone 5, 6, 8, 9 (70%) (21). Implant tips placed in the zones 4 or 7, are from the bio-mechanical point of view in the area of rotational forces. This might account for rotation of the head and neck fragment with the effect of loosening or cutting out. Other 30% were

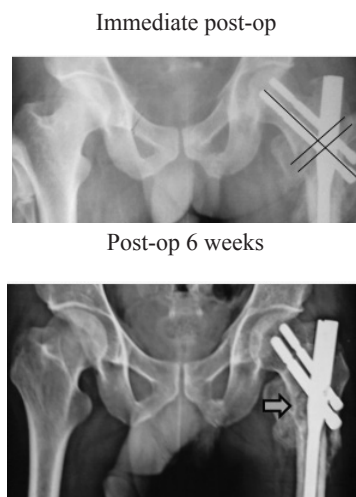


Fig. 18a, 18b. — Post-op serial X-rays showing reduction of fracture gap.

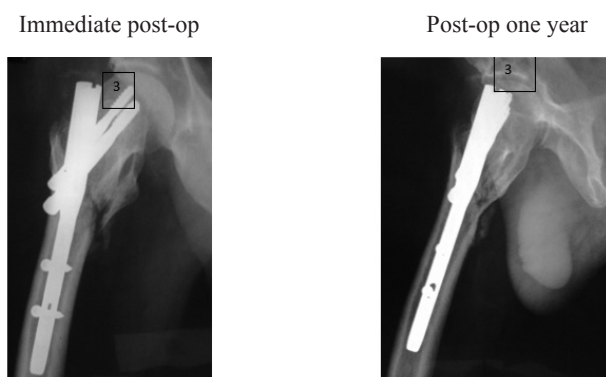


Fig. 19a, 19b. — Post-op follow-up x-rays in consideration of Cleveland zones.

mistakenly placed in the unstable zones but showed no signs of loosening. (Fig. 19a, 19b).

Baumgaertner described a lower complication rate for implant tips placed close to the subchondral bone of the femoral head (22). Because of the good bone quality in this area, we tried to bring the tip of the cervical screw up to 5 mm close to the subchondral area. Regarding Tip-apex distance (TAD) measurement, we had two cases with TAD > 25 mm, but at the end of one year, no incidence of loss of reduction, or neck screw cut-out been encountered. (Fig. 20a, 20b, 20c, 20d).

Regarding treatment of the complications,

A. Two cases of superficial surgical site infection were cured after proper intravenous antibiotics and sterile dressing.

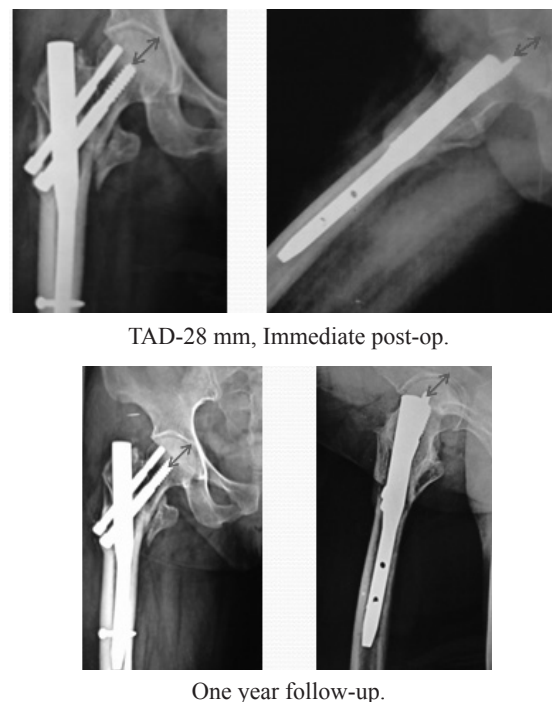

Fig. 20a, 20b, 20c, 20d. — Post-op follow-up x-rays in consideration of (TAD) measurement. (TAD = 28 mm, immediate Post-operative, remained same at 1 yr follow-up).

B. Regarding intra-op guide wire breakage, as the procedure was performed after closed reduction, we had not tried intra-osseous wire removal. We had followed up regularly for signs of wire migration, but it remained stationary at the end of two years without any symptoms.

C. Regarding Neck – shaft angle measurement, fractures unfortunately bound to fix in varus reduction showed implant related complication in two cases.

I. Broken nail – revised with femoral interlocking nail and prolonged bed rest until solid callus formation was evident.

II. Reverse Z deformity – removal of protruded screw done. Fracture healing and subsequent period was uneventful.

III. Limb shortening of 2cm was managed with shoe raise.

IV. Another case was uneventful except for Hip pain & significant ipsilateral knee stiffness. (Fig. 21a, 21b, 21c, 21d).

Until recently most of the trochanteric fractures were treated by sliding hip screw. Since these

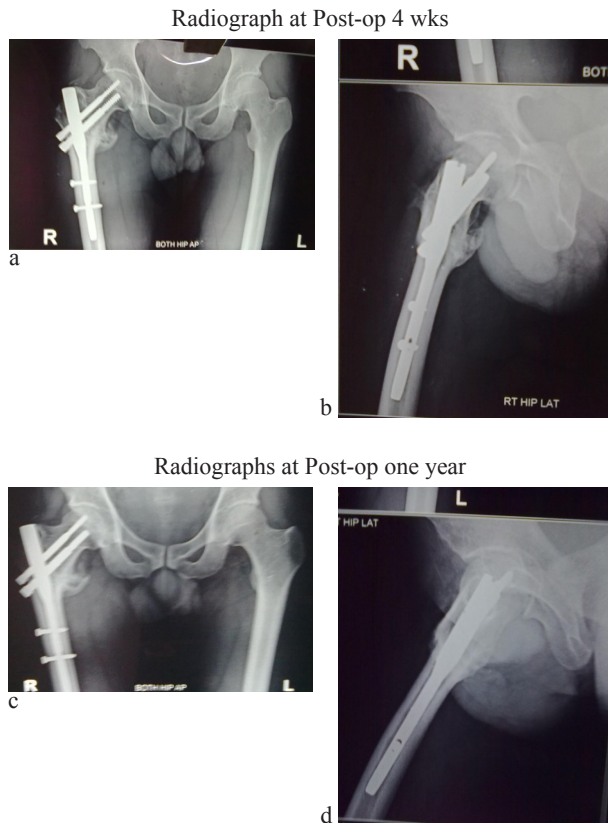


Fig. 21a, 21b, 21c, 21d. —Follow-up X-rays in a patient with varus deformity. (No implant related complications & further varus collapse at the end of 1yr.).

devices performed less well in unstable trochanteric fractures with high rates of failure, intra medullary devices (PFN, RECON nail, TFN) have become increasingly popular (23).

Biomechanically the TFN is stiffer ; it has a shorter moment arm (i.e. from the tip of the lag screw to the centre of the femoral canal) whereas the Dynamic Hip Screw (DHS) has a longer moment arm (i.e. from the tip of the lag screw to the lateral cortex). The DHS with a longer moment arm undergoes significant stress on weight bearing and hence higher incidence of lag screw cut-out and varus malunion (24) The larger proximal diameter of TFN imparts additional stiffness to the nail. It also combines the advantages of closed intramedullary nailing, a dynamic femoral neck screw, minimal blood loss, shorter operative time and early weight bearing than DHS (25). The lateral entry point of TFN is convenient as many patients needing this procedure are elderly and therefore less active ;

resulting in them being overweight and for them TFN is the ideal implant (26).

We found that using two proximal lag screws could provide better rotational control of the femoral head fragment and decrease the cut-out of the femoral head by prevention of head fragment toggling. Anatomical reduction is also extremely important ; especially varus-mal-alignment should be avoided to prevent implant failure.

In this kind of fracture we have not used cerclage wire fixation of the fragments to preserve blood supply to bone and avoid damage to the periosteum, which is the integral part for bone healing.

It may also be important to place the inferior lag screw as close as possible to the inferior femoral neck cortex on AP view and both screws as close as possible to the central part of the femoral head to create a stable fixation and to prevent varus collapse of the femoral head (27).

Patients with narrow femoral canal and abnormal curvature of the proximal femur are the relative contra indications to intra medullary fixation with PFN due to its additional 55-60 mm length (6,7,8). If there is no need for extra stabilisation over a longer nail tip, we recommend the 180 mm long nail.

Disadvantage of the procedure are : entire technique is too instrumentation dependent, it is technically more challenging than side plate system and radiation exposure is comparatively higher than using DHS system. Moreover, iatrogenic separation of fracture fragments occurs at the time of reaming and nails insertion. Not only that, fixation of the unstable postero-medial fragment cannot be achieved by closed means. Additionally there is no mode for providing compression at the fracture site, which is an issue for osteoporotic fractures. Finally, if the nail fails, revision surgery is too tough where chance of fracture neck of femur and osteonecrosis of femoral head is present both intra-operative and post-operatively.

Limitations of our study are lack of control group and relatively small patient population.

Thus, the Trochanteric Femoral Nail, an acceptable minimally invasive, technically demanding implant ; when used in comminuted unstable trochanteric fractures, are more advantageous than extra medullary devices from biological & bio-

mechanical point of view, has less complication rate than its Intramedullary predecessors and thus, been emerged as a good therapeutic option with excellent outcome.

Ethical standard statement

Ethical Committee of the concerned Institution had granted Ethical approval for this study and it has been performed in accordance with the Ethical standards of the 1964 Declaration of Helsinki as revised in 2000. The need for informed consent was waived by the ethical committee since rights and interests of the patients would not be violated and their privacy and anonymity would be assured by this study design.

Acknowledgements

My parents, teachers, the patients and finally my beloved better-half, my wife.

REFERENCES

1. **A. Lenich, E. Mayr et al.** First results with the Trochanter Fixation Nail (TFN) : a report on 120 cases. Springer-Verlag 2006.
2. **Adams CI, Robinson CM, Court-Brown CM, McQueen MM.** Prospective randomized controlled trial of an intramedullary nail versus dynamic screw and plate for intertrochanteric fractures of the femur. *J Orthop Trauma.* 2001 ; 15 : 394-400.
3. **Baumgaertner MR, Curtin SL, Lindskog DM, Keggi JM.** The value of the tip-apex distance in predicting failure of fixation of peritrochanteric fractures of the hip. *J Bone Joint Surg Am.* 1996 ; 78 : 1058-1064.
4. **Boldin C, Seibert F, Fankhauser F et al.** The trochanteric femoral nail (TFN)- a minimal invasive treatment of unstable proximal femoral fractures. A prospective study of 55 patients with a follow up of 15 months. *Acta Orthop Scand.* 2003 ; 74 : 53-58.
5. **Bridle SH, Patel AD, Bircher M, Calvert PT.** Fixation of intertrochanteric fractures of the femur. A randomised prospective comparison of the gamma nail and the dynamic hip screw. *J Bone Joint Surg Br.* 1991 ; 73 : 330-334.
6. **Celebi L, Can M, Muratli HH. et al.** Indirect reduction and biological internal fixation of comminuted intertrochanteric fractures of the femur. *Injury.* 2006 ; 37 : 740-750.
7. **Cleveland M BDM, Thompson F R, Hudson J, Wilson J, Ishizuka Tadao.** A ten year analysis of intertrochanteric fractures of the femur. *J Bone Joint Surg.* 1959 ; 41-A : 1399-1408.
8. **Davis TR, Sher JL, Horsman A, Simpson M, Porter BB, Checketts RG.** Intertrochanteric femoral fractures.

Mechanical failure after internal fixation. *J Bone Joint Surg Br.* 1990 ; 72 : 26-31.

9. **Dousa p, Bartonicek J, Jehlicka D, Skala-Rosenbaum J.** Osteosynthesis of trochanteric fractures using trochanteric femoral nails, *Acta Chir Orthop Traumatol Cech.* 2002 ; 69 : 22-30.
10. **Ekstrom W, Karlsson-Thur C, Larsson S. et al.** Functional outcome in treatment of unstable trochanteric and Subtrochanteric fractures with the Proximal femoral nail and Medoff sliding plate. *J Orthop Trauma.* 2007 ; 21 : 18-25.
11. **Friedl W, Colombo-Benkmann M, Colombo-Benkmann M, Machens HG, Mieck U.** Gamma nail osteosynthesis of per- and Subtrochanteric femoral fractures. 4 years experiences and their consequences for further implant development. *Chirurg.* 1994 ; 65 : 953-963.
12. **Fritz T, Hiersemann K, Krieglstein C, Friedl W.** Prospective randomized comparison of gliding nail and gamma nail in the therapy of trochanteric fractures. *Arch Orthop Trauma Surg.* 1999 ; 119 : 1-6.
13. **Gupta R.K., Sangwan K. et al.** Unstable Trochanteric Fractures : the role of lateral wall reconstruction. *International Orthopaedics (SICOT).* 2010 ; 34 : 125-129.
14. [http ://www.edoctor.co.in/#/dynamic-hip-screw/4529649829](http://www.edoctor.co.in/#/dynamic-hip-screw/4529649829)>.
15. **Jeffrey O. Anglen, MD, and James N.Weinstein.** Nail or Plate Fixation of Intertrochanteric Hip Fractures : Changing Pattern of Practice A Review of the American Board of Orthopaedic Surgery Database. *J Bone Joint Surg.* 2008 ; 700.
16. **Kostal R, Dousa P, Bartonicek J.** The proximal femoral nail(PFN – another alternative for osteosynthesis of trochanteric fractures, *Rozhl Chir.* 2003 ; 82 : 28-31.
17. **Leung KS, So WS, Shun WY, Hui PW.** Gamma nails and dynamic hip screws for peritrochanteric fractures : a randomized prospective study in elderly patients, *J Bone Joint Surg (Br).* 1992 ; 74-8 : 345-51.
18. **Lin J.** Encouraging results of treating femoral trochanteric with specially designed double-screw nails. *J Trauma.* 2007 ; 63 : 866-874.
19. **Loubignac F, Chabas JF.** A newly designed locked intramedullary nail for trochanteric hip fractures fixation : results of the first 100 trochanteric implantations. *Orthop Traumatol Surg Res.* 2009; 95 : 139-144.
20. **Nuber S, Schonweiss T, Rüter A.** Stabilisation of unstable trochanteric femoral fractures. Dynamic hip screw (DHS) with trochanteric stabilisation plate vs. proximal femur nails (PFN). *Unfallchirurg.* 2003 ; 106 : 39-47.
21. *Operative orthopaedics; Campbells 11th edition* 2008.
22. **Palm H, Jacobsen S, Sonne-Holm S, Gebuhr P.** Hip Fracture Study Group Integrity of the lateral femoral wall in intertrochanteric hip fractures : an important predictor of a reoperation. *J Bone Joint Surg Am.* 2007; 89 : 470-475.
23. **Pavelka T, Kortus J, Linhart M.** Osteosynthesis of trochanteric fractures using proximal femoral nails. *Acta Chir Orthop Traumatol Cech,* 2003 ; 70 : 31-8.

24. **Rubenstein L.** Hip protectors—a breakthrough in fracture prevention. *N Engl J Med.* 2000 ; 343 : 1562-1563.
25. **Ruecker AH, Rupprecht M, Gruber M. et al.** The treatment of intertrochanteric fractures : results using an intramedullary nail with integrated cephalocervical screws and linear compression. *J Orthop Trauma.* 2009 ; 23 : 22-30.
26. **Sadowski C, Lubbeke A, Saudan M, Raand N, Stern R, Hoffmeyer P.** Treatment of reverse oblique and transverse intertrochanteric fractures with use of an intramedullary nail or a 95 degree screw plate : a prospective randomised study. *J Bone Surg Am.* 2002 ; 372-81
27. **Utrilla AL, Reig JS, Muñoz FM, Tufanisco CB.** Trochanteric gamma nail and compression hip screw for trochanteric fractures : a randomized, prospective, comparative study in 210 elderly patients with a new design of the gamma nail. *J Orthop Trauma.* 2005 ; 19 : 229-233.

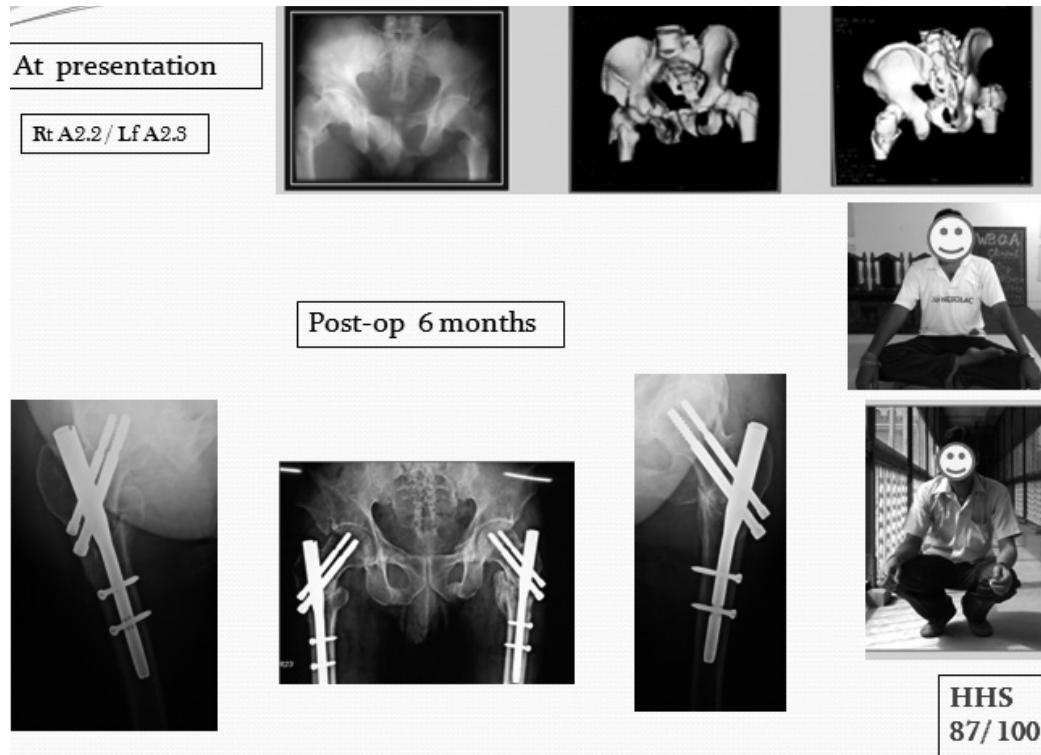


Fig. 22. — Model Case.