



## Acute acromioclavicular joint dislocation treated with tightrope : Mini-open versus percutaneous stabilization

Di LU, Te WANG, Jian-Jun HONG, Hua CHEN, Liao-Jun SUN

From Department of Orthopaedic Surgery, The Second Affiliated Hospital and Yuying Children's Hospital of Wenzhou Medical University, Wenzhou, Zhejiang, China

The purpose of this study was to compare prospectively the radiographic and clinical results of patients treated with tightrope through either mini-open or percutaneous stabilization for acute AC joint injuries. Eighty patients were included in this study and were randomly divided into two groups. Group A included 40 injuries treated with mini-open repair. Group B consisted of 40 injuries treated with percutaneous stabilization. Demographic and clinical data were comparable between the two groups before surgery ( $P>0.05$ ). Peri-operative data, complications and clinical outcomes between the two groups were compared. The average follow-up time of Group A, was  $26.5\pm 4.3$  months and Group B, was  $25.2\pm 5.6$  months ( $P>0.05$ ). The mean operative time was  $63.2\pm 9.6$  minutes and  $45.6\pm 7.1$  minutes, and the mean incision length was  $6.0\pm 1.5$  cm and  $4.0\pm 0.8$  cm, respectively. The operative time and incision length were significantly longer in Group A (both  $P<0.05$ ). However, the radiological assessment revealed no significant difference in the coracoclavicular (CC) distance between the two groups ( $P>0.05$ ). The rate of loss of reduction in the Group A was similar to that in Group B (6/40 vs. 5/40,  $P>0.05$ ).

Both methods were efficient methods for acute AC joint dislocation. However, percutaneous fixation had the advantages of a shorter surgical time and smaller incision length.

Each author certifies that he or she has no commercial associations (e.g., consultancies, stock ownership, equity interest, patent/licensing arrangements, etc.) that might pose a conflict of interest in connection with the submitted article. Each author certifies that his or her institution has approved the reporting of this case and that all investigations were conducted in conformity with ethical principles of research. Conflict of interest : None.

**Keywords :** shoulder ; acromioclavicular injury ; tightrope ; mini-open ; percutaneous stabilization

### INTRODUCTION

Many surgical treatments have been described to type III, IV acromioclavicular (AC) joint dislocations (5,9,21). Anatomical reconstruction of coracoclavicular ligament is the main method of treatment for AC joint injury (4,10,12,17,18,22). Moreover, anatomical reconstruction using tightrope is very popular and good outcomes were reported (8,14,15,19,23). It can be inserted through open or minimally invasive procedure, and many

- Di Lu, MD;
- Te Wang, MD;
- Jian-Jun Hong, MD;
- Hua Chen, MD;
- Liao-Jun Sun, MD

Department of Orthopaedic Surgery, The Second Affiliated Hospital and Yuying Children's Hospital of Wenzhou Medical University, Wenzhou, Zhejiang, China.

Corresponding authors: Di Lu, Department of Orthopaedic Surgery, The Second Affiliated Hospital and Yuying Children's Hospital of Wenzhou Medical University, 109 Xueyuanxi Road, Wenzhou 325000, China. Tel : 86-577-88002810. Fax : 86-577-88879123.

Email: ludi@wmu.edu.cn, ludiyishi@126.com

© 2019, Acta Orthopædica Belgica.

studies have confirmed that mini-open produces satisfactory long-term results (1,23). Until now, only a few reports in the literature about percutaneous stabilization with button plates were found (8), but whether percutaneous stabilization has better outcomes than mini-open technique or not is still unclear. However, there is presently no study comparing the results of mini-open and percutaneous stabilization. The objective of this study was to assess the radiographic and clinical results of patients treated with tightrope through either mini-open or percutaneous stabilization for acute AC joint separation.

### PATIENTS AND METHODS

Between April 2011 and June 2014 at our hospital, 80 patients who underwent AC joint reconstructions using tightrope were considered eligible to participate in our prospective randomized study. Of all the patients, 40 patients underwent mini-open (Group A) and 40 patients underwent the percutaneous stabilization (Group B). Approval for the study was given by the Ethics Committee and informed consent was obtained from all patients before operation. The inclusion criteria were: (1) age from 18 to 60 years, (2) acute dislocations (<3 weeks after trauma) (19), (3) Rockwood type III patients with higher requirements for functional recovery such as manual laborers and athletes, (4) Rockwood IV dislocations, (5) primary reconstruction using tightrope. The following patients were excluded: (1) ipsilateral or contralateral upper limb dislocation, (2) combined with nerve or vascular injury, (3) old acromioclavicular dislocation, (4) patients with osteoporosis, (5) mental illness, (6) patients who declined to participate. At admission, type of treatment was randomized by computer allocation and assigned to the patients prospectively through sequentially numbered opaque envelopes. There was no significant difference in the preoperative variables between the two groups. The patient demographics were shown in Table 1.

All operations were performed by the three upper limb surgeons. The patient was placed in a beach-chair position under general anesthesia. Preoperatively, we measured radiologically the patient's total

Table 1. — Data on the patients

Variable	Group A	Group B	P
Mean age (years)	37.4±10.5	36.6±13.0	0.763 <sup>a</sup>
Sex (male: female, n)	31:9	34: 6	0.390 <sup>b</sup>
Affected side (left : right, n)	25:16	22:19	0.496 <sup>b</sup>
Cause of injury (road accident : fall, n)	27:13	24:16	0.485 <sup>b</sup>
Rockwood type (III:IV, n)	21:19	22:18	0.823 <sup>b</sup>
Injury to surgery time (d)	3.5±2.5	3.0±2.0	0.326 <sup>a</sup>

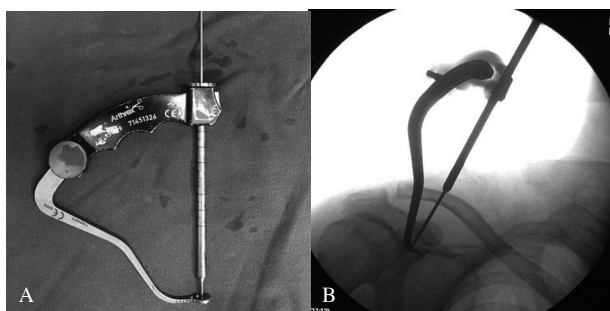
<sup>a</sup> Student's t test. <sup>b</sup> Chi-squared test.  $P < 0.05$  is considered statistically significant.

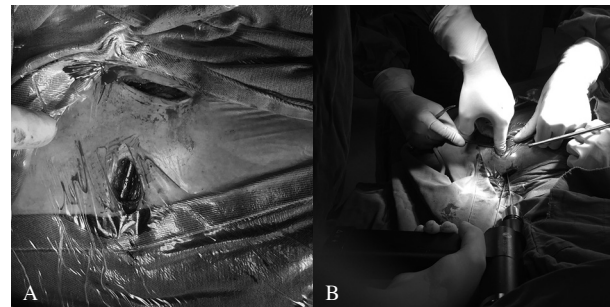

Fig. 1. — A : The coracoid base was under direct visualization. B : Bone tunnel was drilled over through the clavicle.

clavicle length in addition to the standard anatomic landmarks (coracoid, clavicle and acromion). Two independent points, one representing trapezoid insertion which is approximately 2.5 cm from lateral end of the clavicle constituting about 17% of total clavicle length (17), another representing conoid insertion which is approximately 4.5 cm from lateral end of the clavicle constituting about 30% of total clavicle length (17), were marked for optimal clavicular tunnel placement on top of the clavicle with a sterile pen.

For the mini-open technique, a 3 to 4 cm incision was made above the edge of the clavicle and a second 2 to 3 cm incision perpendicular to the clavicle towards the coracoid process would allow direct visualization of its base (Fig. 1A). The clavicle was reduced manually by direct pressure. The reduction of the AC joint was identified by the AP views. Then two guide wires were placed through the clavicle in anatomical positions (Fig. 1B). The exact positioning had been measured according to data by Rios et al. (17) and Salzmann et al. (18). Two independent 4 mm bone tunnels were drilled over the K-wires through the clavicle. The position of the



**Fig. 2.** — A : The guide used in surgery. B : The guide was inserted under the base of the coracoid.

medial drill was slightly posterior of the superior surface of the clavicle. And the position of the lateral drill was slightly anterior to the middle of the clavicle. Then guide wire drilling was continued to the base of the coracoid after confirming that the tip of the guide wire was well centred between the medial and lateral edges of the coracoid. A 4 mm drill was then used to ream over the guide wire. Two suture-button device (TightRope ; Arthrex, FL, USA) were inserted to independently replace the conoid and trapezoid ligaments and hold the AC joint in reduction. The trapezius and deltoid were repaired in layers.

For percutaneous stabilization, a 1 cm vertical skin incision was set directly over approximately 1.5 cm lateral to the coracoid process. The coracoid process was identified and cleared off to the base so clear visualization of the base was achieved. The tip of a drill guide with a marking hook (Acromioclavicular TightRope™-AR1510- Drill Guide, Arthrex, FL, USA) was inserted through the incision and maintained at the center of the coracoid base, and its precise location was checked using radiographs (AP views) (Fig. 2). A second 1 cm skin incision was made over the clavicle, 4.5 cm medial to the AC joint, and the pin-sleeve of the guide was positioned at the previous marked point of the conoid ligament on the clavicle. A 2 mm K-wire was inserted through the clavicle and coracoid and a 4 mm bony tunnels was drilled over the K-wires. Then a third 1 cm skin incision was made over the clavicle, 2.5 cm medial to the AC joint. The drill sleeve was placed on top of the clavicle and a 4 mm bony tunnels were drilled over the K-wires through the clavicle and the coracoid. Two suture-

button device (TightRope ; Arthrex, FL, USA) were inserted through the cannulated guide and the drill bits were removed. First the medial and then the lateral device were tightened by aid of the pulley system and secured by alternating surgical knots in a reduced and fluoroscopically controlled position of the AC joint.

The postoperative treatments in both groups were the same. The arm was placed in a sling for 6 weeks with limited range of motion. Only passive abduction and flexion limited to 90° was allowed during this time. Internal and external rotation was not restricted. On the sixth postoperative week, progressive resistance exercises were encouraged to enhance muscle power. Return to sports activities was allowed 6 months after the operation.

All patients were reviewed at 1, 3, 6, 12 and 18 months and evaluated objectively by clinical and a radiological examination. Standard AP radiographs were obtained for both shoulders in all patients by a seasoned radiologist. A preoperative standard AP and axillary views were used for classification of the Rockwood grade of AC joint separation (17). For data collection, the operative time was defined as the time from the skin incision to skin closure. The fluoroscopy time was obtained from the fluoroscopy logger. The incision length was measured using a sterile ruler during surgery by an independent instrument nurse. The cost included surgeons' payment, hospital bill and hardware. At the 18 months postoperatively, the clinical outcome was evaluated using the simple shoulder test (SST) score (2), Constant score (11), and Visual Analogue Scale (VAS) score (0 representing no pain and 10 representing maximal imaginable pain). The vertical distance between the anterior-inferior border of the clavicle and the superior border of the coracoid process (CC distance) was calculated on standard AP views preoperatively, and at 18 months after surgery on both shoulders.

Statistical analysis was performed using SPSS software, version 11.0 (SPSS, Inc., Chicago, IL, USA). The Pearson's chi-square test and Student's t test were used to compare the clinical outcome of the mini-open group with the percutaneous group, with a *P*-value of < 0.05 considered as significant.

## RESULTS

The average follow-up time of Group A, was  $26.5 \pm 4.3$  (range 20-33 months) and Group B, was  $25.2 \pm 5.6$  (range 18-34 months) ( $P > 0.05$ ). The mean fluoroscopy time, length of hospitalization, hospitalization costs and return to work time did not differ significantly between the two groups (Table 2). However, the patients of Group A had longer operation time ( $63.2 \pm 10$  min vs.  $45.6 \pm 7$  min,  $P < 0.05$ ) and incision length ( $6.0 \pm 1.5$  cm vs.  $4.0 \pm 1$  cm,  $P < 0.05$ ).

Slight loss of reduction, defined as less than 50% of the width of the clavicle, was observed both groups (6 cases in Group A and 5 cases in Group B) with no impact on their functional outcome. No secondary surgical intervention was performed for the loss of reduction. A representative case is shown in Fig. 3. In Group B, one infection was treated with a short course of oral antibiotics and resolved uneventfully. Osteolysis with a small scale occurred around the plate in some cases, mainly in the clavicular side. Five patients had some periarticular ossification between the clavicle and the coracoid

Table 2. — Intraoperative data on the patients

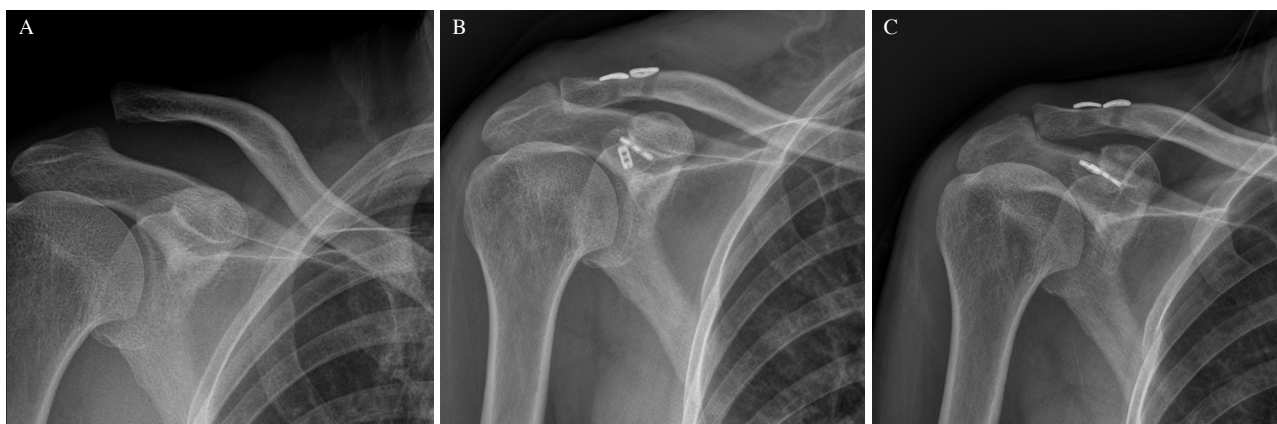
Variable	Group A	Group B	P
Incision length (cm)	$6.0 \pm 1.5$	$4.0 \pm 0.8$	0.000 <sup>a</sup>
Surgery time (min)	$63.2 \pm 9.6$	$45.6 \pm 7.1$	0.000 <sup>a</sup>
Fluoroscopy time (sec)	$19.8 \pm 5.8$	$21.4 \pm 7.5$	0.289 <sup>a</sup>
Length of hospitalization (d)	$6.0 \pm 2.0$	$6.2 \pm 2.1$	0.664 <sup>a</sup>
Hospitalization costs (USD)	$3840.0 \pm 107.5$	$3869.3 \pm 110.6$	0.233 <sup>a</sup>
Return to work time (week)	$8.2 \pm 1.8$	$7.8 \pm 2.0$	0.350 <sup>a</sup>
Follow-up period (m)	$26.5 \pm 4.3$	$25.2 \pm 5.6$	0.248 <sup>a</sup>

<sup>a</sup> Student's t test.  $P < 0.05$  is considered statistically significant.

Table 3. — Postoperative complications on the patients

Variable	Group A	Group B	P
Loss of reduction	6 (15.0%)	5 (12.5%)	0.745 <sup>a</sup>
Infection	0 (0.0%)	1 (2.5%)	1.000 <sup>a</sup>
Osteolysis	4 (10.0%)	3 (7.5%)	1.000 <sup>a</sup>
Heterotopic ossification	2 (5.0%)	3 (7.5%)	1.000 <sup>a</sup>
Total complications	12 (30.0%)	12 (30.0%)	1.000 <sup>a</sup>

<sup>a</sup> Chi-squared test.  $P < 0.05$  is considered statistically significant.



**Fig. 3.** — A : A 47-year-old male patient with a Rockwood type III AC joint dislocation of the right shoulder. B : Postoperative AP radiograph at five months indicated the AC joint also maintained a satisfactory reduction. C : Radiograph at 18 months postoperatively showed a slight loss of reduction compared with figure B.



Table 4. — Functional and radiological outcomes on the patients

	Group A	Group B	P
Constant			
Preoperative	34.4±6.9	34.9±7.1	0.703 <sup>a</sup>
Final follow-up	91.1±3.7	91.5±3.6	0.626 <sup>a</sup>
VAS			
Preoperative	4.6±1.9	4.8±1.7	0.621 <sup>a</sup>
Final follow-up	0.3±0.5	0.3±0.4	1.000 <sup>a</sup>
SST			
Preoperative	2.8±2.2	2.7±2.1	0.836 <sup>a</sup>
Final follow-up	11.8±0.6	11.7±0.8	0.529 <sup>a</sup>
CC distance			
Preoperative	20.4±4.7	19.5±5.6	0.439 <sup>a</sup>
Final follow-up	10.5±3.4	10.3±4.0	0.810 <sup>a</sup>

<sup>a</sup>Student's t test.  $P < 0.05$  is considered statistically significant.

process, which did not cause loss of motion or other symptoms. Moreover, the total incidence of complications in Group A was same as that in Group B (Table 3).

At 18 months postoperatively, the mean CC distance on anteroposterior view was 10.5±3.4 (range 10.1-16.6 mm) in Group A versus 10.3±4.0 (range 10.7-16.3 mm) in Group B. Compared with preoperative data, the average CC distance decreased significantly in both groups ( $P < 0.05$ ). There were no significant differences in the SST, Constant and VAS scores between the two groups (Table 4).

## DISCUSSION

Today, there are numerous published articles reporting on encouraging clinical outcomes in patients operated upon with either mini-open or percutaneous stabilization using tightrope (8,15,19,23).

From our data, there were no significant differences in the mean fluoroscopy time, length of hospitalization, hospitalization costs and time of returning to work between the two groups. Interestingly, the operative time and incision length of in Group A was significantly longer. The cause might be that the mini-open procedure needed more time to expose the coracoid process and provide direct surgical visualization. Moreover, repairing the trapezius and deltoid in layers would cost more time. Without full exposure of the base

of the coracoid process, percutaneous stabilization could easily provide a satisfactory tunnel drill and subsequent fixation assisted by inserting and maintaining the tip of a guide at the center of the coracoid base. In addition, the three 1-cm-length incisions were directly sutured as one layer and these all shortened the operation time. Furthermore, percutaneous repair required only three 1-cm-length incisions which had shorter total incision length than mini-open technique.

The overall complication rate was no significant difference between the two groups ( $P > 0.05$ ). Loss of reduction was the most common complication and the reported rate of loss of reduction ranged from 12% to 28% (19,20,23). The complication rates in our study were 15.0% in Group A and 12.5% in Group B. All cases had slight loss of reduction that was defined as less than 50% of the width of the clavicle. Without secondary surgical intervention, the loss of reduction had no significant influence on their functional outcomes. Cook et al. (3) found a significant impact of the clavicular bone tunnel position on the failure rate after CC ligament reconstruction. The malalignment of the bone tunnels may cause a wear in the strands leading to failure of the suture. In their biomechanical study, Ferreira et al. (6) found higher peak loads to failure for centre-centre and centre-medial drilling of the coracoid bone tunnel in cortical button reconstructions. Schliemann et al. (20) also reported 7 of the 11 patients with the coracoid button placed laterally to the centre of the coracoid base had an early failure of the reconstruction due to button dislocation. From our practice, we believe that the loss of reduction may determine by the size of the drilled hole and the technical aspects of drilling such a hole in the base of the coracoid.

In addition, osteolysis and ossification along the course of the CC ligaments were also relatively common complications. Despite their irregular incidence (7,16,20), they did not affect the final outcomes.

Salzmann et al. (19) recently reported on their 2-year outcome of 23 cases with Rockwood grade III, IV and V dislocations using two tightrope devices. They found similar functional outcomes to our data. The subjects that have been reported

on by Salzman et al. had Constant scores of 93.9 (12 months postoperatively) and 94.3 (24 months postoperatively). Salzman et al. reported on a SST score of 11.9 (12 months postoperatively) and 12.0 (24 months postoperatively). Similarly, Venjakob et al. (23) also reported good clinical results in a midterm (58-month) findings (19,23). The above scores of our study were comparable with their data. We also found the clinical scores and the radiological assessment revealed no significant difference between the two groups. This showed that these two techniques had similar clinical results.

## REFERENCES

1. **Beris A, Lykissas M, Kostas-Agnantis I, Vekris M, Mitsionis G, Korompilias A.** Management of acute acromioclavicular joint dislocation with a double-button fixation system. *Injury*. 2013 ; 44 : 288-92.
2. **Constant CR, Murley AH.** A clinical method of functional assessment of the shoulder. *Clin Orthop Relat Res*. 1987 : 160-4.
3. **Cook JB, Shaha JS, Rowles DJ, Bottoni CR, Shaha SH, Tokish JM.** Clavicular bone tunnel malposition leads to early failures in coracoclavicular ligament reconstructions. *Am J Sports Med*. 2013 ; 41 : 142-8.
4. **Defoort S, Verbort O.** Functional and radiological outcome after arthroscopic and open acromioclavicular stabilization using a double-button fixation system. *Acta Orthop Belg*. 2010 ; 76 : 585-91.
5. **Epstein D, Day M, Rokito A.** Current concepts in the surgical management of acromioclavicular joint injuries. *Bull NYU Hosp Jt Dis*. 2012 ; 70 : 11-24.
6. **Ferreira JV, Chowaniec D, Obopilwe E, Nowak MD, Arciero RA, Mazzocca AD.** Biomechanical evaluation of effect of coracoid tunnel placement on load to failure of fixation during repair of acromioclavicular joint dislocations. *Arthroscopy*. 2012 ; 28 : 1230-6.
7. **Johansen JA, Grutter PW, McFarland EG, Petersen SA.** Acromioclavicular joint injuries : indications for treatment and treatment options. *J Shoulder Elbow Surg*. 2011 ; 20 : S70-82.
8. **Katsenis DL, Stamoulis D, Begkas D, Tsamados S.** Minimally invasive reconstruction of acute type IV and Type V acromioclavicular separations. *Orthopedics*. 2015 ; 38 : e324-30.
9. **Ladermann A, Gueorguiev B, Stimec B, Fasel J, Rothstock S, Hoffmeyer P.** Acromioclavicular joint reconstruction : a comparative biomechanical study of three techniques. *J Shoulder Elbow Surg*. 2013 ; 22 : 171-8.
10. **Lizaur A, Sanz-Reig J, Gonzalez-Parreno S.** Long-term results of the surgical treatment of type III acromioclavicular dislocations : an update of a previous report. *J Bone Joint Surg Br*. 2011 ; 93 : 1088-92.
11. **Matsen FA, 3rd.** Early effectiveness of shoulder arthroplasty for patients who have primary glenohumeral degenerative joint disease. *J Bone Joint Surg Am* 1996 ; 78 : 260-4.
12. **Mazzocca AD, Arciero RA, Bicos J.** Evaluation and treatment of acromioclavicular joint injuries. *Am J Sports Med*. 2007 ; 35 : 316-29.
13. **Mehrberg RD, Lobel SM, Gibson WK.** Disorders of the acromioclavicular joint. *Phys Med Rehabil Clin N Am*. 2004 ; 15 : v, 537-55.
14. **Pan Z, Zhang H, Sun C, Qu L, Cui Y.** Arthroscopy-assisted reconstruction of coracoclavicular ligament by Endobutton fixation for treatment of acromioclavicular joint dislocation. *Arch Orthop Trauma Surg*. 2015 ; 135 : 9-16.
15. **Petersen W, Wellmann M, Rosslenbroich S, Zantop T.** [Minimally Invasive Acromioclavicular Joint Reconstruction (MINAR)]. *Oper Orthop Traumatol*. 2010 ; 22 : 52-61.
16. **Petron DJ, Hanson RW, Jr.** Acromioclavicular joint disorders. *Curr Sports Med Rep*. 2007 ; 6 : 300-6.
17. **Rios CG, Arciero RA, Mazzocca AD.** Anatomy of the clavicle and coracoid process for reconstruction of the coracoclavicular ligaments. *Am J Sports Med*. 2007 ; 35 : 811-7.
18. **Salzman GM, Paul J, Sandmann GH, Imhoff AB, Schottle PB.** The coracoidal insertion of the coracoclavicular ligaments : an anatomic study. *Am J Sports Med*. 2008 ; 36 : 2392-7.
19. **Salzman GM, Walz L, Buchmann S, Glabgyl P, Venjakob A, Imhoff AB.** Arthroscopically assisted 2-bundle anatomical reduction of acute acromioclavicular joint separations. *Am J Sports Med*. 2010 ; 38 : 1179-87.
20. **Schliemann B, Rosslenbroich SB, Schneider KN, Theisen C, Petersen W, Raschke MJ, et al.** Why does minimally invasive coracoclavicular ligament reconstruction using a flip button repair technique fail? An analysis of risk factors and complications. *Knee Surg Sports Traumatol Arthrosc*. 2015 ; 23 : 1419-25.
21. **Takase K, Yamamoto K.** Changes in surgical procedures for acromioclavicular joint dislocation over the past 30 years. *Orthopedics*. 2013 ; 36 : e1277-82.
22. **Tauber M.** Management of acute acromioclavicular joint dislocations : current concepts. *Arch Orthop Trauma Surg*. 2013 ; 133 : 985-95.
23. **Venjakob AJ, Salzman GM, Gabel F, Buchmann S, Walz L, Spang JT, et al.** Arthroscopically assisted 2-bundle anatomic reduction of acute acromioclavicular joint separations : 58-month findings. *Am J Sports Med* 2013 ; 41 : 615-21.