



## Manipulation under anesthesia for frozen shoulders : a retrospective cohort study

Tim KRAAL, Oetz VAN DER MEER, Maaïke VAN DEN BORNE, Koen KOENRAADT, Denise EYGENDAAL, Ronald BOER

*From the Department of Orthopaedic Surgery, Amphia Hospital, Breda, The Netherlands*

### Abbreviations

MUA, manipulation under anesthesia ; FS, frozen shoulder ; SPADI, Shoulder Pain and Disability Score ; OSS, Oxford Shoulder Score ; NPRS, Numeric Pain Rating Scale.

**Manipulation under anesthesia is a well-established, but controversial, treatment for frozen shoulders. We will evaluate our results of manipulation and physiotherapy in stage two frozen shoulders.**

**Questionnaires were sent to 65 patients with stage 2 frozen shoulders, treated with manipulation under anaesthesia between January 2012 and January 2014. Outcome parameters consisted of SPADI, OSS, EQ-5D, pain and satisfaction.**

**A response rate of 75% was obtained. Mean follow up was 21 months (range 11-36). The median SPADI score was 11.2 (IQR 0.8-25.2) and median OSS was 39.0 (IQR 30-43). Only 72% of patients reported that they reached their pre injury level of functioning. A satisfaction rate of 92% was reported.**

**Manipulation is a relatively easy intervention with a high satisfaction rate. We assume that manipulation could shorten the duration of symptoms. However, this needs to be confirmed in a randomized trial with a control group.**

**Keywords :** Frozen Shoulder ; adhesive capsulitis ; manipulation

*All authors certify that they have NO affiliations with or involvement in any organization or entity with any financial or non-financial interest in the subject matter or materials discussed in this manuscript.*

### INTRODUCTION

Frozen shoulder (FS), also known as adhesive capsulitis, is a common cause of shoulder pain, and affects approximately 2-4% of the general population (24). FS is historically classified in three different stages, freezing (one), frozen (two) and thawing (three) (16). An inflammatory cascade leads to fibrosis and thickening, resulting in contracture of the anterosuperior shoulder capsule and rotator interval, as well as the glenohumeral and coracohumeral ligaments. On clinical examination, there is a typical manifestation of restricted passive external rotation (11,15). Although the etiology and pathophysiology of FS are not fully understood yet, it is known that this process is reversible and, left alone, will show functional recovery within one to three years in most patients (9,16). Despite this,

- T. Kraal MD
- O. van der Meer MD
- MPJ. van den Borne MD
- KLM. Koenraadt, PhD
- D. Eygendaal MD, PhD, professor
- R. Boer MD

*Department of Orthopaedic Surgery, Amphia Hospital, Breda, The Netherlands*

Correspondence : Koen Koenraadt, PhD, orthopaedic research coordinator Amphia Hospital, Department of Orthopaedics, Amphia Hospital, Molengracht 21, 4818 CK Breda, The Netherlands. Telephone : +3176-5953080. Fax : 0765953819

E-mail : kkoenraadt@amphia.nl,  
© 2019, Acta Orthopædica Belgica.

persistent symptoms or restrictions can occur (3,19). Even if the natural course is mostly self-limiting, patients often experience a prolonged period with a considerable amount of pain and disability in daily life. This disorder has a peak incidence between the age of 40 and 65 and can occur in otherwise healthy people (9,23). Therefore, these patients experience substantial limitations in their ability to work. Although some authors suggest that supervised neglect is the most appropriate regimen (5), we believe it is important to endeavour to improve mobility hereby limiting the duration and severity of symptoms. The optimal treatment regimen has not yet been determined, and systematic reviews point to a lack of good quality evidence (10,14,18).

Although nowadays arthroscopic capsular release is probably gaining in popularity, manipulation under anesthesia (MUA) is a traditionally well-established, straightforward treatment method in frozen shoulder. There are no good quality randomized controlled trials in favor of arthroscopic capsular release in comparison to MUA (8). It is unclear at which stage of disease MUA is most beneficial. Consequently, a clear protocol for Orthopaedic Surgeons in treatment of frozen shoulder is lacking. Dodenhof et al describe the capability of MUA to rapidly restore the range of motion and reduce symptoms within days after the procedure (6). However, the role of MUA in the treatment of FS is controversial as it can potentially lead to serious complications such as humeral fracture, glenoid rim fracture, glenohumeral dislocation, brachial plexus traction injury or intra-articular damage to the cartilage or rotator cuff (1,2,13). The true incidence rate of these complications is unknown, but estimated to be 0.5% (8). These are possible reasons why orthopaedic surgeons may have a cautious attitude concerning MUA. A recent survey among shoulder specialists in Belgium and The Netherlands showed that MUA was carried out most frequently at our hospital. We assume that MUA is well tolerated and can lead to satisfactory results with a quicker recovery of function and faster subsequent return to work, compared to a conservative approach. This retrospective study, will critically evaluate the patient reported results, satisfaction after MUA, and safety of the procedure.

## MATERIALS AND METHODS

Questionnaires were sent to all 65 patients who were treated by a single orthopaedic surgeon with MUA between January 2012 and January 2014. The clinical diagnosis of a stage two FS was made on clinical merits by the treating orthopaedic surgeon. Stage two is characterized by diminished pain compared to stage one, marked restriction of passive and active shoulder movements and significant pain mainly at the end range of motion. Conventional radiographs were used to rule out bone abnormalities. Diabetes, thyroid disorders and previous surgery to the shoulder for other reasons were not excluded. Some patients underwent conservative treatment before presenting in the Orthopaedic Department. Conservative treatment options included a course of physiotherapy or sometimes an intra-articular corticosteroid injection.

The questionnaires included the following patient reported outcome measures; Shoulder Pain And Disability Index (SPADI), which consists of five domains of pain and 8 domains of shoulder disability scores on a zero to ten scale. This generates a score between 0 (best) and 100 (worst); (17) Oxford Shoulder Score (OSS), 12 questions related to pain and function of the arm in daily life. Items are responded on a zero to four point scale. This leads to an OSS score between 0 (worst) and 48 (best); (4) EQ-5D, a standardised health questionnaire addressing five domains (mobility, self-care, daily activities, pain/complaints and mood). In addition, patients report their health condition on a 0-100 VAS scale; The Numeric Pain Rating Scale (NPRS) at rest and during activity was reported.

We used two anchor questions regarding patients' pre and post treatment pain (anchor-Pain), and pre and post treatment level of daily functioning (anchor-ADL). This was reported on a seven-point scale. In addition, we asked if reached their pre-injury level of functioning and if patients would opt again for MUA as a treatment procedure in case of a contralateral frozen shoulder. Patients were also asked if they would recommend the procedure to others.

The actual procedure of MUA was performed by a single surgeon in a standardized, identical way in

all cases. An interscalene plexus block was used in all cases. If necessary, short duration general anesthesia was used in a minority of patients when there was still pain or active muscle resistance, or at the request of the patient. The scapula is indirectly stabilized by the supine position. A short lever arm with the elbow flexed at 90 degrees, is used to prevent fractures and brachial plexus traction injuries. The glenohumeral joint is forced through a full range of motion in a strict pattern : anteflexion, abduction, external rotation in 90 degrees' abduction, internal rotation in 90 degrees' abduction, horizontal adduction with dorsal compression and external rotation in neutral. A recognizable tearing sound was always more or less present, which in our experience confirms the diagnosis of frozen shoulder. The sequence was repeated until maximum range of motion was acquired. At the end of the procedure, an infiltration of kenacort 40mg (1 ml) and chirocaine (4ml) was administered in the glenohumeral joint. Postoperative physiotherapy was started directly the same day to maintain the full range of motion that was obtained. Patients remained as hospital in-patients until the morning following their procedure. Intensive physiotherapy was advised, with an aim for a total treatment plan of 2 weeks (6 days a week), and was continued if deemed necessary by the treating physiotherapist.

## RESULTS

Of 65 patients, 49 people (75%) completed and returned the questionnaires. Table I shows the patient characteristics, associated comorbidity and pre-manipulation range of motion. No patients with mamma carcinoma, cerebral vascular accident with shoulder involvement or previous shoulder fractures were involved. Conventional X rays showed no abnormalities in 37 patients (75.5%), mild glenohumeral arthrosis defined as Kellgren Lawrence  $\leq 1$  in 7 patients (14.3%) and calcifications were seen in 5 patients (10,2%). There were seven patients (14.3%) with previous surgery to the affected shoulder for other reasons.

The mean time from onset of symptoms to MUA was 8 months (range 2-25). The mean follow up was 21 months (range 11-36). The median SPADI

Table I. — Patient characteristics (N=49)

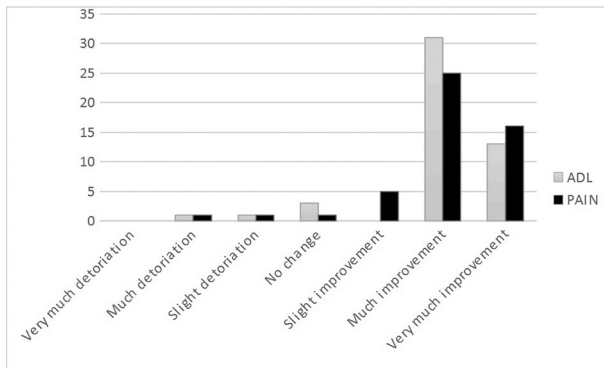
	Mean (SD) or N (%)
Age (years)	57.6 (6.9)
Sex – female	30 (61.2%)
Preferred side affected	25 (51%)
Smoking	12 (24.5%)
Thyroid disorder	5 (10.2%)
Diabetes	5 (10.2%)
Previous shoulder surgery	7 (14.3%)
Previous physical therapy	29 (59.2%)
Previous injections	30 (61.2%)
Pre-MUA anteflexion (degrees)	106 (13)
Pre-MUA abduction (degrees)	105 (13)
Pre-MUA external rotation (degrees)	24 (14)

Table II. — Outcome parameters at mean follow up of 21 months (range 11-36)

Outcome Measure	Mean (SD), median (IQR) or N(%)
NRS pain rest	1 (1-2)
NRS pain activity	1 (1-3)
SPADI	11.2 (0.8-25.2)
OSS	39 (30-43)
EQ-5D	73.8 (18.1)
Recommendation	9 (8-10)
Benefits MUA retained	41 (83.7%)

score at follow up was 11.2 (IQR 0.8-25.2) and the median OSS was 39.0 (IQR 30-43). The mean EQ-5D was 73.8 (SD 18.1). Median NPRS for pain at rest was 1 (IQR 1-2) and median NPRS during activity was also 1 (IQR 1-3). An overview of these results is presented in Table II.

Forty-five patients (92%) reported to be satisfied or very satisfied with the treatment and stated that they would chose the same treatment again if they should suffer a frozen shoulder on the contralateral shoulder. Sixty-five percent reported a pre-injury level of functioning within three months after MUA, and 72% after six months. The maximum effect of MUA was reported within six weeks by 61% of the patients. Forty-one patients (83.7%) reported that the benefits following MUA were retained. The result of both anchor questions related to change in pain and change in daily functioning are shown in Figure 1. Eighty-four percent reported much or very much improvement with respect to the pain after



**Figure 1.** — Results of two anchor questions. Patients were asked to rate their change after manipulation regarding pain (pain) and function in daily life (ADL) on a seven point scale.

the procedure and even 90% reported much or very much improvement with respect to the functioning in daily life.

No complications were seen during manipulation nor reported by the patients afterwards.

## DISCUSSION

This retrospective cohort study tends to demonstrate that MUA followed by physiotherapy treatment is an effective treatment option for patients with an FS in stage two when conservative treatment fails. A high percentage of patients (92%) is satisfied with the procedure. Seventy-two percent of patients reported to reach their pre-injury level of functioning within six months. And the beneficial effect of MUA was retained in 84% (n=41) of patients at a mean follow up of 21 months.

Conservative treatment is widely used in the management of idiopathic frozen shoulders. Conservative treatment mainly consists of corticosteroid injections and, or physiotherapy therapy (18). MUA is indicated when conservative treatment fails. However, it remains unclear when to decide that conservative treatment fails. Some authors doubt the fact if MUA influences the natural course of the disease at all. Kivimäki et al conducted a randomized trial in which MUA was compared to a home exercise program (12). They were not able to demonstrate a beneficial effect of MUA. Unfortunately, 37% of patients were lost to follow up at final follow up.

The physiotherapy intervention in their study was markedly different than in our cohort. We advocate intensive stretching and range of motion exercises supervised by a physiotherapist on a daily basis for the first two weeks to preserve the obtained range of motion. In the study of Kivimäki et al, patients were instructed in only two sessions to exercise by themselves.

Our results regarding satisfaction are in line with the results of Dodenhoff et al, a prospective cohort in which 94% of the patients were satisfied with the procedure after MUA (6). We agree with Dodenhoff et al that this high satisfaction rate might be due to an early recovery of functional activities, within days of the procedure. We found good outcomes on the pain and disability scores SPADI and the OSS, but because of the retrospective nature of the study, we are not able to demonstrate this effect specifically at short term. However, the maximum effect of MUA in our study is reported within six weeks by 61% of patients. Thus, quite an amount of patients (39%) do not experience an immediate response to MUA.

The reports of Vastamäki and Farrel confirm our finding that the obtained results of MUA persists at long term (7,20). Unfortunately, there is a small group of patients (four patients, 8%, in our study) without a positive response to MUA regarding pain and disability. It would be interesting to predict why these patients failed to respond to MUA. However, in the current literature we did not find any risk factors for failure of MUA.

We think that potentially decreasing the duration of pain and disability justifies MUA in patients with frozen shoulder when conservative treatment fails. The disorder is mainly considered self-limiting, so it could be suggested that use of MUA could lead to over-treatment. However, a high threshold for MUA, or late intervention, can lead to an unnecessarily long duration of complaints. Vastamäki et al describe an optimal timing between 6-9 months (21). They retrospectively compared a group treated with MUA between 6 and 9 months, with grossly all the other time points (less than 6 months combined with more than 9 months). From our perspective, this is not convincing evidence to conclude that the optimal time point is between 6 and 9 months from onset of symptoms.

There were some limitations to the current study. The most important is that it lacks a control group to compare these results with the natural course of the disease. Therefore, it is not possible to conclude if the duration of symptoms is shortened by MUA. And more, due to the lack of a control group it is not possible to conclude that the patients are better off treated with MUA than if they were left alone. Also, the potential magnitude of overtreatment cannot be estimated without a control group. The range of motion was only measured when there was an unexpected result. Patients with a good, to very good result, after MUA did not have their range of motion reported in the notes. This cohort does not consist of patients solely with primary idiopathic frozen shoulders. This variety of patients were chosen with the intention of analyzing the entire population who underwent MUA. We included patients with diabetes mellitus and patients with a previous surgical procedure to the affected shoulder. Both groups are too small for reasonable subgroup analysis. It is known that a frozen shoulder in patients with diabetes tends to have a more severe and protracted course (9,22). Non response bias is a possible confounder with a reasonable response rate of 75%.

In conclusion, MUA is a short and relatively easy procedure to perform. If duration of symptoms can be decreased, we hypothesize that it can be cost effective when the socio-economic issues are taken into account. In this retrospective cohort study, good results regarding pain and disability were obtained and patients reported a high satisfaction rate of 92%. However, only 72% of patients reached their pre injury level of functioning. We acknowledge that a control group is essential to evaluate the influence of MUA on the natural course of the disease. A randomized controlled trial with MUA followed by physiotherapy compared to conservative treatment is currently under preparation in our Upper Limb Centre.

## REFERENCES

1. **Amir-Us-Saqlain H, Zubairi A, Taufiq I.** Functional outcome of frozen shoulder after manipulation under anaesthesia. *J Pak Med Assoc.* 2007 ; 57 : 181-185.
2. **Anil Kumar PG, Jacob MB, Newton J, Stewart MPM.** Transient brachial plexus palsy following manipulation and local anaesthetic infiltration of a "primary frozen shoulder." *Orthopaedics.* 2003 ; 3 : 83-84.
3. **Binder AI, Bulgen DY, Hazleman BL, Roberts S.** Frozen shoulder : a long-term prospective study. *Ann Rheum Dis.* 1984 ; 43 : 361-364.
4. **Dawson J, Fitzpatrick R, Carr A.** Questionnaire on the perceptions of patients about shoulder surgery. *J Bone Joint Surg Br.* 1996 ; 78 : 593-600.
5. **Diercks RL, Stevens M.** Gentle thawing of the frozen shoulder : a prospective study of supervised neglect versus intensive physical therapy in seventy-seven patients with frozen shoulder syndrome followed up for two years. *J Shoulder Elbow Surg.* 2004 ; 13 : 499-502.
6. **Dodenhoff RM, Levy O, Wilson A, Copeland SA.** Manipulation under anesthesia for primary frozen shoulder : effect on early recovery and return to activity. *J Shoulder Elbow Surg.* 2000 ; 9 : 23-26.
7. **Farrell CM, Sperling JW, Cofield RH.** Manipulation for frozen shoulder : long-term results. *J Shoulder Elbow Surg.* 2005 ; 14 : 480-484.
8. **Grant JA, Schroeder N, Miller BS, Carpenter JE.** Comparison of manipulation and arthroscopic capsular release for adhesive capsulitis : a systematic review. *J Shoulder Elbow Surg.* 2013 ; 22 : 1135-1145.
9. **Griggs SM, Ahn A, Green A.** Idiopathic adhesive capsulitis. A prospective functional outcome study of nonoperative treatment. *J Bone Joint Surg Am.* 2000 ; 82 : 1398-1407.
10. **Guyver PM, Bruce DJ, Rees JL.** Frozen shoulder - A stiff problem that requires a flexible approach. *Maturitas.* 2014 ; 78 : 11-16.
11. **Harris G, Bou-Haidar P, Harris C.** Adhesive capsulitis : review of imaging and treatment. *J Med Imaging Radiat Oncol.* 2013 ; 57 : 633-643.
12. **Kivimäki J, Pohjolainen T, Malmivaara A, Kannisto M, Guillaume J et al.** Manipulation under anesthesia with home exercises versus home exercises alone in the treatment of frozen shoulder : a randomized, controlled trial with 125 patients. *J Shoulder Elbow Surg.* 2007 ; 16 : 722-726.
13. **Loew M, Heichel TO, Lehner B.** Intraarticular lesions in primary frozen shoulder after manipulation under general anesthesia. *J Shoulder Elbow Surg.* 2005 ; 14 : 16-21.
14. **Maund E, Craig D, Suekarran S, Neilson AR, Wright K et al.** Management of frozen shoulder : a systematic review and cost-effectiveness analysis. *Health Technol Assess.* 2012 ; 16 : 1-264.
15. **Ozaki J, Nakagawa Y, Sakurai G, Tamai S.** Recalcitrant chronic adhesive capsulitis of the shoulder. Role of contracture of the coracohumeral ligament and rotator interval in pathogenesis and treatment. *J Bone Joint Surg .Am* 1989 ; 71 : 1511-1515.
16. **Reeves B.** The natural history of the frozen shoulder syndrome. *Scand J Rheumatol.* 1975 ; 4 : 193-196.

17. **Roach KE, Budiman-Mak E, Songsiridej N, Lertratanakul Y.** Development of a shoulder pain and disability index. *Arthritis Care Res.* 1991 ; 4 : 143-149.
18. **Rookmoneea M, Dennis L, Brealey S, Rangan A, White B et al.** The effectiveness of interventions in the management of patients with primary frozen shoulder. *J Bone Joint Surg Br.* 2010 ; 92 : 1267-1272.
19. **Shaffer B, Tibone JE, Kerlan RK.** Frozen shoulder. A long-term follow-up. *J Bone Joint Surg Am.* 1992 ; 74 : 738-746.
20. **Vastamäki H, Vastamäki M.** Motion and pain relief remain 23 years after manipulation under anesthesia for frozen shoulder. *Clin Orthop Relat Res.* 2013 ; 471 : 1245-1250.
21. **Vastamäki H, Varjonen L, Vastamäki M.** Optimal time for manipulation of frozen shoulder may be between 6 and 9 months. *Scand J Surg.* 2015 ; 104 : 260-266.
22. **Wang K, Ho V, Hunter-Smith DJ, Beh PS, Smith KM et al.** Risk factors in idiopathic adhesive capsulitis : a case control study. *J Shoulder Elbow Surg.* 2013 ; 22 : e24-9.
23. **White LM, Kandel R.** Osteoid-producing tumors of bone. *Semin Musculoskelet Radiol.* 2000 ; 4 : 25-43.
24. **van der Windt DA, Koes BW, de Jong BA, Bouter LM.** Shoulder disorders in general practice : incidence, patient characteristics, and management. *Ann Rheum Dis.* 1995 ; 54 : 959-964.