



Gouty flexor tenosynovitis mimicking infection : a case report emphasising the value of ultrasound in diagnosis

Nadim ASLAM, Steven LO, Ian McNAB

From Nuffield Orthopaedic Centre, Oxford, U.K.

Tenosynovitis of the flexor tendons of the hand is a rare manifestation of gout. We present an unusual case of gouty tenosynovitis mimicking infection. The role of ultrasound in the management of this condition is emphasised.

INTRODUCTION

Gout can present with both articular and extra-articular manifestations. Well recognised and frequently encountered manifestations of gout include joint disease, subcutaneous tophi and renal dysfunction. The presentation of gout in the hand includes arthritis, skin ulceration, sinus formation, tenosynovitis and infection (3). Flexor tenosynovitis is an uncommon manifestation of gout in the hand, and has been rarely reported in the literature (3,4,5,6,7). Here we present a rare case of gouty flexor tenosynovitis of the index finger, which was initially thought to be infection. The case is unusual in both the young age of the female patient, and the absence of a history of gout. Ultrasound guided aspiration allowed a diagnosis to be made and non operative management.

CASE REPORT

A 44-year-old right hand dominant female administrator, presented as an emergency with a swollen painful left index finger. She had suffered a small puncture wound to the volar aspect of the

proximal interphalangeal joint of the index finger six months previously. Significant past medical history included successfully treated Hodgkin's lymphoma 13 years previously. On examination, the scar site had completely healed, and the finger was tender, erythematous and swollen, with decreased range of movement (fig 1a,b). Her urate level was within normal limits at 260 micromol/l (reference range, 150-390 micromol/l). Inflammatory parameters were also normal with a CRP < 8mg/l and erythrocyte sedimentation rate at 11mm/hr.

Examination was consistent with a diagnosis of infection, and she underwent urgent ultrasound examination. High resolution ultrasound of the index finger revealed tenosynovitis with loculated fluid in flexor sheath from A1 pulley to distal phalanx, with a normal flexor tendon. No joint synovitis was noted. A turbid looking fluid was aspirated and sent for culture and microscopy.

Microscopy revealed uric acid crystals and no organisms ; she was therefore commenced on

■ Nadim Aslam, MD, FRCS Specialist Registrar

■ Steven Lo, MD, Senior House Officer

■ Ian McNab, MD, Consultant Hand Surgeon

Nuffield Orthopaedic Centre, Windmill Road, Headington, Oxford, OX3 7LD, U.K.

Correspondence : Nadim Aslam, Compton Vectis, 49 Marlow Road, High Wycombe, Bucks, HP11 1TG, U.K.

E-mail : nadimaslam@hotmail.com

© 2004, Acta Orthopædica Belgica.

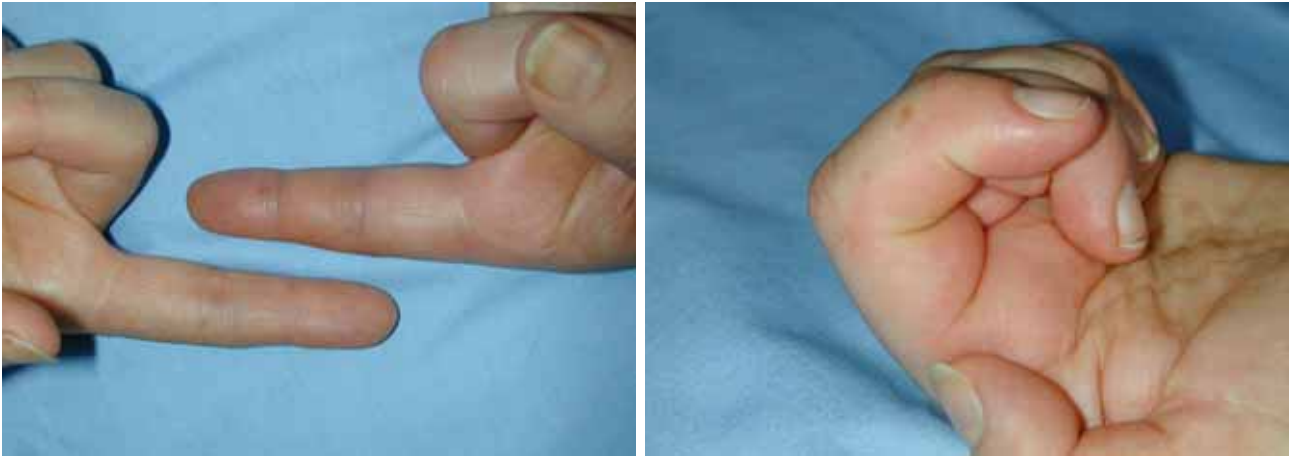


Fig. 1a,b. — Photographs showing the swollen digit with reduced range of motion on flexion.

colchicine treatment, to which she responded rapidly. Examination of the finger 24 hours later revealed marked improvement in appearance and range of movement, and it was decided at that stage to continue with medical management. Cultures were all negative. She was followed up by the hand clinic and by rheumatology, and she was subsequently started on a Cox 2 inhibitor anti-inflammatory. Latest follow up at 3 months revealed a painfree fully functional finger.

DISCUSSION

Gouty involvement of the flexor tendons is an unusual site for deposition of the sodium urate crystals that characterise this disease. It is more

commonly associated with articular, tendons other than flexor tendons, synovial, nerve and renal deposition (8). Flexor tendon tenosynovitis is a rare manifestation of gout, and has been recently described in a case series of three, relatively older men who had longstanding histories of gout ranging from 7 to 30 years (7). Magnetic Resonance Imaging was used as an adjunct to diagnosis. The authors also commented that confirmatory diagnosis was only possible at the time of surgery, when specimens were sent for uric acid crystal analysis.

All previously reported cases except for one, had a past history of gout and all were treated with surgical intervention (table I). There has been one previous reported case of gouty tenosynovitis simulating infection which was managed surgically (1).

Table I. — Cases of gouty flexor tenosynovitis in the digits.

Reference	Age	Sex	History of Gout	Investigations	Management
Weniger	54	M	Yes	Plain XR	Debridement of tophus and repair of underlying FDP tendon in little finger
Weniger	74	M	Yes	Plain XR + MRI	Debridement of tophi and tenosynovectomy to specified index finger
Weniger	72	M	Yes	Not specified	Debridement of tophi and partial tenosynovectomy
Weinzweig	65	F	Yes	Plain radiograph	Excision of tophi left hand and carpal tunnel
Moore	84	F	Yes	Not specified	Tenosynovectomy of ring finger Extensor
Moore	52	M	No	Raised urate	Hemisublimis resection, tenolysis
Abrahamsson	74	M	Yes	ESR 38	Excision of tophi and tenosynovectomy of middle finger

Our case highlights three essential points. Firstly, gouty tenosynovitis can occur in the absence of a long history of gout. Secondly, high-resolution ultrasound offers an alternative form of diagnostic imaging to MRI, in that pre-operative or diagnostic aspiration can be performed. The role of high resolution ultrasound in peritendinous lesions has been recently evaluated (2).

Finally, the presence of both infection and gout within the flexor tendon sheaths of the hand requires a rapid diagnosis and appropriate treatment, but the treatment modalities can be different. The treatment for a flexor tendon sheath infection will include a surgical washout of the tendon sheath, however surgery may not always be required for the treatment of gout, and is not without risks. We have shown that if a preoperative diagnosis of gouty tenosynovitis can be made, by using the minimally invasive technique of ultrasound guided aspiration, then the patient can be safely and successfully treated medically. If the facilities and technical expertise are available to allow this technique to be used, then it may eliminate the need for surgical intervention.

REFERENCES

1. **Abrahamsson SO.** Gouty tenosynovitis simulating an infection. A case report. *Acta Orthop Scand* 1987 ; 58 : 282-283.
2. **Ho CF, Chiou HJ, Chou YH, Chang CY.** Peritendinous lesions: the role of high-resolution ultrasonography. *Clin Imaging* 2003 ; 27 : 239-250.
3. **Moore JR, Weiland AJ.** Gouty tenosynovitis in the hand. *J Hand Surg* 1985 ; 10-B : 291-295.
4. **Primm DD Jnr, Allen JR.** Gouty involvement of a flexor tendon in the hand. *J Hand Surgery* 1983 ; 8 : 863-865.
5. **Schuind FA, Clermont B, Stallenberg B, Rummeling M, Pasteels JL.** Gouty involvement of flexor tendons. *Chir Main* 2003 ; 22 : 46-50.
6. **Weinzeig J, Fletcher JW, Linburg RM.** Flexor tenosynovitis and median nerve compression caused by gout in a patient with rheumatoid arthritis. *Plast Reconstr Surg* 2000 ; 106 : 1570-1572.
7. **Weniger FT, Davison SP, Risin M, Salyapongse AN, Manders RK.** Gouty flexor tenosynovitis of the digits: report of three cases. *J Hand Surg* 2003 ; 28-A : 669-672.
8. **Wortman RL.** Gout and other disorders of purine metabolism. In : Fauci AS, Braunwald E, Isselbacher KJ, Wilson JD, Martin JB, Kasper DL *et al*, eds. *Harrison's Principles of Internal Medicine*. 14th ed. New York : McGraw-Hill Book Co., 1998 : pp 2163-2165.