



## Importance of assistant intra-operative medial distraction technique for intraarticular calcaneus fractures

Tao YU, Yunfeng YANG, Bing LI, Sanjaya SAH, Kai CHEN, Guangrong YU

From the Department of Orthopaedics, Tongji Hospital, Tongji University School of Medicine, China

To report the clinical efficacy of open reduction and internal fixation (ORIF) assisted by medial distraction for intra-articular calcaneus fractures. From September 2010 to November 2013, 151 patients with intra-articular calcaneus fractures were treated at our department by ORIF. They were 95 men and 56 women, 18 to 69 years of age. According to the Sanders classification, there were 24 cases of type II, 76 ones of type III and 51 ones of type IV. Medial distraction was used in 27 cases but not in 124 ones. The 2 groups were compatible, without significant differences in preoperative general data ( $p > 0.05$ ). The two groups were compared in intraoperative indexes and follow-up radiological data. The mean duration of surgery in the distraction group ( $71.6 \pm 18.3$  minutes) was significantly shorter than that in the non-distraction group ( $80.4 \pm 20.7$  minutes), and the varus angle in the distraction group ( $5.3^\circ \pm 4.4^\circ$ ) was significantly smaller than that in the non-distraction group ( $10.6^\circ \pm 6.5^\circ$ ) ( $p < 0.05$ ). There were no significant differences between the 2 groups in intraoperative bleeding, postoperative drainage, hospital stay, bone union time, follow-up duration, American Orthopaedic Foot & Ankle Society score, Böhler angle, Gissane angle, calcaneal axis, calcaneal horizontal length, tuberosity height, hillock calcaneal height, calcaneal width, or talar inclination angle ( $p > 0.05$ ). ORIF assisted by medial distraction technique is effective for intra-articular calcaneal fractures, especially in correcting the calcaneal axis.

**Keywords** : calcaneus ; fractures ; bone ; fracture fixation ; internal ; medial distraction.

### INTRODUCTION

The calcaneus is the largest bone in the foot, which plays a very important role in the weight-bearing and walking. It accounts for about 60%-70% of the tarsal fractures (3). The intraarticular fracture constitutes approximately 75% of all calcaneus fractures which are most common in tarsal injuries. Calcaneal fractures are a challenging clinical problem due to the complex anatomy of the os calcis and special condition of local soft tissue (8). The treatment of these injuries remains controversial. In our clinical work, we found that some patients still could not adapt previous work three years after injury, and some still remained dysfunction even 5 years after.

Open reduction and internal fixation (ORIF) through lateral "L" incision is a popular method currently because of its advantage for exposure and reduction (6). However there are still some patients with inadequate correction of alignment

- Tao Yu.
- Yunfeng Yang.
- Bing Li.
- Sanjaya Sah.
- Kai Chen.
- Guangrong Yu.

Department of Orthopaedics, Tongji Hospital, Tongji University School of Medicine, China.

Correspondence : Yunfeng Yang, Department of Orthopaedics, Tongji Hospital, Tongji University School of Medicine, China.

E-mail : yangyunfeng1051@126.com

© 2019, Acta Orthopaedica Belgica.

No benefits or funds were received in support of this study. The authors report no conflict of interests.

Acta Orthopædica Belgica, Vol. 85 - 1 - 2019

and length of the calcaneus postoperatively which is a common kind of complication in addition to incision infection (10,12,13). The pain and poor outcome is often due to an inadequate reduction and fixation. Post-operative persistent varus deformity is a common cause of postoperative pain, movement disorders and traumatic arthritis. The main reason for calcaneal fracture malunion may be intraoperative malreduction (10). In order to further improve the intraoperative reduction and explore new ways to avoid postoperative varus deformity, we treated some calcaneal fractures using ORIF with intraoperative medial distraction which can make the reduction better and prevent varus deformity. From September 2010 to November 2013, 151 patients of intra-articular calcaneus fractures were treated with or without MDT (medial distraction technique). We found that the mean duration of surgery in the distraction group ( $71.6 \pm 18.3$  minutes) was significantly shorter than that in the non-distraction group ( $80.4 \pm 20.7$  minutes), and the varus angle in the distraction group ( $5.3^\circ \pm 4.4^\circ$ ) was significantly smaller than that in the non-distraction group ( $10.6^\circ \pm 6.5^\circ$ ) ( $p < 0.05$ ).

### PATIENTS AND METHODS

Inclusion criteria: 1. intraarticular fracture; 2. varus deformity before surgery; 3. ORIF with lateral "L" incision. Exclusion criteria: 1. comminuted fracture of calcaneal tuberosity.

All the cases who met the above criteria were included in the study from September 2010 to November 2013. There were 151 patients retrospectively divided to MDT group (27 cases) and non-MDT group (124 cases).

There were 18 males and 9 females with an average age of 48.5 years (range, 23-69 years) in MDT group. They included 3 cases of Sanders type II, 11 of III and 13 of IV. There were 77 males and 47 females with an average age of 39.5 years (range, 18 - 67 years) in non-MDT group. They included 21 cases of Sanders type II, 65 of III and 38 of IV. There was no open fracture in this study. There was no statistically significant difference of general information between the two groups ( $P > 0.05$ , Table I).

The patient was placed in a side position. A lateral expanded "L"-shaped incision was made, about 15cm, and then skin and subcutaneous tissue were cut directly to lateral wall of the calcaneus. Caution was taken to protect the sural nerve and to retain peroneal tendon intact. The flap was separated close to the lateral wall of the calcaneus up to the subtalar joint and then calcaneocuboid and subtalar joints were exposed. Comminuted fracture, collapse of the posterior articular surface, bulging outward of the lateral wall and heel varus were found. A 2.5 mm Kirschner wire was drilled into calcaneus tuberosity and talus respectively from lateral to medial through the incision. Tibial distraction device (Figure 1) was embedded by Kirschner and distraction was performed at the medial side. Long axis of the calcaneus and varus were corrected under intra-operative C-arm fluoroscopy by distraction. Next, the lateral wall of the calcaneus was opened and articular fragments were lifted up by scissors. Then the lateral wall and calcaneal width were restored, temporarily fixed with Kirschner wire. Plate and screws were placed at the lateral wall after satisfactory reduction was seen in C-arm fluoroscopy. Finally location of plate and length of screws were confirmed appropriate with C-arm.

Non-MDT group: it was the same with MDT group except without medial distraction technique. The length and varus was corrected by distraction with big towel forceps.

No weight bearing motion was started 2-3 days after surgery; progressive functional training

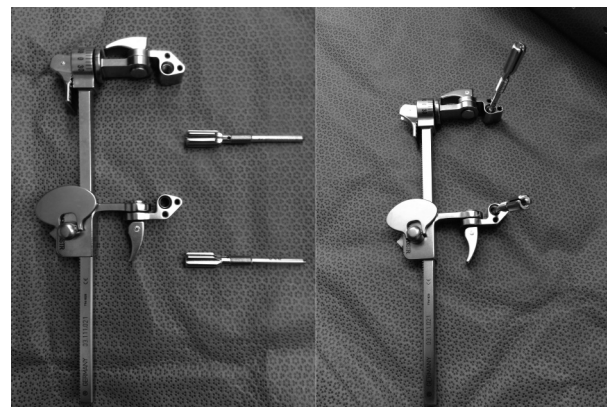


Fig. 1. — Medial distraction device

Table 1 — Clinical outcomes for volar and dorsal wrist ganglion

	Volar wrist ganglion (n=16)	Dorsal wrist ganglion (n=26)	P Value
Age	42 ( $\pm$ 16)	33 ( $\pm$ 12)	0.05
Follow-up period (months)	19 ( $\pm$ 2)	22 ( $\pm$ 7)	0.12
Wrist flexion pre-op	75 ( $\pm$ 12)	74 ( $\pm$ 18)	0.91
Wrist flexion post-op	77 ( $\pm$ 12)	76 ( $\pm$ 12)	0.89
Wrist extension pre-op	82 ( $\pm$ 10)	75 ( $\pm$ 16)	0.28
Wrist extension post-op	83 ( $\pm$ 10)	82 ( $\pm$ 10)	0.66
Grip strength (ratio of normal side) pre-op	0.99 ( $\pm$ 0.1)	0.95 ( $\pm$ 0.2)	0.61
Grip strength (ratio of normal side) post-op	1.00 ( $\pm$ 0.1)	0.97 ( $\pm$ 0.2)	0.7
Hand20 score pre-op	17 ( $\pm$ 14)	24 ( $\pm$ 13)	0.12
Hand20 score post-op	6 ( $\pm$ 7)	8 ( $\pm$ 12)	0.61
Pain score pre-op	3.2 ( $\pm$ 2)	4.6 ( $\pm$ 2)	0.1
Pain score post-op	1.0 ( $\pm$ 1.5)	1.2 ( $\pm$ 1.6)	0.76
Recurrence number (%)	0 (0%)	6 (23%)	< .05

Data are expressed as mean ( $\pm$  SD) except for recurrence

(partial weight bearing) was performed 1-2 weeks postoperatively with a walker boot. The walker boot was removed and start full weight-bearing allowed when bone union was seen at radiographs.

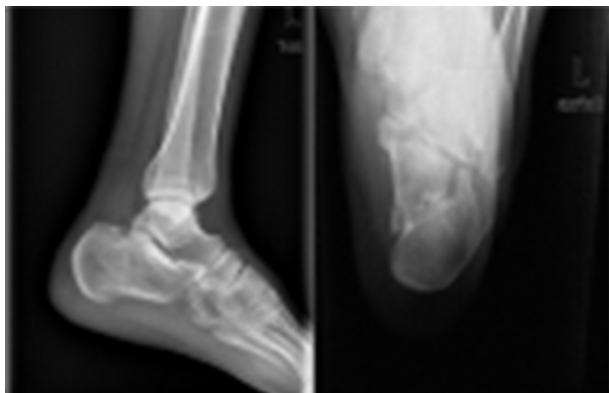
The patients were followed up 2 weeks, 6 weeks, 12 weeks after surgery and every three months after bone union. They were evaluated by lateral, axial radiographs and contralateral comparison. The AOFAS (American Orthopaedic Foot & Ankle Society) ankle-hindfoot score was used to make an assessment of the function. Surgical duration (5), intraoperative bleeding, postoperative drainage, hospital stay, bone union time, follow-up duration, complications, AOFAS score, Böhler angle, Gissane angle, calcaneal axis, calcaneal horizontal length, tuberosity height, hillock calcaneal height, calcaneal width, or talar inclination angle, varus angle were measured.

SPSS 14.0 statistical software was used. Shapiro-Wilk test was used first to determine whether the data were normally distributed. All measurement data were proved normally distributed and homogeneity of variance. Measurement data between two groups were compared with two independent samples t-test and count data were compared using the X<sup>2</sup>-test. P < 0.05 was considered statistically significant.

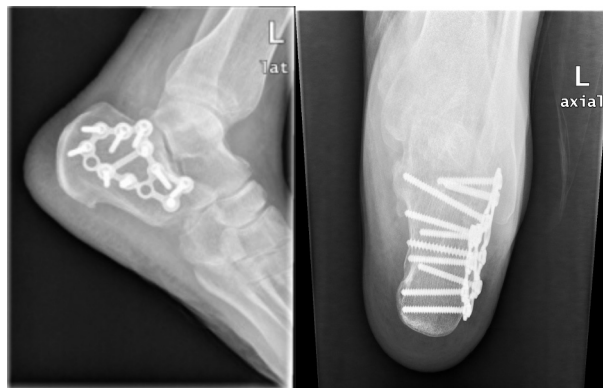## RESULTS

The mean duration of surgery was 71.6 minutes (range, 65 - 93 minutes) and mean hospital stay was 15.1 days (range, 5 - 22 days) in MDT group. There was one drop-out in the MDT group and 15 drop outs in the non MDT group.

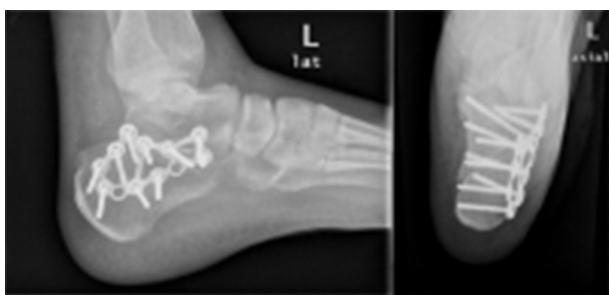The 26 patients from MDT group were followed up for 18.3 months (range, 13-26 months) in



**Fig. 2.** - Displaced fracture with varus and shortening deformity preoperatively



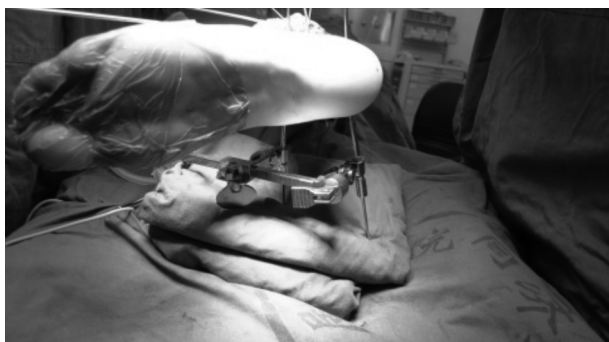**Fig. 5.** — The axis was satisfactory and internal fixation was in position 15 months after surgery



**Fig. 3.** — Postoperative X-ray showed reduction of articular surface and correction of varus and shortening deformity

1 year after surgery with excellent and good rate of 80.8% . A typical case is shown in figure 2.

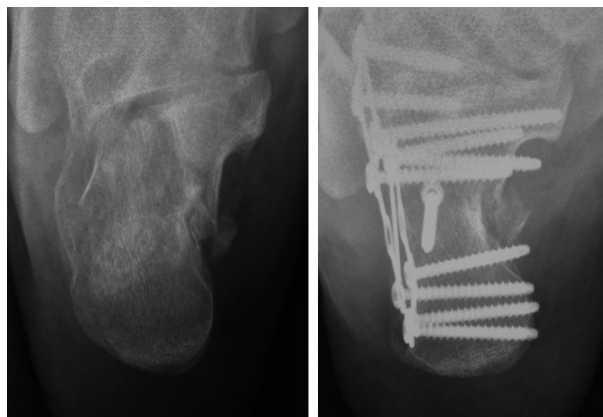
The mean duration of surgery was 80.4 minutes (range, 69 - 101 minutes) and mean hospital stay was 16.1 days (range, 6 - 24 days) in non-MDT group. The 112 patients from non-MDT group were followed up for 20.1 months in average (ranged from 15 to 36 months). All of the cases healed well, and the mean time of bone union was 11.1 weeks (range, 8 - 18 weeks). Complications were observed in 4 patients with painful fixation and 6 patients with delayed healing of incisions. The mean AOFAS score was 85.2 at 1 year after surgery. Typical case is shown in picture 6.



**Fig. 4.** — Intra-operative distraction

There were no significant differences between the 2 groups concerning intraoperative bleeding, postoperative drainage, hospital stay, bone union

average. All of the cases with MDT healed well, and the mean time of bone union was 10.2 weeks (range, 8 - 17 weeks). Complications were observed in 1 patient with painful fixation. None of the patients experienced a nonunion or an adverse event related to the neurovascular structures in MDT group. The mean AOFAS score was 87.4 at



**Fig. 6.** — Case from non-MDT group: residual varus deformity at 1 year follow-up



Table II. — Operative time, intraoperative blood loss, postoperative drainage, hospital stay, bone union time, follow-up duration, AOFAS score between two groups

	Cases	Operative time (min)	Intraoperative blood loss (ml)	Postoperative drainage (ml)	hospital stay (day)	bone union time (mon)	follow-up duration (week)	AOFAS score
MDT	26	71.6±18.3	25.7±4.7	248.4±27.2	15.1±4.9	10.2±2.1	18.3±5.9	87.4±13.0
Non-MDT	112	80.4±20.7	28.1±6.4	259.8±30.5	16.1±5.3	11.1±2.5	20.1±6.4	85.2±14.7
t	-	2.041	1.841	1.761	0.879	1.700	1.310	0.702
p	-	0.043	0.068	0.080	0.381	0.091	0.192	0.484

time, follow-up duration, AOFAS score, Böhler angle, Gissane angle, calcaneal axis, calcaneal horizontal length, tuberosity height, hillock calcaneal height, calcaneal width, or talar inclination angle ( $p > 0.05$ , table 2, 3). The mean duration of surgery in the distraction group was significantly shorter than that in the non-distraction group, and the varus angle in the distraction group was significantly smaller than that in the non-distraction group ( $p < 0.05$ , table II, III).

## DISCUSSION

The intra-articular calcaneal fracture is one of the most severe fractures. Its treatment remains

Table III. — Imaging evaluation between two groups

	MDT	Non-MDT	t	p
Böhler angle (°)	25.9±6.8	25.2±7.3	0.457	0.648
Gissane angle (°)	119.5±8.1	121.4±9.0	1.012	0.311
Axis length (mm)	56.1±7.1	53.6±8.2	1.470	0.144
Horizontal length (mm)	77.7±7.3	75.2±6.9	1.688	0.094
Tuberosity height (mm)	48.2±3.8	48.7±4.6	0.527	0.599
Hillock height (mm)	45.0±4.7	44.8±5.2	0.184	0.854
Width (mm)	33.7±2.9	34.5±3.8	1.548	0.124
Talar tilt angle (°)	13.1±5.3	12.9±4.7	0.196	0.845
Calcaneal varus angle (°)	5.3±4.4	10.6±6.5	4.046	0.000

controversial. Irregular anatomical shape and complex biomechanical relationship among the tarsals bring a lot of difficulties to therapy. There are some limitations: inadequate exposure, difficulty to get good intraoperative axial radiograph, difficulty to reduce medial intercalation wall through lateral incision. These make it hard to correct heel varus and shortening. This eventually leads to long-term state of non-physiological biomechanics. Residual varus deformity can severely affect hind foot function, and increases the risk of unhealthy lower limb alignment. Intraoperative inadequate reduction is a major risk factor of postoperative varus (10). The aim of our medial distraction is to further recover calcaneal shape and alignment, reduce unfavorable factors of intraoperative simple pulling, shorten operative time and improve surgical results. We found that the medial distraction technique could further assist reduction and improve results because it can effectively restore the alignment and length of the calcaneus, at the same time, it is helpful to reduce the articular surface. Then the calcaneal width is corrected through lateral incision and the calcaneal shape is recovered maximally, avoiding the incidence of postoperative varus deformity.

There is mesh cancellous bone inside calcaneus with a thin layer of cortical bone surrounding the outside. Bone is less or even absent in the center portion (neutral triangle) of calcaneus body beneath the posterior articular surface, while trabecular aggregation is at its front and rear the loading positions. Calcaneal fractures are often caused by falling injury resulting in central compression of the posterior articular surface and bulging of lateral

wall, which often leads to heel varus deformity. It is the most common pathologic deformity of calcaneal fractures. The goal of ORIF is to obtain anatomic reduction and achieve recovery of alignment, height, length and width. The axis is most important among them. Reduction with Kirschner and clamp alone is difficult and takes a long time, which is likely to cause soft tissue cutting, infections and other complications. For varus deformity, we designed a medial surgical approach distraction, making it easier to get recovery of axis. In addition, after the exposure of posterior articular fragments through lateral incision, the collapse of the articular surface is often necessary to be reduced with upward rotation; sometimes there are flake fragments which require separate reduction. At this time, strong traction is important to obtain exposure of articular surface and recovery of axis because of the limitations of approach. Temporary intraoperative traction with clamp is often insufficient. Therefore, we use two 2.5 mm Kirschner wires to drill in the talus and calcaneus tuberosity and embed the tibial distraction device from the medial side so that satisfactory articular exposure and correction of calcaneus varus deformity are achieved under its traction.

The advantages are as follows: 1. medial distraction makes it more convenient to correct heel varus and lateral expansion deformity, and then to restore axis line; As in this study, Bohler angle, Gissane angle, calcaneal height are about the same between two groups without statistical difference whereas varus angle of MDT group was significantly less than control group, and the difference was statistically significant. Typical case of non-MDT group is depicted in figure 5; 2. distraction is more effective for traction than the clamp, which can make us deal with the articular surface unhurriedly. Application of clamp may lead to infection, or even cutting injury; 3. it does not affect the lateral operation and can provide a better exposure, thereby it shortens the operation time. The disadvantages are: 1. medial trauma and the risk of wound complications increases due to two nail holes; 2. drilling Kirschner may impact the blood supply of talus so that there is a potential risk of avascular necrosis.

In recent years, "balloon" technique, minimally invasive technique as well as Ilizarov technique have been applied in calcaneal fractures which provide us some alternative options and new ideas of development direction. But the malreduction of axis and articular surface is still difficult to effectively solve by these methods. While the medial distraction is an additional assistive technique on the basis of ORIF through lateral classic "L"-shaped incision which is good at control of both alignment and articular surface (2,4,11).

The main indication of this technique is Sanders II, III, IV type fracture with varus and shortening deformity. In the study, there was one case of postoperative pain and the pain disappeared after implant removal. All of the cases healed well and the average time of bone union was 10.15 weeks (range, 8 - 17 weeks). The mean AOFAS ankle-hindfoot score was 87.38 at 1 year after surgery with excellent and good rate of 80.8%. It is about the same with control group (85.23, 81.5%) and it is comparable to a previous report with 83 points (9), excellent and good rate of 72% at follow-up using three points distraction and minimally invasive treatment. Massari et al reported that AOFAS excellent and good rate was 70.6% and complication incidence was 23% using isolate ORIF through lateral "L"-shaped incision (7). It is a little better in this study with 80.8% and 7.7% respectively which indicates that the clinical efficacy of this technique is good.

Intraoperative notes: 1. distraction Kirschner wire is 2.5 mm to prevent cutting; 2. anterior Kirschner drilling point should be chosen at the area with good bone mass of talar neck or head to avoid loosening; posterior point is at calcaneal tubercle; the K-wire can be drilled angulately to the calcaneus in order to facilitate the correction of heel varus; 3. K-wire should be drilled with caution to avoid injury if medial important structures; 4. a little valgus and over-distraction should be seen at intraoperative fluoroscopy after reduction to compensate the postoperative loss; it is out of question that restoration of axis, height, length and width should also be confirmed by fluoroscopy. 5. the degree of distraction can be decided according to the preoperative plan or intra-operative contralateral

comparison; if the subtalar joint is tightened by over-distraction to restrain reduction of articular surface, the distraction can be released a little and regain distraction after satisfactory reduction; 6. a temporary fixation can be performed with K-wires and then plate and screws are placed. The surgeon should angle the ST (sustentaculum tali) lag screw approximately 30° from posteriorly and laterally to anteriorly and medially to land centrally in the ST (1). A mini C-arm is helpful to take a better view of the calcaneus axis because it is usually difficult to dorsiflex the ankle adequately when taking a intraoperative fluoroscopy.

This study was a retrospective analysis and the number of cases was relatively small so that there was no classified analysis as well as relationship analysis between union time and age, surgical options, complications. In addition, it is not a prospective randomized study; furthermore, we did not use a sensitivity analysis to test the results, so it is unable to evaluate other factors that may have an impact on the patient's response to surgery such as comorbidity, smoking and so on. However, we believe that the technique of medial distraction is an effective treatment for intra-articular calcaneus fractures in spite of these disadvantages. Further study is to perform a more cases and a randomized controlled study with/without medial distraction in our institution.

## REFERENCES

1. **Bussewitz BW, Hyer CF.** Screw placement relative to the calcaneal fracture constant fragment: an anatomic study. *J Foot Ankle Surg* 2015 ; 54: 392-4.
2. **Cao L, Weng W, Song S, et al.** Surgical treatment of calcaneal fractures of Sanders type II and III by a minimally invasive technique using a locking plate. *J Foot Ankle Surg* 2015 ; 54: 76-81.
3. **Ding L, He Z, Xiao H, et al.** Risk factors for postoperative wound complications of calcaneal fractures following plate fixation. *Foot Ankle Int* 2013 ; 34: 1238-44.
4. **Faroug R, Stirling P, Ali F.** A novel technique for closed reduction and fixation of paediatric calcaneal fracture dislocation injuries. *Case Rep Orthop* 2013 ; 928938.
5. **Kitaoka HB, Alexander IJ, Adelaar RS, et al.** Clinical rating systems for the ankle-hindfoot, midfoot, hallux, and lesser toes. *Foot Ankle Int* 1994 ; 15: 349-53.
6. **Kolodziejski P, Czarnocki L, Wojdasiewicz P, et al.** Intraarticular fractures of calcaneus - current concepts of treatment. *Pol Orthop Traumatol* 2014 ; 79: 102-11.
7. **Massari L, Ferrante R, Massini G, et al.** A new technique for treatment of calcaneal fractures with a multihole plate: **indications and results.** *Foot Ankle Surg* 1999 ; 5: 39-45.
8. **Potter MQ, Nunley JA.** Long-term functional outcomes after operative treatment for intra-articular fractures of the calcaneus. *J Bone Joint Surg Am* 2009 ; 91: 1854-60.
9. **Schepers T, Schipper IB, Vogels LM, et al.** Percutaneous treatment of displaced intra-articular calcaneal fractures. *J Orthop Sci* 2007 ; 12: 22-7.
10. **Shi ZM, Mei GH, Zou J.** Varus malunion following surgery for intra-articular calcaneal fracture: Pearls and pitfalls. *Chin J Orthop Trauma* 2014 ; 16(12): 1028-32.
11. **Vittore D, Vicenti G, Caizzi G, et al.** Balloon-assisted reduction, pin fixation and tricalcium phosphate augmentation for calcaneal fracture. *Injury* 2014 ; 45 Suppl 6: S72-9.
12. **Yao Q, Zhu MH, Peng LB.** Wound complications after operative fixation of calcaneal fracture. *Chin J Orthop Trauma* 2015 ; 17: 757-60.
13. **Yu X, Pang QJ, Chen L, et al.** Postoperative complications after closed calcaneus fracture treated by open reduction and internal fixation: a review. *J Int Med Res* 2014 ; 42: 17-25.