



Results of the treatment of intracapsular femoral neck fractures with a new dynamic locking plate

Dominik GRUSZKA, Sven-Oliver DIETZ, Romy BRODT, Daniel WAGNER, Pol Maria ROMMENS, Raphael KUECHLE

*From the Department of Orthopaedics and Traumatology University,
Medical Center of Johannes Gutenberg University Mainz, Germany*

The purpose of this study was to evaluate the outcomes in patients with intracapsular femoral neck fractures treated with the novel Targon FN implant. Sixty two patients (mean age: 57 years) were included. The clinical and radiological results were investigated. Radiological and clinical follow-up (mean time: 21,2 months) was available for 51 patients; in 36 patients, Harris Hip Score (HHS) outcome data were additionally assessed. The overall complication rate was 8%. The median Harris Hip Score was 92 (range 30-100). The results of the Harris Hip Score were rated excellent or good in 26 (72%) patients and fair or poor in 10 (28%). The HHS was correlated significantly with age at trauma, time from admission to operation, preexisting cardiovascular risk factors and disease of the ipsilateral leg. The positive experience with Targon FN suggests that this implant is an advance in treatment of intracapsular femoral neck fractures with head-preserving surgery.

Keywords : femoral neck fracture ; dynamic locking plate ; telescopic screws ; Targon FN.

INTRODUCTION

There were 446.806 hip fractures in the European Union in 2010, constituting 18% of all fractures and accounting for the most common human fracture. Moreover, according to epidemiologic projections, its incidence will rise to 814.747 fractures by 2025, for an estimated increase of 32% over a 15-year

time period. The incidence of hip fractures in men was approximately half that noted in women, and the incidence of deaths directly resulting from hip fractures within the first year was 11 per 100.000 inhabitants aged older than 50 years. Considering the costs, there are substantial differences among countries, with the first-year cost of a hip fracture in the European Union equaling 13.816 euros (range from 1.826 to 25.117 euros) (11).

Hip fractures in elderly traumatized patients usually result from a low-energy trauma, and they substantially increase the risk of death or major morbidity. In young patients, these fractures occur after a direct high-energy blow to the trochanter or axial trauma to the femur. Complications following

-
- Dominik Gruszka, Consultant, Orthopaedic Surgeon.
 - Sven-Oliver Dietz, Consultant, Orthopaedic Surgeon.
 - Romy Brodt, Medical Student.
 - Daniel Wagner, Consultant, Orthopaedic Surgeon.
 - Pol Maria Rommens, Professor, Orthopaedic Surgeon.
 - Raphael Kuechle, Leading Consultant, Orthopaedic Surgeon.

*Department of Orthopaedics and Traumatology University
Medical Center of Johannes Gutenberg University, Langen-
beckstr. 1, D-55131 Mainz, Germany.*

Correspondence : Dominik Gruszka, MD ; Telephone: 0049
6131 172845 ; Fax number: 0049 6131 176687.

E-mail : dominik.gruszka@unimedizin-mainz.de

© 2017, Acta Orthopaedica Belgica.

*Disclosure of potential conflicts of interest: The authors
declare that they have no conflict of interest.*

surgical repair, including infection, chronic pain, dislocation, nonunion, avascular necrosis (AVN), and posttraumatic arthritic changes, can have debilitating and life-changing consequences for the patient. The rate of AVN has reached 16-23%, and that of nonunion has reached 8-19% after dislocated fractures (9,16,22).

A valid treatment option is femoral head-preserving closed or open reduction and internal fixation with screws or different plate systems. Alternatively, a replacement with a hemi- or a total hip prosthesis can be performed (20). Conservative treatment is reserved for rare cases because it incurs a high risk of complications. In the literature, the evidence for the different surgical methods has not been clear; however, in patients younger than 65 years or in relatively healthy, functioning older patients, femoral head-preserving surgery should be the goal (5,7,17,18,19). A systematic review of this subject including 19 trials (3,044 participants) found that internal fixation resulted in less blood loss and less risk of deep wound infection (15). However, the reoperation rate was significantly lower in patients undergoing primary arthroplasty. Differences in mortality or the regaining of previous residential status could not be identified. Due to the aforementioned considerations, the optimal treatment method has not been identified, and new devices are being introduced to the market.

The purpose of this study was to evaluate the preliminary clinical and radiological outcomes, as well as complications, in patients with femoral neck fractures treated with the novel Targon Femoral Neck (FN) implant.

PATIENTS AND METHODS

Between between January 2009 and December 2012, 86 patients with an intracapsular femur neck fracture were treated in our Level-1 trauma center with internal fixation. Sixty-two were treated with the novel Targon FN plate system (Braun/Aesculap AG, Tuttlingen, Germany) and the remaining cases with either a triple screw technique or a sliding hip screw. There were no exclusion criteria for this study. All patients included were skeletally mature and had sustained a femoral neck fracture

(AO 31 B2-B3, Garden I-IV). The data were obtained retrospectively from regular follow-up examinations.

Surgical technique and postoperative care

The Targon FN is technically a hybrid between cancellous lag screws and a sliding hip screw (SHS), providing complete rotational stability with controlled possible collapse of the femoral neck along the screws, hence preventing screw toggling within the femoral neck. The plate is fixed with two angle stable screws to the femur shaft. No extension treatment was performed before the operation. All of the reductions were performed in the supine position using an extension table. Open reduction was not required, and capsulotomy was not performed. Three or four telescopic screws were placed into the femoral neck, according to the surgeon's choice. Postoperatively, patients with non-displaced fractures (Garden types I and II) were instructed to touch their toes while weight-bearing for 6 weeks or with full weight-bearing in very light and fit patients. Those with displaced fractures (Garden types III and IV) were not allowed any weight-bearing for 6 weeks. All of the patients perioperatively received antithrombotic prophylaxis with low-molecular-weight heparin (mostly Dalteparin). The wound drain was removed between 24 and 48 h after surgery. All of the patients were asked to participate in a full-time 3 week rehabilitation after achieving full weight bearing.

Clinical and radiographic evaluations

Data such as the age at the time of injury, sex, cardiovascular risk factors (CRFs), mechanism of injury, time between admission and operation, day of surgery and the duration of the operation were obtained.

Radiological assessment was performed with conventional X-ray of the hip in apical and axial views, as well as intraoperative images. Fractures were classified according to Garden (6). The reduction was classified as neutral, valgus or varus. Screw numbers were noted, as well as screw

positions within the femoral head, which were classified as central, superior, posterior, inferior and anterior. During follow-up, healing was evaluated and standardized by means of conventional X-rays on two planes for normal and disturbed bone healing (delayed union, non-union, malunion, refracturing). MRI or CT scans were performed in cases in which conventional radiographs did not definitively exclude AVN or non-union.

The Harris Hip Score (HHS) (10) was obtained in patients who presented in our outpatient clinic for follow-up examinations. The HHS is a validated test to assess the results of hip surgery and to evaluate various hip disabilities. Subjective and objective clinical parameters are investigated in four categories (pain, function, range of motion and deformity). A maximum of 100 can be obtained, with higher scores representing better function. A total score of 90-100 was considered excellent, 80-90 was good, 70-80 was fair, and less than 70 was poor.

Statistics

The collected data were assessed with explorative statistical methods, and Spearman's correlation coefficient (ρ) was calculated for the factors possibly influencing outcomes, using IBM SPSS Statistics software, version 22 for Macintosh (IBM Corporation, Armonk, NY, USA).

RESULTS

We analyzed the preoperative and direct postoperative outcomes of 62 patients. Radiological and clinical results were available for 51 patients, and the complete follow-up data, including HHS scores, were available for 36 patients. These patients were examined on the basis of regular visits to our outpatient clinic with a mean length of follow-up of 21,2 months (SD 11,7, range 3-38).

The mean age of the 62 patients included was 56,6 (range 18-81, SD 14,8) years at the time of the trauma. There were 34 (56%) women and 28 (44%) men. Forty-three patients (69%) were younger than 65 years, and 19 (31%) were older than 65 years.

We found 15 (24%) patients with a Garden I fracture, 10 patients (16%) with Garden II, 22

(36%) with Garden III and 15 (24%) with Garden IV; hence, 60% were displaced fractures.

The median time from admission to surgery was 4,8 hours, ranging from 1,2 to 222,7 hours (n=62). Twenty-three patients (64%) treated within 6 hours attained a median HHS of 97 (range 41-100), whereas 13 patients (36%) operated on after 6 hours attained an HHS of 88 (range 30 to 96, Spearman's ρ -0,41, $p < 0,05$) (Fig. 1).

The median operation time was 96 (range 65-217) minutes, including time for closed reduction

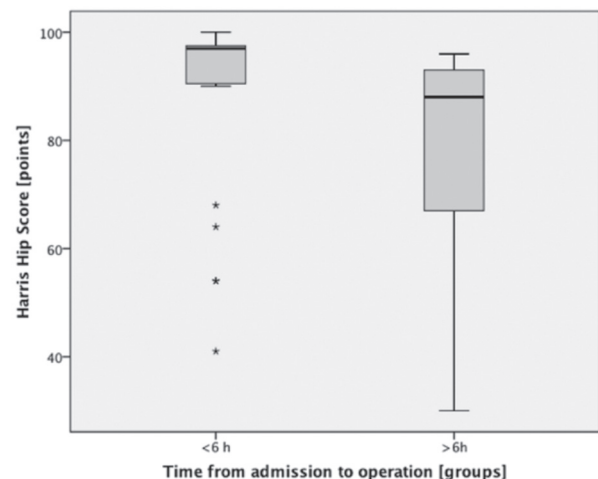


Fig. 1.— HHS according to time from admission to surgery

(n=62). The HHS in 30 patients (n=36) with an operating time of less than two hours was 92,5 (range 41-100), and 6 patients operated on for more than 2 hours attained an HHS of 73 (range 30-97). The length of surgery had no correlations with the outcome on the HHS (Spearman's $\rho=0,32$, $p < 0,01$). The mean time of hospitalization in the group of 62 patients was 9,2 days (SD 4,8; range 3-34). Forty-nine patients (79%) were discharged home, 2 (3%) to a rehabilitation facility, and 7 (11%) to a nursing home, and 4 (5%) were moved to other medical wards because of diseases not related to the fracture.

Four complications were observed in the followed-up collective (n=51): one secondary dislocation after a Garden III fracture; one aseptic femur head necrosis, which was converted into a total hip prosthesis in a Garden IV fracture; one loosening of the neck screws with consequent

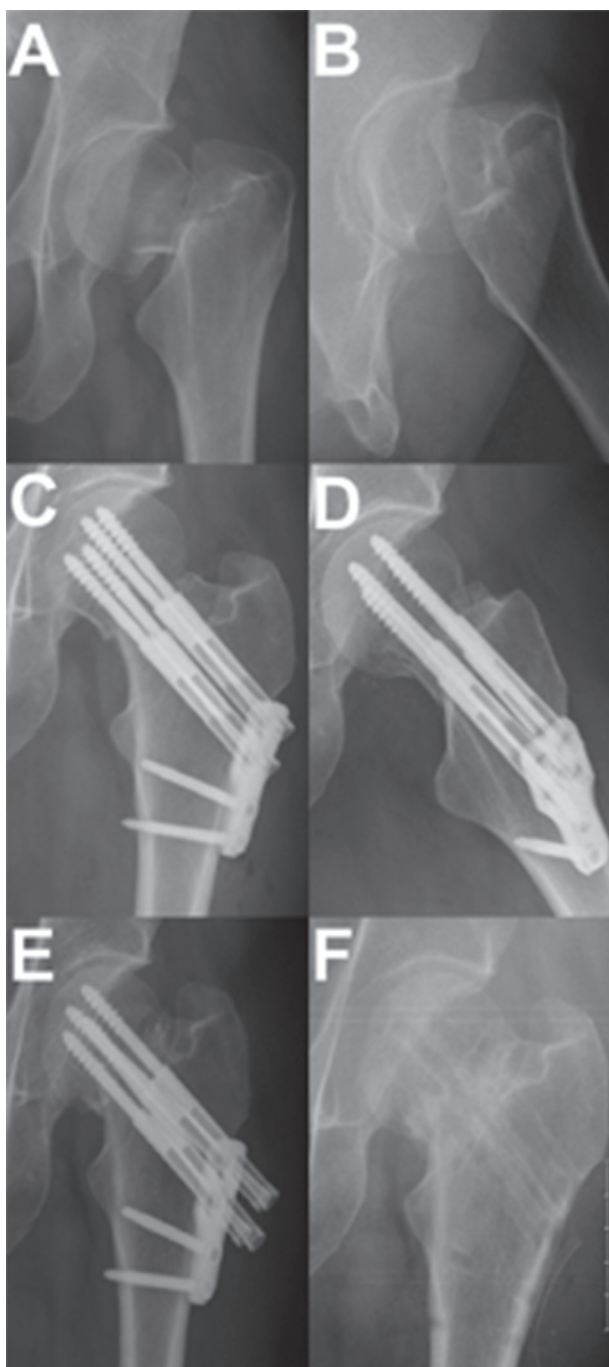

Fig. 2.— A 49-year-old female patient with Garden IV fracture. The time to surgery was less than 6 h, and the surgery time was 80 minutes. Already at two weeks, loosening of two telescoping screws could be seen. The remainder of the screws were loosened after 5 months. The metal was removed after 7 months. The fracture healed in time and full weight-bearing was possible. a, b – ap and axial views at the time of admission, c, d – ap and axial views postoperatively, e – ap view at 4 months of follow-up, f – ap view after metal removal

impaction of the fracture in a Garden IV fracture (Fig. 2); and one postoperative hematoma in a Garden II fracture, which was revised operatively.

The HHS of 36 patients presented a median of 92 (range 30-100; mean 83,2, SD 20,9) points. The analysis of HHS in correlation with different factors is presented in the Table 1. Among these patients,

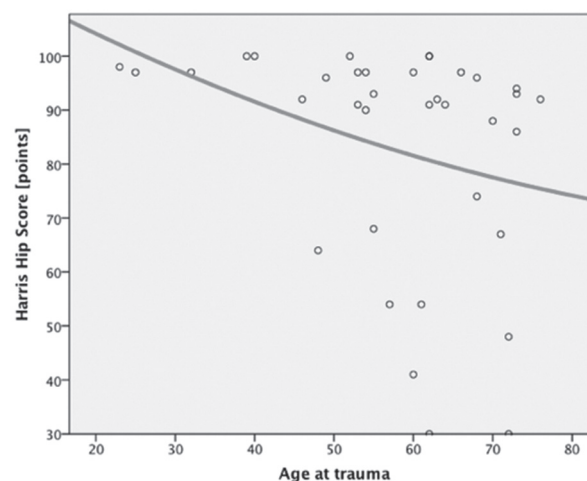


Fig. 3.— HHS score correlation with the age of the patients (n=36)

24 achieved an excellent result (90-100 points; 67%), 2 a good result (80-89 points; 5%), one a fair result (70-79 points; 3%), and 9 a poor (under 70 points; 25%) result.

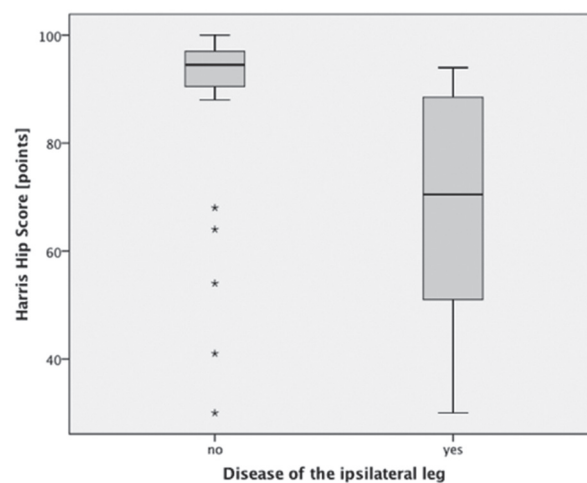


Fig. 4.— HHS relative to a preexisting disease of the ipsilateral leg (n=36)

Table I. — Descriptive statistics and correlations of factors influencing the HHS

Harris Hip Score (points)							
Factor	Value	Amount	Mean HHS	SD	Median HHS	Range	Spearman's ρ $p < 0,05$
ASA score	I	4 (7%)*	89,3	18,5	100	68-100	-0,32
	II	27 (44%)*	87,3	19,5	95	30-100	
	III	12 (19%)*	79,8	19,5	91	48-94	
	IV	0*					
Smoking	no	33 (53%)*	87	16,7	92	41-100	-0,027
	yes	10 (16%)*	79,3	32,9	95	30-98	
Cardiovascular risk factors	no	30 (48%)*	89	17,9	96	30-100	-0,331
	yes	24 (39%)*	79,7	21,3	88	41-100	
Osteoporosis	no	39 (63%)*	85,9	20,5	94,5	30-100	-0,061
	yes	15 (24%)*	85,8	17,6	92	48-100	
Diabetes mellitus	no	49 (91%)*	87,9	18,2	93	30-100	-0,189
	yes	5 (8%)*	61	18,4	61	48-74	
Disease of ipsilateral leg	no	42 (68%)*	87,8	19	96	30-100	-0,459
	yes	11 (18%)*	74,8	19,2	80	48-91	
Disease of spine	no	38 (61%)*	87,4	19,3	96,5	30-100	-0,296
	yes	15 (24%)*	83,7	19,8	91	41-98	
Fracture dislocation	non dislocated	25 (40%)	83,7	19,6	92	30-100	-0,071
	dislocated	37 (60%)	82,9	22,1	93	30-100	
Length of operation	with reduction	62 (100%)	105,9	35,5	95,5	65-217	-0,24
	incision to closure	62 (100%)	69,6	30	62	37-183	-0,15
Position of screws	neutral	30 (48%)	87,7	16,1	92	41-100	-0,133
	anterior	8 (13%)	72,6	27,4	88	30-97	
	posterior	10 (16%)	87,7	12,3	92	64-97	
	inferior	6 (10%)	81	28,6	97	48-98	
	superior	8 (13%)	74,4	30,9	91	30-100	
Number of screws	3	26 (42%)	85,2	22,9	96	30-100	-0,204
	4	36 (58%)	81	18,8	91	41-100	
Reduction	varus	4 (7%)	42	17	42	30-54	-0,132
	neutral	41 (66%)	89,8	15,2	93	41-100	
	valgus	17 (27%)	73,9	22,7	74	30-97	
Time from admission to operation	<6 h	35 (57%)	87,5	17,7	97	41-100	-0,408
	>6 h	27 (43%)	75,5	24,4	88	30-96	
Daytime of operation	8 am to 4 pm	15 (24%)	75,7	26,8	91	30-100	0,05
	4 pm to midnight	36 (58%)	84,8	20,3	93	30-100	
	midnight to 8 am	11 (18%)	85,7	16,4	89	54-100	

* The summation of percentage values does not equal 100 because there were cases with unknown answers.

In the 25 patients younger than 65 years of age, the median HHS was 93 (range 30-100) points, whereas in the 11 patients older than 65 years, the median HHS was 88 points (range 30-97). There was a weak correlation between age at trauma and outcome HHS (Spearman's $\rho=-0,41$, $p<0,05$) (Fig. 3).

Preexisting disease of the ipsilateral leg (previous operations, palsy or trophic changes due to metabolic diseases) was weakly correlated with the resulting Harris Hip Score (Spearman's $\rho=-0,46$, $p<0,01$) (Fig. 4)

Preexisting cardiovascular risk factors (CRFs) were weakly correlated with the resulting Harris Hip Score (Spearman's $\rho=-0,33$, $p<0,05$) (Fig. 5)

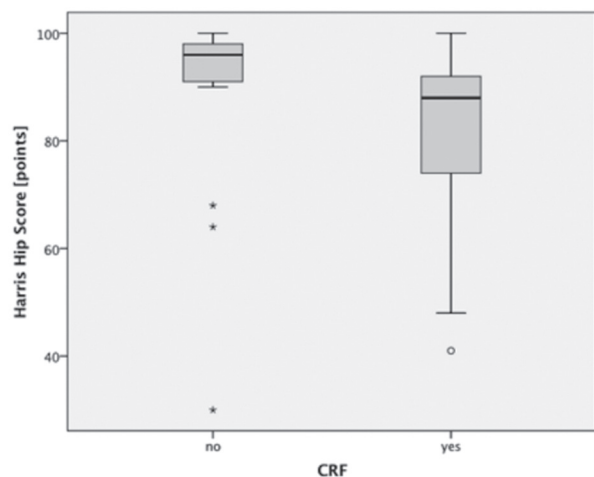


Fig. 5.— Correlation between preexisting CRF and the resulting HHS (Spearman's $\rho=-0,33$, $p<0,05$)

DISCUSSION

The treatment of intracapsular femoral neck fractures in adults remains a challenge with a considerable number of cases of non-union or avascular necrosis. We described good functional outcomes treating these patients with a hybrid construct of cannulated telescoping screws and an angular stable plate (Targon FN). Our study showed a median HHS of 92 points, of whom 26 (72%) attained an excellent or good outcome (Fig. 6) and 10 (28%) a fair or poor outcome. The overall complication rate was 8%. Only one patient required conversion to a total hip prosthesis. Risk factors for a worse functional outcome were age at trauma, time from admission to operation, preexisting cardiovascular risk factors and disease of the ipsilateral leg for the resulting HHS.

We could not find any connecting factor influencing the outcomes of patients with good and poor HHS results except for the age at trauma. In the group with poor results, the mean age was 62 years, compared to 56,6 years in the whole group of patients examined. The report of Humphrey et al. concerning internal fixation of femoral neck stress fractures in young female athletes supports the indication for use of Targon FN in young patients.(12). Additionally, the preexisting cardiac risk factors or a preexisting disease of the ipsilateral leg predisposed patients toward inferior function using this treatment method. Rapid timing of the operation has already been proved to have better results, and this association was emphasized in our study (3,13,14).

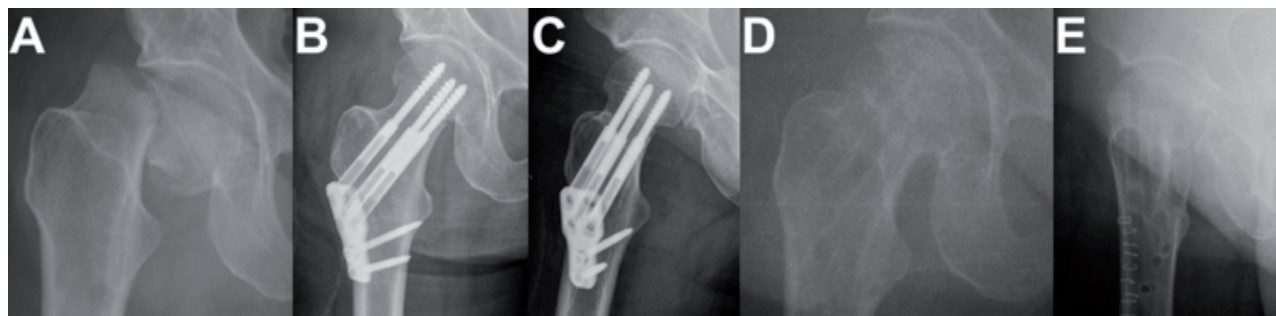


Fig. 6.— A 49-year-old female patient with a Garden IV fracture. The time to surgery was less than 6 hours, and the surgery time was 93 minutes. No perioperative complications occurred. Metal removal was performed after 14 months with a postoperative range of motion: Ext/FI 10-0-130, IR/ER 30-0-50. HHS 96 points. a – ap view at trauma, b – direct postoperative ap view, c – direct postoperative axial view, d – ap view after metal removal, e – axial view after metal removal

The low complication rate proved the quality of this treatment alternative and of the implant chosen. The combination of angular stability with controlled collapse of the fracture area seemed to be advantageous for healing and function. Nevertheless, a follow-up of at least two years is needed to be able to consider these results as definitive (1, 21). In our series, with 21,2 months, the follow-up was nearly two years.

Early results of the 52 patients treated from Eschler et al. (4) showed similar functional results with the Targon FN (n=27) compared to SHS (n=25), with a lower amount of femoral neck shortening in the Targon FN group. Additionally, a lower rate of conversion to hemiarthroplasty in the Targon FN group was noted. In their study, the Targon FN group attained a mean HHS of $69,5 \pm 14,5$ points, whereas in our study, the patients attained a mean HHS of $83,2 \pm 20,9$. According to our previously mentioned correlation of HHS with age at trauma, the mean age of 67 years of the patients in the study of Eschler et al., compared to 56,6 years in our study, might have significantly influenced the outcomes.

In contrast, Thein et al. (21) examined the results of 78 patients treated with Targon FN or multiple cancellous screws (CS) without assessing the HHS score. The treatment was regarded as satisfactory in patients who did not experience failure at the follow-up of at least one year. The data showed lower nonunion rate of 3.2% in Targon FN vs. 46.8% in CS group. The revision rates of Targon FN compared with CS (accordingly 12.9% in Targon FN group vs. 34.0% in CS group) could also be reduced. Nevertheless, the mean time from diagnosis to surgery was 30,3 hours for the Targon FN. We were able to reduce the time to surgery to 4,8 hours, and because this factor appeared to have a significant correlation with HHS, it might have had an influence in our low level of complications. Similarly, Griffin et al. in a study on 83 patients with a mean age of 83 could reach a reduction of a total surgical complication rate to 12,6% with a non-union rate of 2,4% and femoral head necrosis of 2,4% (8).

Biber et al. examined 135 patients in a prospective study of the Targon FN in femoral neck fractures. (2)

The inclusion criteria for head preserving surgery were patient age younger than 60 years of age or older but with an undisplaced fracture. Patients older than 60 years with displaced fractures and the remainder with severe osteoarthritis or renal osteopathy were treated directly with arthroplasty. The data showed a 16% complication rate, while 10% of patients required conversion to a joint replacement. The group reported an underestimated implant perforation rate. We could find one clinically relevant perforation in our series of patients.

The shortcomings of the our study were the use of a retrospective methodology, the involvement of multiple surgeons, among whom everyone required a learning curve, and the missing group treated alternatively, for comparison. With the available numbers of patients, we were not able to find a clear correlation between the fracture classification and the rate of osteonecrosis or nonunion.

There remains little evidence for clear indications to use the Targon FN. Although our data showed satisfactory clinical outcomes, patients with preexisting problems, either with CRFs or disease of the ipsilateral leg, had a higher risk of not achieving a good functional result. In these cases, primary treatment with a hip prosthesis might be a reasonable alternative. However, more clinical and biomechanical evidence is necessary to advocate for regular use of this type of implant to stabilize femoral neck fractures.

CONCLUSIONS

Initial positive experience with the Targon FN suggests that this implant might constitute an advance in the management of the intracapsular fracture and a possible solution to increasing clinical outcomes and reduced complication rates, especially in young, healthy patients.

ACKNOWLEDGEMENTS

This manuscript is based on the analysis of data included in the Dr. med. thesis of RB.

Sources of funding: No outside funding was received for this work.

REFERENCES

1. **Bachiller FG-C, Caballer AP, Portal LF.** Avascular necrosis of the femoral head after femoral neck fracture. *Clin Orthop Relat Res* 2002 ; 87:109.
2. **Biber R, Brem M, Bail HJ.** Targon® Femoral Neck for femoral-neck fracture fixation: lessons learnt from a series of one hundred and thirty five consecutive cases. *Int Orthop* 2013 ; 23;38 : 595-9.
3. **Bonnaire F, Kuner EH, Lorz W.** [Femoral neck fractures in adults: joint sparing operations. II. The significance of surgical timing and implant for development of aseptic femur head necrosis]. *Unfallchirurg* 1995 ; 98 : 259-64.
4. **Eschler A, Brandt S, Gierer P et al.** Angular stable multiple screw fixation (Targon FN) versus standard SHS for the fixation of femoral neck fractures. *Injury* 2014 ; 1;45 : S76-S80.
5. **Florschütz AV, Langford JR, Haidukewych GJ, Koval KJ.** Femoral neck fractures: current management. *J Orthop Trauma* 2015 ; 29 : 121-9.
6. **Garden RS.** Malreduction and avascular necrosis in subcapital fractures of the femur. *J Bone Joint Surg Br* 1971 ; 53 : 183-97.
7. **Gardner S, Weaver MJ, Jerabek S et al.** Predictors of early failure in young patients with displaced femoral neck fractures. *Journal of Orthopaedics* 2014 ; 7;12 : 75-80.
8. **Griffin XL, Parsons N, Achten J et al.** The Targon femoral neck hip screw versus cannulated screws for internal fixation of intracapsular fractures of the hip: a randomised controlled trial. *Bone Joint J* 2014 ; 96-B : 652-7.
9. **Haidukewych GJ, Rothwell WS, Jacofsky DJ et al.** Operative treatment of femoral neck fractures in patients between the ages of fifteen and fifty years. *J Bone Joint Surg Am* 2004 ; 86-A : 1711-6.
10. **Harris WH.** Traumatic arthritis of the hip after dislocation and acetabular fractures: treatment by mold arthroplasty. An end-result study using a new method of result evaluation. *J Bone Joint Surg Am* 1969 ; 51 : 737-55.
11. **Hernlund E, Svedbom A, Ivergård M et al.** Osteoporosis in the European Union: medical management, epidemiology and economic burden. A report prepared in collaboration with the International Osteoporosis Foundation (IOF) and the European Federation of Pharmaceutical Industry Associations (EFPIA). *Arch Osteoporos* 2013 ; 8 : 136-115.
12. **Humphrey JA, Jandoo R, Tofghi M et al.** Internal fixation of femoral neck stress fractures in young female athletes with a dynamic locking plate *Acta Orthopaedica Belgica* 2015 ; 81 : 358-362
13. **Muhm M, Klein D, Weiss C et al.** Mortality after proximal femur fracture with a delay of surgery of more than 48h. *Eur J Trauma Emerg S* 2014 ; 40 : 201-212.
14. **Manninger J, Kazar G, Fekete G et al.** Avoidance of avascular necrosis of the femoral head, following fractures of the femoral neck, by early reduction and internal fixation. *Injury* 1985 ; 16 : 437-48.
15. **Parker MJ, Gurusamy K.** Internal fixation versus arthroplasty for intracapsular proximal femoral fractures in adults. *Cochrane Database Syst Rev* 2006 ; CD001708.
16. **Parker MJ, Raghavan R, Gurusamy K.** Incidence of Fracture-healing Complications after Femoral Neck Fractures. *Clin Orthop Relat Res* 2007 ; PAP:1-5.
17. **Sachse D, Bludau F, Obertacke U.** [Fractures of the neck of the femur in younger patients (15-50 years old). Systematic literature research on medial fractures of the neck of the femur in young patients]. *Unfallchirurg* 2010 ; 113 : 69-74.
18. **Sharma JC, Biyani A, Kalla R et al.** Management of childhood femoral neck fractures. *Injury* 1992 ; 23 : 453-7.
19. **Slobogean GP, Sprague SA, Scott T et al.** Management of young femoral neck fractures: Is there a consensus? *Injury* 2015 ; 46 : 435-40.
20. **Su EP, Su SL.** Femoral neck fractures: a changing paradigm. *Bone Joint J* 2014 ; 96-B : 43-7.
21. **Thein R, Herman A, Kedem P et al.** Osteosynthesis of unstable intracapsular femoral neck fracture by dynamic locking plate or screw fixation: early results. *J Orthop Trauma* 2014 ; 28 : 70-6.
22. **Upadhyay A, Jain P, Mishra P et al.** Delayed internal fixation of fractures of the neck of the femur in young adults. A prospective, randomised study comparing closed and open reduction. *J Bone Joint Surg Br* 2004 ; 86 : 1035-40.