



## Antibiotic impregnated cement coated Ilizarov rod for the management of infected non union of long bone

Tahir A DAR, Shabir A DHAR, Naseer A MIR, Saheel MAAJID, Reyaz A. DAR, Abid HUSSAIN,

*From the SKIMS MC Bemina Srinagar Kashmir India*

The infected non union of the long bones in the presence of the intramedullary nail is a dreaded complication of fracture management. Around 7% patients may develop an infected non union of the long bones in intramedullary nailing. Amongst the various grades of infection, grade three infection is the most difficult to cure and manage as it involves an osteomyelitic bone. Amongst an array of therapeutic modalities, the two stage methods are commonly used with the first stage aimed at controlling the infection and the second stage at inducing union. This increases the number of surgical procedures. We used an Ilizarov threaded rod coated with antibiotic impregnated cement to replace the intramedullary nail with the idea of delivering higher concentration of antibiotic locally as well as provide stability. We achieved a union rate of 91% in a relatively small number of patients with this single procedure. The antibiotic impregnated cement coated Ilizarov rod that we used in our study achieves both infection control and union simultaneously and does not allow cement debonding at removal.

**Keywords** : infected non union ; Ilizarov rod ; antibiotic cement.

### INTRODUCTION

Treatment of non unions is a challenge for orthopaedic surgeons. This challenge is compounded further by the presence of infection. In the clinical setting, chronic bone infection associated with non

union is often seen secondary to open fractures or in a post-operative situation (23).

Conventionally infected non union of long bones is treated by debridement of the infected area, reconstruction of the bony defect, stabilization of the bone and at times creation of a soft tissue cover (6).

The risk of infection following IM nailing of closed long bone fractures is thought to be similar to the general risk of infection after any orthopaedic trauma procedure, but this risk is substantially increased in the setting of open fractures and has been reported to range between 4% and 7% (20). Intramedullary nailing associated with infection is different as the infection tends to involve the whole bone complicating the management.

Romano et al divided infections into three categories (14). The first stage (early) was considered as bacterial cellulitis occurring in the immediate postoperative period usually within 2-6 weeks. The second stage defined between 2 to 9 months

- 
- Tahir A. Dar, MS.
  - Shabir A. Dhar, MS.
  - Naseer A. Mir, MS.
  - Saheel Maajid, MS.
  - Reyaz A. Dar, MS.
  - Abid Hussain, MS.

*SKIMS MC Bemina Srinagar Kashmir India.*

Correspondence : Shabir A. DHAR, SKIMS MC Bemina Srinagar Kashmir India.

E-mail : shabirdhar@yahoo.co.in

© 2017 Acta Orthopaedica Belgica.

*No benefits or funds were received in support of this study. The authors report no conflict of interests.*

post-operatively, is associated with delayed wound healing, wound necrosis or discharge from the operative site. The third stage (late) represents established intramedullary osteomyelitis.

The third stage is the most difficult to manage and treatment options available include the Ilizarov method, bone grafting, debridement and canal irrigation (8). One of the methods reported by Paley et al involves the use of a rod which can be custom-made at the time of surgery, using different diameter chest tubes as molds and embedding a 3-mm beaded guidewire within the cement. The smooth molded surface of this nail makes extraction of the cement rod relatively easy. The cement rod also provides some limited temporary support to the fracture or nonunion site while the infection is being treated. After 6 weeks, the rod can be removed and replaced with a definitive metal intramedullary nail, with or without bone grafting to treat the previously infected fracture or nonunion site (12).

This paper reports 11 consecutive cases of stage three infected non union of the long bones post intramedullary nailing managed by removal of the intramedullary nail and its replacement with an Ilizarov rod coated with antibiotic impregnated cement. This series shows that the second procedure may not be needed as the antibiotic rod itself may induce union while delivering high antibiotic concentrations in the non union area.

## MATERIAL AND METHODS

We studied 11 consecutive cases of infected non union of long bones with stage 3 involvement. All cases had radiologic and clinical evidence of infection along with non union. At the start of the study, we intended to use the antibiotic impregnated cement coated threaded rod to overcome the infection before going on to the final procedure [bone grafting/ fixation]. We found compelling signs of union in these cases at 6-8 weeks when we had intended to remove the coated rod. We continued to keep the rod in place due to the progress in the union. We removed the rods from 12 weeks onward and protected the union with a brace until radiologic union was complete.

The institution ethical committee approval was

taken for the study and informed consent was taken from all the patients after explaining the procedure to them in their own language at the outset.

Patients had drainage around the fracture site and the antibiotic was chosen on the basis of the culture report from the swabs taken from the sinus area. In 4 patients we were able to obtain material for culture by aspirating around the non union area under ultrasound guidance. In two patients the aspirate was culture negative.

Implant removal was performed first. The wound and the entire medullary canal were cleaned with pulse lavage of about 4-5 L of normal saline. The antibiotic-impregnated cement rod was prepared around a threaded Ilizarov rod of a length matching the intramedullary nail that was in place. Antibiotic to bone cement is 25 ml of antibiotic to a pack of 40 g cement. A higher mix ratio would alter the setting time markedly as also the handling properties. We used 2 g of vancomycin and 2 g of gentamicin mixed with every 40 g of bone cement in the cases where we were not able to quantify the infecting organism. In all others the antibiotic used was based on the culture report. A cement coated rod of size 1 mm less than the largest reamer was used. Manual mixing of cement was performed and the cement was applied to the nail in a uniform fashion (Fig. 1). Size of the nail was checked using a nail width measuring scale. In all cases we used hands to mould the cement and did not aim for a uniform mantle. This helped in creating a larger surface area for antibiotic elution.



*Fig. 1a.*— The femoral cement rod



*Fig. 1b.*— The tibial rod. The Herzog bend has been recreated according to the removed nail

All rods were inserted through the portal from which the nail was extracted. In none of the cases was the fracture area opened or debrided.

A complete blood count (CBC), erythrocyte sedimentation rate (ESR), and C-reactive protein (CRP) levels were performed initially and then at regular biweekly intervals to record rising or falling trends. All patients were administered 4-6 weeks of intravenous antibiotics according to the culture reports. Infection control was judged on the basis of discharge from the wound, clinical signs of inflammation, and laboratory parameters like CBC, ESR, and CRP.

## RESULTS

11 consecutive cases were included in this report. All patients were males. The average age of the patients was 33.5 yrs (21-64). In seven patients the femur was involved and in the other 4 the tibia was involved. Six fractures were open and five were closed at the outset. The patients had undergone an average of 2.6 surgeries with a range of 1 to 5. The average duration of the non union was 16.36 months with a range 12-36 months. We were unable to isolate any causative organism in 2 cases. In the other 9 cases staph aureus was isolated in five, E coli in two, Pseudomonas in one and a mixed culture was grown in one case.

In the two cases where we did not grow a culture, we used a combination of Vancomycin and Gentamycin. In five cases Tobramycin was used. In

two cases gentamycin was used and in two more we used Amikacin.

Seven cases had a draining sinus at the outset. All except one healed. The case in whom the sinus persisted at union had a visible sequestrum on Xray.

Ten out of the 11 cases united radiologically and clinically at an average of 13.5 weeks. The range of time to union was 12-23 weeks.

We removed the cement rod in 5 cases including the case who did not go onto union. The other 6 cases did not consent to rod removal.

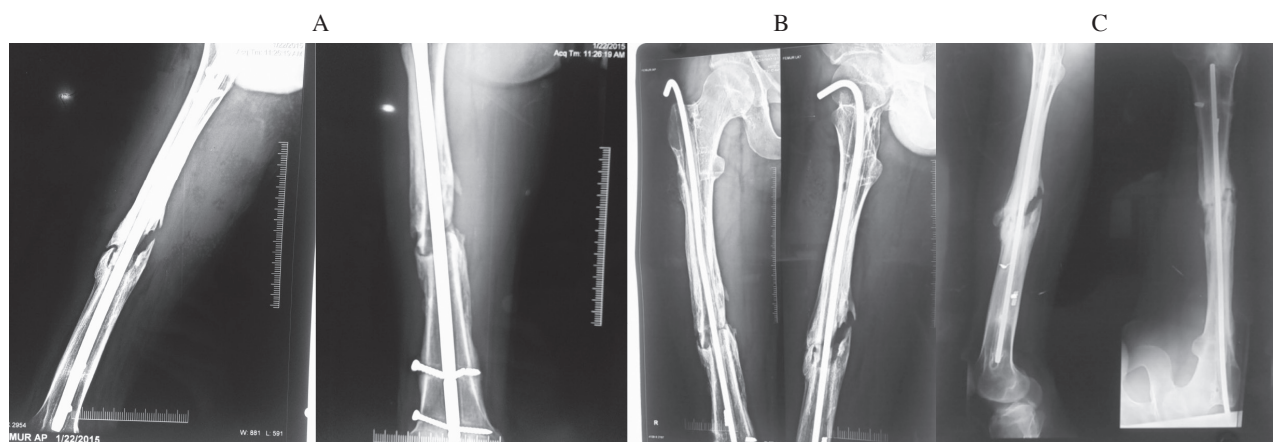
During rod removal of the patient who did not go onto union, we found that the cement in the non union area was absent. This had happened in all probability due to the insertion of a rod on which the cement had not set fully and the cement had got stripped during insertion.

## DISCUSSION

Intramedullary infection leading to non-union of the fracture is a known complication of intramedullary nailing (13) Compound fractures have a higher incidence than closed fractures treated with intramedullary nailing (3,5).

Chronic infection of bone with nonunion and/or bone defects is traditionally treated by a 2-stage procedure involving initial debridement and antibiotic delivery and then definitive stabilization and fixation.

Débridement should include accurate and complete excision of the sinus tract and all infected



**Fig. 2.**— A) Femoral infected non union. B) Antibiotic impregnated rod placed. C) Union at 12 weeks.

avascular tissues, i.e., avascular soft tissue bed (including skin, subcutaneous tissue, fascia, muscle, and scar tissue between bone ends) and avascular bone bed (avascular bone bed can result in persistent infection with drainage). Moreover, proximal and distal medullary canals must be curetted and reamed to remove all necrotic debris.

Stability can be achieved by several means. Nonoperative techniques such as traction or cast immobilization cannot provide acceptable stability and should only be used as a temporary measure in selected cases. Therefore, internal or external fixation are usually employed to obtain adequate stability.

External fixators are used to provide stability (18). The external fixators cause complications with fatty patients and when the bone is already damaged. That is why alternative modes of action have been looked for. Overall, many methods exist for the obliteration of the dead space after radical debridement for necrotic bone and soft tissue, including exteriorization, plompage, cancellous bone grafting or bone substitutes, transfer of living tissue, and the simultaneous treatment of bone and soft tissue with Ilizarov's method (2,10).

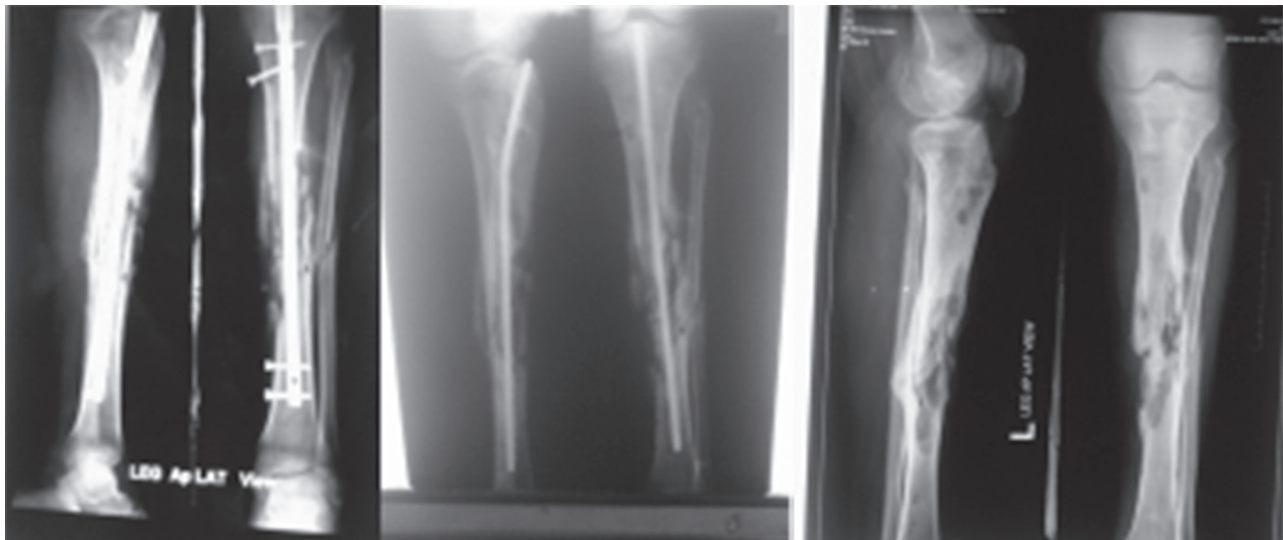
The management of infection after intramedullary nailing of the femoral shaft fracture remains a challenge to orthopedic surgeons. The dilemma confronting surgeons concerns the removal or

retention of the nail in the presence of infection (22). Retention of the intramedullary nail is performed if the fixation is stable and the infection is under control. External fixation is most suitable for uncontrollable osteomyelitis or infected nonunion. Staged bone grafting is usually necessary when a bone defect is present.

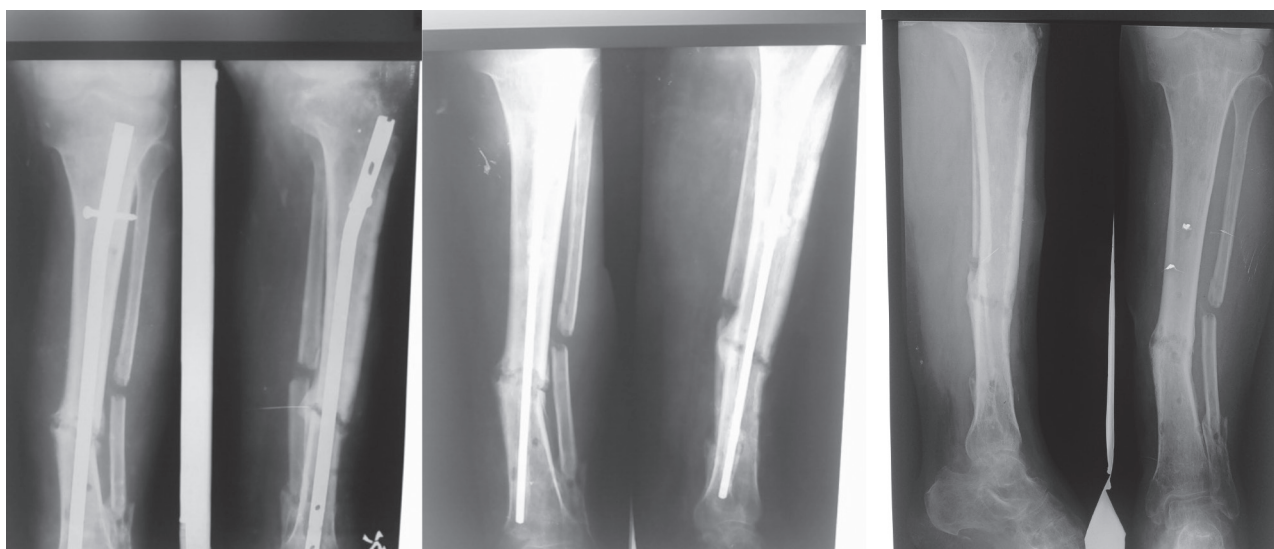
Insertion of antibiotic-impregnated cement beads in and around the infected area is another method that can help in the obliteration of the infection. These beads offer no mechanical support and are difficult to remove if left in place for more than 2 weeks (12). In cases with infected non-union, the primary step is eradication of the infection before attempting to achieve union. Release of antibiotics from the bone cement at a high concentration and its penetration to the surrounding tissues, including cortical and cancellous bone, prompted the use of antibiotic cement in the control of bone infection (17).

The infected foci within the bone are surrounded by a sclerotic, relatively avascular bone covered by a thickened periosteum, scarred muscle and subcutaneous tissue. This avascular envelope of scar tissue leaves systemic antibiotics essentially ineffective.

Antibiotic cement-coated intramedullary nails can be used to treat the infection with high doses of local antibiotics and to provide bone stability. Use of these devices allows immediate weight-bearing



*Fig. 3.*— Tibial infected non union. Union in the radiograph shows a sequestrum which caused persistence of draining sinus.



**Fig. 4.** — Antibiotic impregnated rod used in a tibial non union. The patient had undergone dynamisation also.

and prevents many complications associated with external fixation, such as pin-track infections and joint stiffness (17). Various methods have been developed to make the antibiotic coated nail. Amongst these methods is the use of the chest tube as a dye into which the cement is poured around a guide wire to make the nail. A tape has also been used to make the core of the nail (11,9). However in several studies the antibiotic nail is only used as a space holder and a definitive stabilisation with a nail is performed later (12,11).

The use of cement impregnated with antibiotics was first reported by Bucholz and Engelbrecht (19,1).

A high local concentration of antibiotics and low systemic side effects were the major advantage. Gentamicin has been the most widely used agent followed by vancomycin (7,16,21). Use of two antibiotics, namely gentamicin and vancomycin, with bone cement widens the spectrum of activity and also enhances the elution properties of the two antibiotics (4).

Placing cement around an intramedullary device like a guide wire or a K wire provides added concerns, such as cement nail debonding which may later cause the cement to stay back as a foreign body increasing the chances of formation of the a biofilm and consequent persistence of infection.

We used the Ilizarov rod as it is easily available and could be moulded in the tibia to recreate the Herzog bend. In the femur we could attach a nut and a washer to the top of the rod which allowed easy removal. The thickness of the rod allowed early weight bearing and mobilization as the chance of rod breakage was lesser. There was no case of cement debonding at removal due to the threaded rod. Initially we were apprehensive that the cement mantle would be on the thinner side reducing the delivery of the cement at the infected areas. However our results seem to show that the mantle delivers enough antibiotic to induce union. The uneven surface made as a result of the manual moulding of the cement in all probability increased the speed of delivery of the cement from the rod.

## CONCLUSION

The infected non union of the long bones in the presence of the intramedullary nail is a dreaded complication of fracture management. Amongst an array of therapeutic modalities, the two stage methods are commonly used with the first stage aimed at controlling the infection and the second stage at inducing union. This increases the number of surgical procedures. The antibiotic impregnated cement coated Ilizarov rod that we used in our

study achieves both infection control and union simultaneously and does not allow cement debonding at removal.

## REFERENCES

1. **Buchholz HW, Elson RA, Heinert K.** Antibiotic-loaded acrylic cement: Current concepts. *Clin Orthop Relat Res.* 1984 ; 190 : 96-108.
2. **Chen CE, Ko JY, Wang JW, Wang CJ.** Infection after intramedullary nailing of the femur. *J. Trauma,* 2003 Aug. ; 55 : 338-46
3. **Coles CP, Gross M.** Closed tibial shaft fractures: Management and treatment complications: A review of the prospective literature. *Can. J. Surg.,* 2000 ; 43 : 256-62.
4. **Gallo J, Kolár M, Florschütz AV, Novotný R, Pantůček R, Kesselová M.** In vitro testing of gentamicin-vancomycin loaded bone cement to prevent prosthetic joint infection. *Biomed Pap Med Fac Univ Palacky Olomouc Czech Repub.,* 2005 ; 149 : 153-8.
5. **Joshi D, Ahmed A, Krishna L, Lal Y.** Unreamed interlocking nailing in open fractures of tibia. *J. Orthop. Surg. (Hong Kong),* 2004 ; 12 : 216-21.
6. **Kocaoglu M, Eralp L , Rashid HU, Sen C, Bilsel K.** Reconstruction of segmental bone defects due to chronic osteomyelitis with use of an external fixator and an intramedullary nail. *J. Bone Joint Surg. Am.,* 2006 ; 88 : 2137-2145.
7. **Koo KH, Yang JW, Cho SH, Song HR, Park HB, Ha YC, et al.** Impregnation of vancomycin, gentamicin, and cefotaxime in a cement spacer for two-stage cementless reconstruction in infected total hip arthroplasty. *J. Arthroplasty,* 2001 ; 16 : 882-92.
8. **Kostas G Makridis, Theodoros Tosounidis, and Peter V Giannoudis.** Management of Infection After Intramedullary Nailing of Long Bone Fractures: Treatment Protocols and Outcomes. *Open Orthop. J.,* 2013 ; 7 : 219-226.
9. **Matthews D, Samdany A, Ahmed SU.** An alternative management option for infected non-union of long bone fractures. *J. Clin. Orthop. Trauma,* 2013 ; 4(1) : 43-45.
10. **Maurer DJ, Merkow RL, Gustilo RB.** Infection after intramedullary nailing of severe open tibial fractures initially treated with external fixation. *J. Bone Joint Surg. Am.,* 1989 ; 71 : 835-838.
11. **Oz M, Walter G, Walter G.** Temporary intramedullary stabilisation of infected non-union in long bones with local antibiotic-impregnated cement rods: case reports. *Z. Orthop. Unfall.,* 2010 Sep. ;148 : 559-65.
12. **Paley D, Herzenberg JE.** Intramedullary infections treated with antibiotic cement rods: preliminary results in nine cases. *J. Orthop. Trauma,* 2002 ; 16 : 723-9.
13. **Petrisor B, Anderson S, Court-Brown CM.** Infection after reamed intramedullary nailing of the tibia: A case series review. *J. Orthop. Trauma,* 2005 ; 19 : 437-41.
14. **Romano CL, Romano D, Logoluso N, Drago L.** Bone and joint infections in adults: a comprehensive classification proposal. *Eur. Orthop. Traumatol.,* 2011 ; 1 : 207-17.
15. **Shyam AK, Sancheti PK, Patel SK, Rocha,S, Pradhan S, and Patil A.** Use of antibiotic cement-impregnated intramedullary nail in treatment of infected non-union of long bones. *Indian J. Orthop.,* 2009 ; 43 : 396-402.
16. **Springer BD, Lee GC, Osmon D, Haidukewych GJ, Hanssen AD, Jacofsky DJ.** Systemic safety of high-dose antibiotic-loaded cement spacers after resection of an infected total knee arthroplasty. *Clin. Orthop. Relat. Res.,* 2004 ; 427 : 47-51.
17. **Thonse R, Conway JD.** Antibiotic Cement-Coated Nails for the Treatment of Infected Nonunions and Segmental Bone Defects. *J. Bone Joint Surg. Am.,* 2008 ; 90 : 163-174.
18. **Thonse R, Conway J.** Antibiotic cement-coated interlocking nail for the treatment of infected nonunions and segmental bone defects. *J. Orthop. Trauma,* 2007 ; 21 : 258-68.
19. **Wininger DA, Fass RJ.** Antibiotic-impregnated cement and beads for orthopedic infections. *Antimicrob Agents Chemother.,* 1996 ; 40 : 2675-9.
20. **Young S, Lie SA, Hallan G, Zirkle LG, Engesaeter LB, Havelin LI.** Risk Factors for Infection after 46,113 Intramedullary Nail Operations in Low- and Middle-income Countries. *World J. Surg.,* 2013 ; 37 : 349-55.
21. **Zalavras CG, Patzakis MJ, Holtom P.** Local antibiotic therapy in the treatment of open fractures and osteomyelitis. *Clin. Orthop. Relat. Res.,* 2004 ; 427 : 86-93.
22. **Zych GA, Hutson JJ Jr.** Diagnosis and management of infection after tibial intramedullary nailing. *Clin Orthop Relat Res.* 1995 ; 153-162.
23. **Zhang X, Liu T, Li Z, Peng W.** Reconstruction with callus distraction for nonunion with bone loss and leg shortening caused by suppurative osteomyelitis of the femur. *J Bone Joint Surg. Br.* 2007 ; 89 : 1509-1514.